

POSTTRAUMATIC HIGH-FLOW PRIAPISM: CASE REPORT, CURRENT MANAGEMENT OPTIONS AND LITERATURE REVIEW

Goran Benko¹, Goran Štimac², Josip Katušić², Anđela Barišić³, Borislav Spajić² and Ognjen Kraus²

¹Department of Urology, Varaždin General Hospital, Varaždin; ²University Department of Urology, Sestre milosrdnice University Hospital, Zagreb; ³Department of Urology, Dr. Josip Benčević General Hospital, Slavonski Brod, Croatia

SUMMARY – A rare case of posttraumatic high-flow priapism is presented. A 20-year-old man underwent diagnostic procedure with color Doppler sonography and angiography. On color Doppler sonography and selective and supraseductive angiographic images, arteriocavernosal fistula and pseudoaneurysm were detected in the proximal part of the right cavernous body. Complete detumescence of the penis was achieved by selective embolization with microcoil. No recurrence was observed and postoperative erectile function was incompletely restored. The clinical, diagnostic and therapeutic peculiarities of this rare condition are presented, along with review of the literature on the topic.

Key words: *Penis – injury; Penis – blood supply; Priapism – etiology; Priapism – physiopathology; Priapism – therapy; Case report*

Introduction

Priapism is an uncommon medical condition characterized by persistent tumescence or erection of the penis that is not associated with sexual desire or stimulation¹. High-flow arteriogenic priapism is uncommon and usually occurs after trauma to the genitoperineal area^{1,2}. It is also termed arterial or nonischemic priapism. The onset of prolonged erection can be delayed and is often relatively pain free. The corpora cavernosa are not usually fully rigid. A classic feature of high-flow priapism is painless erection of the cavernous bodies while the corpus spongiosum stays flaccid. A pathologically increased arterial flow can be visualized on color Doppler ultrasound. It is theorized that injury-induced priapism results from arterial damage, in which by-passing of the high-resistance protective system of the helical arteries allows for direct passage of arterial blood to the lacunar space³. These distended spaces would produce partial

compression of the subalbugineal venous system against the tunica itself, causing reduction of venous return with erection³. Without treatment, high-flow priapism will lead to corporeal fibrosis and impaired erectile function. The initial management of nonischemic priapism should be observation. Selective arterial embolization offers the next step for the patient desirous of an immediate resolution². Both nonpermanent (i.e. autologous clot, absorbable gels) and permanent (i.e. coils, ethanol, polyvinyl alcohol particles, and acrylic glue) embolization materials are used^{2,4}.

Case Report

A 20-year-old man was referred to the emergency room of our urologic department with a 16-day history of painless priapism. He had sustained blunt trauma to the perineal region during a football match 2 days before priapism occurred. The trauma was not especially painful. The man had never experienced hematuria or voiding difficulty and was in healthy condition. On examination, the corpora cavernosa were not fully erect and tense. Palpation was not painful. The glans penis

Correspondence to: *Goran Štimac, MD, MS*, University Department of Urology, Sestre milosrdnice University Hospital, Vinogradska c. 29, HR-10000 Zagreb, Croatia

E-mail: goran.stimac2@zg.t-com.hr

Received November 27, 2008, accepted December 30, 2008

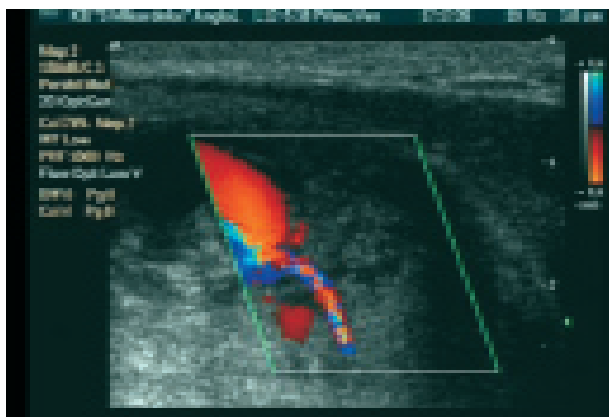


Fig. 1. Pulse wave sagittal color Doppler image showing turbulent flow within the pseudoaneurysm originating from the right cavernosal artery.

was normal. Scrotal and perineal examination was normal, without hematoma. Color Doppler ultrasound was performed immediately to show hyperdynamic blood flow in both cavernous bodies. However, the flow was higher on the right side. The penile veins were open. The right cavernous body had greater width than the

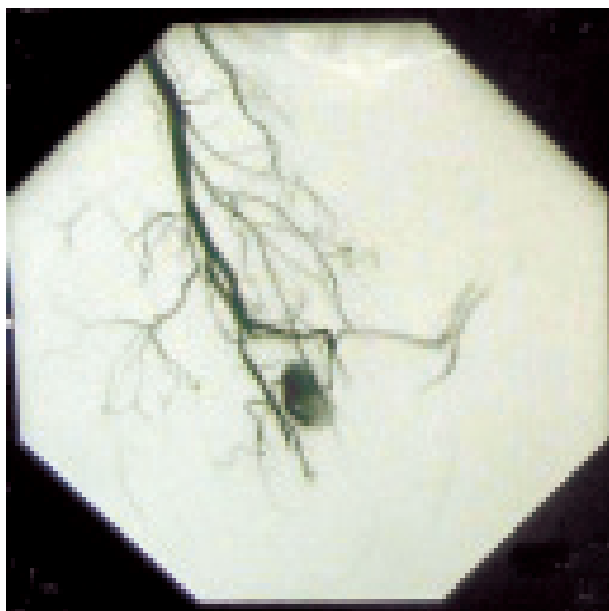


Fig. 2. Selective pelvic digital subtraction angiography with supraselective angiography of the right pudendal artery showing cavernosal pseudoaneurysm originating from the right cavernosal artery. Angiogram shows extravasation of contrast material from the torn vessel, an appearance indicative of arterial laceration.

left one. On the right cavernous body base, an anechoic lesion of 15x10 mm in dimension and arterial fistula were detected in close proximity to the right corpus cavernosum artery. The pulse wave Doppler image showed turbulent flow within the pseudoaneurysm (Fig. 1). High blood flow with low resistance was shown in the proximal right cavernosal artery. Pelvic digital subtraction angiography (DSA) with selective angiography of the right pudendal artery and the left internal iliac artery was performed. Angiography was performed through the left transfemoral approach. On selective and supraseductive images, in the proximal part of the right cavernous body, a pseudoaneurysm was detected and was irrigated from the cavernosal artery (Fig. 2). A pseudoaneurysm was also irrigated from the branches of the left pudendal artery. Supraselective embolization of the right cavernosal artery was performed with microcoils and DSA confirmed occlusion of the fistula. After one month, complete detumescence occurred and incomplete penile rigidity was achieved.

Discussion

High-flow arteriogenic priapism is uncommon and usually occurs after genitoperineal trauma, which may damage a feeding cavernosal artery, leading to an arteriovenous fistula and, occasionally, to an associated pseudoaneurysm. In high-flow priapism, erection develops as a consequence of unregulated arterial blood flow into the corpora cavernosa through a tear of a cavernosal artery. The lacunar endothelium adjacent to the fistula is exposed to oxygenated blood with high velocity and turbulent flow, which creates shear stress and stimulates the release of nitric oxide³. Shear stress and high oxygen tension stimulate the synthesis and release of endothelium-derived nitric oxide, resulting in arterial and trabecular dilatation through the corpora cavernosa. Patients with high-flow priapism usually develop painless partial erection and are able to increase rigidity with sexual stimulation. The venous outflow is maintained, preventing complete erection, stasis, and hypoxia³. Since the clinical presentation of high-flow priapism is not as dramatic as that of the low-flow, ischemic type, the disease is occasionally recognized several days or even months after the onset of symptoms⁵. When the clinical history is indicative of arterial or high-flow priapism, the patient should undergo color Doppler sonography of the penis to look for the possible arterial lesion. In patients with recent arterial laceration, the cavernous tissue sur-

rounding the arterial-sinusoidal fistula appears as a hypoechoic region with undefined margins. In long-standing priapism, this area is usually more regular and circumscribed, mimicking a pseudoaneurysm⁵.

The treatment of high-flow priapism varies from watchful waiting to mechanical compression with ice packs, aspiration and intracavernous administration of alpha-adrenergic agonists, or even open surgery with ligation of the offending artery⁶⁻⁹. As may be expected from the underlying causative mechanism of this form of priapism, these measures often fail. Open surgery poses a significant threat to the surrounding tissues. Most authorities recommend treating high-flow priapism with superselective embolization of the torn artery^{7,10}. Selective embolization of the feeding artery is a commonly used procedure to treat the condition in a minimally invasive fashion. This technique was first employed in 1977 with autologous clot which is not radiopaque, making localization and precision of occlusion difficult^{5,11}. As a result, the use of metallic microcoils has been advocated, as they can be very precisely deposited to produce focal occlusion. Microcoils as a permanent material for embolization allow for definitive injury treatment⁵.

Conclusion

Priapism caused by trauma to the perineum is rare in young subjects. Color Doppler sonography is a useful preangiographic study for localization of the causative lesion and it is currently considered the imaging modality of choice for the diagnosis of high-flow priapism because it is sensitive, noninvasive, and widely available. DSA with supraseductive or selective embolization is a safe and effective method to correct posttraumatic high-flow priapism. In our case, complete detumescence was restored after one month and incomplete postoperative rigidity was achieved.

References

1. PAUTLER SE, BROCK GB. Priapism. *Urol Clin North Am* 2001;28:391-403.
2. PARASCANI R, PALLESCHI G, BOVA G, Di VICCARO D, DRUDI FM, MANDER A, SALVATORI F, CARBONE A. Arteriovenous intracavernous post-traumatic fistula: clinical management and treatment by superselective embolization. *Urology* 2004;63:380-2.
3. KIM N, VARDI Y, PADMA-NATHAN H, DALEY J, GOLDSTEIN I, SAENZ de TEJADA I. Oxygen tension regulates the nitric oxide pathway: physiological role in penile erection. *J Clin Invest* 1993;91:437-42.
4. GONZALEZ EA, PAMPLONA M, RODRIGUEZ A, GARCIA-HIDALGO E, NUNEZ V, LEIVA O. High flow priapism after blunt perineal trauma: resolution with bucrylate embolization. *J Urol* 1994;151:426-8.
5. BERTOLOTTO M, QUAIA E, MUCELLI FP, CIAMPALINI S, FORGACS B, GATTUCCIO I. Color Doppler imaging of posttraumatic priapism before and after selective embolization. *Radiographics* 2003;23:495-503.
6. MABJEESH NJ, SHEMESH D, ABRAMOWITZ HB. Posttraumatic high flow priapism: successful management using duplex guided compression. *J Urol* 1999;161:215-6.
7. BASTUBA MD, SAENZ de TEJADA I, DINLENC CZ, SARAZEN A, KRANE RJ, GOLDSTEIN I. Arterial priapism: diagnosis, treatment, and long-term follow-up. *J Urol* 1994;151:1231-7.
8. ILKAY AK, LEVINE LA. Conservative management of high-flow priapism. *Urology* 1995;46:419-24.
9. STEERS WD, SELBY JB Jr. Use of methylene blue and selective embolization of the pudendal artery for high flow priapism refractory to medical and surgical treatments. *J Urol* 1991;146:1361-3.
10. HAKIM LS, KULAKSIZOGLU H, MULLIGAN R, GREENFIELD A, GOLDSTEIN I. Evolving concepts in the diagnosis and treatment of arterial high flow priapism. *J Urol* 1996;155:541-8.
11. WEAR JB Jr, CRUMMY AB, MUNSON BO. A new approach to the treatment of priapism. *J Urol* 1977;117:252-4.

Sažetak

POSTTRAUMATSKI PRIJAPIZAM: PRIKAZ SLUČAJA, TERAPIJSKE OPCIJE I PREGLED LITERATURE

G. Benko, G. Štimac, J. Katušić, A. Barišić, B. Spajić i O. Kraus

Prikazuje se rijedak slučaj bolesnika s posttraumatskim arterijskim (neishemičnim) prijazmom. U 20-godišnjeg muškarca provedena je dijagnostička obrada obojenim Doppler ultrazvukom i angiografijom. Na obojenom Doppler ultrazvuku, te na selektivnim i supraselektivnim angiografskim snimkama potvrđeno je postojanje arteriokavernozne fistule i pseudoaneurizme. Nakon selektivne embolizacije postignuta je potpuna detumescencija penisa. Poslijeoperacijski nije bilo povrata prijazma i došlo je do nepotpunog oporavka erektilne funkcije. Prikazane su kliničke, dijagnostičke i terapijske osobitosti ovoga rijetkog slučaja, uz pregled relevantne literature.

Ključne riječi: *Penis – ozljeda; Penis – opskrba krvlju; Prijapizam – etiologija; Prijapizam – fiziopatologija; Prijapizam – liječenje; Prikaz slučaja*