

SIGNA VITAE 2009; 4(1): 33 - 34

CASE REPORT

Migration of foreign body from mouth to nose

KOJI YAMAKAWA • HIROSHI DOHGOMORI • TAKEHIKO FURUSAWA • YOSHIHISA SODE • KIMINORI NETSU

HIROSHI DOHGOMORI (✉)
Department of Emergency
and Critical care Medicine
Shinshu University Hospital
3-1-1 Asahi, Matsumoto, Japan
Phone: +81 263 37 2222
Fax: +81 263 37 3028
E-mail: hd5621hd@yahoo.co.jp

KOJI YAMAKAWA •
TAKEHIKO FURUSAWA •
YOSHIHISA SODE •
KIMINORI NETSU
Division of Emergency Medicine
Nagano Red Cross Hospital

ABSTRACT

A man appeared in the Emergency Department complaining of discomfort in his neck because he had swallowed a toothpick while taking a nap. The examining physician could find no foreign body in the patient's mouth or pharynx. An additional examination using a fiberscope disclosed the existence of a foreign body in the nose. The toothpick was thought to have migrated to the nose from the pharynx after it was swallowed. Foreign bodies of various sizes may migrate to the nose from other parts of the body. Therefore, protocols must be designed for additional examination of the nose.

Key words: airway, foreign bodies, migration, toothpick

Case Report

A sixty-nine-year-old man appeared in the Emergency department complaining of discomfort in his neck because he had accidentally swallowed a toothpick while taking a nap. The physician in charge checked the patient's upper airway directly and then with a device for tracheal intubation (Airtraq®) but found no sign suggesting the existence of a foreign body. Next, an otolaryngologist checked the patient using a flexible fiberoptic pharyngeal scope and observed a toothpick in the patient's nasal cavity that was promptly removed. The toothpick, about 5 cm in length, 2 mm in width (figure 1) was thought to have migrated from the pharyngeal region to the nose, according to the physicians' observations (figure 2).

Discussion

Foreign bodies can induce several pathological states. They can also induce airway obstruction, infection,

hemorrhage and other complications, (1,2) including migration to other parts of the body. (3) In addition, misdiagnosis may complicate the case. (4) Critical care management is therefore needed for patients with suspected foreign bod-

ies, especially in the management of the airway.

In the present case, the migration was thought to have occurred after the patient swallowed the wooden toothpick. The toothpick was thought to




Figure 1. A common type of toothpick used in Japan. It measures 6.5 cm in length and 2 mm at its widest point.

have entered the patient's pharyngeal region and by some mechanism, perhaps a cough, migrated to his nose area. Fortunately, it was removed after being directly observed through the fiberscope.

Throughout the literature, there are reports of unusual foreign bodies in the human body, (5) but as far as we are able to ascertain, there have been no reports on the possibility we describe in the present case. From this and other reports, it appears that even straight objects of various sizes can migrate from the pharyngeal or laryngeal region to the nose.

In brief, an object such as a straight stick could migrate from the pharyngeal region to the nose. Therefore, when examining patients complaining of a foreign body, protocols should be designed for examining the airway as well as the nose.

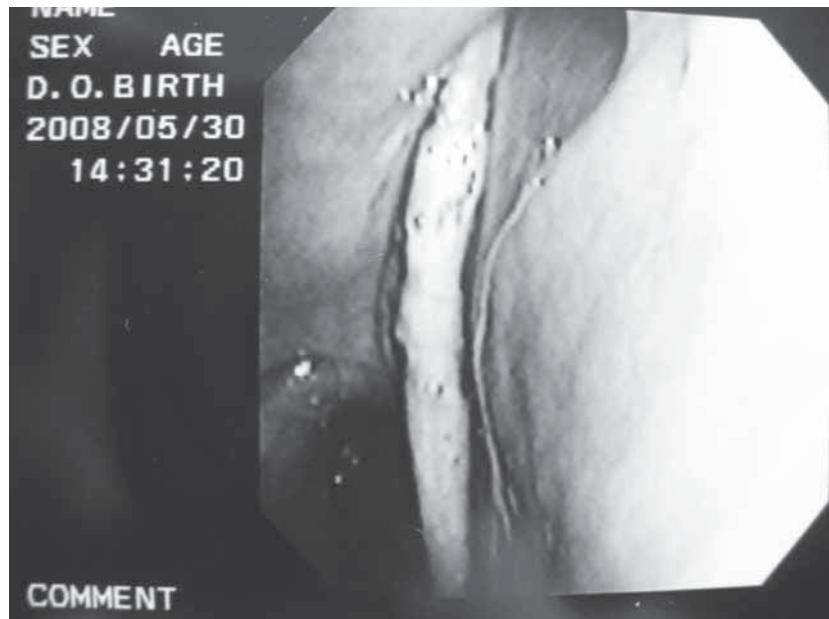


Figure 2. Picture of the toothpick in the nose. The toothpick was found in the nose using a fiberscope.

REFERENCES

1. Pons PT. Foreign bodies. In: Rosen P, Barkin R, editors. Emergency Medicine, concepts and clinical practice. St.Louis: Mosby; 1998. p. 861-77.
2. Heim SW, Maughan KL. Foreign bodies in the ear, nose, and throat. Am Fam Physician 2007;76:1185-9.
3. Cinar Ugur, Vural Cetin, Turgut Suat. A laryngeal foreign body misdiagnosed as asthma bronchiale. E J E M 2003;10:334-6.
4. Chee LW, Sethi DS. Diagnostic and therapeutic approach to migrating foreign bodies. Ann Otol Rhinol Laryngol 1999;108:177-80.
5. Sheikh S, Natarajan B, Johnston A. Foreign body in the hypopharynx, an unusual presentation. EMJ 1996;13:292-3.