

COMBINED MEGALOBLASTIC AND IMMUNOHEMOLYTIC ANEMIA ASSOCIATED – A CASE REPORT

Vesna Vucelić¹, Vladimir Stančić¹, Mario Ledinsky², Biserka Getaldić³, Dragica Sović⁴, Javorka Dodig⁴, Ljiljana Grbac⁵, Petar Gaćina¹, Goran Rinčić¹ and Dubravka Čaržavec¹

¹Department of Hematology; ²University Department of Surgery ³University Department of Clinical Chemistry, ⁴Department of Transfusion Medicine, Sestre milosrdnice University Hospital, Zagreb; ⁵Department of Pediatrics, Požega General Hospital, Požega, Croatia

SUMMARY – A 55-year-old female with a history of psychosis and rheumatoid arthritis was admitted to the hospital for fatigue and dizziness. At admission, macrocytic anemia, high serum lactic acid dehydrogenase (LDH) and gastrin concentrations, decreased serum vitamin B₁₂ concentration, with macroovalocytes and poikilocytes in peripheral blood smear suggested the diagnosis of pernicious anemia. Indirect antiglobulin test (IAT) was negative. Surprisingly, treatment by vitamin B₁₂ and folic acid administered for two weeks was ineffective and followed by transitory worsening of hemoglobin concentration on day 8. Repeat direct antiglobulin test (DAT) and IAT were positive. This immunotransfusion conversion, suggesting the presence of autoimmune hemolytic anemia, could be explained by change in the macroblastic erythrocyte population, i.e. emerging red cells with completely exposed membrane antigens due to vitamin B₁₂ treatment and/or higher degree of dysregulation of the lymphocyte clone secreting erythrocyte autoantibodies. We proposed the coexistence of pernicious and autoimmune hemolytic anemia; therefore, methylprednisolone was added to vitamin B₁₂ treatment. This therapy successfully improved hemoglobin and erythrocyte concentration. Although megaloblastic-pernicious anemia is a common disease, association of pernicious and autoimmune hemolytic anemia with two mechanisms of hemolysis (ineffective erythropoiesis and immune mechanism) is a rare condition, with only several dozens of cases described so far.

Key words: *Anemia, hemolytic – diagnosis; Anemia, hemolytic – therapy; Anemia megaloblastic – drug therapy; Anemia, megaloblastic – diagnosis; Case report*

Introduction

Only several cases of synchronous presentation of pernicious anemia and autoimmune hemolytic anemia (AIHA) have been described¹⁻⁵. There also are rare descriptions of coexistence of pernicious anemia and another autoimmune disease, e.g., of the thyroid or connective tissue, and immune cytopenias^{6,7}. The annual incidence of AIHA is 1/80,000 to 2.6/100,000 in general population. Approximately 18% of AIHA may be caused by medications, 75% of patients with AIHA have sec-

ondary AIHA combined with another disease, and 25% have primary AIHA. According to thermal characteristics of autoantibodies, AIHA is classified as “warm”, usually of IgG class, and as “cold” when the highest reactivity of autoantibodies, usually of IgM class, is recorded at 32 °C⁸. The mechanism leading to immune hemolysis depends on the concentration and biological characteristics of antibodies, i. e. class, subclass and complement activation. A basic test for AIHA is direct antiglobulin test (DAT, Coombs test), which shows the presence of antibodies on erythrocyte membrane. Although never an obligatory part of pretransfusion testing, DAT enables early detection of immune response to a recent transfusion, diagnosis of hemolytic disease in a newborn, and suspected autoimmune or drug induced hemolysis. Positive DAT should never be identified with the diag-

Correspondence to: *Vladimir Stančić, MD*, Department of Hematology, Sestre milosrdnice University Hospital, Vinogradska c. 29, HR-10000 Zagreb, Croatia

E-mail: vladimir.stancic@zg.htnet.hr

Received October 10, 2008, accepted November 19, 2008

nosis of AIHA. In the same way, negative DAT does not necessarily exclude immunologically induced hemolysis. The diagnosis of AIHA with negative DAT may be established when the patient has laboratory and clinical signs of hemolysis, and non-immune causes have been excluded. Approximately 60% of patients with warm AIHA also have circulating autoantibodies in serum, i.e. positive indirect antiglobulin test (IAT). Many patients have only autoantibodies in serum, but some (30%) also have alloantibodies. In most cases with cold AIHA (which accounts for 10%-15% of all AIHA), only the complement is present on erythrocytes. In warm AIHA, the proportion of IgG is 30%-40%, in combination with C3 40%-50%, and of the complement alone 10%-20%. The proportion of DAT-negative AIHA is 2%-4%⁹. Megaloblastic anemias (including a subclass of autoimmune pernicious anemia) are disorders of DNA synthesis, for which vitamin B₁₂ and folic acid are essential as coenzymes. RNA synthesis is continued and faster maturation of the cytoplasm occurs, while the nucleus is relatively immature (asynchronism in maturation of the nucleus and cytoplasm). The first sign of megaloblastic anemia is an increase in the erythrocyte mean corpuscular volume (MCV >100 fL) with macroovalocytosis in peripheral blood smear and hemolysis in the bone marrow compartment due to ineffective erythropoiesis. In advanced megaloblastic anemia, pancytopenia may occur. Except for MCV, high red blood cell distribution width (RDW) showing the presence of anisocytosis is also very important. At the same time, the erythrocyte histogram analysis enables recognition of unimodal and bimodal curves showing changes in cellular population¹⁰. Apart from these parameters, an urgent microscopic check-up of erythrocyte morphology (exclusion of schistocytes, target cells, etc.) is needed for differentiation from other hemolytic anemias.

Case Report

A female patient aged 55 was admitted to the hospital for weakness and exhaustion. She had been treated for schizophrenia, rheumatoid arthritis (RA) and bilateral gonarthrosis for ten years, and in the past five years for hypertension. At admission, the patient was communicative, without psychotic or neurologic symptoms, pale, adynamic and eupneic (14 respiration/min). She was adipose, body weight 117 kg, height 162 cm, and moved with difficulty. Blood pressure was 180/100 mm Hg, pulse 72/min. On palpation, there was no thyroid gland,

peripheral lymph node, liver and spleen enlargement. On auscultation, normal respiratory sounds and cardiac tones without cardiac murmurs were obtained. Laboratory tests on admission were as follows: RBC $1.68 \times 10^{12}/L$; Hb 65 g/L; Hct 0.189 L/L; MCV 112.7 fL (normal range 83.0-97.2 fL); MCH 38.9 pg (27.4-33.3 pg); MCHC 345 g/L (320-345 g/L); RDW 32.8% (9.0-13.8); PLT $87 \times 10^9/L$ (158-424 $\times 10^9/L$); MPV 7.4 fL (6.8-10.4 fL); and WBC $5.4 \times 10^9/L$ (3.4-9.7 $\times 10^9/L$) with 0.80 granulocytes, 0.17 lymphocytes and 0.03 monocytes. RDW index showed RBC polymorphism (microerythrocytes and macroerythrocytes) (Fig. 1).

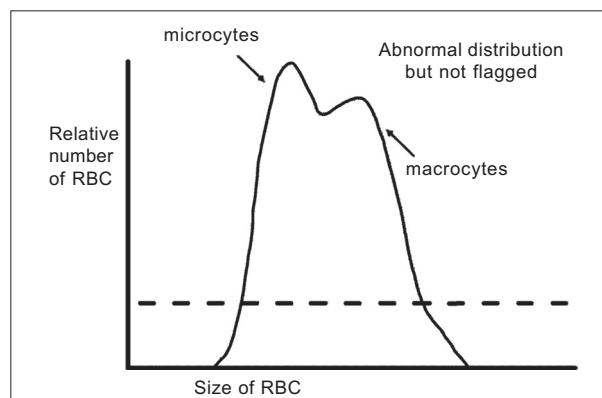


Fig. 1. Red blood cell distribution width (RDW) at admission.

Macroovalocytosis, anisocytosis, poikilocytosis, hyperchromatism and neutrophils with hypersegmented nuclei were found in peripheral blood smear. Serum LDH concentration was extremely high (26,900 U/L), while the concentrations of bilirubin, urobilinogen, creatinine, sodium, potassium, calcium and uric acid were normal. IAT was negative. Serum concentration of vitamin B₁₂ was low (41 pg/mL) and of folic acid normal. The patient refused bone marrow aspiration for fear. Ferritin, iron and TIBC in serum were normal, while gastrin was increased (534 $\mu U/mL$). Analysis of gastric mucosa samples obtained by endoscopy (EGD) and biopsy pointed to the diagnosis of chronic gastritis, without histologic evidence of *Helicobacter pylori* infection.

The clinical picture, macrocytic anemia, high values of LDH, low serum vitamin B₁₂ concentration, high serum gastrin, chronic atrophic gastritis and peripheral blood smear findings were highly suggestive of megaloblastic anemia and justified therapy with 1000 μg of vitamin B₁₂ and 5 mg of folic acid *per* day. Three days later, LDH concentration significantly decreased to 4715 U/L but did not normalize (normal values <241 U/L at 37 °C).

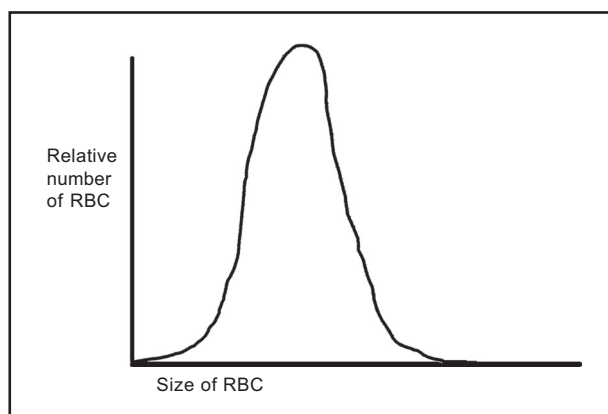


Fig. 2. Red blood cell distribution width (RDW) after vitamin B₁₂ and corticosteroid therapy. Prominent marks: anemia, anisocytosis and macrocytosis.

After 8 days of vitamin B₁₂ and folate administration, hemoglobin concentration and erythrocyte count deteriorated, as follows: RBC $1.27 \times 10^{12}/L$; Hb 54 g/L; Hct 0.157 L/L; MCV 123.4 fL; MCH 42.1 pg; MCHC 341 g/L; RDW 30.3; Rtc 148‰; PLT $76 \times 10^9/L$; and WBC $6.6 \times 10^9/L$. The patient's clinical status was unchanged without short breath or dyspnea. Transfusion of red cells was considered and repeat immunotransfusion assessments were performed: IAT and DAT (anti-IgG, anti-C3d), now being positive. Therapeutic strategy was changed because the finding of immune hemolysis due to AIHA was obviously coexisting synchronously with megaloblastic anemia. Methylprednisolone 120 mg *per* day intravenously (i.v.) was administered and after 48 hours the clinical status improved: RBC $2.40 \times 10^{12}/L$; Hb 80 g/L; Hct 0.242 L/L; MCV 101.0 fL; MCH 33.4 pg; MCHC 331 g/L; RDW 22.3%; Rtc 49‰; PLT $441 \times 10^9/L$; MPV 7.4 fL; and WBC $6.7 \times 10^9/L$. RDW curve changed in one macrocytic population (Fig. 2).

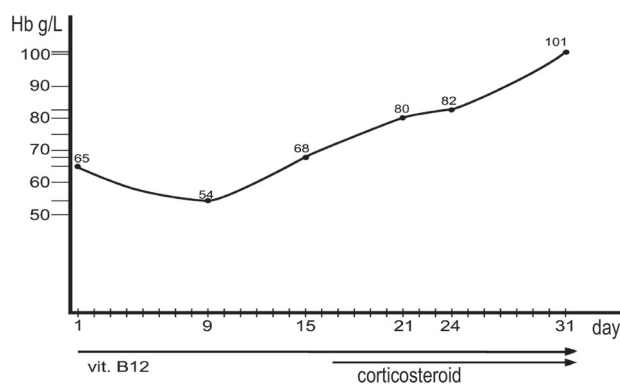


Fig. 3. Diagram of hemoglobin increase with therapy.

Therapy with daily methylprednisolone 80 mg i.v., vitamin B₁₂ 500 mg i.m., twice weekly, and folic acid was continued and followed by continuous rising of hemoglobin level (Fig. 3).

Delayed bone marrow aspiration cytology, done after 21 days of treatment by vitamin B₁₂ and methylprednisolone, did not show changes typical of megaloblastic anemia: marrow was hypercellular due to regeneration, with normoblastic erythropoiesis and mature thrombocytopoiesis and granulocytopoiesis.

At discharge, DAT and IAT tests were still positive; MCV was 98 fL, Hb 91 g/L, while LDH and reticulocytes were slightly elevated. During the last two years of follow up, the patient was well and her hemoglobin concentration was between 120 and 125 g/L on maintenance intermittent methylprednisolone therapy with 8 mg/48 h. Her psychosis and rheumatoid arthritis were well controlled by therapy. She had normal glycemia and her body weight was unchanged.

Discussion

On admission, the clinical picture, macrocytic anemia, high values of LDH and low serum concentration of vitamin B₁₂, endoscopic and histologic picture of chronic atrophic gastritis with high serum gastrin concentration were highly suggestive of pernicious anemia and justified bone marrow analysis. Bone marrow aspiration was not performed because the patient refused the procedure. The administration of 1000 µg of vitamin B₁₂ and 5 mg of folic acid was justified. Four additional points support the thesis of pernicious-megaloblastic anemia: 1) decrease in serum LDH concentration after 36 h of vitamin B₁₂ administration, probably due to reduced early hemolysis in the bone marrow compartment. Extremely high concentration of LDH is due to inefficient erythropoiesis, a large number of megaloblasts in the bone marrow deteriorate, while megalocytes of poor quality and other abnormal erythrocytes are hemolyzed in peripheral blood vessels, producing a high concentration of LDH and indirect bilirubin. The increase in the activity of the LDH1 isoenzyme (prevailing in megalocytes) is greater than the increase in LDH2 (prevailing in normocytes). Such characteristically high LDH values were also found in our patient; 2) pathognomonic "reticulocyte crisis" of 145‰ after 8 days of vitamin B₁₂ therapy; 3) continuous reduction and eventually normalization of erythrocyte MCV on vitamin B₁₂ therapy; and 4) high RDW value, characteristic of macro-

cytic anemia is primarily associated with three conditions: (a) vitamin B₁₂ deficiency, pernicious anemia and post-gastrectomy intestinal disorders; (b) folate deficiency: dietary deficiency, possible in vegetarians, folate destroyed by prolonged cooking, impaired absorption: sprue, increased folate requirements in pregnancy, infancy, hemolytic anemia, and malignancy; and (c) hemolytic anemia that was also diagnosed but simultaneously presented in combination with vitamin B₁₂ deficiency.

Schilling test, serum homocysteine and methylmalonic acid were not done due to technical reasons, but were not crucial in the diagnostic procedure. Bone marrow aspiration was performed on day 21 of hospital stay, after obtaining the patient's consent. In the meantime, hematopoiesis normalized with vitamin B₁₂ treatment and pathognomonic cytomorphological signs of megaloblastic hematopoiesis disappeared.

We proposed that the patient suffered from a combination of two autoimmune diseases, pernicious anemia and secondary autoimmune hemolytic anemia, which, in our opinion, occurred in the context of attenuation of immune surveillance, due to another pre-existent, third autoimmune disease, rheumatoid arthritis. Synchronous conversion of IAT negativity at admission to IAT positivity with intensification of hemolysis, observed after 7 days of vitamin B₁₂ therapy, could be explained by intensification of the synthesis and release of antierythrocyte antibodies by the aberrant, pre-existing lymphocytic population. This nonsuppressed and dysregulated clone could be restimulated by the "burst" of the exposition of now completely conformed epitopes of erythrocyte membrane, induced by vitamin B₁₂ therapy.

Regarding AIHA, many patients with warm AIHA do not need transfusion therapy. Of course, in case of severe and life-threatening anemia, transfusion therapy is necessary. Our patient did not receive transfusion because of excellent response to corticosteroids and stable cardiopulmonary status despite hemoglobin concentration of 54 g/L. If alloantibodies are present in serum, compatible ABO and RhD erythrocytes are transfused. If patients have positive DAT and IAT, it is very difficult to find compatible blood. In this case, "the least positive" blood dose is given, however, only to patients in life-threatening condition because transfusion can speed up hemolysis. The underlying disease, if present, should be primarily treated. Before transfusion, corticosteroid therapy should be initiated (for example, pred-

nisolone 1.5-2.0 g/kg). Approximately 80% of patients respond well to therapy and complete remission of the disease occurs in 20% of patients. The same outcome of corticosteroid therapy was observed in our patient. Some 10% of patients fail to respond to therapy. In these cases, therapy of choice might be splenectomy, plasmapheresis, and administration of cytostatics.

References

- ZAFAD S, MADANI A, HARIF M, QUESSAR A, BENCHEKROUN S. Pernicious anemia associated with autoimmune hemolytic anemia and alopecia areata. *Pediatr Blood Cancer* 2007;49:1017-8.
- BABA AA, MAHARAJ D. Hypocalcaemia in autoimmune haemolytic anaemia and pernicious anaemia. *Postgrad Med J* 1988;64:61-3.
- SALVIDIO E, VENZANO C, BOCCACCIO P, RAVAZZOLO R, GAETANI GF, AJMAR F. Pernicious anaemia followed by autoimmune haemolytic anaemia. *Proc R Soc Med* 1975;68:421-2.
- LAUB M, HORVÁTH K, SZALÓKY P. Autoimmune cytopenia in pernicious anemia. *Orv Hetil* 1993;134:2201-4.
- FELD S, LANDAU Z, GEFEL D, GREEN L, RESNITZKY P. Pernicious anemia, Hashimoto's thyroiditis and Sjögren's syndrome in a woman with SLE and autoimmune hemolytic anemia. *J Rheumatol* 1989;16:258-9.
- RABINOWITZ AP, SACKS Y, CARMEL R. Autoimmune cytopenias in pernicious anemia: a report of four cases and review of the literature. *Eur J Haematol* 1990;44:18-23.
- LU-LUENG SHIH, DEH MING CHANG. Excellent effect of steroid plus azathioprine in a young woman with pernicious anaemia and systemic lupus erythematosus. *Clin Rheumatol* 2000;6:492-4.
- LABAR B, JAKŠIĆ B. Anemije zbog povećane ili ubrzanje razgradnje eritrocita (hemolitičke anemije). In: VRHOVAC B, FRANCETIĆ I, JAKŠIĆ B, LABAR B, VUCELIĆ B, eds. *Interna medicina*. 3rd amended and supplemented edition. Zagreb: Naklada Ljevak, 2003;1020-5.
- MRATINOVIĆ-MIKULANDRA J, JURAKOVIĆ-LONČAR N. Mjesto i uloga direktnog antiglobulinskog testa u prijetransfuzijskom ispitivanju. Prijettransfuzijsko ispitivanje i liječenje bolesnika toplim autoprotiljima. In: GOLUBIĆ-ČEPULIĆ B *et al.*, eds. *Priettransfuzijsko ispitivanje – Klinička transfuziologija*: Zagreb: Zagreb University Hospital Center, 2001;63-74.
- MARGETIĆ S. Medicinskobiokemijska dijagnostika hematoloških bolesti i bolesti sustava zgrušavanja: bolesti eritrocita. In: TOPIĆ E, PRIMORAC D, JANKOVIĆ S, eds. *Medicinskobiokemijska dijagnostika u kliničkoj praksi*. Zagreb: Medicinska naklada: Zagreb, 2004;176-97.

Sažetak

KOMBINIRANA MEGALOBLASTIČNA I IMUNOHEMOLITIČKA ANEMIJA – PRIKAZ SLUČAJA

V. Vucelić, V. Stančić, B. Getaldić, D. Sović, J. Dodig, Lj. Grbac, P. Gaćina, G. Rinčić i D. Čaržavec

Opisuje se 55-godišnja bolesnica koja je primljena u bolnicu zbog slabosti i vrtoglavica. Ranije je bila liječena od reumatoidnog artritisa i psihoze. Pri dolasku su nalazi makrocitne anemije s makroovalocitima i hipersegmentiranim neutrofilima u perifernom razmazu, u serumu visoka koncentracija laktat dehidrogenaze (LDH) i gastrina, te snižena koncentracija vitamina B₁₂ upućivali na dijagnozu perniciozne anemije. Indirektni antiglobulinski test (IAT) bio je negativan. Dvotjedno liječenje vitaminom B₁₂ i folnom kiselinom ne samo da nije imalo učinka, nego se osmog dana liječenja pogoršao stupanj anemije. Razmatralo se liječenje transfuzijom eritrocita, ali su kontrolni IAT i direktni antiglobulinski test (DAT) sada bili pozitivni, što je ukazivalo na autoimunu hemolitičku anemiju (AIHA). Ova imunotransfuziološka konverzija, uz ostale razloge možda vezana i uz dvotjedno liječenje vitaminom B₁₂, mogla je biti uzrokovana pojačanom reaktivnošću i “gubitkom nadzora” klona limfocita koji luče anteritocitna antitijela i/ili promjenama u sazrijevanju i konformaciji eritrocitne membrane makroblasti s jačim izražajem antigena na koje su reagirali “nekontrolirani” limfociti. Anemija je tada shvaćena kao združena pojava perniciozne anemije i AIHA. Dodatkom metilprednisolona vitaminu B₁₂ postignut je porast hemoglobina i eritrocita, a stanje bolesnice se popravilo. Iako je perniciozna anemija česta bolest, udružena perniciozna i autoimuna hemolitička anemija su opisane samo u nekoliko desetaka slučajeva, uglavnom u sastavu drugih autoimunih bolesti.

Ključne riječi: *Anemija, hemolitična – dijagnostika; Anemija, hemolitična – terapija, Anemija, megaloblastična – terapija lijekovima; Anemija, megaloblastična – dijagnostika; Prikaz slučaja*

