

An Overview of Bcl-2 Expression in Histopathological Variants of Basal Cell Carcinoma, Squamous Cell Carcinoma, Actinic Keratosis and Seborrheic Keratosis

Neira Puizina-Ivić¹, Damir Sapunar², Dujomir Marasović¹ and Lina Mirić¹

¹ Clinic of Dermatovenerology, School of Medicine, University of Split, Split, Croatia

² Department of Histology and Embryology, School of Medicine, University of Split, Split, Croatia

ABSTRACT

The Bcl-2 protein has been shown to suppress cell death and protects cell against apoptosis induced by different death-inducing signals. In this study the authors have analyzed immunohistochemically the expression of Bcl-2 protein in the histopathological variants of the most common malignant tumors of the skin – basal cell carcinoma (BCC) and squamous cell tumor (SCC), as well as in the precancerous lesion actinic keratosis (AK) and in benign tumor seborrheic keratosis (SK). Bcl-2 expression in solid, adenoid and cystic variants of BCC exhibited immunoreactivity of tumor stroma with more intense staining among peripheral palisading cells. Morphoeic variant demonstrated reduced amount of Bcl-2 expression. Among SCC in all samples, tumor tissue lack to express Bcl-2 positivity. In cases of hypertrophic and atrophic variants of AK, Bcl-2 expression was confined to basal cell layer, as well as in one case of hypertrophic variant in suprabasal cells. In three histological variants of SK expression of Bcl-2 protein was in areas of basaloid proliferation, while in areas of squamous differentiation was negative. In clonal variant immunostaining was positive among cells in characteristic »nests« Distribution of Bcl-2 protein expression in solid, adenoid and cystic variant of BCC showed that peripheral proliferating cells are protected against apoptosis what permits tumor growth. In morpheiform variant reduced amount of Bcl-2 expression indicated that this variant of BCC has increased cell proliferation, and in practice shows tendency for recurrence and difficulties to eradicate. Bcl-2 expression supports the observation that tumor cells are derived from basal keratinocytes. In SCC, lack of Bcl-2 expression indicates that origin of tumor cells is from more differentiated suprabasal keratinocytes. In AK results suggest that immunoreactivity is regulated with respect of the keratinocyte's differentiation status, but not closely correlate with proliferative rate.

Key words: Bcl-2 protein, programmed cell death, apoptosis, immunohistochemistry

Introduction

A fundamental feature of carcinogenesis is deregulation of normal cellular genes termed proto-oncogenes. The products of activated proto-oncogenes and mutated tumor suppressor-genes act to cause increased cellular proliferation. They contribute to malignancy by inhibiting programmed cell death. In the cell death pathway, bcl-2 is the best understood gene, and it functions as a repressor of programmed cell death¹⁻³.

The cell cycle, which includes cellular proliferation pathways, is regulated by multiple genes. Some of them

are oncogenes which have been divided into two categories: genes that promote cellular proliferation and growth, and genes that regulate apoptosis^{2,3}. Apoptosis is a type of cell death that has been shown to differ from necrosis by well defined ultrastructural and biochemical criteria. bcl-2 is among the most widely studied of those oncogenes known as regulators of apoptotic cell death⁴. Bcl-2 protein is a suppressor of the cell death. It protects a cell against apoptosis induced by different death-inducing signals. So, Bcl-2 expression in tumor or proliferating tis-

sue can predict behavior, prognosis and therapeutic results^{4–8}. In the normal mature human skin, Bcl-2 expression is limited to cells within the basal layer of epidermis, as well as within melanocytes, outer root sheath, dermal papillae of hair follicles, epithelial cells of the secretory coils of eccrine sweat glands and in the excretory ducts of sebaceous glands but not in the suprabasal cell layers of the epidermis^{5,9–11}. It is possible that Bcl-2 positive cells appear to serve as reserve cells from which squamous epithelium renews itself¹¹. Bcl-2 expression may be important for the maintenance of stem cells compartments in tissues that undergo continuous self-renewal^{5,12–14}. Bcl-2 protein is localized on the mitochondrial inner membrane and suppresses apoptotic mode of cell death^{6,7}.

Basal cell carcinoma (BCC) and squamous cell carcinoma (SCC) of the skin are the most common neoplasms which originate from epidermal keratinocytes. Both predominantly develop on sun-exposed sites, either as a result of UV induced DNA damage or UV-induced immunosuppression^{12–15}. BCCs are slow growing tumors taking months to years to reach significant proportions¹⁶. Several explanations for this behavior have been proposed as; tumoral prolongation of the S-phase of the cell cycle; a small proportion of proliferating cells; tumor regression in response to host immune factors; enzyme lysis of adjacent connective tissue and mechanical resistance of the dermis counteracting the expansion of the carcinoma¹⁷. Several histopathological variants exist; solid, adenoid, cystic and morpheic¹⁷. As BCC is thought to arise from basal keratinocytes, Bcl-2 expression is expected in BCC tumor cells.

In SCC, which originate from suprabasal keratinocytes, would be expected to be negative for Bcl-2, as well as in actinic keratosis (AK) whose cells also originate from suprabasal cell layers². According to histopathological variants, there are hypertrophic, atrophic, acantholytic and bowenoid form¹⁷. Seborrheic keratosis (SK) is by far one of the most common benign skin tumors in the dermatological practice. It consists of localized proliferation of basaloid keratinocytes with subsequently papillomatosis and pseudocysts appearance¹.

The aim of this study was to examine in details the distribution of Bcl-2 protein within the normal skin including the epidermis and adnexal structures and compare with distribution in the most frequent histopathological variants of BCC, SCC, AK and SK. The aim was also to evaluate the potential histogenetic origin of particular groups of cells in various variants of these tumors and precancerous lesions.

Materials and Methods

Surgical specimens were obtained from the Outpatient Department Clinical Hospital Center Split. The specimens included: five solid variants of BCC, five adenoid, five cystic and five morpheiform variants of BCC. Among SCC, 10 samples were of the first grade, and ten of second grade according to Broders. Five hypertrophic and five atrophic variants of actinic keratosis and five

acanthotic types, five irritated and five clonal variants of seborrheic keratosis were examined. The samples with minimal pigmentation and contents of melanin were chosen in order to avoid positive results because of melanocyte Bcl-2 expression.

The control group contained ten specimens of normal photoexposed skin obtained from dorsal skin of hands.

The diagnosis was established on 5 µm thickness hematoxylin-eosin (HE) stained sections. For immunohistochemistry the paraffin sections were deparaffinized by placing them through two 10-minute changes of xylene, and then dehydrated in absolute ethanol. Endogenous peroxidase was blocked with 3% hydrogen peroxide in distilled water for 5 minutes. Slides were rehydrated in decreasing concentrations of ethanol, and rinsed in distilled water. To optimize Bcl-2 detection, sections were placed in a thermoresistant jars in citrate buffer, pH 6, and exposed for 10 minutes to microwave fixation at 750 W until boiling to increase immunoreactivity. The slides were removed from oven and left to cool for 20 minutes until room temperature was reached. Slides were then washed in distilled water and in phosphate-buffered saline solution. The specimens were incubated at room temperature for another 30 minutes with monoclonal antibody Bcl-2 at a dilution of 1:500 (M887 DAKO, Glostrup, Denmark). They were then rinsed with phosphate-buffered saline and incubated with biotin-conjugated goat anti-mouse IgG at a dilution of 1:400 for 40 minutes. A biotin-streptavidin detection system was employed with diaminobenzidine (DAB) (Sigma, Bornem, Belgium) as the chromogen. The slides were rinsed repeatedly with phosphate buffered saline and incubated with biotinylated rabbit antimouse immunoglobulin for 30 minutes, and again rinsed with phosphate-buffered saline, and then incubated in 0.5% copper sulfate and lightly counterstained with hematoxylin.

Basal cells and scattered lymphocytes within dermal infiltrates, both of which normally expressed Bcl-2, as well as normal skin sections, served as positive internal controls. Negative controls were sections with omission of the primary antibody, or incubated with an irrelevant antibody.

Results

All specimens were assessed for Bcl-2 expression by immunohistochemical staining. A fine granular brown cytoplasmatic staining of the cells with Bcl-2 was considered positive. In the epidermis of normal photoexposed skin in 10 samples, Bcl-2 expression was uniformly present in the basal cell layer. Epithelial cells in the infundibulum of the hair follicles, cells lining the ducts of sebaceous glands, sebaceous glands and eccrine sweat ducts also showed expression of Bcl-2. The suprabasal layers were consistently negative. Positive expression was found within melanocyte and some cellular components of dermal infiltrate as it was within lymphocytes, plasma cells and endothelial cells (Figure 1).

All variants of BCCs were Bcl-2 positive with homogeneous cytoplasmatic staining throughout the whole lesion, but much more prominent on the periphery of the solid, adenoid and cystic variants (Figures 2–4). Morphoeform variant showed reduced amount of Bcl-2 expression (Figure 5). In all samples of SCCs no one ex-

pressed bcl-2 (Figure 6). In specimens of hypertrophic and atrophic variants of AK, Bcl-2 expression was confined to basal cell layer, as well as in one case of hypertrophic form in suprabasal cells (Figure 7). Five samples of acanthotic and irritated variant of SK revealed positive staining for Bcl-2 expression (Figure 8). The areas of

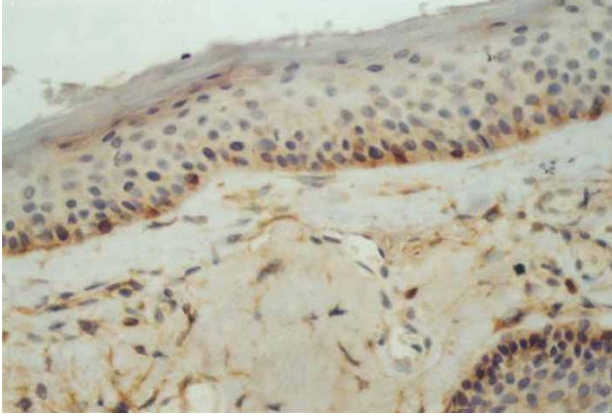


Fig. 1. Immunohistochemical staining with anti-bcl-2 monoclonal antibody of normal photoexposed skin ($\times 40$).

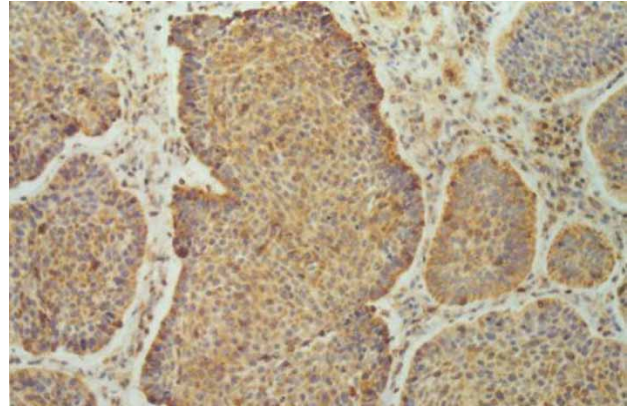


Fig. 2. Immunohistochemical staining with anti-bcl-2 monoclonal antibody of solid variant of basal cell carcinoma ($\times 40$).

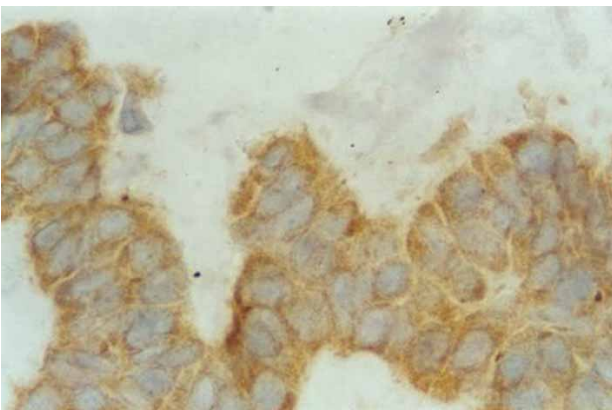


Fig. 3. Immunohistochemical staining with anti-bcl-2 monoclonal antibody of adenoid variant of basal cell carcinoma ($\times 100$).

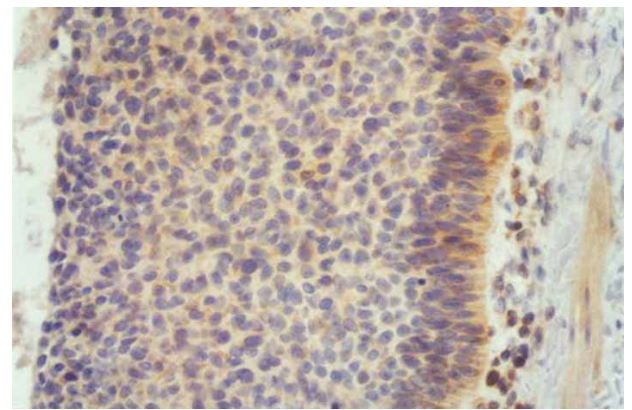


Fig. 4. Immunohistochemical staining with anti-bcl-2 monoclonal antibody of cystic variant of basal cell carcinoma ($\times 40$).

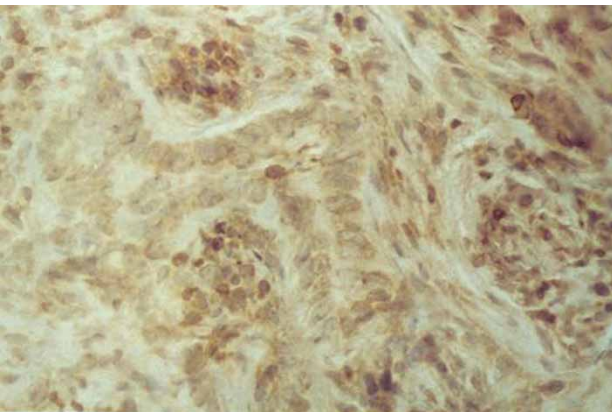


Fig. 5. Immunohistochemical staining with anti-bcl-2 monoclonal antibody of morpheiform variant of basal cell carcinoma ($\times 40$).

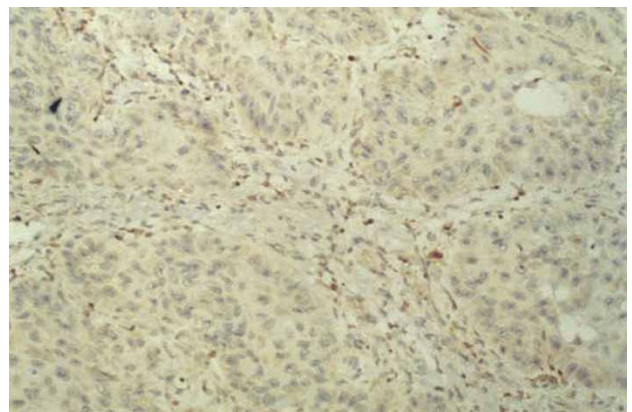


Fig. 6. Immunohistochemical staining with anti-bcl-2 monoclonal antibody of well differentiated squamous cell carcinoma ($\times 40$).

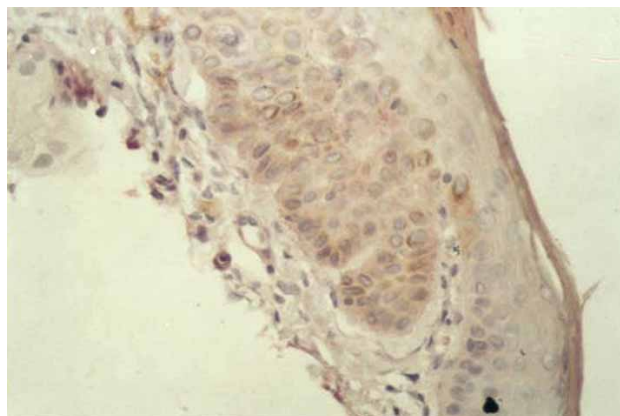


Fig. 7. Immunohistochemical staining with anti-bcl-2 monoclonal antibody of hypertrophic variant of actinic keratosis ($\times 40$).

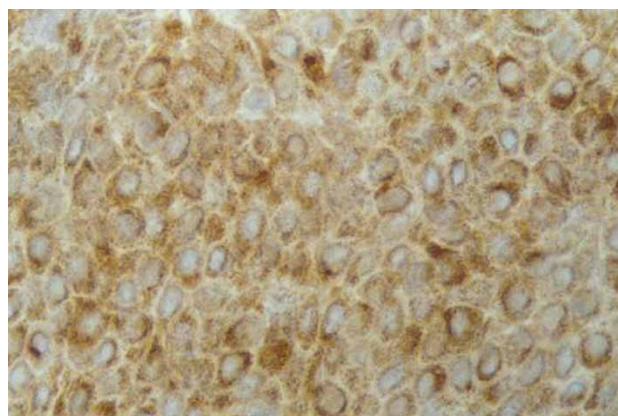


Fig. 8. Immunohistochemical staining with anti-bcl-2 monoclonal antibody of acanthotic variant of seborrheic keratosis ($\times 100$).

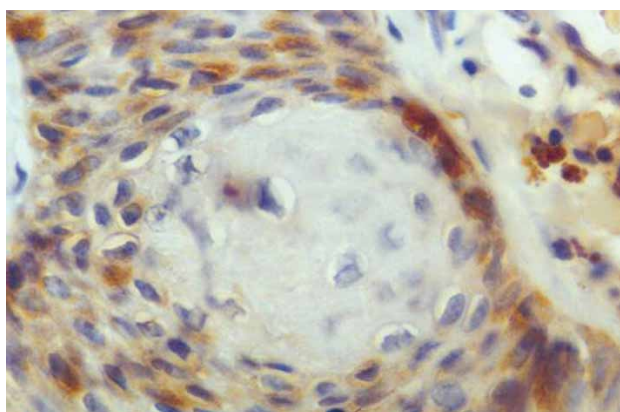


Fig. 9. Immunohistochemical staining with anti-bcl-2 monoclonal antibody of irritated variant of seborrheic keratosis ($\times 100$).

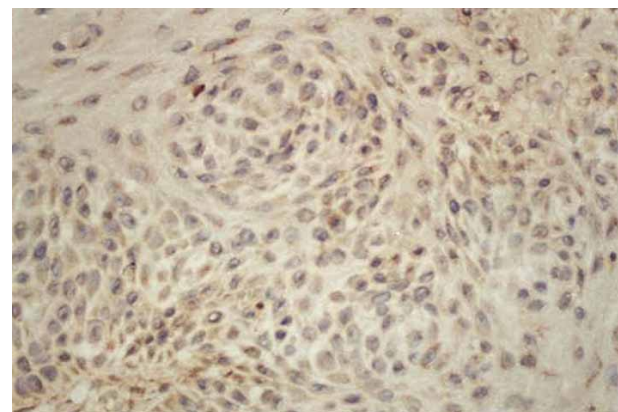


Fig. 10. Immunohistochemical staining with anti-bcl-2 monoclonal antibody of clonal variant of seborrheic keratosis ($\times 40$).

squamous differentiation lacked Bcl-2 expression particularly in irritated variant of SK (Figure 9). Examination of five clonal variants revealed positive immunostaining with anti-bcl-2 within basaloid keratinocytes as well as within characteristic »nests« (Figure 10).

Discussion and Conclusion

The physiologic role of Bcl-2 protein is to prevent or delay programmed cell death during proliferation. The distribution of the Bcl-2 in normal photoexposed skin suggests that expression is limited exclusively to the basal cell layer which has been committed to the formation of the epidermis and adnexal structures⁵. Investigation of Bcl-2 expression revealed that it is not strictly correlated with proliferative rate of keratinocyte but more closely correlates with the differentiation status of the cell. This is possible reason why immunoreactivity is not found in suprabasal and upper layers of epidermis^{5,8–10}. These cells of the basal layer which is the major proliferative compartment, express Bcl-2 that may function in protecting of basal cells from the death after apoptotic stimuli. Consistent with this role, cells whose major

function to give rise to new cell populations are Bcl-2 positive. Suprabasal keratinocytes with subsequent rising to upper parts of epidermis can undergo either apoptosis or much more often terminal differentiation depending upon balance of regulatory factors, intrinsic and external factors^{11,15}. Nakagawa's results are not consistent with these results probably due to the different antibodies and technique used in studies⁶. In this investigation we examined three variations of seborrheic keratosis. The most common type is acanthotic. Irritated type can be found on photoexposed areas or after irritation with chemicals. Pesce and Scalora propose that apoptosis has a role in the squamous differentiation in irritated SK¹⁶. Their results supported hypothesis that in irritated type of SK is decreased binding of epidermal growth factor. They postulated that this variant can correspond with involution phase of the lesion characterized by an altered cell balance¹⁶. On the other side, Ackerman proposed that in this type of SK, squamous eddies represent tangential section of spirals of sebaceous and eccrine ducts through the acanthotic epidermal proliferation¹⁷. Comparing this statement with findings of Bcl-2 immunoreactivity of the excretory duct of sebaceous and eccrine glands, we must

point out that this statement must be changed. This finding gives a new light in the field of histogenesis of this variant of SK. The fact that in clonal variant of SK, basaloid keratinocytes and cells within »nests« are Bcl-2 positive as well as within excretory ducts of sebaceous and eccrine glands in the control normal skin, can indicate

that this variant of SK can represent tangential section of excretory ducts of adnexal epithelium through epidermal proliferation. Further investigations are necessary to be performed maybe with some novel antibodies in order to resolve this dilemma.

REFERENCES

1. KIRKHAM N, Tumors and cysts of the epidermis. In: ELDER D, ELENITSAS R, JAWORSKY C, JOHNSON B Jr (Eds) *Lever's histopathology of the skin* (Lippincott-Raven, Philadelphia, 1997). — 2. MORALES-DUCRET CRJ, VAN DE RIYN M, LEBRUN DP, SMOLLER BR, Arch Dermatol, 131 (1995) 909. — 3. TSUJIMOTO Y, GORHAM J, COSSMAN J, CROCE EM, Science, 229 (1985) 1390. — 4. KERR JFR, WILLIE AH, CURRIE AR, Br J Cancer, 26 (1972) 239. — 5. RODRIGUEZ-VILLANUEVA J, COLOME MI, BRISBAY S, McDONNELL TJ, Path Res Pract, 191 (1995) 391. — 6. NAKAGAWA K, YAMAMURA K, MAEDA S, ICHIHASHI M, Cancer, 74 (1994) 1720. — 7. RASKIN CA, J Am Acad Dermatol, 36 (1997) 885. — 8. VERHAEGH MEJ, SANDERS CJG, ARENDS JW, NEUMAN HAM, Br J Dermatol, 132 (1995) 740. — 9. POLAKOWSKA RR, PIACENTINI M, BARTLETT R, GOLDSMITH LA, HAAKE A, Developmental Dynamics, 199 (1994) 176. — 10. HOCKENBERY DM, OLTVAI ZN, YIN XM, MILLMAN CL, KORSMEYER SJ, Cell, 75 (1993) 241. — 11. HISA T, TANIGUCHI S, KOBAYASHI H, SHIGENAGA Y, NOMURA S, TAKIGAWA M, Acta Derm Venereol, 75 (1995) 412. — 12. BATINAC T, ZAMOLO G, RUŽIĆ A, PERŠIĆ V, Coll Antropol, 31 (2007) 23. — 13. BATINAC T, HADŽIŠEJDIĆ I, BRUMINI G, RUŽIĆ A, VOJNKOVIĆ B, ZAMOLO G, Coll Antropol, 31 (2007) 17. — 14. GRUBER F, ZAMOLO G, KAŠTELAN M, PRPIĆ MASSARI L, ČABRIJAN L, PEHARDA V, BATINAC T, Coll Antropol, 31 (2007) 101. — 15. BORNER C, MONNEY L, OLIVER R, ROSSE T, HACKI J, CONUS S, Cell death and differentiation, 6 (1999) 201. — 16. PESCE C, SCALORA S, J Cutan Pathol, 27 (2000) 121. — 17. ACKERMAN AB, JAKOBSON M, VITALE PA, Clues to diagnosis in Dermatopathology (ASCP Press, Philadelphia, 1993).

N. Puizina-Ivić

Clinic of Dermatovenereology, University Hospital »Split«, Šoltanska 1, 21 000 Split, Croatia
e-mail: neira.puizina@kbsplit.hr

PREGLED IZRAŽAJANOSTI Bcl-2 BJELANČEVINE U HISTOPATOLOŠKIM VARIJANTAMA BAZOCELULARNOG I PLANOCELULARNOG KARCINOMA TE AKTINIČKE I SEBOROJIČNE KERATOZE

SAŽETAK

Pokazalo se da Bcl-2 bjelančevina suprimira staničnu smrt i tako štiti stanice od apoptoze koja je inducirana različitim signalima. U članku, autori proučavaju imunohistokemijsku izražajnost Bcl-2 bjelančevine u histopatološkim varijantama najčešćih malignih tumora kože – bazocelularnom karcinomu (BCC) i planocelularnom karcinomu (SCC), te u prekanceroznoj leziji aktinočke keratoze (AK) te dobroćudnom tumoru – seboroičnoj bradavici (SK). Izražajnost Bcl-2 u solidnoj, adenoidnoj i cističnoj varijanti BCC pokazala se u stromi tumora sa nešto jačom obojanošću perifernih palisadnih slojeva tumora. Morfeiformna varijanta pokazala je slabiju imunoreaktivnost na anti-Bcl-2. Svi uzorci SCC nisu pokazali reaktivnost na anti-Bcl-2 monoklonsko bojanje. U slučaju hipertrofične i atrofične varijante AK, Bcl-2 izražajnost je viđena samo u bazalnom sloju, dok je u samo jednom uzorku hipertrofične varijante viđena i suprabazalno. U sve tri varijante SK izražajnost Bcl-2 bjelančevine je bila ograničena na područja sa bazaloidnom proliferacijom, dok je u područjima sa rožnatom diferencijacijom bila negativna. U klonalnoj varijanti, imunohistokemijski pozitivitet je dokazan unutar karakterističnih »gnijezda«. Izražajnost Bcl-2 bjelančevine u solidnoj, adenoidnoj i cističnoj varijanti BCC, pokazuje da je rubni sloj stanica zaštićen od apoptoze što omogućava rast tumora. U morfeiformnoj varijanti smanjena izražajnost Bcl-2 ukazuje da ova varijanta ima ubranu staničnu proliferaciju te u praksi pokazuje sklonost recidivima uz otežano iskorjenjivanje. Bcl-2 izražajnost potvrđuje da su tumorske stanice nastale iz bazalnoig sloja. U SCC, manjak izražajnosti Bcl-2 ukazuje ja je podrijetlo tumoskih stanica iz bolje diferenciranih suprabazalnih keratinocita. U aktiničkoj keratozi rezultati ukazuju da je imunoreaktivnost određena stupnjem diferencijacije keratoinocita, ali nije usko povezana sa stupnjem proliferacije.