



original scientific paper / izvorni znanstveni rad

SARCOCYSTOSIS IN CLOVEN-HOOFED GAME IN SLOVAK REPUBLIC

MÁRIA GOLDOVÁ¹, ŠTEFAN TÓTH², VALÉRIA LETKOVÁ¹,
JANA MOJŽIŠOVÁ¹, JURAJ CIBEREJ¹, DEAN KONJEVIĆ³,
ALICA KOČIŠOVÁ¹ & ALEN SLAVICA³

¹Department of Parasitology and Infectious Diseases,
University of Veterinary Medicine, Komenského 73, 041 81 Košice,
Slovak Republic

²Department of Histology and Embryology, Faculty of Medicine,
P. J. Šafárik University, Šrobárova 2, 040 01 Košice, Slovak Republic

³Department for Game Biology, Pathology and Breeding,
The Faculty of Veterinary Medicine, University of Zagreb, Heinzelova 55,
10 000 Zagreb, Croatia

Goldová, M., Tóth, Š., Letková, V., Mojžišová, J., Ciberej, J., Konjević, D., Kočišová, A. & Slavica, A.: Sarcocystosis in cloven-hoofed game in Slovak Republic. *Nat. Croat.*, Vol. 17, No. 4, 303–309, 2008, Zagreb.

In this paper, we analyze the results of surveys of *Sarcocystis* spp. carried out on heart and skeletal muscles from 71 ex. of cloven-hoofed game hunted in Central and Eastern Slovakia between 2005 and 2007. *Sarcocystis* infection was determined among 91.5 % of the 71 cloven-hoofed game animals (deer, mouflon, chamois, wild boar): 100% in 13 roe deer, 10 mouflons, 8 fallow deer, and 6 chamois; 85.0 % in 20 wild boars, 78.6 % in 14 red deer. In examined cloven-hoofed game in Slovakia a high intensity of infection of *Sarcocystis* spp., was recorded. The highest intensity of infection was in wild boars (up to 1,495 microcysts per gram) and roe deer (903 microcysts per gram). Animals under one year of age showed low intensity of infection in comparison with adults: red deer (19/g), mouflon (19/g), chamois (19/g) and wild boar (52/g). Muscle samples of males had a significantly higher intensity of infection than females. Intensity of infection was statistically significant in red deer male *versus* calves $p < 0.05$; chamois male *versus* lamb $p < 0.001$, chamois female *versus* lamb $p < 0.001$, chamois male *versus* female $p < 0.05$, wild boar male *versus* female $p < 0.01$, wild boar female *versus* piglet $p < 0.05$. We also present the morphology of thin-walled microcysts of *Sarcocystis* spp. according to histological sections. Light microscopy showed typical features of *Sarcocystis* spp. microcysts in skeletal muscles and myocardium. Thin-walled microcysts were filled with numerous bradyzoites, which are situated inside chamber-like hollows in the cysts.

Key words: cloven-hoofed game, microcyst of *Sarcocystis* spp., prevalence, intensity of infection, histological observation

Goldová, M., Tóth, Š., Letková, V., Mojžišová, J., Ciberej, J., Konjević, D., Kočišová, A. & Slavica, A.: Sarkocistoza papkarske divljači u Slovačkoj. Nat. Croat., Vol. 17, No. 4, 303–309, 2008, Zagreb.

U radu je istraživana prisutnost parazita *Sarcocystis* spp. u poprečno-prugastom srčanom i skeletnom mišiću 71 primjerka papkarske divljači odstrijeljene u razdoblju od 2005. do 2007. na području središnje i istočne Slovačke. Invazija sarkocistama je utvrđena u 91% pregledane divljači (jelenska divljač, muflon, divokoza, divlja svinja), i to u 100% od pregledanih 13 srna, 10 muflona, 8 jelena lopatara i 6 divokoza; 85.0% u 20 pregledanih divljih svinja; 78.6% u pregledanih 14 jelena običnih. Također je u pretražene papkarske divljači zabilježen i visoki intenzitet invazije, najviši u divljih svinja (do 1.495 mikrocista po gramu) i srna (903 mikrociste po gramu). Niži intenzitet invazije zabilježen je u mladunčadi u odnosu na odrasle životinje; jelen obični (19/g), muflon (19/g), divokoza (19/g) i divlja svinja (52/g). Statistički značajno jača invazija utvrđena je u mužjaka negoli u ženki. Nadalje, statistički značajne razlike uočene su u intenzitetu invazije kod mužjaka jelena običnog u odnosu na telad $p < 0.05$; divojaraca u odnosu na janjad $p < 0.001$, divokoza u odnosu na janjad $p < 0.001$, divojaraca u odnosu na divokoze $p < 0.05$, veprova u odnosu na krmače $p < 0.01$ te krmača u odnosu na prasad $p < 0.05$. U radu su također prikazane i morfološke osobitosti mikrocista parazita *Sarcocystis* spp. u poprečno-prugastom skeletnom i srčanom mišiću, prema histološkom prikazu. Mikrociste su bile ispunjene brojnim bradizoitima, smještenima unutar komorica.

Ključne riječi: papkarska divljač, mikrociste parazita *Sarcocystis* spp., prevalencija, jačina invazije, histološka opažanja

INTRODUCTION

Monitoring the health of the wildlife population is important for understanding and controlling possible disease transmission between wildlife and humans or livestock. Parasites whose developmental stages (protozoan or helminth cysts) residing within game muscles are often not noticed by standard veterinary examination of hunted cloven-hoofed game. Except for their zoonotic potential (toxoplasmosis, trichinelosis) the majority of parasites are not in a direct parasite – host relationship, i.e. they do not cause human diseases; they only bring about aesthetic damage of the game meat. However the consumption of insufficiently heat-treated venison that is infected by *Sarcocystis* represents certain health risks for man, as poisonings by thermo-labile sarcosporidian toxin are known (HIEPE, 1991). The impact of Sarcocystosis on game meat hygiene was confirmed by the cases of two people in Germany, who became ill 4 hours after eating lightly fried deer meat. They experienced nausea and vomiting, and shortly afterwards diarrhoea (SCHULZE, 1988).

An important role in the epizootology of tissue parasitoses is played by domestic and wild canids (dog, fox, and wolf) as definitive hosts in the life cycle of *Sarcocystis* spp. This means that sexual reproduction of a parasite takes place in the digestive system of the aforementioned species. Infectious forms of protozoan parasites, oocysts and sporocysts of *Sarcocystis* spp. are thus disseminated into the broad surroundings via their excreta representing a source of infection for hoofed game (EMNETT & HUGHGINS, 1982).

The circulation of heteroxenous coccidia in nature is mostly of a sylvatic character, cloven-hoofed game being infected by sporocysts present in the excreta of foxes,

wolves and stray dogs. A high prevalence of sarcocystosis in cloven-hoofed game depends on the abundance of definite hosts. The highest prevalence of the muscular cysts *Sarcocystis* spp. is recorded in roe deer, which is related to its habits and its frequent visits to places near human residences as well its living in gorges and ditches that foxes like to use (DUBEY *et al.*, 1989).

The aim of our study was to establish the prevalence and intensity of infection of sarcocystosis in cloven-hoofed game in Slovakia together with morphological features of microcysts of *Sarcocystis* spp.

MATERIALS AND METHODS

Samples of heart, and skeletal muscles from 71 cloven-hoofed game (roe, red, fallow deer, mouflon, chamois and wild boar) hunted during 2005 and 2007 in Central and Eastern Slovakia were examined to determinate the prevalence, intensity of infection and morphology of *Sarcocystis* spp. microcysts in muscle samples (Fig. 1).

Animals

In total, seventy one cloven-hoofed game animals of different ages were examined for *Sarcocystis* spp.: 14 red deer (5 male, 5 female, 4 calves) age range 1–2 years, 13 roe deer (8 male, 5 female) age range 1–10 years, 8 fallow deer (4 male, 4 female) age range 2–7 years, 10 mouflons (3 male, 4 female, 3 lambs) age range 0.5–5 years, 6 chamois (2 male, 2 female, 2 lambs) age range 0.5–7 years, 20 wild boars (8 male, 5 female, 7 piglets) age range 0.5–2 years.

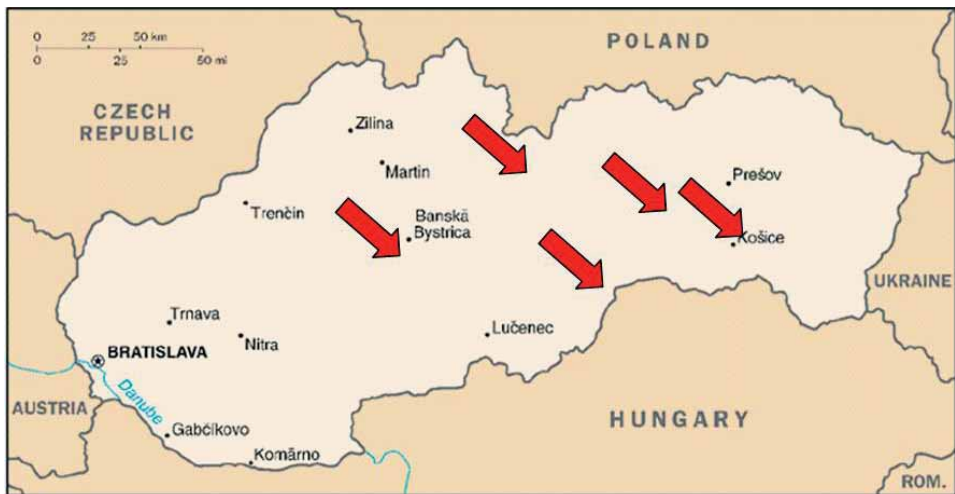

Fig. 1. Localities in Central and Eastern Slovak Republic – origin of samples of cloven-hoofed game.

Methods

1. Trypsine digestive method – *Sarcocystis* spp. microcysts

15 g muscle samples were briefly mixed in 40 ml of digestive solution (buffered solution – pH 7.38 with 25 mg of trypsin); after 30 minutes of trypsination the sample was concentrated and examined with the microscope under x200 and x400 magnifications.

2. Quantitative method – number of microcysts per gram of muscle samples.

Microcysts were counted in 1 millilitre of suspension from the trypsin digestive method and then calculated to one gram of sample.

3. Histological investigation

Tissue samples from heart and skeletal muscles were fixed in 4% neutral formalin and subjected to routine paraffin processing. Histological sections (4–5 µm thick) were stained with Hematoxylin-eosin and examined for histopathological changes, and morphological determination of the *Sarcocystis* spp. microcysts. Histological sections were viewed in an Olympus BX50 light microscope under x100, x200 and x400 magnifications in conjunction with Olympus SP350 and Olympus BX50 cameras. Images were then analyzed using Quick PHOTO MICRO 2.2 software.

4. Statistical analysis

We performed statistical analysis using GraphPad InStat version 3.01 (GraphPad Software, San Diego, CA). The quantitative results were determined by one-way ANOVA with a multiple comparison Tukey-Kramer post hoc test. All the results are expressed as mean ± SEM. P values less than 0.05 were considered significant.

RESULTS AND DISCUSSION

In our study sarcocystosis was determined among 91.5 % of the analysed 71 cloven-hoofed game animals (deer, mouflon, chamois, wild boar) hunted in Central and Eastern Slovakia between 2005 and 2007: 100% *Sarcocystis* spp. were present in examined 13 roe deer, 10 mouflon, 8 fallow deer, and 6 chamois; 85.0 % in 20 wild boars, and 78.6 % in 14 red deer.

In a survey of the prevalence of sarcocystis infection in cloven-hoofed game in Hungary KAVAI & SUGAR (1976) reported that 88 out of 99 roe deer, 46 out of 59 red deer, 39 out of 42 fallow deer, 12 out of 19 mouflon and 12 out of 25 wild boars examined were infected. A high prevalence of *Sarcocystis* spp. infection of cloven-hoofed game was also recorded in Poland. Results revealed sarcocystosis among 24.7% of wild boars, 94.3% of red deer and 88.7% of roe deer (TROIPOLO *et al.*, 2001). In Germany sarcocystosis was determined among 86% of red deer, 87.3% of roe deer, and 90.2% of mouflon (SPICKSCHEN & POHLMAYER, 2002). In the Bitburg-Prum area of Germany 98% of 50 red deer and 86.2% of 114 roe deer were infected (PARTENHEIMER–HANNEMAN, 1991). The prevalence of sarcocystosis in red deer was reported in Lithuania as 70.2% (KUTKIENĖ, 2003), in Spain as 63% (NAVARRETE *et al.*,

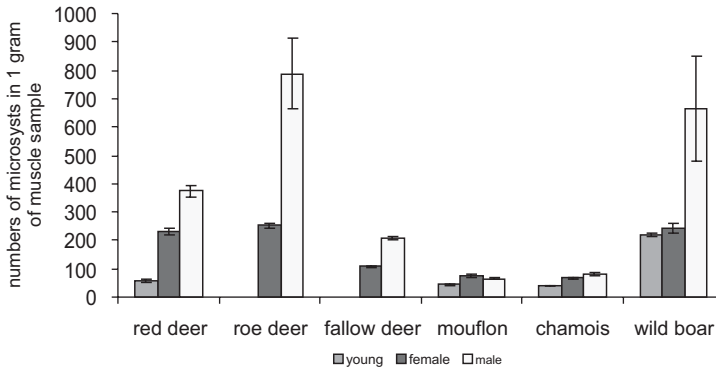


Fig. 2. Intensity of infection of muscles with *Sarcocystis* spp. Significantly higher numbers of *Sarcocystis* microcysts were found in the muscle samples of males than in females.

1978), and in Czechoslovakia as 25% (LUKEŠOVÁ & PÁV, 1989). Examination of 132 roe deer hunted in north-western Spain showed an 85.6% prevalence, the highest density of infection being in the heart, particularly the inner part of the myocardium, with 15 ± 16.8 microcysts/gram of tissue (LOPEZ *et al.*, 2003).

Intensity of infection expressed by number of microcysts in gram of muscle sample was in red deer male 74.8 ± 19.61 , female 43.8 ± 12.74 , calves 15.2 ± 3.8 ; roe deer male 121.2 ± 10.18 , female 50.4 ± 7.73 ; fallow deer male 53.6 ± 5.16 , female 28.6 ± 3.91 ; mouflon male 23.8 ± 2.67 , female 24.4 ± 3.42 , lambs 15.4 ± 1.29 ; chamois male 40.25 ± 1.44 , female 34.25 ± 1.49 , lambs 18.75 ± 0.25 ; wild boar male 29.28 ± 4.26 , female 59.72 ± 7.39 , piglets 36.29 ± 2.97 . There were significantly higher numbers of *Sarcocystis* microcysts in male than in female muscle samples (Fig. 2).

According to our results the highest intensity of infection of cloven-hoofed game in Slovakia was in wild boars (up to 1,495 microcysts per gram) and roe deer (903 microcysts per gram). Animals under one year of age showed low intensity of infection in comparison with adults: red deer (19/g), mouflon (19/g), chamois (19/g) and wild boar (52/g).

Intensity of infection was statistically significant in red deer male *versus* calves $p < 0.05$; chamois male *versus* lamb $p < 0.001$, chamois female *versus* lamb $p < 0.001$, chamois male *versus* female $p < 0.05$, wild boar male *versus* female $p < 0.01$, wild boar female *versus* piglet $p < 0.05$.

Our findings correspond with results described by PARTENHEIMER-HANNEMANN, (1991), who found in red deer males a significantly higher intensity of infection than in females, and higher intensity of infection in adults than in calves. The author did not confirm sex-linked differences in roe deer. Investigation of muscle samples taken from 102 roe deer, 100 red deer and 41 mouflons in Lower Saxony, Germany, showed a significantly lower intensity of infection in fawns, red deer calves and mouflon lambs than in animals older than 2 years (SPICKSCHEN & POHLMEYER, 2002).

In deer, five *Sarcocystis* species was recorded: *S. hofmanni* (red, roe, and fallow deer), *S. capreolicanis* (roe, red deer), *S. grueneri* (red, fallow deer), *S. gracilis* was recorded in the heart of roe deer, and *S. jorrini* in fallow deer. Mouflons, chamois, are intermediate hosts of *Sarcocystis ovicanis* and *S. arieticanis*, which were also recorded in sheep and goats. *Sarcocystis* spp., known in domestic pigs such a *S. miescheriana*, *S. porcifelis* and *S. sui hominis*, were also recorded in wild boars. Species diagnosis is possible according to special digestive methods and also by electron microscopy (HERNANDEZ-RODRIGUEZ *et al.*, 1992; SEDLACZEK & WESEMEIER, 1995; WESEMEIER & SEDLACZEK, 1995; KUTKIENE, 2003).

Histological section examined by light microscopy showed typical features of *Sarcocystis* spp. microcysts in skeletal muscles and myocardium. Thin-walled, elongated muscle cysts up to 0.5 mm in length were filled with bradyzoites located in chamber-like hollows. Surrounding host tissue was without pathological changes or inflammatory reaction. (Fig. 3).

Sarcocystosis in game animals is a frequent, usually accidental finding, which is rarely followed by any notable changes in the affected tissue. According to our study, the highest numbers of infested animals were found among wild boars and roe deer. Animals under one year of age were less frequently affected.

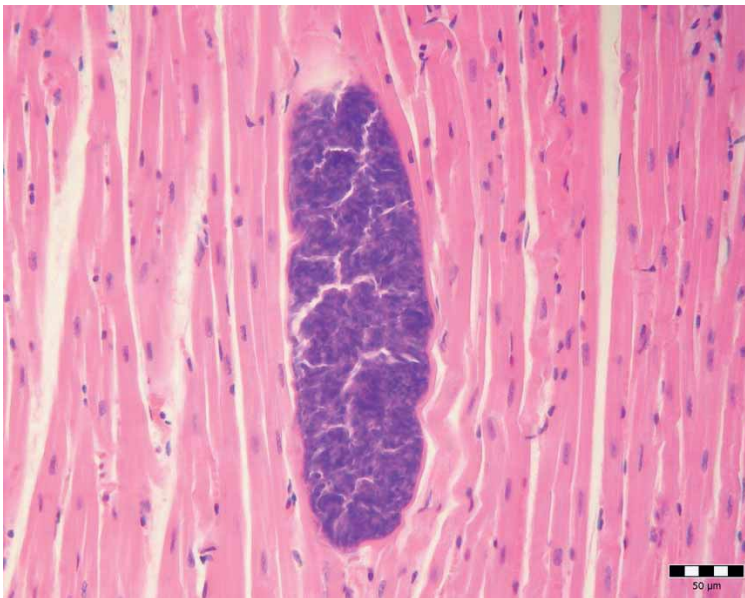


Fig. 3. Microcyst of *Sarcocystis* spp., histological section of myocardium of red deer, HE, magnification x400 (orig.)

ACKNOWLEDGEMENTS

This work was supported by a research grant from the Scientific Grant Agency of The ministry of Education of the Slovak Republic and Slovak Academy of Sciences (Grant 1/1363 /04).

REFERENCES

- DUBEY, J. P., SPEER, C. A. & FAYER, R., 1989: Sarcocystosis of animals and man. Florida: Boca Raton, CRC Press.
- EMNETT, C. W. & HUGGHINS, E. J., 1982: *Sarcocystis* of deer in South Dakota. Journal of wildlife diseases **18**, 2, 187–193.
- HIEPE, T., 1991: The significance of toxic components in the pathogenesis of *Sarcocystis* infections. Nova Acta Leopoldina **66**, 237–246.
- KUTKIENĖ, L. 2003: Investigations of red deer (*Cervus elaphus*) *Sarcocystis* species composition in Lithuania. Acta Zoologica Lithuanica **13**, 390–395.
- LOPEZ, C., PANADERO, R., BRAVO, A., PAZ, A., SANCHEZ-ANDRALE, R., DIEZZ-BANOS, P. & MORRODO, P., 2003: *Sarcocystis* spp. infection in roe deer (*Capreolus capreolus*) from the north-west of Spain. Zeitschrift für Jagdwissenschaft **49**, 3, 211–218.
- LUKEŠOVÁ, D. & PÁV, J., 1989: Sarkocystóza spárkaté zvěře v České socialistické republice. Folia venatoria **34** (19), 173–193.
- NAVARRETE, I., HERNÁNDEZ, S., CALERO, R. & MARTINEZ, F., 1978: The dog as a final host for *Sarcocystis* sp. from the red deer (*Cervus elaphus*). Fourth International Congress of Parasitology, Warszawa. 19–26 August 1978, Short communication Sec B: 78.
- PARTENHEIMER-HANNEMANN, C., 1991: Untersuchung zum Vorkommen von Sarkosporidien bei Reh- und Rotwild im Raum Bitburg-Prüm area (Rheinland-Pfalz). Inaugural-Dissertation, Hannover, Germany: Tierärztliche Hochschule Hannover, 114.
- SCHULZE, K., 1988: Erkrankungen nach dem Verzehr von massiv mit Sarkosporidien befallenen Rehfleisch. Fleischwirtschaft **68**, 1139–1140.
- SEDLACZEK, J. & WESEMEIER, H. H., 1995: On the diagnostics and nomenclature of *Sarcocystis* species (Sporozoa) in roe deer (*Capreolus capreolus*). Applied Parasitology **36**, 73–82.
- SPICKSCHEN, C. & POHLMAYER, K., 2002: Investigation on the occurrence of Sarkosporidien in roe deer, red deer, and mouflon from two different natural habitats in Lower Saxony. Zeitschrift für Jagdwissenschaft **48**, 35–48.
- TROILO, J., KATKIEWICZ, M. T. & WISNIEWSKI, J., 2001: *Sarcocystis* spp. infection in free-living animals: wild boar (*Sus scrofa* L.), deer (*Cervus elaphus* L.), roe deer (*Capreolus capreolus* L.). Polish Journal of Veterinary Sciences **4**, 15–18.
- WESEMEIER, H. H. & SEDLACZEK, J., 1995: One known *Sarcocystis* species and two found for the first time in red deer and wapiti (*Cervus elaphus*) in Europe. Applied Parasitology **36**, 4, 245–251.