

Prognostic Markers and Gene Abnormalities in Subgroups of Diffuse Large B-cell Lymphoma: Single Center Experience

Petra Korać, Mara Dominis

Department of Pathology and
Cytology, Merkur University
Hospital, Zagreb, Croatia

Aim To explore the association between FOXP1, BCL2, and BCL6 gene expression in diffuse large B-cell lymphoma tumor cells and their association with the presence of FOXP3 lymphocytes.

Methods Samples of lymph nodes from 53 patients with newly diagnosed diffuse large B-cell lymphoma were taken at the time of the diagnosis and immunostained for CD10, MUM1, BCL6, BCL2, FOXP1, and FOXP3. Fluorescent in situ hybridization analysis was used for the detection of *FOXP1*, *BCL2*, and *BCL6* gene abnormalities. The χ^2 test was used for data analysis.

Results FOXP1 protein was detected in 28 cases, genetic abnormalities involving the *FOXP1* locus were found in 19 cases, and both were present in 13 cases ($\chi^2=7.157$; $P=0.028$). FOXP3 positive cells were detected in 37 cases. There was a significant relationship between BCL2 expression and *FOXP1* genetic abnormalities ($\chi^2=5.858$; $P=0.016$) and between BCL2 expression and *BCL2* genetic abnormalities ($\chi^2=6.349$; $P=0.012$). There was also an association between *BCL6* and *FOXP1* genetic abnormalities ($\chi^2=8.497$; $P=0.004$).

Conclusion Association was observed between additional FOXP1 gene copies and BCL2 protein expression as well as changes on both FOXP1 and BCL2 genes in samples of our DLBCL patients. FOXP3 positive cells showed no association with presence of any of analyzed proteins considered as a prognostic markers in DLBCL neither with changes of their genes.

Diffuse large B-cell lymphoma represents 30-40% of all non-Hodgkin lymphomas in Western countries (1). Tumor cells are peripheral lymphocytes from germinal centers or a postgerminative stage of B-cell development. Very high percentage of the cells express BCL6, with 30-50% cases showing the expression of BCL2 protein. 3q27 region abnormalities, with the most likely candidate being the *BCL6* gene, are detected in 30% of the cases. The

> **Correspondence to:**

Mara Dominis
Department of Pathology and Cytology
University Hospital Merkur
Zajčeva 19
10000 Zagreb, Croatia
mara.dominis@zg.htnet.hr

> **Received:** March 31, 2008

> **Accepted:** August 26, 2008

> **Croat Med J. 2008;49:618-24**

> doi: 10.3325/cmj.2008.5.618

IgH/BCL2 - t(14;18)(q32;q21) translocation is known to be the oncogenic event underlying the development of follicular lymphoma and is seen in 20-30% of cases of diffuse large B-cell lymphoma (1). Diffuse large B-cell lymphoma shows heterogeneity of its genetic abnormalities and cell type of origin. Many authors have tried to divide diffuse large B-cell lymphoma into groups according to its relationship to normal B-cell counterparts sharing a common gene expression profile (1). The currently accepted subgroups include the germinal center (GC)-like cells subgroup, activated B cell (ABC)-like subgroup, and a third subgroup named simply "type 3," representing all the diffuse large B-cell lymphoma cases that cannot be specified as either GC or ABC subgroup (2-6).

There is a lack of predictive markers that can be reliably and robustly applied to routine diagnosis of diffuse large B-cell lymphoma. Some studies found that *BCL2* and *BCL6* proteins have an impact on diffuse large B-cell lymphoma development and outcome, but there is debate as to whether they can be used as good prognostic markers (1). Other studies have shown that overexpression of *FOXP1* protein has an impact on diffuse large B-cell lymphoma development (7-9). In normal tissue, *FOXP1* expression was observed in scattered cells in germinal centers, in most cells of the mantle zone, and in a few B-cells in the T-cell zone (10). It was found to have stronger expression following B-cell activation (11), to be an essential transcriptional regulator for early B-cell development (12), and to influence *RAG* expression (13). In tumor cells, *FOXP1* shows loss of expression, cytoplasmic localization, or overexpression (10). Translocation of the *FOXP1* gene has been demonstrated in extranodal B-cell lymphoma of marginal zone of MALT type and other B-cell non-Hodgkin lymphomas (14-16).

Other members of *FOXP* family are also known to have a role in tumorigenesis. *FOXP3* mutations can cause IPEX syndrome (immune deregulation, polyendocrinopathy, enteropathy, X-linked syndrome) (17,18). This gene has been recently recognized as a significant factor in the regulation of T-cell activation (19) and as an important gene for the development of regulatory T-lymphocytes (20,21). *FOXP3* immunostaining can be used for detection of Treg cells (22) and has been used for analyzing the correlation between the number of Tregs and the prognosis in follicular lymphoma patients (23,24).

In this study, we investigated the expression and genetic abnormalities of *BCL2*, *BCL6*, and *FOXP1* genes in Croatian patients with diffuse large B-cell lymphoma from a single hematopathology center. Our aim was to determine the association between *FOXP1* and *BCL2*, as previously described by Banham et al (8) and Barrans et al (7), and the differences in this association between GC and ABC subgroup of diffuse large B-cell lymphoma. We were especially interested in the association among *FOXP1*, *BCL2*, and *BCL6*, which would indicate the processes in diffuse large B-cell lymphoma tumor cells. The presence of *FOXP3* positive cells and their association with prognostic markers and/or gene abnormalities in tumor cells was also explored.

Patients and methods

Patients

We have analyzed 53 samples of formalin-fixed paraffin-embedded lymph nodes taken at the time of a diagnosis from patients with *de novo* diffuse large B-cell lymphoma. The patients were 25 women and 28 men with median age of 66 years (range, 23-91). The diagnoses were made by pathologists from the Department of Pathology and Cytology, Merkur University

Hospital according to the World Health Organization criteria (1).

This study is a part of a research project approved by the Ethics Committee of the Zagreb University School of Medicine.

Methods

Immunostaining. Immunostaining was performed on 4 μm -thick formalin-fixed paraffin-embedded lymph nodes sections using the LSAB/HRP kit (Dako, Glostrup, Denmark), according to the manufacturer's instructions. The JC12 anti-FOXP1 and 236A/E7 anti-FOXP3 antibodies were acquired from Dr Alison Banham, Oxford, UK; BCL2-124 from the LRF Immunodiagnostics Unit, Oxford, UK; and BCL6 from Dako.

Cases with more than 30% of positive tumor cells were considered positive. FOXP1 staining intensity was graded as weak (+), moderate (++), or strong (+++).

All cases with at least some FOXP3-positive cells were scored as positive for the presence of Tregs cells.

Diffuse large B-cell lymphomas were divided into GC or ABC types according to the method described by Hans et al (4).

Fluorescent in situ hybridization. Fluorescent in situ hybridization (FISH) was performed according to the protocol described by Ventura et al (25). Abnormalities of the *FOXP1* gene were detected with a break-apart probe (26), abnormalities of *BCL2* gene with a dual color fusion probe (Vysis, Downer's Grove, IL, USA), and abnormalities of *BCL6* gene with a break-apart probe (Vysis). Cut-off values for each FISH probe were determined on 5 sections of non-tumor formalin-fixed paraffin-embedded lymph nodes. Cut-off values for all probes were first found to be in the range between 5% and 7% of tumor cells in a sample with any of the investigated abnormalities (FOXP1 probe 6.3%, BCL2 probe 5.2%;

BCL6 probe 6.9%) and then the value was estimated to be 7%.

Statistical analysis

Differences between the groups were tested using χ^2 test (Statistical Package for the Social Sciences for Windows, version 14.0; SPSS Inc., Chicago, IL, USA). The level of statistical significance was set at 0.05.

Results

Immunostaining

BCL2 and BCL6 protein were expressed in 37 and 17 diffuse large B-cell lymphoma cases, respectively (Figure 1D and 1E). Both proteins were expressed in tumor cells of all positive samples with approximately same intensity. FOXP1 protein was expressed in 28 cases (Figure 1F), with weak staining observed in 10 cases, moderate staining in 7 cases, and strong staining in 11 cases (Table 1). FOXP3 positive infiltrating lymphocytes were found in 37 cases. There were 1%-10% of FOXP3 positive cells in the whole tumor section area in 31 cases and more than 30% of FOXP3 positive cells in 6 cases.

Two or more of the investigated proteins were expressed in the same case of diffuse large B-cell lymphoma (FOXP1 and BCL2 in 15 cases; FOXP1 and BCL6 in 3 cases; and FOXP1, BCL2, and BCL6 in 5 cases). Seven cases were negative for all the investigated proteins.

Fluorescent in situ hybridization

BCL2 locus abnormalities were observed in 15 cases (Figure 1A). The abnormalities were as follows: 5 cases of translocations (five 2F1R1G), 8 cases of amplifications/aneusomy (one 5R2G; seven 3R2G), and 2 cases of both translocation and amplification/aneusomy (one 2F2R1G; one 2F3R1G). *BCL6* abnormalities were observed in 26 cases, as follows

(Figure 1B): 7 cases of translocations (seven 1F1R1G), 14 cases of amplifications/aneusomy (eight 3F; four 4F; two >5F), and 5 cases

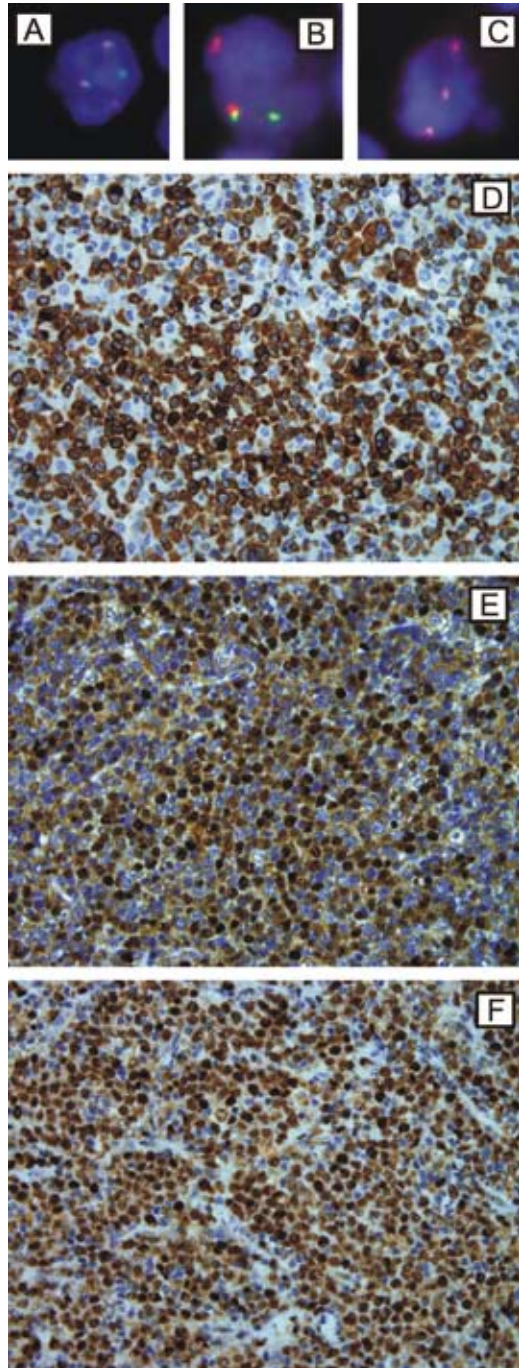


Figure 1. Fluorescent in situ hybridization and immunostaining slides of diffuse large B-cell lymphoma tumor samples. (D) BCL2 immunostaining; (E) BCL6 immunostaining; (F) FOXP1 immunostaining; (A) *IGH/BCL2* translocation (2F1R1G); (B) *BCL6* translocation (1F1R1G); (C) additional FOXP1 gene copy (3F).

of both translocation and amplification/aneusomy (four 2F1R1G; one 3F1R1G). No differentiation was made between amplifications and aneusomy. Only a single case showed a split in the *FOXP1* locus (one 1F1R1G), and additional gene copies/aneusomy of the *FOXP1* probe were seen in 18 cases (13 3F,3 4F,2 5F) (Table 2, Figure 1C). The case with a split in the *FOXP1* locus was checked for *IGH* translocation with an *IGH* break-apart probe (Vysis) and showed a split signal, indicating the presence of *FOXP1/IGH* translocation.

More than one gene abnormality was observed in 17 cases as follows: *BCL2* and *BCL6* in 1 case, *FOXP1* and *BCL2* in 1 case, *FOXP1* and *BCL6* in 6 cases, and *FOXP1*, *BCL2*, and *BCL6* in 9 cases.

FOXP1 gene abnormalities were usually present together with *BCL6* gene abnormalities ($\chi^2_1 = 8.497, P = 0.004$). A significant association was also observed between the absence

Table 1. Immunostaining of BCL2, BCL6, and FOXP1 proteins in tumor cells of 53 patients with diffuse large B-cell lymphoma

Protein	Immunostaining		
	positive	negative	not informative
BCL2	32	21	0
BCL6	17	36	0
FOXP1:*	28		
weak	10		
medium	7		
strong	11		

*Staining was defined as weak (+), medium (++), and strong (+++) (7,8).

Table 2. *BCL2*, *BCL6*, and *FOXP1* gene abnormalities in tumor cells of 53 patients with diffuse large B-cell lymphoma

Abnormality	Gene		
	<i>BCL2</i>	<i>BCL6</i>	<i>FOXP1</i>
No abnormality	35	25	30
Translocation	5	7	1
Additional gene copies	8	14	18
Translocation + additional gene copies	2	5	0
Not informative	3	2	4
Total	53	53	53

Table 3. Intensity of FOXP1 protein expression in relation to *FOXP1* gene abnormalities in 28 patients with FOXP1-positive diffuse large B-cell lymphoma

FOXP1 protein staining*	FOXP1 gene		
	normal	>2 gene copies	not informative
Weak	7	3	0
Moderate	3	4	0
Strong	3	6	2

*Staining was defined as weak (+), medium (++), and strong (+++) (7,8).

of *FOXP1* gene abnormalities and the presence of *BCL2* gene abnormalities ($\chi^2_1 = 10.394$, $P = 0.001$).

Association between genetic abnormalities and protein expression

Cases without *FOXP1* gene abnormalities showed either the presence or absence of expression of *BCL2* protein. However, cases with *FOXP1* gene abnormality showed the expression of *BCL2* protein ($\chi^2_1 = 5.858$, $P = 0.016$). A significant association between *FOXP1* gene abnormalities and FOXP1 protein expression level was also observed. When no gene abnormalities were observed, there was no deregulation of protein expression. Conversely, in cases showing a *FOXP1* translocation or additional gene copy, FOXP1 protein was overexpressed ($\chi^2_2 = 7.157$, $P = 0.028$) (Table 3).

When there was no *BCL2* gene aberration, the *BCL2* protein was or was not expressed, but when there was *IGH/BCL2* translocation or additional *BCL2* gene copy, *BCL2* protein was usually expressed ($\chi^2_1 = 6.349$, $P = 0.012$).

There was no significant association between GC and ABC immunophenotype and abnormalities of FOXP1, either at the genetic or protein level.

There was no association between the presence of FOXP3 positive cells and GC or ABC type. There were also no significant associations between FOXP3 positivity and any of the analyzed diffuse large B-cell lymphoma prognostic markers and between different percentages of FOXP3 positive cells in the samples and *BCL2*, *BCL6*, and FOXP1 protein expression or their gene abnormalities.

Discussion

Our group of diffuse large B-cell lymphoma patients showed additional copy of *FOXP1* gene in 36.7% of cases (18 of 49 samples ade-

quate for interpretation) and FOXP1 protein expression in 58% of cases (28 of 50 samples adequate for interpretation), similar to previously published diffuse large B-cell lymphoma data (4,8,27). FOXP3 positive cells were detected in 37 cases.

Cases with positive FOXP1 expression had varying immunostaining intensities, as was expected (10,15). There was a significant association between *FOXP1* gene abnormality and protein levels – when there were no gene abnormalities, protein expression was present as weak immunostaining intensity and when there was an additional gene copy, protein expression was present as moderate/strong staining. It is possible that cases with additional gene copies or even chromosome 3 gains are actively transcribing FOXP1 and thus yielding higher amounts of protein through gene dosage effects, although this is not the only known mechanism of FOXP1 expression (de)regulation (27,28).

Only a single case showed *FOXP1* translocation. Besides that it also showed *IGH* translocation, thus possibly forming the *FOXP1/IGH* translocation. This case showed no FOXP1 expression, since the total count of FOXP1 positive tumor cells was lower than 30%, suggesting that overexpression of FOXP1 protein is not necessarily a result of gene rearrangement (27,29). This was a morphologically clear case of diffuse large B-cell lymphoma which had no *BCL2* and/or *BCL6* translocations or additional gene copies.

A significant association was found between the presence of *FOXP1* and *BCL6* gene abnormalities. When there was an additional copy of one of these genes, there was also an additional copy of the other. Since both these genes are located on chromosome 3, this is most likely a result of the aneusomy of chromosome 3 (1).

The association between *FOXP1* and *BCL2* gene abnormalities requires further in-

vestigation to discover the mechanism underlying this phenomenon. According to our results, if there is no change on one gene there will be no change on the other gene. However, if there is additional *FOXP1* gene copy then *BCL2* protein will be expressed. This finding is contradictory to the previously described *BCL2* and *FOXP1* association in diffuse large B-cell lymphoma (7) and might be a result of the small number of cases studied in our study.

BCL2 gene abnormalities (both translocations and additional copy numbers) appear together with *BCL2* protein expression, suggesting that *BCL2* expression in diffuse large B-cell lymphoma is regulated by translocations or copy number changes. *IGH/BCL2* translocation has been recognized as a cause for constitutive expression of *BCL2* protein in follicular lymphoma and has been found also in diffuse large B-cell lymphoma (30,31).

We did not find any significant association between GC and ABC group and changes in *FOXP1* gene/protein. This differs from a previous study (7) and suggests that the division of diffuse large B-cell lymphoma based on the tumor cells origin detected by immunohistochemistry is not informative enough, similar to morphological division (1).

FOXP3 expression, indicating the presence of Tregs in a tumor tissue, was also observed, but it did not show any significant association with *BCL2*, *BCL6*, and *FOXP1*. This observation also applies to the abnormalities involving *BCL2*, *BCL6*, and *FOXP1* genes.

Considering *FOXP3* positive cells in our diffuse large B-cell lymphoma group, we found no relation between them and any of the analyzed prognostic markers. This suggests a need for further studies that will investigate whether regulatory T cells have any impact on the processes that take place in diffuse large B-cell lymphoma tumor cells.

In conclusion, the results obtained on 53 patients from the Merkur University Hospital showed that there was an association between *FOXP1* and *BCL2* in diffuse large B-cell lymphoma patients, but their presence was not related to GC or ABC lymphoma subgroups. *FOXP3*-positive T lymphocytes in these entities were present, but their impact on events in B tumor cells is still not clear.

Acknowledgments

We thank Tamara Mohorić, MSc, for the help with statistical data, Dr Davor Solter and Dr Alison Banham for supplying the probes and antibodies, and Dr Roland Ventura for the intellectual input and critical reading of manuscript.

This study was funded by the Croatian Ministry of Science Education, and Sports, research grant No. 108-1081873-1891 "Prognostic value of *FOXP1* and *FOXP3* in B lymphoproliferative disorders."

References

- Gatter KC, Warnke RA. Diffuse large B-cell lymphoma. In: Jaffe ES, Harris NL, Stein H, Vardiman JW, editors. World Health Organization classification of tumours: pathology and genetics of tumours of haematopoietic and lymphoid tissues. Lyon (France): IARC Press; 2001. p. 171-4.
- Lossos IS, Okada CY, Tibshirani R, Warnke R, Vose JM, Greiner TC, et al. Molecular analysis of immunoglobulin genes in diffuse large B-cell lymphomas. *Blood*. 2000;95:1797-803. [Medline:10688840](#)
- Uherova P, Ross CW, Schnitzer B, Singleton TP, Finn WG. The clinical significance of CD10 antigen expression in diffuse large B-cell lymphoma. *Am J Clin Pathol*. 2001;115:582-8. [Medline:11293907](#) [doi:10.1309/84GE-U85A-FMU0-7AUV](#)
- Hans CP, Weisenburger DD, Greiner TC, Gascoyne RD, Delabie J, Ott G, et al. Confirmation of the molecular classification of diffuse large B-cell lymphoma by immunohistochemistry using a tissue microarray. *Blood*. 2004;103:275-82. [Medline:14504078](#) [doi:10.1182/blood-2003-05-1545](#)
- Alizadeh AA, Eisen MB, Davis RE, Ma C, Lossos IS, Rosenwald A, et al. Distinct types of diffuse large B-cell lymphoma identified by gene expression profiling. *Nature*. 2000;403:503-11. [Medline:10676951](#) [doi:10.1038/35000501](#)
- Rosenwald A, Wright G, Chan WC, Connors JM, Campo E, Fisher RI, et al. The use of molecular profiling to predict survival after chemotherapy for diffuse large-B-cell lymphoma. *N Engl J Med*. 2002;346:1937-47. [Medline:12075054](#) [doi:10.1056/NEJMoa012914](#)
- Barrans SL, Fenton JA, Banham A, Owen RG, Jack AS. Strong expression of *FOXP1* identifies a distinct subset of diffuse large B-cell lymphoma (DLBCL) patients with poor outcome. *Blood*. 2004;104:2933-5. [Medline:15238418](#) [doi:10.1182/blood-2004-03-1209](#)
- Banham AH, Connors JM, Brown PJ, Cordell JL, Ott G, Sreenivasan G, et al. Expression of the *FOXP1* transcription

- factor is strongly associated with inferior survival in patients with diffuse large B-cell lymphoma. *Clin Cancer Res.* 2005;11:1065-72. [Medline:15709173](#)
- 9 Kodama K, Massone C, Chott A, Metzger D, Kerl H, Cerroni L. Primary cutaneous large B-cell lymphomas: clinicopathologic features, classification, and prognostic factors in a large series of patients. *Blood.* 2005;106:2491-7. [Medline:15947086](#) [doi:10.1182/blood-2005-03-1175](#)
 - 10 Banham AH, Beasley N, Campo E, Fernandez PL, Fidler C, Gatter K, et al. The FOXP1 winged helix transcription factor is a novel candidate tumor suppressor gene on chromosome 3p. *Cancer Res.* 2001;61:8820-9. [Medline:11751404](#)
 - 11 Shaffer AL, Rosenwald A, Staudt LM. Lymphoid malignancies: the dark side of B-cell differentiation. *Nat Rev Immunol.* 2002;2:920-32. [Medline:12461565](#) [doi:10.1038/nri953](#)
 - 12 Hu H, Wang B, Borde M, Nardone J, Maika S, Allred L, et al. Foxp1 is an essential transcriptional regulator of B cell development. *Nat Immunol.* 2006;7:819-26. [Medline:16819554](#) [doi:10.1038/ni1358](#)
 - 13 Savarese F, Grosschedl R. FOXP1 and RAG1 in B cells. *Nat Immunol.* 2006;7:793-4. [Medline:16855601](#) [doi:10.1038/ni0806-793](#)
 - 14 Streubel B, Vinatzer U, Lamprecht A, Raderer M, Chott AT. (3;14)(p14.1;q32) involving IGH and FOXP1 is a novel recurrent chromosomal aberration in MALT lymphoma. *Leukemia.* 2005;19:652-8. [Medline:15703784](#)
 - 15 Wlodarska I, Veyt E, De Paepe P, Vandenberghe P, Nooijen P, Theate I, et al. FOXP1, a gene highly expressed in a subset of diffuse large B-cell lymphoma, is recurrently targeted by genomic aberrations. *Leukemia.* 2005;19:1299-305. [Medline:15944719](#) [doi:10.1038/sj.leu.2403813](#)
 - 16 Fenton JA, Schuurung E, Barrans SL, Banham AH, Rollinson SJ, Morgan GJ, et al. t(3;14)(p14;q32) results in aberrant expression of FOXP1 in a case of diffuse large B-cell lymphoma. *Genes Chromosomes Cancer.* 2006;45:164-8. [Medline:16252263](#) [doi:10.1002/gcc.20278](#)
 - 17 Chatila TA, Blaeser F, Ho N, Lederman HM, Voulgaropoulos C, Helms C, et al. JM2, encoding a fork head-related protein, is mutated in X-linked autoimmunity-allergic dysregulation syndrome. *J Clin Invest.* 2000;106:R75-81. [Medline:11120765](#) [doi:10.1172/JCI11679](#)
 - 18 Bennett CL, Brunkow ME, Ramsdell F, O'Brian KC, Zhu Q, Fuleihan RL, et al. A rare polyadenylation signal mutation of the FOXP3 gene (AAUAAA→AAUGAA) leads to the IPEX syndrome. *Immunogenetics.* 2001;53:435-9. [Medline:11685453](#) [doi:10.1007/s002510100358](#)
 - 19 Schubert LA, Jeffery E, Zhang Y, Ramsdell F, Ziegler SF. Scurfin (FOXP3) acts as a repressor of transcription and regulates T cell activation. *J Biol Chem.* 2001;276:37672-9. [Medline:11483607](#) [doi:10.1074/jbc.M104521200](#)
 - 20 Khattry R, Cox T, Yasayko SA, Ramsdell F. An essential role for Scurfin in CD4+CD25+ T regulatory cells. *Nat Immunol.* 2003;4:337-42. [Medline:12612581](#) [doi:10.1038/ni909](#)
 - 21 Maloy KJ, Powrie F. Regulatory T cells in the control of immune pathology. *Nat Immunol.* 2001;2:816-22. [Medline:11526392](#) [doi:10.1038/ni0901-816](#)
 - 22 Roncador G, Brown PJ, Maestre L, Hue S, Martínez-Torrecuadrada JL, Ling KL, et al. Analysis of FOXP3 protein expression in human CD4+CD25+ regulatory T cells at the single-cell level. *Eur J Immunol.* 2005;35:1681-91. [Medline:15902688](#) [doi:10.1002/eji.200526189](#)
 - 23 Carreras J, Lopez-Guillermo A, Fox BC, Colomo L, Martinez A, Roncador G, et al. High numbers of tumor-infiltrating FOXP3-positive regulatory T cells are associated with improved overall survival in follicular lymphoma. *Blood.* 2006;108:2957-64. [Medline:16825494](#) [doi:10.1182/blood-2006-04-018218](#)
 - 24 Lee AM, Clear AJ, Calaminici M, Davies AJ, Jordan S, MacDougall F, et al. Number of CD4+ cells and location of forkhead box protein P3-positive cells in diagnostic follicular lymphoma tissue microarrays correlates with outcome. *J Clin Oncol.* 2006;24:5052-9. [Medline:17033038](#) [doi:10.1200/JCO.2006.06.4642](#)
 - 25 Ventura RA, Martin-Subero JI, Jones M, McParland J, Gesk S, Mason DY, et al. FISH analysis for the detection of lymphoma-associated chromosomal abnormalities in routine paraffin-embedded tissue. *J Mol Diagn.* 2006;8:141-51. [Medline:16645199](#) [doi:10.2353/jmoldx.2006.050083](#)
 - 26 Haralambieva E, Adam P, Ventura R, Katzenberger T, Kalla J, Höller S, et al. Genetic rearrangement of FOXP1 is predominantly detected in a subset of diffuse large B-cell lymphomas with extranodal presentation. *Leukemia.* 2006;20:1300-3. [Medline:16673020](#) [doi:10.1038/sj.leu.2404244](#)
 - 27 Goatly A, Bacon CM, Nakamura S, Ye H, Kim I, Brown PJ, et al. FOXP1 abnormalities in lymphoma: translocation breakpoint mapping reveals insights into deregulated transcriptional control. *Mod Pathol.* 2008;21:902-11. [Medline:18487996](#) [doi:10.1038/modpathol.2008.74](#)
 - 28 Brown PJ, Ashe SL, Leich E, Burek C, Barrans S, Fenton JA, et al. Potentially oncogenic B-cell activation-induced smaller isoforms of FOXP1 are highly expressed in the activated B cell-like subtype of DLBCL. *Blood.* 2008;111:2816-24. [Medline:18077790](#) [doi:10.1182/blood-2007-09-115113](#)
 - 29 Barrans SL, Fenton JA, Ventura R, Smith A, Banham AH, Jack AS. Deregulated over expression of FOXP1 protein in diffuse large B-cell lymphoma does not occur as a result of gene rearrangement. *Haematologica.* 2007;92:863-4. [Medline:17550867](#) [doi:10.3324/haematol.10656](#)
 - 30 Tsujimoto Y, Cossman J, Jaffe E, Croce CM. Involvement of the bcl-2 gene in human follicular lymphoma. *Science.* 1985;228:1440-3. [Medline:3874430](#) [doi:10.1126/science.3874430](#)
 - 31 Lee MS, Blick MB, Pathak S, Trujillo JM, Butler JJ, Katz RL, et al. The gene located at chromosome 18 band q21 is rearranged in uncultured diffuse lymphomas as well as follicular lymphomas. *Blood.* 1987;70:90-5. [Medline:3297209](#)