

Types of Central Serous Retinopathy, Analysis of Shape, Topographic Distribution and Number of Leakage Sites

N. Vukojević, J. Šikić, D. Katušić and B. Šarić

Department of Ophthalmology, Clinical Hospital Center Zagreb, Zagreb, Croatia

ABSTRACT

The analysis of 212 fluorescein angiograms of the same number of eyes showed that Type I is by far the most prevalent form of central serous retinopathy. Type I appeared in 92.45%, Type II in 6.60% and the Intermediate type in 0.95% of the examined eyes. The patients were mostly male (81.13%) between 30 and 49 years of age (95.28%). The number of leakage sites in Type I central serous retinopathy varied from 1 (83.67%) to 5 (1.02%). Solitary leakage appeared in 83.67%, while uniform spreading of fluorescein into the subretinal blister in Type I central serous retinopathy appeared in 85.71% of eyes. Most leakage sites (32.50%) were located in the upper nasal quadrant, while the lower temporal quadrant was least affected (15.83%). The foveal avascular zone was affected in 4.14% and the papillomacular bundle in 20.83% of the examined eyes.

Introduction

Central serous retinopathy (CSR) is characterized by the accumulation of clear liquid under the limited zone of detached retina in the vicinity of the back pole (Figure 1). Most frequently the liquid accumulates under the neurosensory retina (94%) leading to Type I CSR. Type II is characterized by the accumulation of liquid under the detached retinal pigment epithelium, while in Type III, the so-called Intermediate type, neurosen-

sory retina and pigment epithelium are both detached¹. Although the etiology and pathogenesis of this disorder are still unclear, in our research we tried to identify types of CSR, possible areas of involvement, shape and number of leakage sites in Type I CSR.

Materials and Methods

Our own clinical material was used in the analysis of different types of CSR, as well as in the analysis of number, shape

and topographic distribution of leakage in the acute Type I CSR. Fluorescein angiograms of 212 eyes examined at the Department of Ophthalmology, Clinical Hospital Center Zagreb, were evaluated. Patients' age ranged from 20 to 50 years. The analyzed zone was circular in shape with a 6-mm diameter and the foveolar groove at its center. This zone was divided into four quadrants while the central avascular zone was observed separately. Leakage in the papillomacular bundle was also observed separately. The vertical diameter of the optic nerve disc was used as a width of the bundle.

Results

The total of 212 fluorescein angiograms of the same number of eyes with CSR was analyzed. There were 81.13% males and 18.87% females. Two hundred and two patients (95.28%) were between 30 and 49 years old and only 4 patients were 50 years or older. One hundred and ninety six eyes (92.45%) had Type I, 14

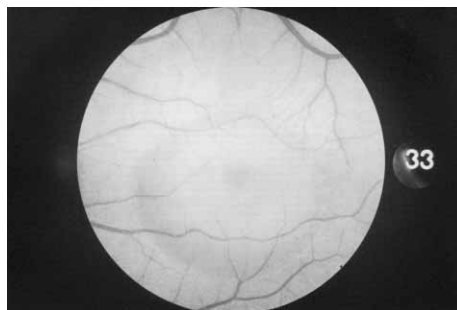


Fig. 1. Central serous retinopathy.

eyes (6.60%) had Type II and 2 eyes (0.95%) had the Intermediate type CSR (Figure 2, Table 1). Of 196 eyes with type I CSR, 164 of them (83.67%) had only one leakage site, with the highest observed number of leakage sites being 5 (2 eyes) (Table 2). By analyzing the shape of leakage sites in Type I CSR we recognized 4 distinct types of leakage: 1) a uniform spreading of fluorescein into the subretinal blister, 2) a smokestack phenomenon, 3) a diffuse retinal pigment epithelial leakage, 4) a leaking scar (Figure 3).

In 168 eyes (85.71%) with type I CSR we registered a uniform spreading of the dye into the subretinal blister. The appearance of the so-called 'leaking scar' was observed in 16 eyes (8.17%), while the smokestack phenomenon and diffuse leakage were present in 6 eyes (Table 3). The most frequent location of leakage

TABLE 1
TYPES OF CENTRAL SEROUS RETINOPATHY

Types of CSR	Number of eyes	%
Type I	196	92.45
Type II	14	6.60
Interm. type	2	0.95
Total	212	100.00

TABLE 2
NUMBER OF LEAKAGE SITES PER EYE

No. of leakage sites per eye	No. of eyes	%
1	164	83.67
2	26	13.27
3	3	1.53
4	1	0.51
5	2	1.02
Total	196	100.00

TABLE 3
DISTRIBUTION OF THE SHAPE OF LEAKAGE SITES

Shape of leakage sites	No. of eyes	%
Uniform spreading	168	85.71
Smokestack phenom.	6	3.06
Area of diff. leakage	6	3.06
Leaking scar	16	8.17
Total	196	100.00

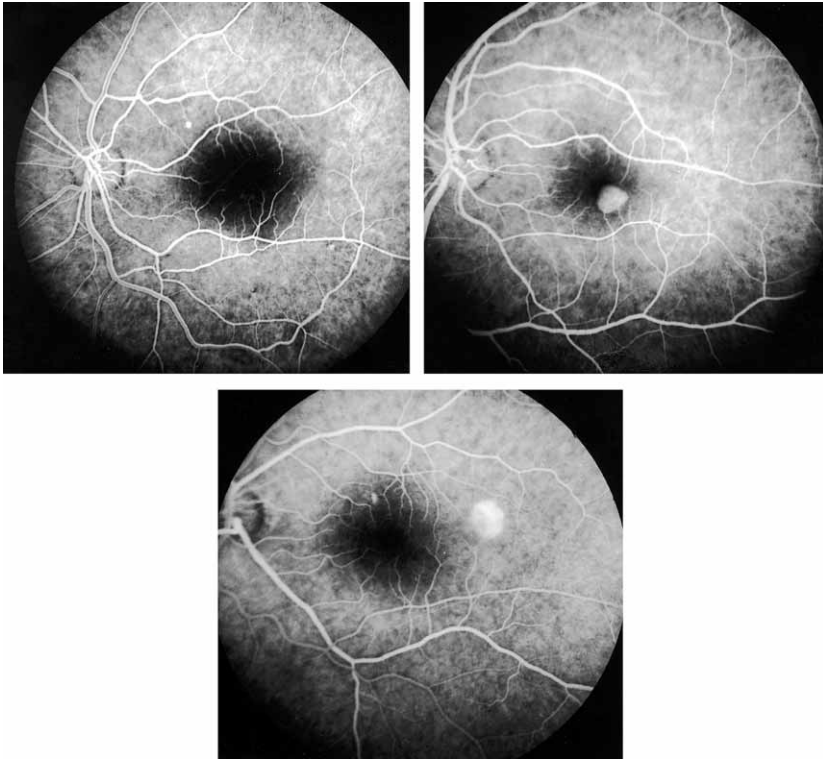


Fig. 2. Angiograms of the types of central serous retinopathy (Type I, Type II, Intermediate type).

was in the upper nasal quadrant, 78 (32.50%), and the most rare one in the lower temporal quadrant, 38 (15.83%).

TABLE 4
TOPOGRAPHIC DISTRIBUTION OF LEAKAGE SITES

Location of leakage sites	No. of leakage sites	%
Upper nas. q.	78	32.50
Lower nas. q.	46	19.17
Upper tem. q.	50	20.83
Lower tem. q.	38	15.83
Fov. av. zone	10	4.17
Outside	18	7.50
Total	240	100.00

The avascular zone had 10 leakage sites (4.17%), 18 (7.50%) of them outside the observed zone (Table 4). 20.83% of the leakage sites were located within the papillomacular bundle.

Discussion

The research shows that, as it is already known, this disease affects mostly male patients between 30 and 50 years of age. Type I is by far the most prevalent form (92.45%) of CSR in practice, as it is explained in literature, while other forms appear sporadically.

The analysis of fluorescein angiograms of our patients has confirmed pre-

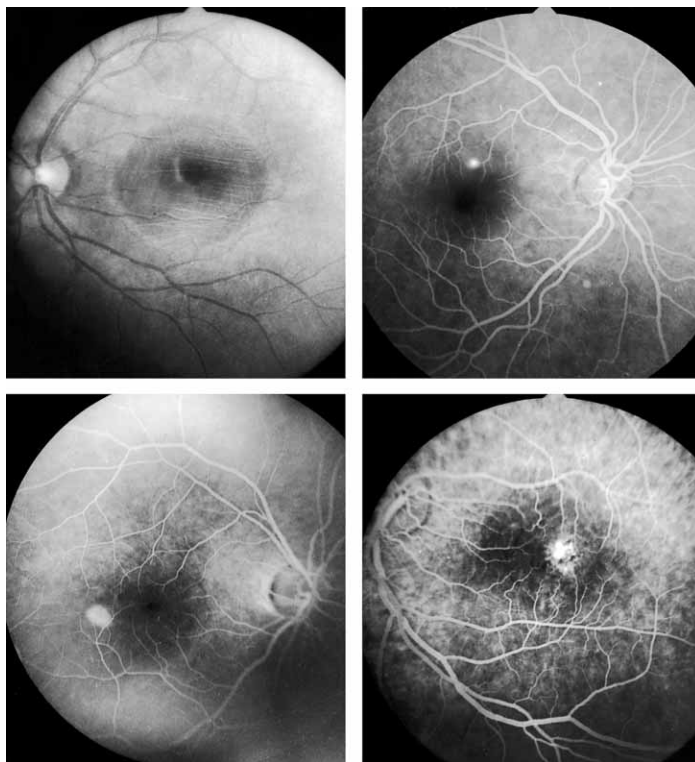


Fig. 3. Shape of leakage sites in type 1 CSR (uniform spreading of fluorescein, smokestack phenomenon, area of diffuse leakage, leaking scar).

vious findings that the upper nasal quadrant of the macula is the most frequent location of leakage in Type I CSR, accounting for 32.50% of cases. This value varies from 29 to 33% in the works of other authors^{2,3}.

The specific morphology of the foveal avascular zone of the macula (strong morphological and functional ties between the cones and the retinal pigment epithelium) and the absence of other retinal structures could account for the lower degree of affectedness of this area. In 20.83% of the examined eyes leakage was

localized within the papillomacular bundle. This result does not correspond with the results of other authors (which themselves are quite different) probably because of the different understanding of the width of the papillomacular bundle. Solitary leakage with uniform spreading of fluorescein within the subretinal blister is by far the most prevalent type of leakage in Type I CSR (85.71%). The so-called smokestack phenomenon was observed in 3.06% of eyes, which is a value significantly lower compared to the reports of other authors (from 7 to 20)⁴.

REFERENCES

1. RYAN, S.: Retina. (Mosby, St.Luis, 1994). — 2. SHIMIZU, K., I. TOBARI, Mod. Probl. Ophthalmol. 9 (1971) 152. — 3. WESSING, A., Ber. Dtsch. Ophthalmol. Ges., 73 (1973) 566. — 4. GILBERT, C., S. L. OWENS, P. D. SMITH, S. L. FINE, Br. J. Ophthalmol., 68 (1984) 815.

N. Vukojević

Department of Ophthalmology, Clinical Hospital Center Zagreb, Kišpatičeva 12, 10 000 Zagreb, Croatia

FORME CENTRALNE SEROZNE RETINOPATIJE, ANALIZA OBLIKA, TOPOGRAFSKOG SMJEŠTAJA I BROJA MJESTA PROPUŠTANJA

SAŽETAK

Analiza 212 fluoresceinskih angiograma od jednakog broja očiju pokazuje da je tip I centralne serozne retinopatije daleko najčešća forma CSR-a. Tip I javlja se kod 92.45%, tip II kod 6.60%, a tip III kod 0.95% pregledanih očiju. Većina pacijenata bili su muškarci (81.13%), u dobi od 30–49 godina (95.28%). Broj mjesta propuštanja kod tipa I CSR-a varira od 1 (83.67%) do 5 (1.02%). Solitarno propuštanje javlja se kod 83.67%, dok se jednolično širenje fluoresceina u subretinalni mjehur kod tipa I CSR-a nalazi u 85.71% očiju. Najviše mjesta propuštanja (32.50%) lokalizirano je u gornjem nazalnom kvadrantu, dok je donji temporalni kvadrant najrjeđe zahvaćen (15.83%). U fovealnoj avaskularnoj zoni propuštanje je lokalizirano u 4.17%, a u papilomakularnom snopiću u 20.83% pregledanih očiju.