

Foramen Mandibulae as an Indicator of Successful Conduction Anesthesia

J. Keros¹, P. Kobler², I. Baučić³ and T. Čabov⁴

¹ Department of Dental Anthropology, School of Dentistry, University of Zagreb, Croatia

² Department of Oral Surgery, School of Dentistry, University of Zagreb, Croatia

³ Department of Dental Prosthetics, School of Dentistry, University of Zagreb, Croatia

⁴ Department of Maxillofacial and Oral Surgery, Department of Stomatology, School of Dental Medicine, University of Rijeka, Croatia

ABSTRACT

Comparative measurements were made of 144 orthopantomographs in 50 patients with successful and 94 patients with unsuccessful inferior alveolar nerve block anesthesia. The results show that the bony lingula is prominent in 28.5% of all patients, or in 56.0% of those with unsuccessful anesthesia. The variables mandibular notch vs. mandibular foramen (MN-MF) and the anterior ramus ridge vs. mandibular foramen (ARR-MF) show greater distances in the group of patients with successful anesthesia, while the variables of posterior ramus ridge vs. mandibular foramen (PRR-MF) and mandibular angle vs. mandibular foramen (MA-MF) were greater in the group of patients with unsuccessful anesthesia ($p > 0.05$). It is concluded that the variability in position of the mandibular foramen among others may be responsible for an occasional failure of inferior alveolar nerve block.

Introduction

Numerous articles and anatomy texts describe the anatomic structures relevant to successful mandibular anesthesia, but failure in this technique still persists¹⁻⁸. The failure involves three major factors. The first and the most common is improper placement of the hypodermic needle, due to inadequate evaluation of anatomic landmarks. The second is accessory enervation of the mandibular denti-

tion, and the third is the marked variability in position of the mandibular foramen. Panoramic radiographs are commonly used for screening diagnosis and selecting the best possible surgical approach^{8,9}. The purpose of this study is to analyze the relationship between different anatomical structures on the inside of the lower mandibular ramus in relation to the mandibular foramen as reference point on orthopantomographs in patients with successful and unsuccessful inferior alveolar nerve block anesthesia.

Materials and Methods

The study was based on a selected group of 50 patients in whom an inferior alveolar block anesthesia was unsuccessful (25 women and 25 men aged from 27 to 80 years), and the control group of 94 subjects (45 women and 49 men ranging from 35 to 79 years). Anesthesia was carried out by the same dental surgeon using direct method with an aspirating syringe (4 cm long, 25 G needle, and 2% Xylocain with adrenaline 1:200,000). Evaluation of anaesthetic effects was made on the basis of the adjusted McGill Melzack Pain questionnaire (MPQ)¹⁰.

All subjects were x-rayed using OR-TOCEF (Siemens, Bensheim, Germany at 80 kVp with Titan 2HS screens (Siemens), and X-OMAT L films (Eastman, Kodak, Rochester, N.Y. USA) processed in a RPX-OMAT M8 Kodak processor at 35 °C for 90 s. On orthopantomograms the following distances were measured: a) distance between the lowest point of the mandibular notch and the mandibular foramen (MN-MF); b) distance between the anterior ramus ridge (external oblique lines) and mandibular foramen (ARR-MF); c) distance between the posterior ramus ridge and mandibular foramen (PRR-MF); and d) distance between the mandibular angle and mandibular foramen (MA-MF). The measure points were marked along with the connecting lines. Measurements were made by using a specially modified electrocaliper (MEBA-Croatia) to an accuracy of 0.01 mm.

Data were evaluated in dry mandibles and panoramic radiographs to study the relation of the narrowest antero-posterior diameter of the ramus, the shortest distance of the FM to the lowest point of the mandibular notch and to the basal plane of the mandible.

In order to measure both intra and inter-examiners errors the measurements on radiographs were repeated by the same person at different time blindly and preferably by others. Descriptive statistical procedures of covariant, multivariate and discriminative analyses were used.

Results

Comparative distributions on the basis of successfulness of anesthesia and prominence of mandibular lingula were markedly prominent i.e. in 56% of patients with unsuccessful and 13.8% of patients with successful anesthesia. The differences between the groups according to sex and age are not statistically significant. Summarized results of contingency tests for orthopantomographic distribution of quantitative properties in normal distribution according to success of anesthesia are presented in Table 1. According to Kolmogorov-Smirnov test in the group of patients with unsuccessful anesthesia the distribution of all variables show statistically significant departure from normal distribution ($p > 0.05$).

Consequently, the two groups were compared on the basis of Mann-Whitney

TABLE 1
SUMMARIZED RESULTS OF CONTINGENCY TESTS ACCORDING TO SUCCESS OF ANESTHESIA

Variables	Successful		Unsuccessful	
	KV	P	KV	P
MN-MF	1.74	< 0.01	1.08	> 0.05
ARR-MF	1.47	< 0.03	0.88	> 0.05
PRR-MF	1.66	< 0.01	1.44	> 0.05
MA-MF	21.9	< 0.01	0.99	> 0.05

TABLE 2
 COMPARISON BETWEEN ORTHOPANTOMOGRAPHIC QUANTITATIVE PROPERTIES DISTRIBUTION AND SUCCESS OF ANESTHESIA (MANN-WHITNEY U-WILCOXON RANK SUM W TEST)

MN-MF			
Sample average	Subjects		
43.66	50	Group 1	
87.84	94	Group 2	
	144	Total	
U	W	Z	Correction
908.0	2183.0	6.1704	0.000
ARR-MF			
Sample average	Subjects		
55.61	50	Group 1	
81.48	94	Group 2	
	144	Total	
U	W	Z	Correction
1505.5	1780.5	3.5988	0.0003
PRR-MF			
Sample average	Subjects		
113.05	50	Group 1	
50.93	94	Group 2	
	144	Total	
U	W	Z	Correction
322.5	5652.5	8.6439	0.000
MA-MF			
Sample average	Subjects		
92.98	50	Group 1	
61.61	94	Group 2	
	144	Total	
U	W	Z	Correction
1326.0	4649.0	4.3764	0.000

Group 1 = unsuccessful
 Group 2 = successful

univariate non-parametric test (Table 2). The differences are highly statistically significant for all variables. The indicators of differences between MN-MF and ARR-MF are greater in the group of patients with successful anesthesia while variables concerning the differences between MA-PRR-MF and MA-MF are greater in the group of patients with unsuccessful anesthesia ($p > 0.05$).

The comparison between orthopantomographic quantitative properties distribution and success of anesthesia is shown in Table 2.

The distribution of respondents in canonical discriminative function for both groups is shown in Figure 1. In general, the discriminative power of the function may be considered as a very high one (96.8%), and even slightly higher in the group of patients with successful anesthesia.

Discussion

Numeric data regarding the location of the mandibular foramen are important when a local anesthetic block of the infe-

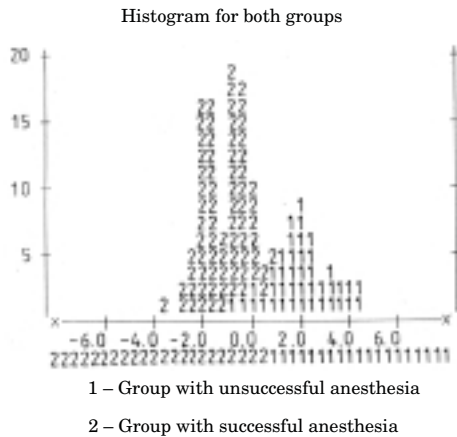


Fig. 1. Distribution of respondents in canonical discriminative function.

rior alveolar nerve is required^{1–14}. Radiology is the only available noninvasive method for diagnosis and treatment planning of major surgical procedures of the mandible^{8,9}. In our study comparative measurements regarding the location of the mandibular foramen and surrounding anatomic landmarks showed a signifi-

cant departure of variables from normal distribution in the group of patients with unsuccessful anesthesia. So, the distance between the mandibular notch (MN) and mandibular foramen (MF) was larger in patients with successful anesthesia (21.3

1.36) than in patients with unsuccessful anesthesia (19.30 ± 1.36). The distance between the anterior ramus ridge (ARR) and mandibular foramen (MF) was larger in patients with successful anesthesia (19.37 ± 1.89) than in patients with unsuccessful anesthesia (18.45 ± 1.73). The distance between the mandibular angle (MA) and mandibular foramen (MF) was larger in patients with successful (40.67 ± 1.50) than in those with unsuccessful anesthesia. The distance between the posterior ramus ridge (PRR) and mandibular foramen (MF) was larger in patients with unsuccessful (16.82 ± 1.12) than in those with successful anesthesia (14.29 ± 1.17). In patients in whom the distance between PRR-MF and MA-MF (MA-MF > MN-MF) is larger at distinct prominence of the lingula anesthesia was observably ineffective.

REFERENCES

1. HESTON, G., J. SHARE, J. FROMMER, J. H. KRONMAN, *J. Oral. Surg., Oral Med., Oral Path.*, 65 (1988) 32. — 2. NICHOLSON, M. L., *Anat. Rec.*, 212 (1985) 110. — 3. ZOGFRAOUS, J. J., E. KAPNIDOI, A. MUTZURI, L. ARDEKIAN, *Stomatologija*, 47 (1991) 26. — 4. HAYWARD, J., E. R. RICHARDSON, S. K. MALHOTRA, *J. Oral Surg.*, 44 (1997) 837. — 5. KEY, Z. M., *Int. J. Oral Surg.*, 3 (1974) 363. — 6. OGAWA, H. M., TOYAMA, M. A. NEBEYA, *Nippon Dent. Univ. Ann. Public.*, 24 (1990) 123. — 7. KEROS-NAGLIĆ, J., J. PANDURIĆ, D. BUNTAK-KOBLER, *Coll. Antropol.*, 21 (1997) 203. — 8. GOAZ, P.

W., S. C. WHITE: *Oral radiology: Principles and interpretations*. (C. W. Mosby, St. Louis, 1994). — 9. KAFFE, I., L. ARDEKIAN, I. GELERENTER, S. TAICHER, *J. Oral Surg., Oral Med., Oral Path.*, 78 (1994) 622. — 10. MELZACK, R., *Pain*, 30 (1978) 191. — 11. RODA, R. S., P. L. BLANTON, *Quintessence Int.*, 25 (1994) 27. — 12. ROOD, J. P., *Brit. Dent. J.*, 15 (1977) 75. — 13. MALAMED, S. F.: *Handbook of local anesthesia*. (C.W. Mosby, St. Louis, 1990). — 14. WONG, M. K. S., P. L. JACOBSEN, *J. Am. Dent. Assoc.*, 123 (1992) 69.

J. Keros

Department of Dental Anthropology, School of Dentistry, University of Zagreb, Gundulićeva 5, 10000 Zagreb, Croatia

FORAMEN MANDIBULE I PROVODNA ANESTEZIJA

SAŽETAK

Unutrašnja grana donje čeljusti ima veliku praktičnu važnost u postupcima anestezije donjega zubišnog živca. Stoga su načinjene ortopantomografske snimke i obavljena usporedna mjerenja protega donje čeljusti u bolesnika s uspješnom i neuspješnom anestezijom u području donje čeljusti. Premda je znano da neuspjeh pri anesteziji donje čeljusti najčešće nastaje zbog neispravne manipulacije pri izvođenju anestezije, gdje i anatomske značajke mogu biti dodatnim uzrokom ovoj pojavi. Primjerice u bolesnika s uspješnom anestezijom vrijednosti su IM-MF bile nešto manje od vrijednosti BM-MF, što je ukazivalo na niži smještaj foramena mandibule, pa stoga u toj skupini nije bilo realne zapreke uspješnom anestezijskom zahvatu.