

Hypohidrotic Ectodermal Dysplasia: Dental Features and Carriers Detection

D. Glavina, M. Majstorović, O. Lulić-Dukić and H. Jurić

Department of Pedodontics, School of Dental Medicine, University of Zagreb, Zagreb, Croatia

ABSTRACT

Ectodermal dysplasia is a heterogeneous condition characterized by affected ectodermal structures, among which the teeth and skin with its derivatives (hair, sweat glands) are the most frequent. The aim of this work is to present the analysis of dental traits in five families (affected boys and their mothers) with hypohidrotic ectodermal dysplasia (HED), and to evaluate the importance of orofacial and dental findings in the determination of female HED gene carriers. Hypodontia (oligodontia) was found in all the patients. The mothers, gene carriers, had either hypodontia or a reduced size of teeth with a particular morphological, peg shape. In patients with hypohidrotic ectodermal dysplasia the deciduous second molar teeth were mostly affected by taurodontism. The characteristic dental finding in heterozygous females of the mandibular peg shaped incisors and canines, as well as of hypodontia or peg shaped upper lateral incisors can be used as a reliable criterion for the detection of HED gene carriers.

Introduction

Hypohidrotic ectodermal dysplasia (HED) is a syndrome characterized by affected ectodermal structures of hair, teeth, nails and skin (sweat glands)^{1,2}. According to the categorization described by Freire-Maia and Pinheiro^{1,2} this condition can be classified as ectodermal dysplasia 1–2–3–4. It has been found that this syndrome is inherited by an X-linked recessive gene^{1–3}. It is only expressed in male children, but females are gene carri-

ers for this disorder. Due to the lyonization phenomenon its phenotypic expression in females varies from unobservable symptoms to full expression of all HED symptoms. As HED is characterized by early morbidity and mortality (resulting from a disturbed regulation of body temperature) and the facial expression of a newborn is devoid of any symptoms, it is difficult to make a timely diagnosis of this condition⁴. The results obtained by a number of studies in different countries show a very high mortality rate of the

newborns affected by this disorder due to hypothermia. It amounts to 10–28% in Great Britain, 13% in USA, and even to 54% in Brazil^{4–7}. The orofacial traits and the dental finding in females, HED gene carriers, can be a very useful factor in the diagnosis of this disorder.

The aim of this paper is to present the analysis of orofacial traits and dental findings in five patients affected by HED and their mothers, gene carriers for this disorder.

Materials and Methods

Study included five families, in which were affected boys and their mothers. Heredogram analysis was performed in all families. Patients and their mothers were examined for establishing oral and dental status. Orthopantomograph analysis was also performed in all patients and their mothers.

Results

Family 1

The affected boy aged two had a characteristic face with frontal bossing, ever-

ted lips and depressed lower third of the face. His hair was delicate, thin and rare, with signs of hypotrichosis. His nails were of normal appearance and shape, while his skin was thin, smooth and dry. The disturbance in the regulation of his body temperature was caused by high hypohidrosis. The dental finding shows oligodontia in the upper jaw and anodontia in the lower jaw. The upper jaw contained only peg shaped medial deciduous incisors. The orthopantomographic finding showed the presence of both canines, the first and the second deciduous molars in the upper jaw and the beginnings of the first and the second deciduous left molars and the second deciduous right molar in the lower jaw. In toothless areas the alveolar ridge was narrow, sharp and hypoplastic. The heredogram analysis indicated X-linked recessive heredity (Figures 1–3).

The patient's mother, aged 43 years, had a normal appearance, but with diagnosed hypodontia of both upper lateral incisors and microdontia of all lower incisors (Figure 4) (Table 1).

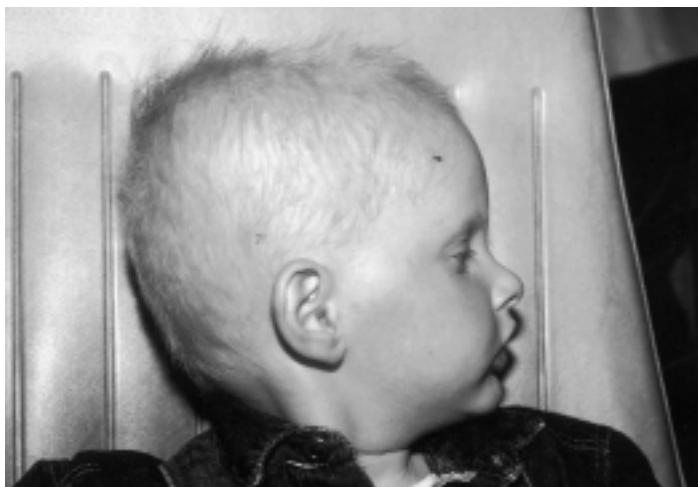

Fig.1. Side view of the face and hypotrichosis of a patient with HED.

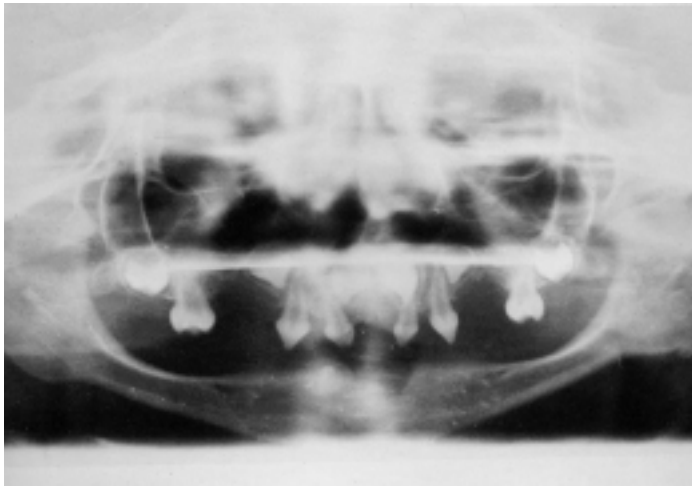


Fig. 2. Orthopantomogram of a patient with HED (oligodontia and peg shaped incisors in the maxilla, anodontia in the mandible).

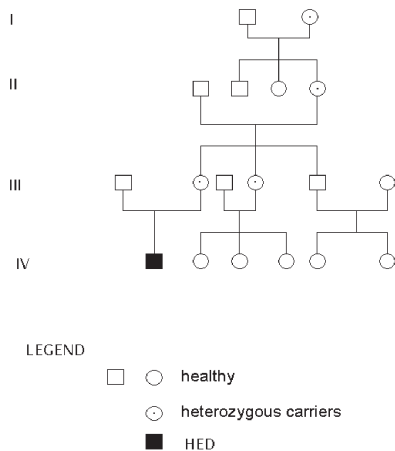


Fig. 3. Heredogram of family 1.

Family 2

A boy, aged two, showed typical characteristics of the syndrome: rare and delicate hair, frontal bossing, saddle nose,

everted lips and depressed lower third of the face. His nails were dysplastic and convex. He frequently suffered from high fevers due to hypohidrosis and was hospitalized for 15 days on account of that. He was also very sun-sensitive due to his thin and dry skin. His growth and psychomotor development were normal. The upper jaw was affected by oligodontia while both medial deciduous incisors and second deciduous molars were present. The upper second deciduous molars were affected by taurodontism. The incisors were peg shaped. The lower jaw was characterized by anodontia. The alveolar ridge was narrow, sharp and hypoplastic. Heredity was determined as X-linked and recessive.

The mother of the patient, aged 22 years, had a typical dental finding with hypodontia of the right lateral incisor in the upper jaw and microdontia with the peg shaped left upper lateral incisor. The lower jaw was characterized by microdontia of all four incisors with a slightly conical form of both left and right lateral incisors (Table 1).

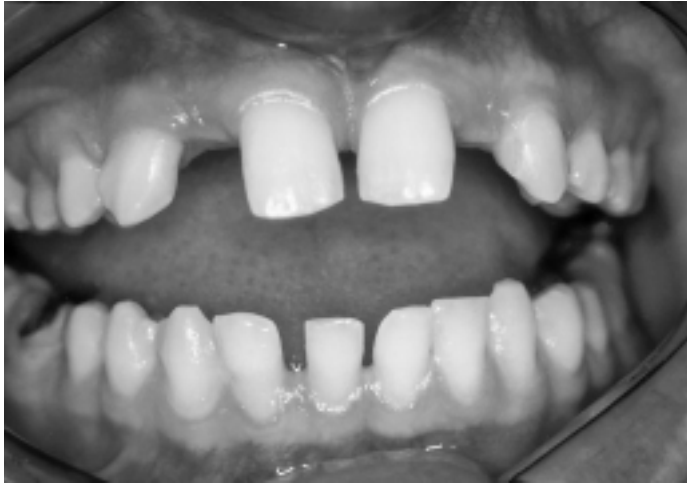

Fig. 4. Hypodontia of lateral incisors in the maxilla and microdontia of mandibular incisors in the mother of the patient with HED.

TABLE 1
DENTAL AND ORAL TRAITS IN HED PATIENTS AND THEIR MOTHERS, GENE CARRIERS

Trait	Patients					Mothers-carriers				
	1	2	3	4	5	1	2	3	4	5
Hypodontia	+	+	+	+	+	-	+	+	+	-
Oligodontia	+	+	+	+	+	-	-	-	-	-
Taurodontism	-	+	+	+	-	-	-	-	-	-
Microdontia	+	+	+	+	+	-	+	+	-	+
Hypoplasia of alveolar ridge	+	+	+	+	+	-	-	-	-	-
Hypotrichosis	+	+	+	+	+	-	-	-	-	-
Hypohidrosis	+	+	+	+	+	-	-	-	-	-

Legend: + present;
- absent.

Family 3

A boy, aged two, showed typical facial HED traits. Maxillary oligodontia and hypoplasia were observed. The existing teeth in the upper jaw included left and right deciduous central incisors, canines and second molars, while in the lower jaw both left and right second deciduous molars, erupting right canine and pre-eruption left canine were observed. Taurodontism of deciduous molars was also recorded.

The alveolar ridge in toothless areas was narrow and hypoplastic. The growth and psychomotor development were normal. Hypohidrosis was also expressed. The heredogram finding indicated X-linked recessive heredity (Figure 5).

The dental finding of the patient's mother, aged 24, was typical for HED, with hypodontia of the upper left and right lateral incisors and microdontia of the lower left and right central incisors (Table 1).

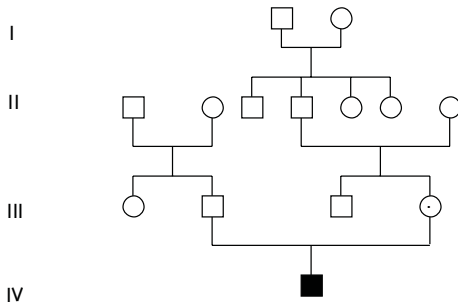


Fig. 5. Heredogram of family 3.

Family 4

A boy aged 6 had all HED symptoms: rare and delicate hair, frontal bossing, saddle nose, protruding and everted lips and depressed middle and lower third of the face. He was frequently hospitalized on account of respiratory infections accompanied by a very high fever. He had hypohidrosis and difficulties with thermal regulation. The dental finding included oligodontia in the upper jaw (with the presence of the left and right central incisors, left and right canines and left and right second molars) and anodontia of the lower jaw. The alveolar ridge in toothless areas was narrow, sharp and hypoplastic. The orthopantomographic finding showed in the mandible the existence of taurodontism of both left and right second deciduous molars as well as rudiments of the permanent left and right central incisors, left and right canines and left and right first molars. Again, X-linked recessive heredity was established.

The patient's mother aged 26 had typical facial HED symptoms. The dental finding included hypodontia of the upper lateral teeth.

Family 5

The mother of a child with diagnosed HED, deceased at the age of seven months,

had microdontia of the maxillary left and right lateral incisors and the diastema between all the incisor teeth. The mandible was characterized by microdontia of all four incisors, which were peg shaped. The orthopantomographic finding showed normal number of teeth (including all four wisdom teeth). All lower incisors were of a reduced size, while medial incisors exhibited also a slight distal crown angulation (Table 1).

Discussion

Delicate, rare hair, characteristic facial look and hypodontia are basic elements of the clinical finding for the diagnosis of hypohidrotic ectodermal dysplasia. The condition is characterized by different intensity of hypodontia (oligodontia) in both jaws. The mandible is more affected than the maxilla. Ulsu et al.⁸ described a significantly higher degree of affection in the mandible than in the maxilla, as well as dental deficiency of the existing incisors and canines that are peg shaped and of a reduced size. A similar finding has been reported also by Borg and Midtgaard⁹. Wright and Finley¹⁰ have described several families affected by CST syndrome and in addition to the characteristic facial look, hair and low-lying auricles they also mention a very expressed mandibular hypodontia and maxillary anodontia. Tuffli and Laxova¹¹ add also delayed dentition and minor anomalies in tooth shape to the finding of oligodontia. Schalk-van-der Weide et al.¹² report that out of 196 patients with oligodontia 59 patients were affected by different forms of ectodermal dysplasia, while in 39 patients isolated oligodontia could not be distinguished from that related to the syndrome.

In all the examined patients with HED described in this paper a high degree of oligodontia of both deciduous and permanent teeth was observed, while mandibu-

lar anodontia was recorded in three of them. The existing teeth were peg shaped and/or of a reduced size, while the alveolar ridge in toothless areas was hypoplastic. The deciduous and permanent molars were frequently affected by taurodontism. In three patients taurodontism of the deciduous second molars was also recorded, which indicates that this condition is not only characterized by ectodermal affection but also by that of mesodermal tissues¹³.

The heredogram analysis in all the examined families with HED showed the model of X-linked recessive heredity. Many authors report cases of both autosomal dominant or recessive^{8,9,14–16} and X-linked heredity of hypohidrotic ectodermal dysplasia^{9,17}. Zonana et al.¹⁸ have shown that the gene locus for HED is found in the region q11–21,1 of X chromosome. By introducing a new method of prenatal diagnosis of HED, Anton-Lamprecht et al. and Zonana et al.^{19,20} did not find a significant genetic heterogeneity of X-linked hypohidrotic ectodermal dysplasia after analyzing 36 affected families.

It should be pointed out that patients with HED show a high degree of hypohidrosis, while in the majority of patients with other forms of ED we find euhidrosis. Frydman et al.²¹ described a case of isolated hypohidrosis without clinical signs of ectodermal dysplasia. The only symptom relevant for diagnosis was frequent hyperthermia due to respiratory infections and sensitivity to high temperatures.

The dental finding of HED consists of high hypodontia (oligodontia), characteristic peg-shaped incisors and reduced teeth size (microdontia) of varying intensity. The toothless areas are characterized by a narrow, sharp and hypoplastic alveolar ridge.

In addition to frequent infections of the upper respiratory tract, hyperther-

mia represents the most serious problem in the treatment of HED patients. It occurs in various pathological conditions of the newborns due to their deficient regulation of body temperature by perspiration which is either considerably reduced or entirely absent. Long-lasting fevers can cause brain damage and secondary mental retardation^{3,22}.

Due to genetic inheritance of HED (X-linked recessive) only male children are affected by this disorder, while female heterozygotes are gene carriers. In females it can be manifested by hypodontia of a variable degree as well as by microdontia or peg shaped teeth. Also, a reduced number of sweat gland pores is observed^{3,23–26}. As the mothers of HED patients are invariably heterozygous it is highly important to recognize them in view of genetic counseling.

The variability of the clinical finding is explained by the phenomenon of lyonization i.e. the accidental inactivation of an X chromosome in the cells so that they are mosaic, some of them containing an active X chromosome with HED gene and the others containing normal X chromosome. The clinical finding and the expression of the gene depend on the proportion between the two cell types. Cambiaghi, Restano et al.²⁷ in their study showed positive relation between normal and abnormal skin along Blaschko lines and diagnosing mosaicism for HED.

In a study on the frequency of female carriers with hypodontia Sofaer³ has found out that the prevalence of HED gene carriers in the female population affected by hypodontia amounts to 75%, ranging between 1:500 and 1:50 for deciduous dentition and between 1:5,000 and 1:500 for permanent dentition⁵. This conclusion is also supported by the findings of Stevenson and Kerr, Tocchini et al., Pinheiro and Freire-Maia^{4,23,26}. Pinheiro and Freire-Maia²³ consider that this proportion is even higher as many potential female

carriers have never been examined or are regarded as normal because of only minor signs which go unrecognized, or even in cases of severely affected boys their mild symptoms are not related to the disorder (e.g. some teeth are already extracted or prosthetically treated). The teeth most frequently affected by hypodontia in heterozygous females include the upper lateral incisors and the second premolars, and the lower central incisors and the second premolars. Along with hypodontia of varying intensity, microdontia and peg shaped incisors can be also present. Alveolar bone in toothless areas undergo resorption changes that can affect design of full or partial dentures^{28–32}. The finding in the observed group of gene carriers is also characteristic. Hypodontia of both upper lateral incisors with present microdontia of bilateral lower central incisors was found in two women. In cases with less expressed hypodontia microdontia was

characteristically present. Hypodontia of only the upper right lateral incisor and microdontia of the upper left lateral incisors and bilateral lower central and lateral incisors were found in one woman. In a case without hypodontia, the upper lateral incisors and the lower central and lateral incisors were affected by a highly expressed microdontia.

Conclusion

For a more efficient and accurate diagnosis of HED and an early detection of female gene carriers, the dental analysis of the daughters of positive gene carriers is required. The determination of the hypoplastic and sharp alveolar ridge as an early sign of HED is important for the early diagnosis of this disorder in male children before the manifestation of dental abnormalities.

REFERENCES

1. FREIRE-MAIA, N.: Maformacoes sindromes e displasias. (Actas V Congr Latinoam Genet, Chile, 1982). — 2. FREIRE-MAIA, N., M. PINHEIRO: Ectodermal dysplasias: A clinical and genetic study. (Alan R Liss Inc., New York, 1984). — 3. SOFAER, J. A., Br. Dent. J., 151 (1981) 327. — 4. STEVENSON, A. C., C. B. KERR, *Mutat. Res.*, 4 (1967) 339. — 5. CLARKE, A., D. M. PHILLIPS, R. BROWN, P. S. HARPER, *Arch. Dis. Child.*, 62 (1987) 989. — 6. FREIRE-MAIA, N., M. PINHEIRO, *Am. J. Med. Genet.*, 37 (1990) 299. — 7. PINHEIRO, M., M. T. IDERIHA, E. A. CHANTARD-FREIRE-MAIA, N. FREIRE MAIA, S. L. PRIMO-PARMO, *Hum. Genet.*, 57 (1981) 428. — 8. ULUSU, T., A. ALACAM, H. N. ISCAN, N. UCUNCU, *J. Clin. Pediatr. Dent.*, 15 (1990) 46. — 9. BORG, P., K. MIDTGAARD, *J. Dent. Child.*, 44 (1977) 34. — 10. WRIGHT, J. T., W. H. FINLE, *Ala. J. Med. Sci.*, 23 (1986) 84. — 11. TUFFLLI, G. A., R. LAXOVA, *Am. J. Med. Genet.*, 14 (1983) 381. — 12. SCHALK-VAN DER WEIDE, Y., W. H. A. STEEN, F. BOSMAN, *J. Dent. Child.* 59 (1992) 133. — 13. ŠKRINJARIĆ, I., *J. Dent. Res.*, 71 (1992) 1018 (abs). — 14. ZERGOLLERN, L.J.: *Medicinska genetika 1*. (Školska knjiga, Zagreb, 1991). — 15. GRINBERG, S., P. JOVER, L. QUIROS, L. G. DIAZ, F. TERRON, *J. Dent. Child.*, 47 (1980) 193. — 16. RICHIERI-COSTA, A., M. L. GUIÓN-ALMEIDA, N. FREIRE-MAIA, M. PINHEIRO, *Am. J. Med. Genet.*, 44 (1992) 158. — 17. MCDONALD, R. E., D. R. AVERY: *Dentistry for the child and adolescent*. (C.V. Mosby Comp., St Louis, 1983). — 18. ZONANA, J., A. SCHINZEL, M. UPADHYAYA, N. S. T. THOMAS, I. ANTON-LAMPRECHT, P. S. HARPER, *Am. J. Med. Gen.*, 35 (1990) 132. — 19. SALINAS, C. F., J. M. OPITZ, N. W. PAUL: Recent advances in ectodermal dysplasias. (Alan R. Liss for the National Foundation-March of Dime, New York, 1988). — 20. ZONANA, J., A. CLARKE, M. SARFARAZI, N. S. T. THOMAS, K. ROBERTS, K. MARYMEE, P. S. HARPER, *Am. J. Hum. Genet.*, 43 (1988) 75. — 21. FRYDMAN, M., H. A. COHEN, A. KAUSCHANSKY, Y. MATOTH, *Am. J. Med. Genet.*, 31 (1988) 591. — 22. O'LEARY, E., J. SLANEY, D. G. BRYANT, F. C. FRASER, *Clin. Genet.*, 29 (1986) 122. — 23. PINHEIRO, M., N. FREIRE-MAIA, *Am. J. Med. Genet.*, 4 (1979) 113. — 24. FRIAS, J. L., D. W. SMITH, *J. Pediatr.*, 72 (1968) 606. — 25. NORVAL, E. J. G., C. W. VAN WYK, N. J. BASSON, J. COLDREY, *Pediatr. Dermatol.*, 5 (1988) 159. — 26. TOCCHINI, J. J., F. T. WEST, R. W. BARTLETT, *J. Dent. Child.*, 37 (1970) 341. — 27. CAMBIAGHI, S., L. RESTANO, K. PAAKKONEN, R. CAPUTO, *J. KERE, Arch. Dermatol.*, 136 (2000) 217. — 28. PANDURIĆ, J., J. KEROS, V. PANDURIĆ, I. BAGIĆ, *Coll. Antropol.*, 23 (1999) 143. — 29. NABADALUNG D. P., *J. Prosthet. Dent.*, 81 (1999) 499. —

30. ČELEBIĆ, A., M. VALENTIĆ-PERUZOVIĆ, J. STIPETIĆ, Z. DELIĆ, T. STANIČIĆ, L. IBRAHIM-AGIĆ, Coll. Antropol., 24 Suppl. (2000) 71. — 31. CAREK, V., V. JEROLIMOV, A. ČATOVIĆ, D. BUKOVIĆ, Jr., Coll. Antropol., 21 (1997) 211. — 32. BUKOVIĆ, D., Jr., D. RADIONOV, Ž. VERZAK, O. LULIĆ-DUKIĆ, Z. AZINOVIĆ, I. BAGIĆ, Coll. Antropol., 21 (1997) 217.

D. Glavina

*Department of Pedodontics, School of Dental Medicine, University of Zagreb,
Gundulićeva 5, 10000 Zagreb, Croatia*

HIPOHIDROTIČNA EKTODERMALNA DISPLAZIJA: OROFACIJALNE I DENTALNE OSOBITOSTI

S A Ž E T A K

Ektodermalne displazije su heterogena skupina stanja koje karakterizira zahvaćenost ektodermalnih struktura. Zubi, koža i njeni derivati (kosa, žlijezde znojnice) su uz ostale ektodermalne strukture najčešće zahvaćeni. Cilj je ovoga rada bio analiza dentalnih obilježja pet obitelji (zahvaćenih dječaka i majki nosioca) sa hipohidrotičnom ektodermalnom displazijom (HED). Cilj je bio i evaluacija vrijednosti orofacijalnog i dentalnog nalaza u utvrđivanju žena nosioca gena za HED. U svih pacijenata utvrđena je hipodoncija (oligodoncija). Majke, nosioci gena, imale su hipodonciju ili redukciju veličine zubi uz poseban morfološki konični oblik zubi. U pacijenata s hipohidrotičnom ektodermalnom displazijom čest je nalaz taurodontizma drugih mliječnih molara. Karakterističan dentalni nalaz u žena heterozigota u smislu koničnih inciziva i kanina u mandubuli, te hipodoncije ili koničnih gornjih lateralnih inciziva može poslužiti kao pouzdan kriterij za otkrivanje nosioca gena za HED.