

Coll. Antropol. **26** (2002) 1: 47–54
UDC 617.713-089.843
Original scientific paper

Amniotic Membrane Transplantation for Ocular Surface Reconstruction in Neurotrophic Corneal Ulcers

R. Iveković, E. Tedeschi-Reiner, I. Petric, K. Novak-Lauš and M. Bradić-Hammoud

Department of Ophthalmology, University Hospital »Sestre milosrdnice«, Zagreb, Croatia

ABSTRACT

The purpose of this study is to analyze clinical experience about the effects of human amniotic membrane transplantation in eyes with neurotrophic ulcers. In 11 eyes the application of amniotic membrane was performed since January 1999 because of neurotrophic ulcers. The follow up period was longer than 12 months: 19.7 ± 6.0 months. The average healing period after the surgery was 1.6 ± 0.6 weeks. All corneas were fluorescein negative even 12 months after operation. Visual acuity after the transplantation was similar to the one before the surgery in 8 eyes. In 3 eyes the visual acuity after the surgery was better than before. Amniotic membrane transplantation can be considered an effective alternative for treating persistent epithelial defects such as neurotrophic ulcers. It has some advantages over corneal transplantation: a relatively simple procedure, no allograft rejection and it could be particularly beneficial in countries where cornea shortage is apparent.

Introduction

Management of ocular surface disturbances still remains as therapeutically problem despite various conservative and surgical treatments. For some of them previously had no effective management was available so they lead to loss of vision, especially if there was no normal ocular surface defense and healthy limbal cells were lacking.

One of such conditions is neurotrophic corneal ulcer developed as a result of interruption of the corneal derived sensory afferent nerve anywhere along the course of the ophthalmic division of the trigeminal nerve. The ophthalmic division of trigeminal nerve supplies sensory innervation to the cornea, the conjunctiva as well as upper and lower eyelids. There-

Received for publication April 3, 2002

fore trigeminal denervation abolishes reflexes controlling tear secretion and lid blinking and closure. This innervation constitutes the basic neuroanatomical integration of the entire ocular surface defence¹. If the sensory nerve, anywhere along its course, is interrupted it may result in neurotrophic keratopathy. The consequence is corneal anesthesia with frequent breakdown of corneal epithelial surface which can cause neurotrophic ulcers².

Exogenous and endogenous factors and influences like herpetic infection, corneal burns, tumors, radiation, retrobulbar injection for eye surgery or neurosurgery could lead to this condition^{3,4}.

If neurotrophic ulcers persist (longer than 3 weeks) some conventional treatments like topical artificial tears and lubricants are indicated. Some new techniques have been studied: application of insulin like growth factor, cyanoacrylat glue, conjunctival flaps, tarsorrhaphy or lamellar or penetrating keratoplasty⁵.

Lee and Tseng first introduced in 1997 the use of amniotic membrane in the treatment of persistent epithelial corneal ulcers⁶. The procedure has been shown to promote epithelial healing, reduce vascularization, yield good cosmetic effect and is relatively easy to perform. Kruse et al. (1999) also reported a rapid healing of corneal surface⁷.

The aim of this study was to determine the effect of human amniotic membrane transplantation (mono or multilayer; AMT) on neurotrophic corneal ulcers.

Material and Methods

Human amniotic membrane was prepared and preserved as previously described⁷. Amniotic membrane with an attached placenta was obtained shortly after Caesarian section. By serological testing human immunodeficiency virus

(HIV), hepatitis virus type B and C and syphilis had been excluded. The placenta was cleaned by washing with BSS containing penicillin (50 µg/ml), streptomycin (50 µg/ml), neomycin (100 µg/ml), and amphotericin B (2.5 µg/ml). The amniotic membrane was separated from the chorion and was flattened over a nitro-cellulose filter paper with epithelial surface up, and the stromal matrix down in contact with the paper. Prepared amnion was placed in a plastic container and stored at -80 °C.

All surgeries were performed with the patient receiving parabolbar anesthesia (2% lidocain). After anesthesia in eyes with persistent sterile corneal ulceration the base of the ulcer was debrided and poorly adherent epithelium adjacent to the edge of the ulcer was removed up to the area where the epithelium became adherent. The amniotic membrane was removed from the storage medium peeled from the filter paper. Then it was placed on the surface of the cornea to cover the ulcerated area with the epithelial surface up. Deep ulcers were filled with more than one layer of amniotic membrane. The amniotic membrane was secured to the edge of the defect by interrupted 10.0 nylon sutures. After the transplantation, bandage contact lens was applied in 10 eyes and partial tarsorrhaphy was added in 1 eye. In the postoperative period topical Maxitrol (neomycin sulphate, polymyxin B sulphate and dexamethasone) was administrated 4 times a day until complete epithelization was present.

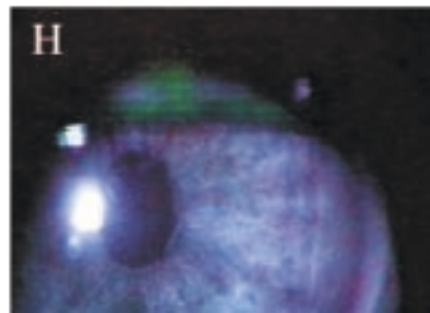
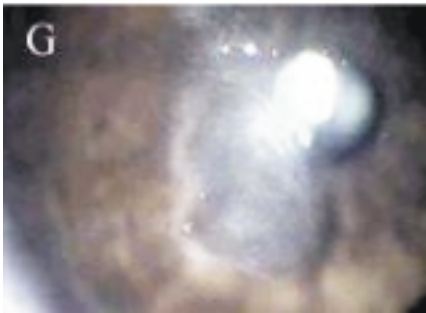
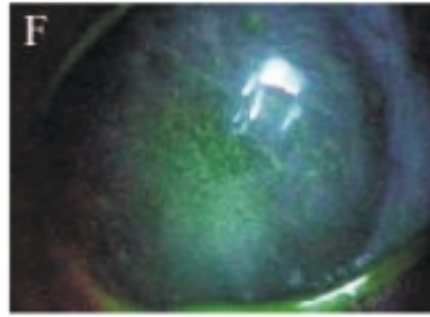
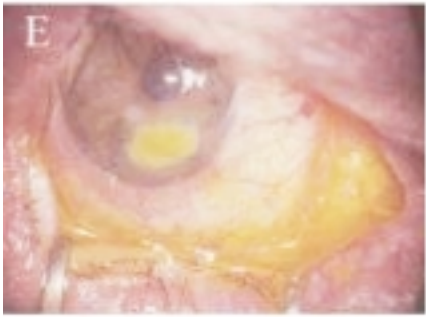
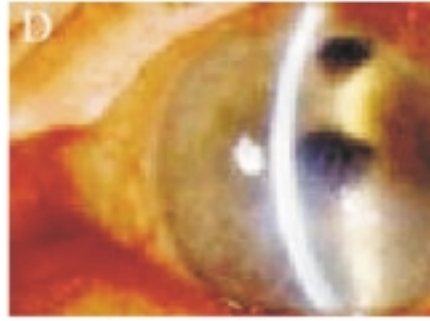

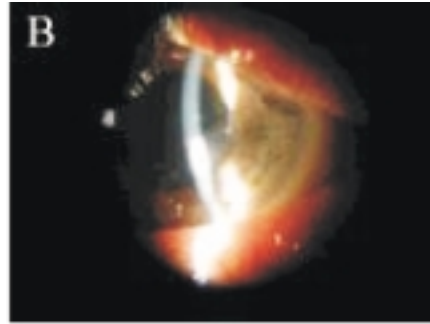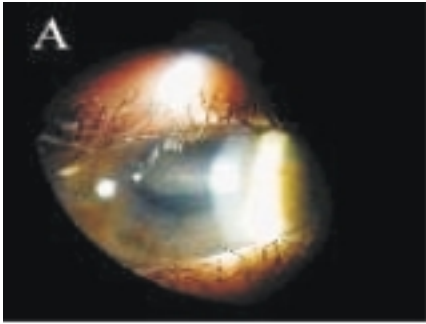
Result of the surgery was evaluated by patients' symptoms (pain, discomfort or irritation), inflammation signs and healing time of the operated eye. Fluorescein staining was used to detect epithelial defects. All patients were examined on the first postoperative day, at the end of the first postoperative week, as well as second, third and fourth postoperative week and monthly thereafter. Cor-

TABLE 1
DEMOGRAPHIC AND CLINICAL DATA OF OPERATED PATIENTS

Case	Age (years)	Gender	Causes of ulcer	Eye location	Duration of ulcer (weeks)	Previous management	AMT	Epithelial healing (weeks)	Follow-up (months)	Complication systemic illness	Pre. VA	Post. VA
1.	31	M	neuroma	L/n	88	art. tears	2 layers	1	14		0.01	0.01
2.	27	M	neuroma	L/n	57	art. tears	2 layers	1	19		0.1	0.1
3.	46	M	neuroma	L/c	91	art. tears CL	2 layers	2	13		NLP	NLP
4.	37	F	neuroma	R/c	141	art. tears	monolayer	1	28		0.05	0.05
5.	50	M	alk. burns	L/c	11	art. tears	2 layers	2	15	PKP in 16 th week	LP	LP
6.	48	F	alco. inj.	R/i	173	art. tears	monolayer	2	30		0.1	0.2
7.	12	M	meningitis	R/c	201	art. tears CL	monolayer	1	21	epilepsy ulcer recidive in 22 nd week	0.2	0.4
8.	61	F	retro. injection	R/i	107	punctual occlusion	monolayer	2	17		NLP	NLP
9.	47	F	excision of teeth	R/i	73	art. tears	monolayer	2	33	diabetes mellitus	0.5	0.5
10.	36	F	multiple eye op.	L/i	89	art. tears	2 layers	3	12	lupus erythematosus	LP	LP
11.	29	M	herpes zoster	L/c	103	tarsorrhaphy	2 layers	1	15	schizophrenia lost graft: re-grafting after 4 days	0.1	0.5

AMT = amniotic membrane transplantation, M = male, F = female, R = right eye, L = left eye, c = central part of cornea, n = nasal part of cornea, i = inferior part of cornea, alk. burns = alkali burns, alco.inj. = alcohol injection, op. = operations, art.tears = artificial tears, CL = contact lens, PKP = penetrating keratoplasty, pre.VA = preoperative visual acuity, post.VA = postoperative visual acuity, NLP = no light perception, LP = light perception

CMYK



neal epithelization healing was classified as success or failure.

The preoperative and postoperative data were analyzed by χ^2 and t test, and p value lower than 0.05 was considered significant.

Results

Amniotic membrane transplantation was performed in 11 patients (11 eyes) with neurotrophic ulcers (Table 1).

The mean age of patients was 38.5 ± 10.8 years (ages between 12 and 61), 5 patients were females (45.5%) and 6 males (54.5%). In 4 patients the cause of neurotrophic problems with cornea was acoustic neuroma surgery, one patient has developed corneal ulcer after alcohol injection because of trigeminal neuralgia, and one patient after extraction of right upper molar and cross section of arteria temporalis superficialis (so called vascular decompression to perform sympathetic denervation) performed by a neurosurgeon because of intensive pain after the tooth extraction (Figure 1). After this surgery patient still had pain in the region of innervation of nervus maxillaris and auriculotemporalis. One year later decreased corneal sensitivity was found and she developed a neurotrophic ulcer. One patient (12 years old) has developed epithelial defects due to the meningitis which he had during varicella infection in age of 2. His first problems with cornea occurred at the age of 8. He was treated with artificial tears, resurfacing gels and

contact lens – without any result. In four patients the reason for developing neurotrophic ulcer was direct ocular damage: in one patient the ulcer was caused by alkali burns of cornea, in one patient by herpes zoster ophthalmicus, and two patients have had multiple eye surgeries: in one patient corneal ulcer developed due to multiple surgeries of retinal detachment (conventional surgery twice and vitrectomy with silicon oil once) and in one patient, who was previously operated by trabeculectomy, after retrobulbar injection of 2% lidocain because of extracapsular cataract extraction. In this patient amaurosis developed immediately after injection. After 2 months neurotrophic ulcer was proven (Table 1).

The duration of persistent corneal ulcers varied from 11 weeks up to 4 years with an average of 103.1 ± 38.1 weeks, i.e. almost 2 years. All patients were initially treated with artificial tears and resurfacing lubricants or contact lenses and prophylactic antibiotics but there were no results. In one patient punctual occlusion by cauterization was performed as well in one partial tarsorrhaphy.

One patient had diabetes mellitus, one lupus erythematosus, one patient suffered from schizophrenia and one had epilepsy. The ulcer was located in 5 patients in central cornea, in 4 patients in inferior periphery of cornea and in 2 patient in nasal periphery of cornea.

The average healing period was 1.6 ± 0.6 weeks. The longest healing period was in the patient with diabetes mellitus despite

☉ *Fig 1. Neurotrophic ulcer of young boy who had meningitis in age of 2 (A). The same cornea 16 months after application of amniotic membrane (B). Deep persisting ulcer on inferior part of cornea in patient who developed neurotrophic ulcer after retrobulbar injection of 2% lidocain because of extracapsular cataract extraction: preoperatively (C), postoperatively (D). Fluorescein positive inferior cornea of the patient who underwent excision of the right upper molar (E) and fluorescein negative cornea 2 months after amniotic membrane transplantation (F). Central neurotrophic persistent ulcer in patient with schizophrenia (G) and fluorescein negative cornea 12 months after operation (H).*

the fact that in this patient multilayer amniotic membrane was transplanted. One patient has lost his graft on the 6th day after the surgery, so new application of amniotic membrane was necessary. The follow up period was 19.7 ± 6.0 months. All eyes were followed up more than one year and in all eyes even 12 months or longer after operation epithelization was present, except in one patient. In the eye of a boy who had his ulcera due to varicella meningitis in childhood (12 years old), 21 months after operation neurotrophic ulcer occurred as recidive. We have performed new application of amniotic membrane, but since only 12 weeks have passed after the second surgery the data concerning the success of this re-operation could not be included in this study.

Neurotrophic ulcera were in 5 eyes situated centrally, in 2 patients in the nasal periphery of cornea and in 4 eyes in inferior corneal periphery. Postoperative visual acuity was improved in 3 eyes and has shown no change in 8 eyes. There was no worsening in visual acuity as compared to the preoperative period in any patient (Table 1). However visual acuity was not the parameter for evaluating the success of operation.

Discussion

In this study we have evaluated the efficacy and safety of amniotic membrane transplantation in neurotrophic ulcera. The common feature of all the analyzed patients was the fact that persistent epithelial defect was a result of damage of corneal sensory nerve. The nerve was affected by herpes, retrobulbar injection, surgical removal of tumors, meningitis or multiple ocular surgery.

The amniotic membrane has several properties that are useful in managing of epithelial defects: it prevents mechanical trauma caused by lids because it serves as biological bandage lens, it prevents ex-

posure and dryness and it promotes ocular surface healing^{2,6,7}.

The AMT has been used since 1910.g. when Davis introduced in general surgery for skin transplantation⁸. In ophthalmology AMT was first reported by De Roth⁹ in the reconstruction of conjunctival defects in 1940 Kim and Tseng¹⁰ reported a new dimension and possible use of amniotic membrane transplantation. They used it in ocular surface reconstruction in rabbits after removal of the epithelium and limbal lamellar keratectomy. Recently, amniotic membrane has been used for ocular reconstruction following chemical or thermal burns, advanced ocular cicatricial pemphigoid and Steven-Johnson syndrome, for pterygium excision, conjunctival surface reconstruction, sterile corneal ulceration and symptomatic bullous keratopathy¹¹.

The amniotic membrane is composed of monolayer epithelial cells, a basement membrane, and an avascular stromal matrix¹². The membrane permits rapid epithelization due to various mechanisms: it facilitates migration of epithelial cells, reinforces adhesion of basal epithelial cells, promotes epithelial differentiation and prevents epithelial apoptosis. The stromal side of the membrane also contains a component that suppresses TGF- β signaling, and the proliferation and differentiation of myofibroblast of normal corneal and limbal fibroblasts and normal human corneal and limbal fibroblasts¹³. This action explains why ATM prevents recurrent scarring after pterygium removal¹¹. Furthermore amniotic membrane produces basic fibroblast growth factor, hepatocyte growth factor and transforming growth factor β , while stromal matrix excludes inflammatory cells and contains several forms of protease inhibitors¹⁴. These properties are the reason why stromal inflammation is reduced after AMT and corneal neovascularization is mitigated.

Because of all the mentioned reasons AMT can be considered as an effective approach for treating persistent sterile corneal ulcerations. In our study we have applied amniotic membrane in 11 cases in which the epithelization occurred in less than 2 weeks postoperatively.

This result is consistent with previous reports in which ATM was used to treat corneal ulcers. Lee et al.⁶ performed AMT in 11 eyes with corneal ulcerations caused by different causes and healed 10 of 11 eyes. Kruse et al. (1999)⁷ reported about corneal ulcerations treated by multilayer AMT and 9 of 11 remained stable for 1 year. In accordance with this report we have also noted that the ocular surface inflammation was reduced after AMT. These findings support recent studies showing that the stromal matrix of the amniotic membrane excludes inflammatory cells, contains various forms of protease inhibitors, and suppresses transforming growth factor β (TGF β) signaling as well as proliferation and myofibroblast differentiation of normal human corneal and limbal fibroblasts¹⁴. A recent study also showed that preserved amniotic membrane expresses mRNAs for several growth factors and contains different growth factor proteins that can help the epithelisation¹².

Pain relief after AMT is associated with restoration of corneal epithelial integrity and can be contributed to the therapeutic effect of amniotic membrane.

As Tseng recently pointed out, amniotic membrane firstly provides a new basement membrane; secondly exerts an anti-inflammatory effect; thirdly has a direct

anti-scarring effect; fourthly the combination of the above three actions may help re-establish a micro-environmental niche that is conducive for the growth of epithelial progenitor cells; and fifthly the amniotic membrane may promote nerve regeneration by maintaining nerve growth factor (NGF) signalling¹⁵.

In some cases the use of amniotic membrane can even eliminate the need for penetrating keratoplasty¹². AMT is particularly beneficial in countries with the lack of grafts^{16,17}. The technique is simple, easy to perform with no additional serious adverse effects for the patient.

It is questionable whether the success of AMT depends upon how long the epithelial defect has persisted before amniotic membrane transplantation. In our small group of patients, most of them have suffered from neurotrophic ulcers longer than 11 months before AMT and all of them have tried prior to AMT all conventional treatment methods. We could not be sure whether this method should be performed immediately when the first signs of neurotrophic ulcers appear or delayed until all conventional treatment failed, as was the case in our analyzed group. Although our results clearly indicate a beneficial effect of AMT for ocular surface reconstruction in neurotrophic corneal ulcers, a larger, randomized, probably multicentric study should be performed to answer all the questions which are still open, particularly the issue when would be the optimal time to perform amniotic membrane transplantation in these patients.

REFERENCES

1. TSENG, S. C. G., *Am. J. Ophthalmol.*, 124 (1997) 825. — 2. CHEN, H. J., R. T. F. PIRES, S. C. G. TSENG, *Br. J. Ophthalmol.*, 84 (2000) 826. — 3. CEROVSKI, B., J. ŠIKIĆ, J. JURI, J. PETROVIĆ, *Coll. Antropol.*, 25 Suppl. (2001) 47. — 4. KOVAČEVIĆ, S., B. CEROVSKI, Z. BUJGER, Z. PAŠTAR, J. PETROVIĆ, *Coll. Antropol.*, 25 Suppl. (2001) 63. — 5. LAMBIASE, A., P. RAMA, S. BONINI, *N. Engl. J. Med.*, 338 (1998) 1174. — 6. LEE, S. H., S. C. G. TSENG, *Am. J. Ophthalmol.*, 123 (1997) 303. — 7.

- KRUSE, F. E., K. ROHRSCHEIDER, H. E. VOLCKER, Ophthalmology, 106 (1999) 1504. — 8. DAVIS, J. W., Johns Hopkins Med. J., 15 (1910) 307. — 9. DE ROTH, S., Arch. Ophthalmol., 23 (1940) 522. — 10. KIM, J. C., S. C. G. TSENG, Cornea, 14 (1995) 473. — 11. DEKARIS, I., N. GABRIĆ, Ž. KARAMAN, I. MRAVIČIĆ, S. KAŠTELAN, N. ŠPOLJARIĆ, Coll. Antropol., 25 Suppl. (2001) 7. — 12. DEKARIS, I., N. GABRIĆ, Ž. KARAMAN, I. MRAVIČIĆ, S. KAŠTELAN, N. ŠPOLJARIĆ, Coll. Antropol., 25 Suppl. (2001) 23. — 13. SENG, S. C. G., D. O. LI, X. J. MA, Cell. Physiol., 179 (1999) 325. — 14. NA, B. K., J. H. HWANG, J. C. SHIN, Invest. Ophthalmol. Vis. Sci., 39 (1998) 90. — 15. TSENG, S. C. G., Br. J. Ophthalmol., 85 (2001) 1400. — 16. GABRIĆ, N., I. DEKARIS, B. VOJNIKVIĆ, Ž. KARAMAN, I. MRAVIČIĆ, I. KATUŠIĆ, Coll. Antropol., 25 Suppl. (2001) 17. — 17. MRAVIČIĆ, I., N. GABRIĆ, I. DEKARIS, Ž. KARAMAN, V. KERHIN-BRKLJAČIĆ, Z. GRUBIĆ, N. ŠPOLJARIĆ, Coll. Antropol., 25 Suppl. (2001) 1.

R. Iveković

Department of Ophthalmology, University Hospital »Sestre milosrdnice«, Vinogradska 29, 10000 Zagreb, Croatia

TRANSPLANTACIJA AMNIJSKE MEMBRANE U REKONSTRUKCIJI POVRŠINE OKA KOD NEUROTROFNOG ULKUSA ROŽNICE

S A Ž E T A K

Cilj studije bio je analizirati učinkovitost transplantacije humane amnijske membrane kod neuroparalitičkog ulkusa. Kod 11 očiju aplicirana je amnijska membrana od siječnja 1999. godine. Razdoblje praćenja bilo je duže od 12 mjeseci: 19,7±6,0 mjeseci. Period cijeljenja rane nakon operacije bio je 1,6±0,6 tjedana. Sve rožnice bile su fluorescein negativne i 12 mjeseci nakon operacije. Kod 8 očiju vidna oštrina nakon transplantacije bila je identična onoj prije operacije. Kod 3 oka vidna oštrina je nakon operacije bila bolja. Transplantacija amnijske membrane može se smatrati efikasnom alternativom terapije perzistirajućih defekata epitela rožnice, kao što je to neuroparalitički ulkus. Ona ima određene prednosti pred transplantacijom rožnice: jednostavna operativna tehnika, nema odbacivanja transplantata i dobrodošla je zamjena u zemljama s nedostatkom transplantata rožnice.