

Coll. Antropol. **27** (2003) 2: 611–616  
UDC 611.819:612.824  
Original scientific paper

# The Fate of the Arachnoid Villi in Humans

Jelena Krmpotić-Nemanić, Ivan Vinter, Zlatko Kelović and Slaven Suknaić

Department of Anatomy »Drago Perović«, School of Medicine, University of Zagreb, Zagreb, Croatia

## ABSTRACT

*Villi arachnoidales undergoes in the course of life changes in relation to the skull bones and sinuses. Our aim was to determine the relations of the villi arachnoidales to the skull bone and/or sinuses from the neonatal period to adults. The investigations were performed on collection of 50 disarticulated macerated skull bones from the newborn to 30 years of age and on 20 skulls from individuals in the life period from 30 to 80 years of age. Villi arachnoidales produced imprints on the skull bones in the shape of holes and/or furrows corresponding to different shape of the villi arachnoidales. These imprints appeared very early in the period when the bony sprouts of the large skull bones received a thin covering of compact bone, the future lamina vitrea. At that time villi arachnoidales had no connection with the dural sinuses but with the diploe and with the diploic veins. By agglomeration of the villi in larger and large formations, granula meningea, Pacchionian granulations, the contact to sinuses was realized by means of short channels. The structural changes of villi arachnoidales may produce thrombophlebitis and hydrocephalus externus, especially in children. The fate and the relations of the villi arachnoidales are therefore of great importance for neurologist, neurosurgeon and otorhinolaryngologist.*

**Key words:** *villi arachnoidales, skull bones, arachnoidea, diploic veins, foveolae granulares, Pacchionian granulations, hydrocephalus*

---

## Introduction

Arachnoid villi undergo in the course of life changes concerning the shape, density and/or agglomeration in larger formations, i.e. Pacchionian granulations. Pacchionian granulations produce de-

fects in the skull bones forming the foveolae granulares. Larger agglomerations of foveolae granulares, fossae lacunares, are said to be localized at either side of the dural sinuses communicating with them

by short channels. The investigations related to the arachnoid villi and/or Pacchionian granulations are connected with names of Key-Retzius<sup>1</sup> and Weed<sup>2,3</sup> who found that »the major absorption of the cerebrospinal fluid in the region of the brain is directly into the great dural venous sinuses by way of villi arachnoidales. Villi were found to occur in all of the common laboratory mammals and in infants. When hypertrophied as in adults, they were identified as the well known Pacchionian granulations. The structure of the arachnoid villus consists of a reduplication of the meshes of the arachnoidea with usually a decreased size of the network. The covering of the cells of the arachnoid membrane are carried into the defect of the dural fibrous tissue so that arachnoidal cells come to lie directly beneath the endothelium of the great venous sinuses. In most cases there is a more or less outspoken aggregation of arachnoidal cells at the top of the villus<sup>2</sup>.« The villi in the region of the basilar sinuses are more cellular and of a smaller mesh<sup>4</sup>. Mesothelial cells are capping the villus. Between the mesothelium and the collagen structure there exists a net of fibres<sup>5</sup>. Besides the structural villi there exist also finger-shaped arachnoidal cell-strings which penetrate the more distant dural tissue. The shape of the villi can be egg-shaped, pear-shaped or grape-shaped. According to Gärtner and col.<sup>4</sup> the Pacchionian granulations appear with 18 months and become tighter in the course of life. According to Hommer<sup>6</sup> the Pacchionian granulations are distributed independently from the sinuses over the cerebral surface. Rouvière<sup>7</sup> mentions that the Pacchionian granulations can protrude either into blood lakes or into the dural sinuses. On the contrary Adams<sup>8</sup> describes a direct communication of the arachnoidal granula with major dural sinuses. Gomez-Potts<sup>9</sup> describe »that the arachnoid granulations are protrusion of

arachnoid cells through small dural defects into the superior sagittal sinus or tributary veins». Ojala<sup>10</sup> mentions that the villi can penetrate the spaces and the venous spaces in the region of the middle ear causing in certain cases the thrombophlebitis. Shukla and coll.<sup>11</sup> mention the connection of the dural sinuses with the diploic veins.

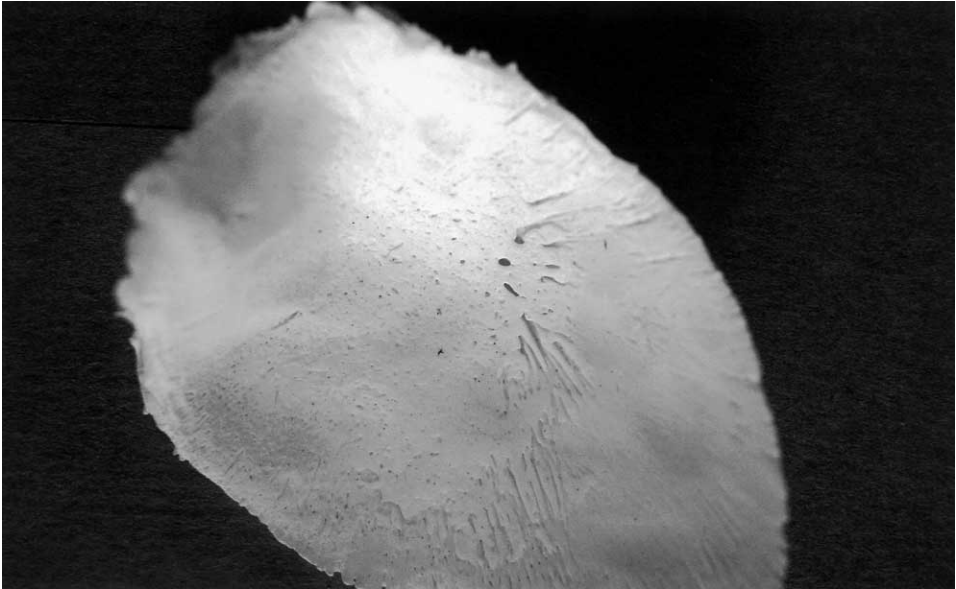We decided to study in human material the relations of the villi and of the Pacchionian granulations to the skull bones, to the dural sinuses and the diploic veins in different life periods.

## Material and Methods

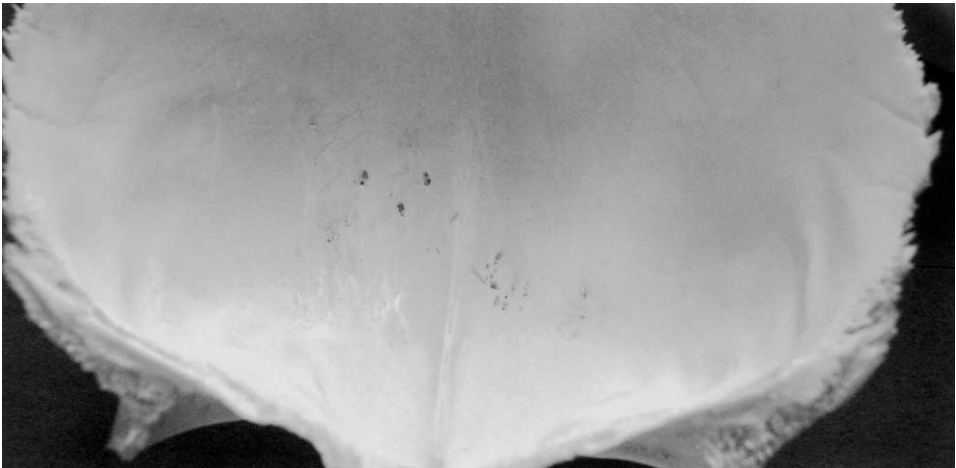We investigated the first appearance of the holes and/or furrows produced by villi arachnoidales and/or by granula meningea in human material on our collection of 50 skull bones in the life period from the newborn to 30 years of age. We checked also the localization, the depth and the shape of the foveolae granulares and fossae lacunares on 20 specimens of the individuals in the life period from 60 to 80 years of age.

## Results

The holes and the furrows produced by villi arachnoidales were found already in the human newborn i.e. in the period when bony sprouts of the skull bones got the first covering of the future lamina vitrea (Figure 1). These holes were spread over the skull bones independently of the future dural sinuses. We gave to these holes the name »foveolae arachnoidales«. With agglomeration of the villi appeared deeper holes in the skull bones, the foveolae granulares. They appeared already with 3 years of age (Figure 2), which is much earlier than stated in general in the literature (10 years of age)<sup>12</sup>. Neither of these formations was in this life period related to the sinuses (Figure



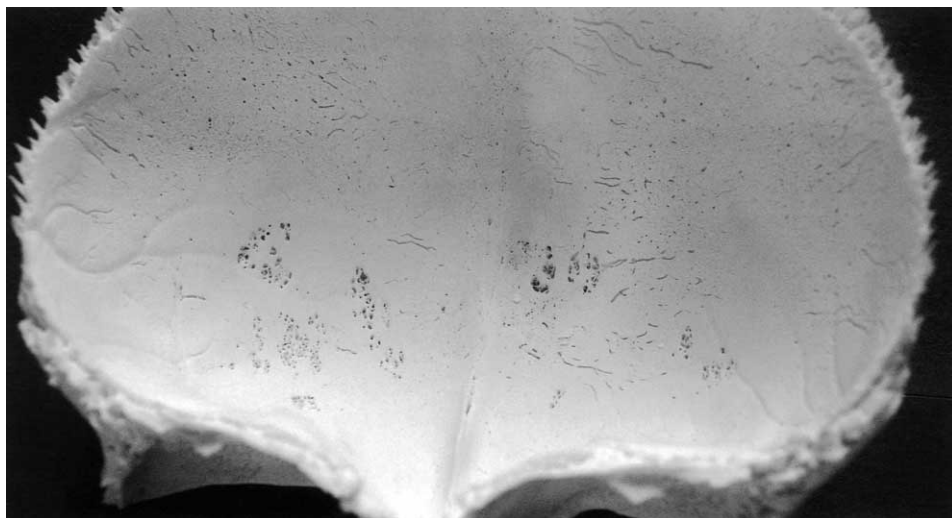
*Fig. 1. The squama of the frontal bone consists in the newborn of bony sprouts which display a thin covering by the future lamina vitrea. Lamina displays imprints in shape of holes and furrows corresponding to the differently shaped villi arachnoidales.*



*Fig. 2. Foveolae granulares on the inner surface of the squama of the frontal bone in a 3 years old child. They are situated far from sinuses and communicate with diploic space and diploic veins.*

3). By intensive agglomeration of the Pacchionian granulations appeared in older individuals on the inner surface of the

skull bones larger multilocular holes, fossae lacunares, most of which were situated on either side of the large dural si-



*Fig. 3. Foveolae granulares in a 7 years old child spread over the inner surface of the frontal bone without direct connection with the sinus sagittalis superior. In this life period the communication with the sinuses is still not realized. It will be realized in later life periods and in adults.*

nuses and connected with them by means of short channels. A large number of fossae lacunares situated in the region of the ala magna of the sphenoid bone, in the inferior part of the squama of the temporal bone and in the cerebellar fossae were not directly connected with the dural sinuses but with diploic veins and/or venous plexuses e.g. plexus pterygoideus.

The foveolae granulares found between the tegmental region and the temporal squama are probably identical with the cases described by Ojala<sup>10</sup>. The number of the foveolae arachnoidales as well as of the foveolae granulares prevailed in the frontal and parietal bones. The fossae lacunares were mostly localized on either side of the superior sagittal sinus and in the region of the confluens sinuum. In some cases the fossae lacunares penetrated through the diploe to the level of the outer lamina vitrea or even under the periosteum of the skull bones.

## Discussion

The finger-shaped, pear-shaped or grape-shaped prolongations of the arachnoid, villi arachnoidales produced imprints in the shape of holes or furrows within the first thin layer of the internal lamina vitrea of the skull bones. These holes and/or furrows were spread all over the skull bones but they prevailed in the frontal bone. The imprints of the villi as well as the villi themselves had no connections with the developing sinuses. After the formation of the inner lamina vitrea the villi formed agglomerations, granula meningeae, which produced foveolae granulares. The foveolae granulares were spread over the skull bones without communication with the dural sinuses. Foveolae granulares appeared already with 3 years of age which is much earlier than stated in the literature. Further agglomerations of the meningeal granula produced larger imprints, fossae lacuna-

res, which approached the big dural sinuses realizing connections with them by means of short channels. The filtration of the liquor from the villi and from the Pacchionian granulations was realized at first via the diploic spaces and diploic veins. The general statement that Pacchionian granulation and/or foveolae granulatae are always connected with the sinuses is not correct. The greatest number of foveolae granulatae had no connection at all with the sinuses. Fossae lacunares as the large recipients and the filtration place of the liquor approached the sinuses especially in the region of the sinus sagittalis superior and the confluens sinuum and usually were connected with them by means of short channels. The appearance of the fossae lacunares in the regions far from the sinuses speaks in favor of the fact that the subarachnoidal spaces and /or cisternae are directly connected with the diploic venous system<sup>13</sup>.

The contact with the big dural sinuses is realized in later life periods. This contact might however be missing.

The relation of the villi arachnoidales and granula meningea to the dural si-

nuses, diploic veins or diploic spaces are of great importance in neurology, neurosurgery, pediatric neurosurgery and otorhinolaryngology.

Penetration of the villi in the region of the middle ear can cause thrombophlebitis. The penetration of villi and/or granula meningea through the ala magna of the sphenoid bone can cause thrombophlebitis of the pterygoid plexus which many results in a neuralgia of the mandibular nerve. The penetration of the villi and/or granula meningea through the skull bones may represent the way of infections in either direction. This is more likely to happen in adults where the agglomeration of villi in large formation occurs more often than in children.

The situation within the region of villi arachnoidales is of great importance in pediatric neurology and pediatric neurosurgery<sup>14</sup>. Changes in the structure of villi may be responsible for development of ventricular subarachnoidal hydrocephalus<sup>15</sup> or chronic hydrocephalus<sup>16</sup>.

## REFERENCES

1. KEY, G., A. RETZIUS: Studien in der Anatomie des Nervensystems und des Bindegewebes. (Stockholm, 1875). — 2. WEED, L. H., Am. J. Anat., 31 (1923) 191. — 3. WEED, L. H., J. Med. Res., 31 (1914) 51. — 4. GÄRTNER, J., J. PFEIFFER, H. E. SCHAEFER, W. SCHÄTZLE, J. M. SCHRÖDER: Pathologie, T. 4: Neuropathologie. (Springer, Berlin-Heidelberg-New-York-Tokyo, 1984). — 5. SCHWAB, M.: Beitrag zur Morphologie der Pacchionischen Granulationen (Granula meningica) des Menschen. Diss (Med. Fakult., Kiel, 1949). — 6. HOMMER, H.: Ueber die Verteilung der Pacchionian Granulationen über der Hirnoberfläche. (Inaug. Diss., Leipzig 1948). — 7. ROUVIÈRE, H.: Anatomie humaine: T. 3. (Masson, Paris, 1974). — 8. ADAMS, J. H.: Greenfield's neuropathology. (Edward Arnold, London-Melbourne-Auckland, 1992). — 9. GOMEZ, D. G., D. POTTS G., Arch. Neurol., 31 (1974) 88. — 10. OJALA, L., Acta Path. Scand., 91 Suppl. (1951) 88. — 11. SHUKLA, V., L. A. HAYMAN, K. H. TABER, J. Comp. Ass. Tomogr., 27 (2003) 98. — 12. JUDAŠ, M., I. KOSTOVIĆ: Fundamentals of neuroscience. In Croat. (University of Zagreb, Zagreb, 1997). — 13. LANG, J., Acta Anat., 86 (1973) 267. — 14. ABRIGHT, A., J. LELAND, F. POLLACK, P. D. ADELSON: Principles and practice of pediatric neurosurgery. (Thieme, New York-Stuttgart, 1999). — 15. CHAZAL, J., B. IRTHUM, T. JAN- NY, Neurochirurgie, 35 (1989) 379. — 16. MESSI-COTE, E. M., M. R. DEL BIGIO, J. Neurosurg., 91 (1999) 80.

*J. Krmpotić-Nemanić*

*Department of Anatomy »Drago Perović«, School of Medicine, University of Zagreb,  
Šalata 11, 10000 Zagreb, Croatia*

## **SUDBINA ARAHNOIDALNIH RESICA U ČOVJEKA**

### **S A Ž E T A K**

Villi arachnoidales mijenjaju u toku života odnos prema kostima lubanje i sinusima. Cilj ove studije bio je odrediti odnos arahnoidalnih resica prema kostima lubanje i sinusima u postnatalnom životu. Istraživanja smo vršili na seriji od 50 rastavljenih maceriranih lubanja u dobi od novorođenčeta do 30 godine života, kao i na 20 lubanjskih baza u dobi od 30 do 80 godine života. Villi arachnoidales ostavljaju na kostima lubanje otiske u obliku rupica i brazda što odgovara obliku arahnoidalnih resica. Ti tragovi se vide vrlo rano, u stadiju kad koštani prutići na ljudskim pokrovnim kostima lubanje počinju dobivati sloj kompaktne kosti koja stvara laminu vitreu. U to vrijeme villi arachnoidales nemaju veze sa sinusnim nego sa spongiozom, diploe, i diploičnim venama. Kasnije spajanjem arahnoidalnih resica u veće i velike formacije, granula meningeae, Pacchionove granulacije, dolaze najveće skupine resica putem kratkih kanala u kontakt sa sinusima. Stanje arahnoidalnih resica i eventualne njihove promjene mogu biti uzrok tromboflebitisa i hidrocefalusa, osobito kod djece. Stoga je poznavanje odnosa arahnoidalnih resica i njihovih odnosa od velike važnosti za neurologa, neurokirurga i otorinolaringologa.