

Pulmonary Embolism Caused by a Migrated Gunshot Projectile

Grgur Dulić¹, Krešimir Čandrić¹, Robert Blažeković¹, Krunoslav Šego¹, Hrvoje Gašparović², Gordan Šarić³ and Jasenka Čandrić-Kalajdžić⁴

¹ Department of Surgery, University Hospital »Osijek«, Osijek, Croatia

² Department of Cardiac Surgery, University Hospital »Rebro«, Zagreb, Croatia

³ Department of Radiology, University Hospital »Osijek«, Osijek, Croatia

⁴ Department of Anesthesiology, University Hospital »Osijek«, Osijek, Croatia

ABSTRACT

Pulmonary embolism caused by a foreign body is an exceedingly rare event. We report on a 62 year old woman who suffered a gun shot injury to her left knee with concomitant vascular lacerations. The bullet migrated through the venous system into the pulmonary circulation causing a pulmonary embolism. The projectile remained stationary for ten years. Taking into consideration that she is virtually asymptomatic and that regular follow up examinations showed no further migration of the foreign body, we opted for a conservative venue of management.

Key words: *pulmonary embolism, foreign body, trauma*

Introduction

Missile embolism to the pulmonary artery remains a rare complication of gunshot wounds. Embolisation from a peripheral vein to the heart was first described by Thomas Davis in 1834¹³ and embolism to the pulmonary artery was first reported by Morestin in 1903⁷. There is significant controversy regarding the management options of a foreign body wedged within the pulmonary vascular tree. Management can be challenging (conservative^{8–13} vs. extraction^{1–7}) especially in patients presenting hemorrhagic shock. Embolism is likely to occur with a low velocity metallic projectile, since it loses most of its energy as it courses through soft tissues and may traverse only one wall of the vessel⁷. The bloodstream sweeps the missile away resulting in remote embolism. Whenever initial X-ray films fail to visualize the missile, remote X-ray films must be obtained.

Case Report

62 year old woman was admitted to the hospital for treatment of a gunshot wound to her left knee. There was no exit wound. Peripheral pulses of the left leg were absent. A X-ray study located missile within the left thigh (Figure 1). Surgical exploration of the wound revealed

laceration of the common femoral artery and vein. The artery was repaired with a greater saphenous vein patch harvested from the contralateral leg. The venous defect was sutured primarily. The foreign body itself, however, was not found. Twelve hours after the operation she was found to have excessive bleeding from the operative wound. Additionally, she had developed symptoms of deep venous thrombosis. Contrast venography proved calf venous, popliteal vein and distal femoral vein thrombosis. Dispersion of the contrast into the soft tissues at the site of the primary vein laceration was also shown. The missile had remained in the same position. Reconstruction of the bleeding site on the femoral vein was performed with an graft coated with collagen. This was preceded by removal of thrombi from the deep calf veins, popliteal vein and distal femoral vein. The missile could not be located. In the immediate postoperative period the patient complained of shortness of breath. A chest radiograph was performed which showed that the missile had migrated into the chest (Figure 2). Pulmonary angiography showed partial blockage of the pulmonary artery branch for the right middle lobe of the lung (Figure 3). Since the patient was asymptomatic the extraction of the missile was not performed. The patient was discharged home one

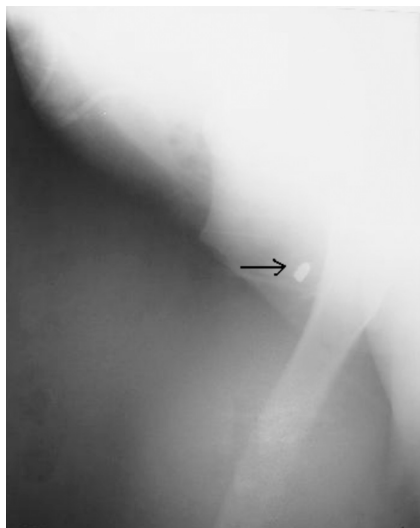


Fig. 1. Bullet in left thigh.

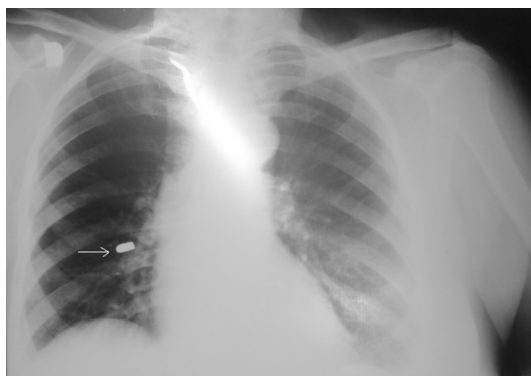


Fig. 2. Chest X-ray showing a bullet in the midzone of the right chest adjacent to the hilum of the right lung.

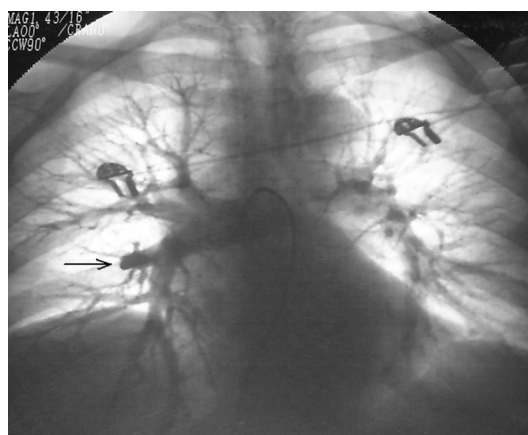

Fig. 3. Pulmonary angiography show partial blockage of the pulmonary artery branch for the right middle lobe of the lung.

month after the incident. Her subsequent course was uneventful. Regular follow up chest X-ray studies did not show migration of the missile within the pulmonary ar-

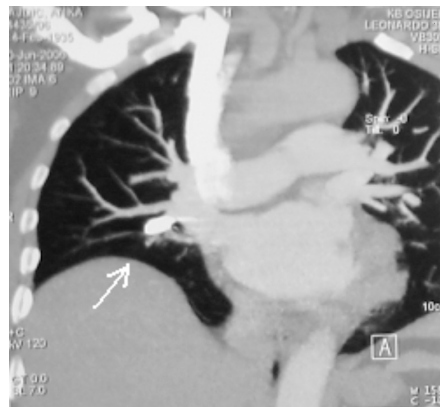


Fig. 4. Computed tomography of chest shows missile in pulmonary artery branch for the middle lobe of the lung.

tery tree. She was medically managed by a cardiologist for her arterial hypertension and incipient hypertensive cardiomyopathy. Ten years after her gunshot injury she was presented with mild dyspnea on exertion. Cor pulmonale was suspected, base on her case history. Chest X-ray and computed tomography angiography proved the missile was still lodged within the chest at its earlier position (Figure 4). Transthoracic echocardiography showed concentric left ventricular hypertrophy and only mild aortic valve stenosis. The morphology of the right ventricle was normal, as were the pressures in the right sided heart structures. Radionuclide images showed a partial perfusion defect in the middle lobe of the right lung. Color Doppler study demonstrated recanalisation of the veins of the left leg, a non-obstructed graft on the left femoral vein and patent arterial tree of the left leg. Mild chronic venous insufficiency was present.

Discussion

The diagnosis of foreign body embolism should be suspected in every gunshot wound if there is no exit wound and if the missile is not found in the operative field. Clinical manifestations of missile emboli to the pulmonary artery vary. Although usually asymptomatic, patients sometimes experience chest pain, dyspnea, hemoptysis, vascular erosions, pulmonary infarction, sepsis, or pulmonary vascular thrombosis. For this reason early extraction of the embolus (catheter extraction or thoracotomy with bullet embolectomy) was suggested by some¹⁻⁷. On the other hand many authors recommend a conservative approach⁸⁻¹³ in patients lacking symptoms. Singer⁵ reported migration of the missile within pulmonary arterial tree, even to the contralateral side prior and during the embolectomy. A second thoracotomy was sometimes needed. In our case, we have chosen a conservative approach. During ten year follow-up period the embolus had no effect on the patient's clinical status. There was no demonstrable impact on hemodynamic parameters either. The mild fatigue and exertional dyspnea could easily be attributed to the patient's age, hypertensive myocar-

diopathy or mild aortic stenosis. We, therefore recommend a conservative approach in the case of pulmonary embolism by a gunshot missile, provided no complications occur and no migration of the bullet within pu-

monary artery takes place. Regular follow up examinations are mandatory in order to early indentify possible complications.

REFERENCES

1. GUPTA AK, DOGRA VS, AHMAD I, DELBALSO AM, *Am J Emerg Med*, 15 (1997) 213. — 2. SYMBAS PN, HARALAFIS N, *Ann Surg*, 158 (1977) 318. — 3. STEPHENSON LW, WORKMAN RB, ALDRETE JS, KARP RB, *Ann Thorac Surg*, 21 (1976) 333. — 4. VAZQUEZ-VALDES E, CONTENO-OLGUIN V, HERNANDEZ-ZAMORA JM, BARRADAS-GUEVARA MC, *Rev Invest Clin*, 41 (1989) 57. — 5. SINGER RL, DANGLEBEN DA, SALIM A, KUREK SJ, SHAH KT, GOODREAU JJ, SHAFF DI, SZYDLOWSKI GW, *Ann Thorac Surg*, 76 (2003) 1722. — 6. JOHN LC, EDMONDSON SJ, *Thorac Cardiovasc Surg*, 39 (1991) 386. — 7. EZBERCI F, KARGI H, *South Med J*, 92 (1999) 1207. — 8. KORTBEEK JB, CLARK JA, CARRAWAY RC, *J Trauma*, 33 (1992) 906. — 9. MATTOX KL, BEAL AC Jr, ENNIX CL, DeBAKEY ME, *Am J Surg*, 137 (1979) 192. — 10. NEHME AE, *J Trauma*, 20 (1980) 344. — 11. LODDER JV, *S Afr J Surg*, 35 (1997) 94. — 12. PANICHABHONGSE V, KASANTIKUL V, PANICHABHONGSE S, KANLUAN S, *J Med Assoc Thai* 79 (1996) 676. — 13. GOLDMAN RL, CARMODY RE, *J Trauma*, 24 (1984) 277.

G. Dulić

*Department of Surgery, University Hospital »Osijek«, J. Huttlera 2, 31000 Osijek, Croatia
e-mail: grgurdulic@yahoo.com*

EMBOLIJA PLUĆA PROUZROČENA MIGRIRAJUĆIM PUŠČANIM PROJEKTILOM

SAŽETAK

Plućna embolija uzrokovana stranim tijelom iznimno je rijedak događaj. Prikazat ćemo slučaj šezdesetdvogodišnje žene koja je zadobila strijelnu ranu lijevog koljena s pridruženim ozljedama krvnih žila. Metak je migrirao kroz venski sustav u plućni krvotok i pritom uzrokovao plućnu emboliju. Narednih deset godina pretragama nije zabilježeno pomicanje metalnog stranog tijela. S obzirom da pacijentica nije imala stvarnih simptoma vezanih uz plućnu emboliju te redovitim pretragama nije utvrđeno daljnje pomicanje stranog tijela odlučeno je u korist konzervativnog načina liječenja.