

Long Term Results of Age-Related Macular Degeneration Therapy with Prednisolone Acetate – Special Refer to Peripheral Visual Field Changes

Božidar Vojniković¹, Damir Kovačević², Sanja Njirić³ and Miran Čoklo⁴

¹ Eye Polyclinic »Dr. B. Vojniković«, Rijeka, Croatia

² Department of Ophthalmology, University Hospital »Rijeka«, Rijeka, Croatia

³ Eye Polyclinic »Dr. L. Pavičević«, Rijeka, Croatia

⁴ Department of Forensic Medicine, School of Medicine, University of Rijeka, Rijeka, Croatia

ABSTRACT

In the north Croatian Adriatic area in the period of seven years (from January 2001 to September 2007) 475 patients (39 to 80 years of age) with dry form of age related macular degeneration (AMD) were diagnosed. Complete ophthalmologic examination with special reference to visual field testing (Perimetric analysis) was performed. Peripheral visual field defects were found in 85% of patients. Elderly patients with more advanced forms of macular degeneration had more peripheral visual field defects. In 400 patients corticosteroid therapy (5 mg Prednisolonacetate, anterior H-inject, Winthorp) was administered via parabolbar injections every day/five days. Control group consisted of 75 patients treated with regular polyvitamine therapy (Lutein, Beta Karoten, Vitamin E). Patients treated with corticosteroids had peripheral visual field improvements from 10 to 25 degrees and central field improvements from 5 to 20 %. In the control group treated with vitamins, central visual field showed improvements from 0.5 to 1% in 43 patients but without peripheral visual field improvements after 6 months.

Key words: macular degeneration, prednisolone acetate, visual field

Introduction

Age related macular degeneration (AMD) is one of the world leading causes of visual impairment in developed countries today. In advanced stages visual function is affected and may lead to macular blindness. Macular degeneration was considered as »central visual disease« or »macular disease«. Some recent publications are giving new insight to this disease, proposing that AMD is both central and peripheral neurosensory retinal disease^{1,2} and Ethan et al. in 2006 confirmed that hypothesis by proteomic analysis of the macular and peripheral neurosensory retina³.

It is well known that different meteorological factors can influence on humans⁴⁻¹². Special risk factors affecting eye status are ultraviolet A and B rays and »blue light«. Exposure to sunlight during summer in coast areas may lead to retinal photo-toxicity. Therapeutic approach to AMD varies, but most authors use similar

agents¹³⁻¹⁸. Some authors use corticosteroids in the treatment of dry macular degeneration¹⁹. The main topic of this paper is steroid treatment of age related macular degeneration with special reference to peripheral visual field improvements.

Patients and Methods

In 475 patients with dry form of macular degeneration special attention was dedicated to peripheral visual field analysis (Kowa perimeter) before and after finishing therapy. Patients were divided in two groups: the first group of 400 patients received five daily doses of 5 mg of Prednisolone acetate (anterior H-inject, Winthorp, Lichtenstein) in parabolbar injections. The second group of 75 patients was a control group and received multivitamin therapy (Lutein, Beta Karoten, Vitamin E) in ordi-

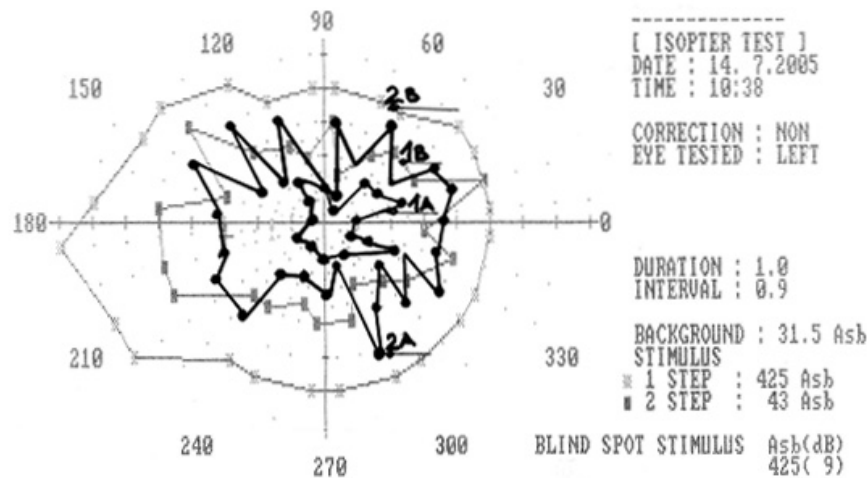


Fig. 1. Visual field before and after therapy with Prednisolone acetate (1A and 2A before; 1B and 2B after therapy).

nary doses. Visual acuity, visual field, intraocular pressure, biomicroscopic and fundus examination were performed before therapy, after first month and after 6 months of therapy.

Results

The first group of patients with parabolbar corticosteroid treatment gained peripheral visual field improvement from 10 to 25% and central improvement of 5 to 20%. In the control group there was a central improvement of 0.5 to 1 % in 43 patients but with no significant peripheral visual field improvement. Typical peripheral isopteres before and after therapy with steroids are shown on Figure 1. Sharp defects of visual field are diminishing after steroid therapy. »Meridian thresholds« of isoptere number 1 show the situation before therapy and isoptere number 2 show stimulus for central macula and periphery up to 35 degree.

Discussion and Conclusion

This large study with respective clinical material has shown that dry form of age related senile macular degeneration affects not only macular area. Peripheral neurosensory retina is very often affected. Central visual acuity in macular degeneration can be altered with certain vitamin therapy, especially vitamin E as an antioxidant. This effect on peripheral vision is minimal. Steroids (Prednisolone acetate) have significant impact not only on central visual acuity but also on peripheral vision.

Dry forms of age related macular degeneration affects entire neurosensory retina. It is very important to perform visual field exam as a standard adjunct to ophthalmological examination. Prednisolone acetate is a drug of choice in the treatment and prevention of dry macular degeneration which is a very serious problem in developed countries.




Fig. 2. Meridian threshold before and after therapy with Prednisolone acetate (1 before and 2 after therapy).

REFERENCES

1. VOJNIKović B, Einsteinov zakon elementarne fotokemijske reakcije. In Croat. (Veleučilište Velika Gorica, Zagreb, 2005.). — 2. VOJNIKović B, Coll Antropol, 31 (2007) 3. — 3. ETHEN CM, REILLY C, FENG X, TIMOTHY WO, FERRINGTON DA, Source Invest. Ophthalmol. Visual Sci., 47 (2006) 2280. — 4. URBACH F, The biologic Effects of Ultraviolet Radiation. (Pergamon Press Ltd, London, 1969). — 5. PENZAR B, PENZAR I, ORLIĆ M, Vrijeme i klima hrvatskog Jadrana, (»Dr. Feletar«, Koprivnica, 2001). — 6. VOJNIKović B, Coll Antropol, 31 (2007) 39. — 7. LERMAN S, Radiant energy and the eye, (MacMillan, New York, 1980). — 8. FORSIUS H, FORSMAN E, FELLMAN J, ERIKSSON AW, Acta Ophthalmol Scand, 80 (2002) 478. — 9. RODNEY B, Concepts in Biochemistry. (JohnWiley & Sons, Inc., Toronto, 2002). — 10. LISAC I, Gospodarstvo i okoliš, 33 (1998) 381. — 11. KWOK LS, CORONEO MT, Cornea, 13 (1994) 219. — 12. KANC RP, Int J Climat, 18 (1998) 457. — 13. LAZIĆ R, Coll Antropol, 31 (2007) 77. — 14. Treatment of age-related macular degeneration with photodynamic therapy (TAP) study group, Arch Ophthalmol, 117 (1999) 1329. — 15. WORMALD R, EVANS J, SMEETH L, HENSHAW K, Cochrane Database Syst Rev, CD002030 (2003). — 16. Verteporfin in photodynamic therapy study group, Am J Ophthalmol, 131 (2001) 541. — 17. LAZIĆ R, Coll Antropol, 31 (2007) 71. — 18. Treatment of age-related macular degeneration with photodynamic therapy (TAP) study group, Arch Ophthalmol, 119 (2001) 198. — 19. VOJNIKović B, Coll Antropol, 31 (2007) 69.

B. Vojniković

*Eye Polyclinic »Dr. B. Vojniković«, Antuna Barca 3B, 51000 Rijeka, Croatia
e-mail: decv@decv.com*

DUGOGODIŠNJA STUDIJA TERAPIJE SENILNE MAKULARNE DEGENERACIJE PREDNISOLON ACETATOM, S POSEBNIM OSVRTOM NA PERIFERNI VID

SAŽETAK

U periodu od 2001. do 2008. godine dijagnosticirali smo na području sjevernog hrvatskog primorja 475 slučajeva senilne makularne degeneracije (SMD), u dobi pacijenata od 39 do 80 godina. Pored rutinske oftalmološke pretrage, posebna se pažnja posvetila perifernom vidu. Defekt perifernog vida dijagnosticiran je u 85% pacijenata. Što su pacijenti bili stariji i makularna degeneracija jače uznapredovala, to je bio jači defekt periferije vida. U 400 pacijenata primijenjena je terapija preparatom Prednisolone acetate (Predni H injekt, Winthrop, Lichtenstein), s 5 mg parabolarno obotranu, svakog dana kroz 5 dana. Kontrolna skupina od 75 pacijenata tretirana je uobičajenom terapijom vitaminima za oči (Lutein, Beta Karoten, Vitamin E) u uobičajenim dozama. U svih 400 bolesnika tretiranih sa Predni H injekt, došlo je do vidljivog proširenja periferije vidnog polja za 10 do 25 stupnjeva, pored poboljšanja centralnog vida za 5 do 20%. U kontrolnoj skupini tretiranoj vitaminima za oči, poboljšao se centralni vid za 0,5 do 1% u 43 slučajeva, ali bez poboljšanja periferije, nakon tretmana od 6 mjeseci.