

# Human Papilloma Virus Associated with Genital Infection

Suzana Ljubojević<sup>1</sup>, Jasna Lipozenčić<sup>1</sup>, Dragana Ljubojević Grgec<sup>2</sup>,  
Ratko Prstačić<sup>3</sup>, Michael Skerlev<sup>1</sup> and Zrinka Bukvić Mokos<sup>1</sup>

<sup>1</sup> University Department of Dermatology and Venereology, University Hospital Centre »Zagreb«, Zagreb, Croatia

<sup>2</sup> Polyclinic for Gynaecology and Obstetrics, Dermatology and Venereology »Gynoderma«, Zagreb, Croatia

<sup>3</sup> Department of Otorhinolaryngology, University Hospital Centre »Zagreb«, Zagreb, Croatia

## ABSTRACT

*Genital human papillomavirus (HPV) infections are among the most common sexually transmitted diseases. HPV is associated with a spectrum of diseases ranging from benign vulgar verrucae and condylomata accuminata to malignant cancers of the cervix, vulva, anus and penis. Genital HPV is in most cases transmitted sexually, but non-sexual routes of transmission, such as perinatal and autoinoculation, are possible. Men can be a reservoir of the virus that lives in latent or subclinical form on genital mucosa. Such an asymptomatic infection may be an oncogenic factor in the development of cervical cancer. Colposcopic examination of the genitalia after the application of 3–5% acetic acid is a reliable method for the identification of subclinical HPV infection. Successful therapy of anogenital warts is characterized by their complete clearance, as well as by the lack of recurrence. Current treatments do not reliably eradicate HPV infections. The diagnosis and therapy of HPV infection in men is potentially beneficial because the eradication of penile HPV infection may decrease the reservoir of the virus.*

**Key words:** human papillomavirus (HPV), asymptomatic HPV genital infections, risk factors, peniscopy, treatment

## Introduction

The incidence of genital human papilloma virus (HPV) has risen dramatically over the past 30 years, and it is now the most common viral sexually transmitted disease (STD)<sup>1</sup>.

The existence of a disease that we today associate with HPV has been documented for centuries, yet it is only in the past two decades that we recognize the clinical diversity, as well as significant morbidity and mortality, associated with HPV infections<sup>2</sup>. Human papillomavirus is associated with a spectrum of diseases, from benign verrucae vulgares and condylomata accuminata to the malignancies of the cervix, vulva, anus and penis. Condylomata are among the most common human papilloma virus-related benign lesions of the genitourinary tract. Of more serious concern is the connection between certain HPV genotypes and malignancies, especially cervical and anal cancer. The clinical manifestation of HPV infection depends on the viral genotype, the immune status of the patient, and the environmental cocarcinogens<sup>3</sup>.

There are over 100 genotypes of HPV, of which approximately 50 infect the genital area<sup>4</sup>. They may be divided into two groups based on their oncogenic potential: low (HPV genotypes 6, 11, 40, 42, 43, 44, 54, 61, 70, 72, 81) and high (HPV genotypes 16, 18, 31, 33, 35, 39, 45, 51, 56, 58, 68, 73, 82). Infections with specific HPV genotypes have an important role in the development of genital cancer in both sexes. Usually, high-risk HPV infection is an important causal factor in the development of cervical intraepithelial neoplasia (CIN) and invasive carcinomas. By contrast, other HPV genotypes, referred to as low-risk HPV, are associated with the development of genital condylomata accuminata and other manifestations of HPV. Although the low risk HPV are primarily associated with condylomata accuminata, they have also been detected in vulvar and anal carcinomas<sup>5</sup>. This may be due to a concurrent infection with a high-risk oncogenic genotype, as HPV infections in anogenital lesions are often multifocal (present on several anatomic sites) and multiform, harbouring more than one HPV genotype<sup>6</sup>.

HPV often inflicts adolescents and young adults shortly after the onset of sexual activity. So, in the first ten years of sexual activity, point prevalence rates approach 25% and the lifetime risk of acquisition of this infection may be as high as 80%<sup>4</sup>.

Sexual transmission is the main pathway for genital HPVs<sup>7</sup>. However, since HPV has been detected in virgins, infants and children as juvenile laryngeal papillomatosis, it has been acknowledged that HPVs may be transmitted by other, non-sexual, routes as well<sup>8</sup>. Modes of transmission include vertical, autoinoculation and heteroinoculation from warts on the hands and sexual contact. The presence of genital warts in children should always raise suspicion of sexual abuse<sup>9,10</sup>. HPV presence is described in infants that are delivered vaginally<sup>11</sup>. Such perinatal transmission of HPV is usually located at oropharyngeal and genital sites<sup>11</sup>. There is a possibility of ascending infection<sup>11,12</sup>, while there are some reports of condylomata acuminata in children delivered by Caesarean section<sup>13</sup>. Fomites, such as surgical gloves, biopsy forceps and undergarments, may carry HPV DNA, but it is not yet known whether HPV infection can be transmitted by such exposure<sup>14</sup>.

It is believed that transient infection is the most common pattern of HPV infection<sup>4,15</sup>. Sexually active couples frequently but not always harbour similar viruses<sup>16</sup>. In one study, the transmission of HPV between sexual partners was demonstrated by the fact that in 87% of the HPV positive men viral genotypes were identical to those of their consorts and correlated with the degree of cervical lesions<sup>17</sup>. Barraso stated that couples in which both partners present lesions of intraepithelial neoplasia are infected by the same potentially oncogenic HPV genotype in at least 50% of the cases<sup>18</sup>. In a review of 1455 affected women, compiled from the literature, 1019 (70%) of their sexual partners were diagnosed as having been infected with the same viral disease<sup>19</sup>. By contrast, Franceschi et al. conducted a study on the husbands of 445 women with invasive cervical carcinoma, 165 women with *in situ* cervical cancer and 717 control women. In their study, the same HPV genotype was seldom identified in both husband and wife<sup>20</sup>. Rotola et al. concluded that regular male and female sexual partners did not always harbour the same HPV genotypes, showing that latent or occult infection and the sexual habits of each individual play an important role in the clinical manifestations of HPV infection observed in sexual couples<sup>21</sup>.

Men may be a reservoir of the virus, which lives in latent or subclinical form on genital mucous membranes. This asymptomatic infection may be an oncogenic factor in the development of cervical cancer. Sometimes men have clinically evident HPV infections, usually condylomata acuminata. The penile skin hosts HPV frequently, while cancer develops very rarely. However, sometimes men develop penile intraepithelial neoplasia (PIN) lesions. In the study of Campion et al., five of six women with HPV 16 had CIN, whereas their male sexual partners with the same viruses had condylomata acuminata<sup>16</sup>. Baggish noted that 82% of male partners of women

with recurrent condylomata were found to have penile condylomata, mostly subclinical<sup>22</sup>. Levine et al., found penile condylomata in 64% of the male partners of women with cervical dysplasia<sup>23</sup>. About 20–30% of the regular male partners of women with cervical squamous intraepithelial lesions have been shown to present with histologic features of PIN<sup>24,25</sup>.

The persistently lower frequency of clinical and subclinical manifestations in the male partners of women with HPV infection may be due to the greater resistance of male genitalia to the virus, including the oncogenic subtypes<sup>26</sup>.

## Risk Factors

HPV infection is common across all races and socioeconomic groups and is prevalent throughout the world. Immunosuppression is the most important risk factor for the development, progression and recurrences of cervical and anal condylomata and neoplasia. Women who have the highest risk of acquiring an HPV infection are those who commenced sexual activity before the age of 15, had more than four lifetime sexual partners, had more than one »once only« sexual partner, and had chosen male sex partners who had previously had more than 16 other female sex partners<sup>27</sup>. The HPV status and number of lifetime sexual partners were strongly predictive of CIN regression: women with five or fewer lifetime sexual partners had higher rates of regression than women with more than five partners<sup>28</sup>. Other cofactors that may increase the risk are: young age at first delivery; suppression and alteration of immune status; and oral contraceptive use before the age of 15. HPV genital infection is associated with birth control pills because of the more frequent sexual contact without the use of condom, multiple sex partners, and sex at early age. Past and current smokers were at a slightly higher risk compared to non-smokers.

The knowledge of risk factors for genital HPV in men is limited. Most risk factors for HPV detection in men resemble those found in women. According to the study of Svare et al., the most important predictors of any HPV are the lifetime number of sex partners, young age, and being uncircumcised<sup>29</sup>. Circumcised male patients of women with CIN have threefold lower rate of PIN than uncircumcised. They also have a lower prevalence of subclinical disease because these are in most cases localized on the prepuce<sup>24</sup>. Circumcision reduces the likelihood of HPV infection, probably due to the reduction of infection-prone non-cornified epithelium<sup>30</sup>. The male sexual partner is a possible vector of the infection. Therefore, men may represent an important reservoir of virus, and so play an important role in the transmission and perpetuation of the disease. It is estimated that there is a 50% risk of infection after a single sexual contact with an infected partner<sup>31</sup>.

### Clinical Picture

The viral particles can penetrate the skin and mucosal surfaces through microscopic abrasions in the genital area, which occur during sexual activity. Once cells are invaded by HPV, a latency period of months to years may occur.

HPV is known to induce three different manifestations: clinical, subclinical, and latent infection. Clinically evident HPV lesions seem to occur between three weeks and eight months after initial infection, and, although most infections are asymptomatic, usually take years or decades to undergo malignant transformation<sup>32</sup>. Male patients generally present no clinical lesions. Their asymptomatic infection may constitute a HPV reservoir for the female partner. The male sexual partners of women with genital warts as well as those with normal cytology are rarely aware of penile lesions, as most of them remain subclinical or latent for a considerable time<sup>33</sup>. Clinical anogenital lesions are defined as those visible to the naked eye, without any enhancing techniques. HPVs infect specifically the stratified epithelium and are responsible for skin and mucous lesions. Skin papilloma viruses produce benign tumours (warts), which commonly occur on the hands, face and feet. Condylomata acuminata (Figure 1) or anogenital warts are found on the external genitalia, the perineum, perianally and in adjacent areas such as the inguinal fold and the mons pubis. The majority of clinically apparent ano-

genital warts are caused by HPV genotypes 6 or 11 and are only seldom associated with epithelial atypia. The main manifestations of anogenital warts are cauliflower-like condylomata acuminata that usually involve moist surfaces and keratotic and smooth papular warts, usually found on dry surfaces. They are often asymptomatic, but occasionally may cause itching, bleeding after intercourse, urinary obstruction, burning and pain. In men, genital warts are located on the shaft of the penis, base of the penis, scrotum, pubic region, under the prepuce, glans and coronae sulcus, rectal area, while in women they are located in the moist areas of the labia minora and vaginal opening. The size may range from less than one millimetre diameter to several square centimetres when many warts join together. Papular genital warts are smooth, circumscribed, elevated lesions, usually found on dry skin, such as the shaft of the penis in men, the outer parts of the female organs, and the perineum. Keratotic genital warts resemble common warts. They are acquired by autoinoculation or by exposure to the hands of the sexual partner. Bowenoid papulosis are lesions that may clinically resemble genital warts, but histologically are high-grade squamous intraepithelial lesions or squamous cell carcinoma *in situ*<sup>34</sup>. Erythroplasia Queyrat is *in situ* carcinoma of the penile mucosa. It can also be seen on the urethra, vulva, conjunctiva, tongue and oral mucosa. It usually presents as a solitary sharply demarcated, velvety, bright reddish plaque. Buschke-Löwenstein tumour (giant condylomata acuminata) (Figure 2) is a large destructive tumour on the genitalia. It is usually located on the penile glans and prepuce, vulva, vagina and perianal region. It has a tendency to infiltrate deeply and to cause local destruction of the underlying tissues. Oral condylomata (Figure 3) may result from digital or oral-genital sexual transmissions. They appear as small, soft, pink or white, slightly elevated papules and plaques on the buccal, gingival or labial mucosa, the tongue or hard palate.

Recurrent laryngeal papillomatosis (Figure 4) is a rare disease of benign exophytic laryngeal papillomas

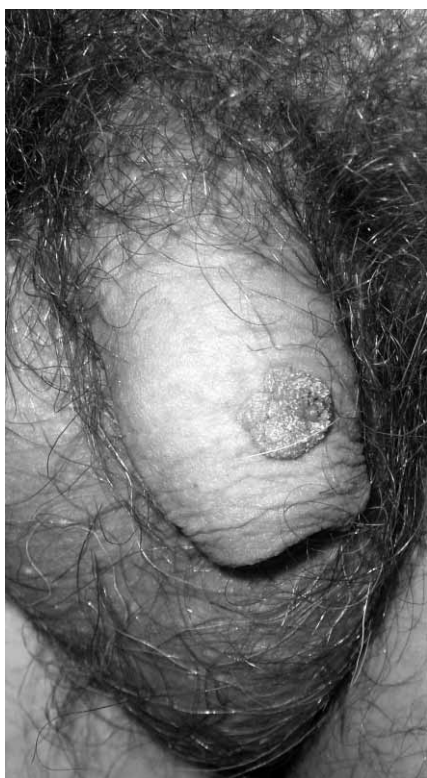

Fig 1. Penile condylomata acuminata.

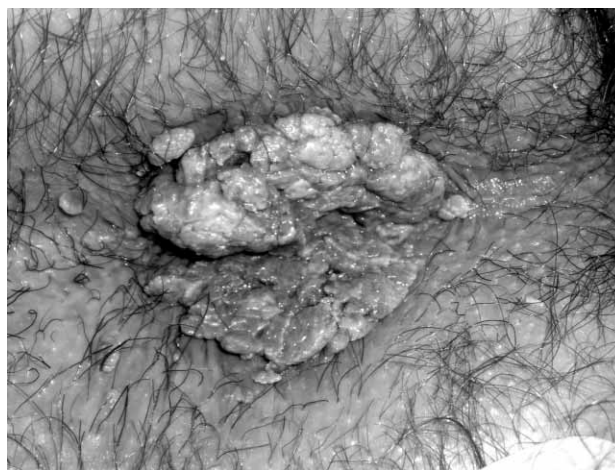


Fig. 2. Giant perianal condylomata acuminata.

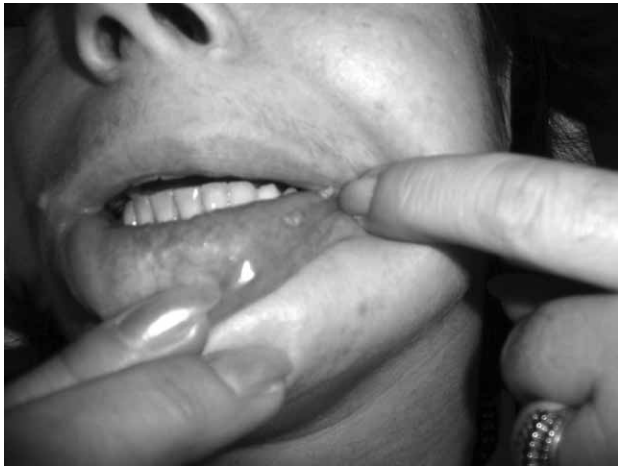

Fig. 3. Oral condylomata acuminata in a patient whose partner had multiple genital warts.

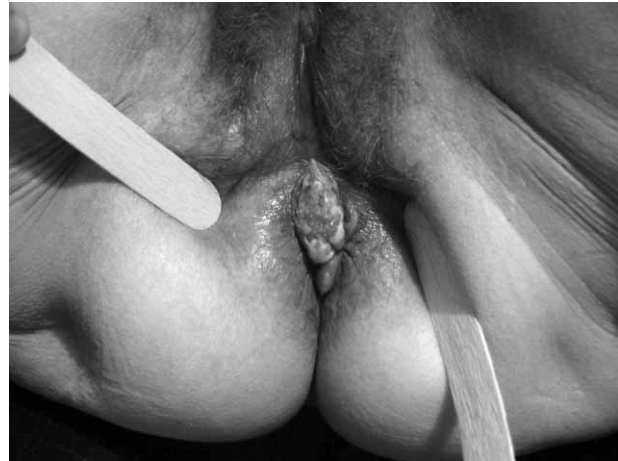

Fig. 5. Squamocellular vulvar carcinoma in a patient with Chron disease with a history of previous HPV cervical infection.

caused by HPV-6 and HPV-11. The typical clinical triad is hoarseness, stridor and respiratory distress. It affects infants and small children as well as adults. Because the tumours grow quickly, young children with the disease may find it difficult to swallow and to breathe when sleeping. Adults with laryngeal papillomatosis may experience hoarseness, chronic coughing and breathing problems. Once they have been removed, these tumours have a tendency to return unpredictably. It is not uncommon for patients to require repeat surgery.

It has been well recognized that HPV infections are frequently associated with genital precancerous lesions, CIN, vaginal intraepithelial neoplasia (VIN), vulvar intraepithelial neoplasia (VaIN), penile intraepithelial neoplasia (PIN), anal intraepithelial neoplasia (AIN) and invasive squamous cell carcinomas (Figure 5).

Condylomata plana or flat warts (Figure 6) are subclinical lesions that are difficult to detect without colposcopy, a specialized technique that involves the application of 3–5% acetic acid for 5–10 minutes. Acetic acid whitens the HPV infected areas, if present on the exam-

ined area. This phenomenon is known as »aceto-whitening«. Subclinical lesions show histological evidence of HPV infection, by the presence of koilocytosis or, less frequently, intraepithelial neoplasia<sup>35</sup>.

Latent infections are defined by the presence of HPV DNA in areas with no clinical or histological evidence of HPV infection. Regardless of their genotype, they are probably the most common form of anogenital HPV infections and they present a »reservoir« of HPV.

## Diagnosis

Although visible anogenital lesions are present in some individuals infected with HPV, the majority do not have a clinically apparent disease. Infection with HPV is often asymptomatic, which makes viral detection challenging. Subclinical lesions are actively infectious, because they show active replication of the HPV virions<sup>36,37</sup>.

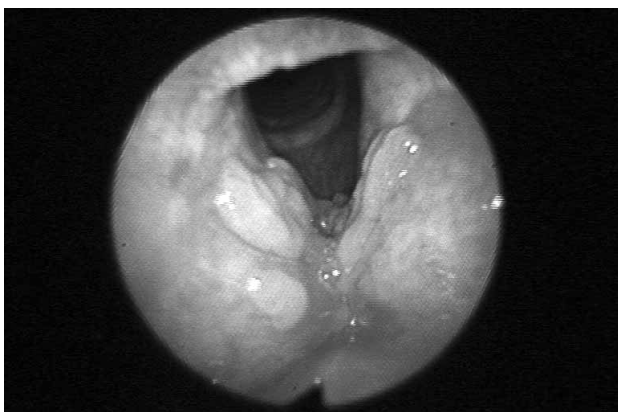

Fig. 4. Laryngeal papillomatosis in a patient whose partner had cervical intraepithelial lesion grade II.

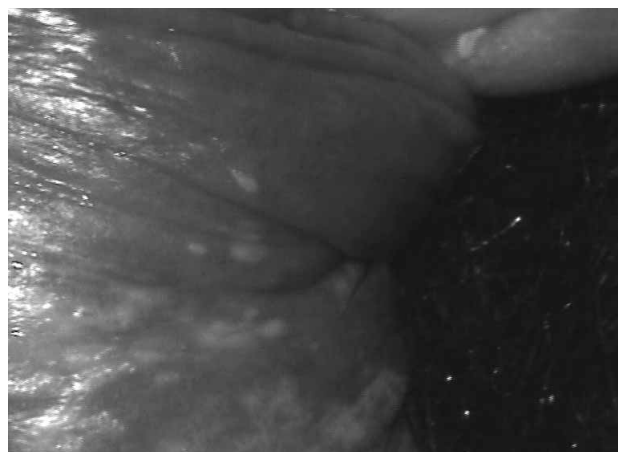

Fig. 6. Multiple condylomata plana (flat warts) lesions in asymptomatic male patient whose female partner had CIN III lesion (view by peniscopy after application of 3% acetic acid).

The infectivity of latent disease is less clear, and no substitutable opinion on this can be offered<sup>35</sup>.

The Papanicolaou test (Pap smear) is the most frequently used method of assessing cytological evidence of HPV infection in women. It is a valuable screening tool, but it misses a large proportion of HPV-infected persons. This test is performed on exfoliated cells, usually from the cervix and vagina, and detects signs of HPV infection such as koilocytic cells and squamous intraepithelial neoplasia.

Conventional viral detection assays, including serologic assays and growth in cell culture, are not available for the diagnosis and tracking of HPV infection.

Several types of HPV DNA tests are now available, including Southern blots, dot blots, *in situ* hybridization, polymerase chain reaction and solution hybridization (Hybrid Capture assay). Of these, the polymerase chain reaction assay is the most sensitive, whereas dot blots and solution hybridization are the least labour-intensive. HPV DNA detection assays have become a key research tool in the detection of HPV infection, particularly in asymptomatic individuals<sup>38,39</sup>.

Examination of the genitalia with colposcopic equipment after application of 5% acetic acid has been claimed to be the most reliable method for the identification of subclinical HPV infection. In 1984, *Levine et al.* were the first investigators to use magnification to examine the penis of the partners of women with condylomata<sup>40</sup>. Since then, the authors writing about this method have used different terms for it: colposcopy of the penis<sup>41</sup>, androscopy<sup>42,43</sup> penis endoscopy<sup>44</sup>, peneoscopy<sup>45</sup>, peoscopy<sup>46</sup> but most of them prefer peniscopy<sup>47,48</sup>.

Examination of the male genitalia is performed with the patient in a lithotomy position on a standard gynaecological table. The patients are recommended not to wash their penis for three days before the exam so that sufficient cellular material can be obtained<sup>49</sup>. Application of 3–5% acetic acid solution to the genital skin followed by magnified examination permits the detection of grossly unapparent flat condylomata accuminata. One half to two thirds of HPV-associated lesions are clinically invisible and detected only after the acetic acid test<sup>18</sup>. The distal urethra may be inspected with a paediatric nasal speculum and anal canal with a proctoscope<sup>47</sup>. The main action of the acid is to coagulate cytoplasmic and nuclear proteins (epithelial cytokeratins, in particular cytokeratin 10) of the epithelial cells and so turn them white<sup>49</sup>. In women it occurs between 10–30 seconds after the application and disappears 30–40 seconds later. In men, the latency time and its effect last longer<sup>47</sup>. In addition to acetic acid, 1% toluidine blue in aqueous solution may be used. The dye has the advantage of a longer-lasting effect, allowing enough time to decide which area to biopsy and to anesthetize it before the lesion disappears<sup>50</sup>. Positive reaction to acetic acid is not specific and not necessarily associated with HPV. The false positive results may be seen especially in inflammatory conditions such as a folliculitis, lichen planus, psoriasis, contact dermatitis, candidiasis, genital herpes, microtraumas from re-

cent intercourse, lichen sclerosus et atrophicus<sup>51–53</sup>. The HPV sample brush may injure glans and prepuce epithelium, as well as the urethral mucosa, possibly leading to false-positive peniscopy findings<sup>47</sup>. Usually patients who have false positive results complain of burning and itching sensations few minutes after applying acetic acid, but these symptoms resolve once the skin is washed in plain water<sup>54</sup>.

Peniscopic lesions may be classified as flat (at skin level), papular (raised slightly above the surface in circumscript area), papillary (obvious protrusion above the surface, forming papillary growth or papilloma), and classic condylomata (grossly recognizable protuberance with finely pointed epithelial excrescences)<sup>36</sup>. Peniscopy is not a conclusive diagnostic tool capable of differentiating HPV from non-HPV finding.

Majority of HPV lesions are located on the meatus and in the immediately contiguous distal urethra (navicular fossa). The cytologic evaluation of smears from the external skin of the penis and scrotum was unsatisfactory because cells representing the deeper layers were too rare to allow a definitive diagnosis<sup>36</sup>. *Cecchini et al.* performed a cytologic examination of urethral smears with a cytobrush in 53 male partners of women with cervical HPV infection and in 14 healthy controls<sup>55</sup>. In their study, cytology was positive in 26 cases (49%) and no controls were positive by the cytology.

The urethra cannot be completely appraised with regard to HPV infections on the basis of its external appearance without endoscopy. Urethroscopy is recommended in all cases of externally visible condylomata of the urethra after therapy. Acetic acid cannot be applied in urethra, which presents a further diagnostic problem. *Schneede et al.*, used 5-aminolevulinic acid (ALA)-induced fluorescence endoscopy<sup>56</sup>.

In rare cases, HPV has been detected, using molecular techniques, along the urinary tract in transitional cell neoplasms without microscopic signs of koilocytic atypia. When affecting the urethra, condylomata are usually limited to its third distal portion. However, transitional cell neoplasms of the urethra are exceptional and in most of the cases remain limited to its proximal portion<sup>57–59</sup>. Cancer of the urethra is relatively rare and shows a clear predilection for female sex (4:1)<sup>57</sup>.

The determination of HPV DNA by laboratory tests and cytological detection of koilocytes in the urine and ejaculate<sup>60</sup> of men without detectable urethral condylomata indicate that subclinical and latent HPV infections must also exist in urethra<sup>61</sup>. However, routine cytological examination of urine specimens for koilocytes has a very low yield<sup>36</sup>.

Biopsy is mandatory to confirm the histopathological presence of HPV infection with acetowhite (subclinical) lesions<sup>62,63</sup>. Histological characteristic of condylomata comprise: acanthosis with broadening and elongation of rete ridges, large atypical convoluted nuclei with perinuclear vesicles (koilocytolitic atypia) presence of parakeratosis and hyperkeratosis.

## Treatment

The traditional goals of the treatment of sexually transmitted diseases are eradication of the infection, elimination of the symptoms, prevention of long-term consequences, and interruption of transmission. Current therapies do not reliably eradicate HPV infection, so benign genital warts and genital tract intraepithelial neoplasms often recur after treatment. Recurrence may be attributed to the re-infection from a sexual partner, long incubation time of HPV and persistence of the virus in the surrounding skin. Because of that, the asymptomatic nature and invisibility of plane epithelial lesions pose a problem in the detection and management. Genital warts are highly infectious and sexual partners may well already be infected when the patient presents for treatment. The treatment of genital warts remains frustrating since it is often painful, expensive and unsuccessful. Genital warts may disappear on their own in about 10–20% of people over a period of 3–4 months. Regardless of the treatment, 30–67% recurrence rates occur, so a regular clinical follow up after treatment is necessary to prevent recurrences and the development of neoplasia<sup>64,65</sup>. It is known that after treatment of clinical disease or with natural regression, about 45% of patients retain latent infection<sup>64</sup>.

Treatments focus on the removal of exophytic warts, leaving the surrounding subclinical and latent HPV infection as areas of possible transmission and recurrence. Effective treatment does reduce HPV viral load, so the infection is reduced if not completely eradicated<sup>66</sup>.

The following HPV infection treatments are available: podofilox, podophyllin, imiquimod, cryotherapy, topical 5-fluorouracil (5-FU), trichloroacetic acid (TCA), intralesional interferon, curettage, electrosurgery, classic and laser surgery.

Cryotherapy with liquid nitrogen is the safest and effective therapy for most forms of condylomata acuminata. Tissue freezing results in membrane rupture and intracellular dehydration, which causes cell death<sup>67</sup>. Warts on the shaft and vulva respond very well to cryotherapy, but when applied on the rectum it is painful and less successful. Cryotherapy is also a safe mode of treatment in pregnancy. Local anaesthetic creams may provide effective topical anaesthesia before cryotherapy for the treatment of external genital HPV<sup>68,69</sup>. When cryotherapy is used weekly, clearance rates of up to 90% may be achieved, with recurrence rates of up to 40%<sup>70</sup>. Podophyllin is one of the oldest remedies for genital warts. It is an alcoholic extract of the podophyllum emodi or podophyllum peltatum plant resins. Application of podophyllin to genital warts leads to inflammatory reaction, histologically demonstrated as keratinocyte necrosis and abnormal mitoses<sup>67</sup>. According to some experts, podophyllin is no longer recommended because of its low efficacy and potential toxicity<sup>53</sup>. The most biologically active component is podophylotoxin, otherwise known as podofilox. Podofilox is a topical antimetabolic that causes necrosis of visible wart tissue. Clearance rates with podof-

filox vary widely, from 45% to 88%<sup>70,71</sup>. Recurrence of warts is common, and long-term clearance rates range from 30% to 60%<sup>70,71</sup>. TCA is a caustic agent used for the superficial destruction of skin lesions by causing immediate superficial tissue necrosis. This therapy is non-toxic and may be used in the treatment of children and pregnant women when other regimens are contraindicated. Godley et al found 81% response rate, but the subsequent relapse rate was 35%, giving an overall response rate approximately 50%<sup>72</sup>. 5-FU is an antimetabolite that inhibits cell growth by interfering with DNA and RNA synthesis. A complete response rate of 61% was seen, with the three-month recurrence rate of 39%<sup>73</sup>. Imiquimod, a topical immunotherapeutic agent that induces interferon and other cytokines has the potential to be a first-line therapy for genital warts. Imiquimod does not act directly against viruses, but it does have antiviral and antitumour properties, attributed to its capacity to induce the production of pro-inflammatory cytokines. This treatment is different from all other recommended therapies for condylomata because it does not rely on the physical destruction of the lesion, but is directed at eradication of the causative agent, HPV<sup>74</sup>. Clearance of external warts with imiquimod therapy occurs in 72%–84%<sup>71</sup>. Clearance rates and partial responses in females are higher than in males. HPV recurrence rate with imiquimod are 5–19%<sup>71</sup>. Interferon has antiproliferative effect against marginal cells and it modulates the host immune response. It enhances the activity of immune cells. Bleomycin applied inside the lesion has a chemotherapeutic effect: it binds DNA and disrupts its function<sup>67</sup>. Intralesional interferon is only considered for recurrent or refractory lesions. Clearance of warts after application of intralesional interferon has ranged from 19% to 62%<sup>75</sup>. The systemic and local use of interferon has been shown unsuccessful<sup>71</sup>. Electrosurgery is quite effective for a limited number of genital lesions. It is easy to perform, well tolerated by most of the patients and the wounds heal rapidly. Long-term clearance rates are about 70%<sup>71</sup>. Surgery is indicated for large genital warts. The overall impression is of high initial cure rates and acceptably low recurrence rates<sup>67</sup>. Buske-Löwensten tumour is treated by wide excision with clear resection margins. Alternatively, the warts may be removed either by tangential excision with a pair of fine scissors or a scalpel, or by curettage. Carbon-dioxide laser is an efficient but expensive method of treating primary and recurrent anogenital warts because of its precision and rapid healing without scarring. Clearance rates are approximately 87%, and, as with electrocautery, recurrence occurs in up to 50% patients<sup>76</sup>. Carbon-dioxide laser and surgery might be useful in the management of extensive warts or intraurethral warts, particularly for those patients who have not responded to other treatments.

Wiltz et al. propose that surgical excision follow by vaccination with autogenous condylomata acuminata vaccine<sup>77</sup>. They conclude that excision of perianal condylomata acuminata, followed by autogenous condylomata acuminata vaccination for approximately ten weeks, is

the most effective and definitive treatment option. Moreover, it should be considered in all patients with perianal condylomata acuminata<sup>77</sup>.

Recurrence of condylomata acuminata is common with all presently used forms of therapy, probably owing to subclinical and latent HPV infection in normal-appearing skin. There is no ideal therapeutical procedure for all forms of HPV infection, but without continued efforts to find better therapeutic modalities and preventative measures, the epidemic of genital HPV infection will continue to spread. Most untreated genital tract lesions eventually resolve spontaneously, but latent or subclinical infection may persist indefinitely<sup>14</sup>. No therapeutic modality appears superior for the treatment of latent disease.

### Prognosis and Prevention

The long term consequences of the sexual transmission diseases are more serious in women than in men. Genital HPV is associated with cervical dysplasia and it can be important in the cervical cancer development.

Penile lesions are frequently found in the sexual partners of women with CIN<sup>78</sup>. Most of these lesions are subclinical and are often associated with the presence of high-risk HPV, indicating that male sexual partners of women with CIN might constitute a reservoir for high-risk HPV<sup>78</sup>.

Median duration of HPV infection is 8 months<sup>79,80</sup>. Persistence of HPV infection is reported in 30% of patients after one year. After 24 months, only 9% of the women studied continued to be infected<sup>79,80</sup>. This provides the possibility to reassure patients with HPV infection that it is most likely a transient infection over which one should not worry unduly. It has been reported that between 21% and 69% of the subclinical infections remain untreated. This may result in dysplastic changes as well as transmission of the virus to the partner<sup>81</sup>.

Although condoms most likely prevent HIV infection, evidence of their effectiveness against other sexually transmitted diseases is mixed<sup>82</sup>. 27 estimates from 20 studies have shown no consistent evidence that condom use reduces the risk of becoming HPV DNA-positive. However, risk for genital warts, CIN II and III, as well as invasive cervical cancer was somewhat reduced<sup>78,82</sup>.

The prevalence of human papillomavirus DNA in penile carcinoma is about 40–45%, which is similar to the detection rate of HPV-DNA in vulvar carcinoma (50%)<sup>83</sup>. It is unclear how high-risk HPV genotypes cause cancer. Only a low proportion of HPV infections result in cervical cancer from the precursor (CIN) lesion<sup>4, 84</sup>. The vast majority of those infected do not develop malignancies, indicating that HPV infection alone is not enough to cause cancer<sup>4,84</sup>.

There are two prophylactic HPV vaccines: the quadrivalent and bivalent vaccine<sup>85, 86</sup>. The quadrivalent vaccine consists of recombinant virus-like particles (VLPs) of HPV -6, -11, -16, -18 mixed with an aluminium-containing adjuvant and bivalent consists of HPV -16 and

18. Vaccine is approved for use in women of 9–26 years of age. The primary target population for vaccination should be 11–12 year old females, although girls as young as 9 as well as those aged between 13 and 26 years, who have been sexually active, may be vaccinated as well.

Both vaccines have been shown to prevent more than 90% of precancerous lesions associated with types 16 or 18 among HPV-naive women<sup>85–87</sup>. The vaccines are given in three doses over a six-month period. Evaluation of HPV vaccines efficiency using prevention of dysplasia and cancer was recommended as the globally accepted endpoint for population based studies. Hughes *et al*<sup>88</sup> found that vaccinating both men and women against a specific HPV type would result in a 44% decrease in the prevalence of that type, whereas vaccinating only women would result in 30% reduction. They have also found that if a vaccine protects against some but not all high-risk types of HPV, the reduction in disease may be less than the reduction in HPV because the remaining high-risk HPV types may replace the disease caused by the eliminated types<sup>88</sup>.

A total of 12,167 women aged 16–26 were vaccinated with either the quadrivalent vaccine or a placebo<sup>89</sup>. The vaccine efficacy against HPV 16/18 related CIN 2/3 and adenocarcinoma in situ was 44%<sup>87, 89</sup>. Out of the 12,167 vaccinated women, 5305 had no evidence of past or present infections with HPV 16/18, and the quadrivalent vaccine was found to be 98% effective at preventing high-grade cervical precancerous lesions related to HPV 16/18 after an average follow-up of three years<sup>89</sup>. The estimated vaccine efficacy against all high-grade cervical lesions, regardless of the causal HPV type, in this intention-to-treat population was 17%<sup>89</sup>. Interim results of the phase III trials of the bivalent vaccine involving 18,644 women aged 15–25 demonstrated a vaccine efficacy of 90.4% against CIN 2/3 lesions containing HPV 16/18 DNA in women who were seronegative and DNA-negative for the vaccine HPV types at day 0 of the trial<sup>90</sup>. The bivalent vaccine also demonstrated an efficacy of between 21.9% and 38.2% against cervical infections of any oncogenic HPV type persisting for six and 12 months respectively.

This prophylactic vaccine, made from non-infectious HPV-like particles, offers a promising new approach to the prevention of HPV and associated conditions. However, this vaccine will not replace other prevention strategies since it will not work for all genital HPV types. A stable sexual relationship and consistent use of condoms in polygamous sexual practices is probably the most meaningful means of controlling the sexual transmission of HPV.

### Conclusion

Treatment for genital warts remains unsatisfactory, there is no cure for HPV infections and recurrences are common. The future therapies should lead to the destruction and complete clearance of visible lesions, as well as to the prevention of recurrences. Ideally HPV should be eliminated completely from the treated tissue.

In a few years time, vaccine may influence the treatment and prophylaxis of cervical carcinomas, which are among the most common cancers that affect women worldwide. Attention must be paid to control and early diagnosis to

prevent neoplastic evolution. Screening and treatment of male partners are mandatory for cervical carcinoma prevention.

## REFERENCES

1. PINTO PA, MELLINGER BC, *Urol Clin North Am*, 26 (1999) 797. — 2. MOSCICKI AB, *Adv Pediatr*, 39 (1992) 257. — 3. CHESEBRO MJ, EVERETT WD, LORINCZ A, *J Lower Genital Tract Dis*, 1 (1997) 234. — 4. HELEY S, *Aust Fam Physician*, 32 (2003) 311. — 5. DALING JR, SHERMAN KJ, WEISS NS, *Sex Transm Dis*, 13 (1986) 16. — 6. RYMARK O, FORSLUND O, HANSSON BG, LINDHOLM K, *Genitourin Med*, 69 (1993) 18. — 7. SCHNEIDER A, *Genitourin Med*, 69 (1993) 165. — 8. CZEGLÉDY J, *Acta Microbiol Immunol Hung*, 48 (2001) 511. — 9. OBALEK S, JABLONSKA S, FAVRE M, WALCZAK L, ORTH G, *J Am Acad Dermatol*, 23 (1990) 205. — 10. GUTMAN LT, HERMAN-GIDDENS M, PROSE NS, *Am J Dis Child*, 145 (1991) 126. — 11. TSENG CJ, LIANG CC, SOONG YK, PAO CC, *Obstet Gynecol*, 91 (1998) 92. — 12. SEDLACEK TV, LINDHEIM S, EDER C, HASTY L, WOODLAND M, LUDOMIRSKY A, RANDO RF, *Am J Obstet Gynecol*, 161 (1989) 55. — 13. ALLEN AL, SIEGFRIED EC, *J Am Acad Dermatol*, 39 (1998) 951. — 14. FERENCZY A, *Am J Obstet Gynecol*, 172 (1995) 1331. — 15. WILKSTÖM A, POPESCU C, FORSLUND O, *Int J STD AIDS*, 11 (2000) 80. — 16. CAMPION MJ, SINGER A, CLARKSON PK, MC CANCE DJ, *Lancet*, 27 (1985) 943. — 17. SCHNEIDER A, KIRCHMAYER R, DE VILLIERS EM, GISSMANN L, *J Urol*, 140 (1988) 1431. — 18. BARRASSO R, *IARC Sci Publ*, 119 (1992) 85. — 19. HAYMAN R, SHULMAN A, MAYMAN B, BECKERMAN A, WERCHOW M, FAKTOR JH, ALTARAS M, *Obstet Gynecol Surv*, 49 (1994) 790. — 20. FRANCESCHI S, CASTELLSAGUE X, DAL MASO L, SMITH JS, PLUMMER M, NGELNGEL C, CHICHICHAREON S, ELUFNETO J, SHAH KV, SNIJDERS PS, MELJER CJ, BOSCH FX, MUNOZ N, *Br J Cancer*, 86 (2002) 705. — 21. ROTOLA A, COSTA S, MONINI P, VENDRA C, GUIDA G, TERZANO P, DI LUCA D, MARTINELLI G, CASSAI E, *Eur J Epidemiol*, 10 (1994) 373. — 22. BAGGISH MS, *J Reprod Med*, 27 (1982) 137. — 23. LEVINE RU, CRUM CP, HERMAN E, SILVERS D, FERENCY A, RICHARDT M, *Obstet Gynecol*, 64 (1984) 16. — 24. BARRASSO R, DE BRUX J, CROISSANT O, ORTH G, *N Engl J Med*, 317 (1997) 916. — 25. ZANARDI C, GUERRA B, MARTINELLI G, *Cervix*, 6 (1988) 127. — 26. KOKELJ F, BARAGGINO E, STINCO G, WIESENFELD U, *Int J Dermatol*, 32 (1993) 661. — 27. KENNEY JW, *Cancer Nurs*, 19 (1996) 353. — 28. CHAN JK, MONK BJ, BREWER C, KEEFE KA, OSANN K, MCMEEKIN S, ROSE GS, YOUSSEF M, WILCZYNSKI SP, MEYSKENS FL, BERMAN ML, *Br J Cancer*, 15 (2003) 1062. — 29. SVARE EI, KJAER SK, WORM AM, OSTERLIND A, MEIJER CJ, VAN DEN BRULE AJ, *Sex Transm Infect*, 78 (2002) 215. — 30. SCHIFFMAN M, CASTLE PE, *Arch Path Lab Med*, 127 (2003) 930. — 31. ORIEL JD, *Br J Vener Dis*, 47 (1971) 1. — 32. SANCLEMENTE G, GIL DK, *J EADV* 16 (2002) 231. — 33. STONE K, *Clinic Obstet Gynecol*, 32 (1989) 112. — 34. SCHWARTZ RA, JANNIGER CK, *J Am Acad Dermatol*, 24 (1991) 261. — 35. LING MR, *Int J Dermatol*, 31 (1992) 682. — 36. KREBS HB, SCHNEIDER V, *Obstet Gynecol*, 70 (1987) 299. — 37. FERENCZY A, BRAUN L, SHA KV, *Am J Surg Pathol*, 5 (1981) 662. — 38. KOUTSKY L, *Am J Med* 102 (1997) 3. — 39. TROFATTER KF JR, *Am J Med*, 102 (1997) 21. — 40. LEVINE RV, CRUM CP, HERMAN E, SILVER D, FERENCZY A, RICHARD RM, *Obstet Gynecol*, 64 (1984) 19. — 41. BARRASSO R, GUILLEMOTONIA A, CATALAN F, COUPEZ F, SIBOULET A, *Ann Dermatol Venereol*, 113 (1986) 787. — 42. EPPERSON WJ, *J Fam Pract*, 33 (1991) 143. — 43. PFENNINGER JL, *J Fam Pract*, 29 (1989) 286. — 44. AYNAUD O, IONESCO M, BARRASSO R, *Ann Urol (Paris)* [in French], 26 (1992) 53. — 45. LLOPIS CARTAGENA M, ALGADO MARTINEZ H, SANCHEZ MARCOS M, MORENO BARRAGAN HJ, *Arch. Esp Urol* [in Spanish], 49 (1996) 112. — 46. KOTOULAS IG, CARDAMAKIS E, RELAKIS K, DIAMANTIS A, PAPATHANASIOU Z, KORANTZIS A, MANTOUVALOS C, *Gynecol Obstet Invest*, 41 (1996) 55. — 47. NICOLAU SM, MARTINS NV, FERRAZ PE, STAVALE JN, GONCALVES WJ, BARACAT EC, DE LIMA GR, *Rev Paul Med*, 115 (1997) 1330. — 48. HIPPELÄINEN M, YLISKOSKI M, SAARIKOSKI S, SYRJÄNEN S, SYRJÄNEN K, *Genitourin Med*, 67 (1991) 291. — 49.

MADDOX P, SZAREWSKI A, DYSON J, CUZICK J, *J Clin Pathol*, 47 (1994) 15. — 50. NICOLAU SM, STAVALE JN, LIMA GR, RIBALTA JCL, FERRAZ PE, In: *Congres Brasileiro de Ginecologia e astencia*, 44, Brasilia [in Portuguese], 1991. *Anais Brasilia 1991* (TL 383). — 51. GRIF-FITHS M, PENNA LK, TOVEY SJ, *Int J STD AIDS*, 2 (1991) 211. — 52. SIEGEL JF, MELLINGER BC, *Urol Clin North Am*, 19 (1992) 87. — 53. VON KROGH G., LACEY CJ, GROSS G, BARRASSO R, SCHNEIDER A, *Sex Transm Infect*, 76 (2000) 162. — 54. SCHULTZ RE, SKELTON HG, *J Urol*, 139 (1988) 777. — 55. CECCHINI S, CIPPARRONE I, CONFORTINI M, SCUDERI A, MEINI L, PIAZZESI G, *Acta Cytol*, 32 (1998) 314. — 56. SCHNEEDEE P, MÜNCH P, WAGNER S, MEYER T, STALFLETH E, HAFSTETTERT A, *J EADV* 21 (2001) 121. — 57. SCHNEEDE P M M W *Fortschr Med* [in German], 145 (2003) 36. — 58. RODRIGUEZ-PINILLA SM, RODRIGUEZ-PERALTO JL, FERNANDEZ-FIGUERAS MT, *Virchows Arch*, 442 (2003) 601. — 59. WIENER JS, LIN, WALTHER PJ, *Cancer Res*, 52 (1992) 5018. — 60. KYO S, INOKE M, KOYAMA A, FUJITA M, TANIZAWA O, HAKURA A, *J Infect Dis*, 70 (1994) 682. — 61. ROSEMBERG SK, HUSAIN M, HERMAN GE, ELFONT EA, *Urology*, 36 (1990) 38. — 62. SCHULTZ RE, MILLER JW, MC DONALD GR, *J Urol*, 143 (1990) 920. — 63. KUMAR B, GUPTA S, *J EADV*, 15 (2001) 27. — 64. FERENCZY A, MITAO M, NAGAI N, SILVERSTEIN SJ, CRUM CP, *N Engl J Med*, 313 (1985) 784. — 65. LAURENT R, *Rev Prat* [in French], 46 (1996) 1961. — 66. WILSON J, *Int J STD AIDS*, 13 (2002) 216. — 67. LING MR, *Int J Dermatol*, 11 (1992) 769. — 68. MANSELL-GREGORY M, ROMANOWSKI B, *Sex Transm Infect*, 74 (1998) 174. — 69. FREGA A, DI RENZI F, PALAZZETTI PL, PACE S, FIGLIOLINI M, STENTELLA P, *Clin Exp Obstet Gynecol*, 20 (1993) 76. — 70. MAW RD, *Dermatol Clin*, 16 (1998) 829. — 71. GUNTER J, *Am J Obstet Gynecol*, 189 (2003) S3. — 72. GODLEY M, BRADBEER C, GELLAN M, THIN RN, *Genitourin Med*, 63 (1987) 390. — 73. BEUTNER KR, FERENCZY A, *Am J Med*, 102 (1997) 28. — 74. BROWN JT, YEN-MOORE A, TYRING SK, *J Am Acad Dermatol*, 41 (1999) 661. — 75. BROWDER JF, ARAUJO OE, MYER NA, FLOWERS F, *Ann Pharmacother*, 26 (1992) 42. — 76. SAVOCA S, NARDO LG, ROSANO TF, D'AGOSTA S, NARDO F, *Acta Obstet Gynecol Scand*, 80 (2001) 1121. — 77. WILTZ OH, TORREGROSA M, WILTZ O, *Dis Colon Rectum*, 38 (1995) 838. — 78. BLEEKER MCG, HOGEWONING CJA, VAN DEN BRULE AJC, VOORHORST FJ, VAN ANDEL RE, RISSE EK, STARINK TM, MELJER CJK, *J Am Acad Dermatol*, 47 (2002) 351. — 79. STRAND A, RYLANDER E, *Dermatol Clin*, 16 (1998) 817. — 80. DE VILLIERS EM, *Clin Dermatol*, 15 (1997) 199. — 81. LEY C, BAUER HM, REINGOLG A, SCHIFFMAN MH, CHAMBERS JS, TASHIRO CJ, MANOS MM, *J Natl Cancer Inst*, 83 (1991) 997. — 82. MANHART LE, KOUTSKY LA, *Sex Transm Dis*, 29 (2002) 725. — 83. GROSS G, PFISTER H, *Med Microbiol Immunol*, 193 (2004) 35. — 84. BEUTNER KR, TYRING S, *Am J Med*, 102 (1997) 9. — 85. Gardasil package insert. Released June 2006. Available from <http://www.fda.gov/cber/label/hpvmer060806LB.htm>, accessed September 5, 2006. — 86. HARPER DM, FRANCO EL, WHEELER CM, MOSCICKI AB, ROMANOWSKI B, ROTEL-MARTINS CM, JENKINS D, SCHUIND A, COSTA CLEMENS SA, DUBIN G; HPV Vaccine Study group, *Lancet*, 367 (2006) 1247. — 87. Guidelines for the introduction of HPV vaccines in EU countries. Available from: [http://ecdc.europa.eu/pdf/HPV\\_report.pdf](http://ecdc.europa.eu/pdf/HPV_report.pdf), accessed April 15, 2008. — 88. HUGHES JP, GARNETT GP, KOUTSKY L, *Epidemiology*, 13 (2002) 622. — 89. FUTURE II STUDY GROUP, *N Eng J Med*, 356 (2007) 1915. — 90. PAAVONEN J, JENKINS D, BOSCH FX, NAUD P, SALMERÓN J, WHEELER CM, CHOW SN, APTER DL, KITCHENER HC, CASTELLSAGUE X, DE CARVALHO NS, SKINNER SR, HARPER DM, HEDRICK JA, JAISAMRAN U, LIMSON GA, DIONNE M, QUINT W, SPIESSENS B, PEETERS P, STRUYF F, WIETING SL, LEHTINEN MO, DUBIN G; HPV PATRICIA STUDY GROUP, *Lancet*, 369 (2007) 2161.



*S. Ljubojević*

*University Department of Dermatology and Venereology, University Hospital Centre »Zagreb«, School of Medicine,  
10000 Zagreb, Salata 4, Croatia  
e-mail: [suzana.ljubojevic@zg.t-com.hr](mailto:suzana.ljubojevic@zg.t-com.hr)*

## **GENITALNE INFEKCIJE POVEZANE S HUMANIM PAPILOMA VIRUSOM**

### **S A Ž E T A K**

Genitalne human papillomavirus (HPV) infekcije pripadaju među najčešće spolno prenosive bolesti. HPV je povezan s brojnim bolestima među koje se ubrajaju vulgarne veruke, akuminirani kondilomi, maligni karcinoma cerviksa, vulve, anusa i penisa. Genitalne HPV infekcije se najčešće prenose spolnim putem, ali mogući su i ostali načini prenošenja poput perinatalnog prenošenja te autoinokulacije. Muškarci su mogući rezervoar virusa koji se obično nalazi na genitalnim sluznicama u latentnom ili subkliničkom obliku. Takve asimptomatske infekcije mogu biti onkogeni faktor u razvoju cervikalnog karcinoma. Kolposkopsko gledanje genitalija nakon aplikacije 3–5% octene kiseline je pouzdana metoda za otkrivanje subkliničke HPV infekcije. Uspješnost terapije anogenitalnih bradavica karakterizirana je njihovim potpunim nestankom te izostankom recidiva. Terapije koje se sada primjenjuju ne eradiciraju HPV infekciju. Dijagnoza i liječenje HPV infekcije u muškaraca je od potencijalne koristi jer iradikacija HPV-a na penisu može smanjiti rezervoar virusa.