

BRANKO PLAVŠIĆ\*,  
IVAN MIRNIK\*\*,  
ANTE RENDIĆ-MIOČEVIĆ\*\*\*,  
MARVIN S. KOGUTT\*\*\*\*

## X-RAY ANALYSIS OF THREE EGYPTIAN MUMMIES

Original Scientific Paper  
UDC 616-073:393.3(32)

*Conventional radiographs of three Egyptian mummies were analyzed. Defects in the bony crania intentionally done by the embalmers may give a clue on how the brain was removed. All three mummies had a single metallic spheric object within their cranial vault. These findings may have religious or cultural significance. Nothing of particular medical significance that would suggest pathological changes of the skeleton was found.*

### Introduction

Egyptian mummies have been the subject of radiographic research since the discovery of X-rays in 1895<sup>1</sup>. Standard X-ray techniques and computed tomography are currently used to noninvasively explore the inner structures of mummies. Radiopaque objects on the surface, inside the bodies or within the wrappings of the mummy can be readily detected. Studying the skeleton enables the determination of sex as well as skeletal diseases of the deceased. Fractures, inflammations, tumors and conditions such as bony infarcts or osteogenesis imperfecta may be detected<sup>2</sup>. Comparative studies of historical documents and X-ray analysis of the mummies may contribute to better understanding of mummification techniques for given historical periods<sup>3</sup>.

ACKNOWLEDGEMENT. The authors appreciate the excellent technical assistance of Donald D. Olivares, Stjepan Iveković and Branka Stojanovski.

\* Branko Plavšić MD, PhD, Professor & Vice-Chairman, Department of Radiology Tulane University SL 54 School of Medicine, 1430 Tulane Avenue, New Orleans LA, 70112 USA.

\*\* Ivan Mirnik, Arheološki muzej u Zagrebu, Trg Nikole Šubića Zrinskog 19, 10000 Zagreb, Croatia.

\*\*\* Ante Rendić-Miočević, Arheološki muzej u Zagrebu, Trg Nikole Šubića Zrinskog 19, 10000 Zagreb, Croatia.

\*\*\*\* Marvin S. Kogutt MD, Professor & Chairman, Department of Radiology Tulane University SL 54 School of Medicine, 1430 Tulane Avenue, New Orleans LA, 70112 USA

1. König, W. 14 Photographien mit Röntgen-Strahlen, aufgenommen im Physikalischen Verein, Frankfurt a.M. Leipzig: 1896: JA. Barth; Vanlathem, M.-P. Tachtigjaar rontgenonderzoek van oudegyptische mummies. *Phoenix* 26/1980, i: 47-63.

2. Gray, P.H.K. A case of osteogenesis imperfecta, associated with dentinogenesis imperfecta, dating from antiquity. *Clin Radiol*, 20/1969; 106; Thompson P, Lynch P.G. - Tapp, E. Neuropathological studies on the Manchester mummies. David, R.A. ed. *Science in Egyptology*, Manchester 1986: 376-378.

3. Pickering, R.B. - Conces, D.J. - Braunstein E.M. - Yurco F. Three-dimensional computed tomography of the mummy Wenuhotep. *Am J Physical Anthropol*, 83/1990: 49.

## Materials and methods

Conventional radiographs of three Egyptian mummies from the Archaeological Museum in Zagreb were obtained in the Institute of Radiology of the University Hospital Rebro, Zagreb, Croatia, in 1987. Three to five exposures were taken to accommodate the length of the particular mummy. The radiographs were then photographed. The photographs were scanned by a flat bed scanner, UMAX (300 dots per inch resolution), to equalize the dimensions of the X-rayed segments of each mummy. Using a slide maker, positive images were made and used to produce negatives and laser prints.

The names of the mummies are inscribed in hieroglyphics on the sarcophagi and are as follows: Kareset, Shepenun and Kaipamaw.

In order to determine the sex of the mummies, due to some controversy, the pelvic radiograph of Kareset was analyzed by fourteen radiologists from the Department of Radiology Tulane University Medical Center in New Orleans, USA.

## Results

Analysis of conventional radiographs of the mummies showed the following results.

Study of the mummies was adversely affected by the superposition of radiopaque resins and natron salts on both the surface and within body cavities. However, bones that could be analyzed had skeletal mineralization and detail comparable with those from a living person.

### Kareset

The mummy was placed in two polychrome wooden anthropomorphic sarcophagi inscribed with hieroglyphics and the mummified body tightly enfolded with linen wrappings<sup>4</sup>. The configuration of the pelvis is not quite typical of either female or male sex (Pl. 1B). Eight of fourteen radiologists who analyzed the radiographs of pelvic bones felt the mummy was a female. The proximal portions of the calves are not included in the picture, which results in apparent shortening of the legs. The hands are crossed over the chest with palms overlaying the opposite shoulders. There is a large defect involving the frontal and right parietal bones of the skull. Popcorn like radiopaque material is seen within the neurocranium (Pl. 4A). The quantity of radiopaque material within both the thorax and the abdomen is relatively sparse. The muscles and subcutaneous tissues of the thighs and to a lesser extent of the calves, are encrusted with opaque material. A single rounded metallic object, 2mm in diameter, is seen projecting in the region of the occipital bone. (Pl. 4A).

### Shepenun

A well preserved mummy was set in a triple polychrome wooden anthropomorphic coffin<sup>5</sup>. The shape of the pelvis indicated a female. The skeleton is well preserved. The hands overlay the femurs (Pl. 2B). A rounded metallic object approximately 3mm in diameter is seen projecting over the upper portion of the skull (Pl. 4B). The lower portion of the neurocranium is filled with radiopaque matter. Both the thorax and the abdomen, particularly the left side, are also densely packed with radiopaque material.

4.538:ZAG EG668; length of the enwrapped mummy: 160cm; Ljubić Š. *Popis Arheološkoga odjela Nar.Zem.muzeja u Zagrebu*. Zagreb, 1889: 20, No.4; Monnet Saleh J. *Les antiquités égyptiennes de Zagreb*. Paris-La Haye, 1970:181, No.898.

5.538:ZAG EG667; length of the enwrapped mummy: 163cm; Ljubić Š. *Popis Arheološkoga odjela Nar.Zem.muzeja u Zagrebu*. Zagreb, 1889: 19-20, No.3; Monnet Saleh J. *Les antiquités égyptiennes de Zagreb*. Paris-La Haye, 1970:181, No.897.

### Kaipamavv

The mummy was X-rayed in the original painted cartonnage, which belonged to an adequate painted anthropomorphic wooden coffin<sup>6</sup>. The pelvis is of a female. The upper arms rest parallel to the thorax with the forearms and hands converging toward the midline. A large mass of very radiopaque material is present within the thorax and abdominal cavity (Pl. 3B). A 2mm metallic foreign body is seen in the left neurocranium. The cranial vault is free of other foreign radiopaque materials. No defects of the bony cranium could be seen (Pl. 4C,D).

The visualized bony structures and joints of all three mummies were otherwise unremarkable.

### Discussion

The goal of mummification was to preserve the corpse in as lifelike appearance as possible. The process was largely shaped by religious beliefs. Preservation of the body was thought to be essential for survival of the deceased in the afterlife. The most important factor in the preservation of the body is desiccation. Early on, this resulted from close contact of the body with dry desert sands in the graves. Afterwards, this was accomplished by packing the body in natron (naturally occurring salt consisting of sodium carbonate and sodium bicarbonate) for at least a month. The bodies were often packed with sand, wax and mud to give the corpse a lifelike appearance. The effects of such procedures and the presence of resins are clearly seen as radiopaque densities on the images. Post mortem evisceration was necessary for adequate desiccation of the corpse. Only the heart and kidneys remained. The removed organs were wrapped and replaced within the body so as to allow the deceased to enter the afterlife intact. Until the 21st Dynasty the viscera (liver, lungs, stomach, intestines) were laid into four limestone Canopic jars, placed in a Canopic chest<sup>7</sup>.

The body cavities of the mummies we analyzed were filled with radiopaque material, most likely linen packing embalmed in resins and natron; in some mummies studied thus far they were filled with resin only<sup>3</sup>. The body cavities of Kareset were not filled with radiopaque material and there is a possibility that the inner organs were not replaced.

There was no evidence of disease or injury of the bones in the mummies we studied. In earlier reports on radiographs of mummies, both pre-mortem and post-mortem broken bones were found<sup>8</sup>.

The bony cranium was often intentionally broken by embalmers which allowed the brain to be removed. Brains were thought to be unnecessary for intelligence and the body's essence believed to reside in the heart. Kareset had a large skull defect that was most likely inflicted to remove the brain. Shepenun and Kaipamavv did not show such changes and, we presume, the brain must have been extracted through the nose. The resultant small bony defects may have easily be missed on conventional anterior-posterior radiographs.

6. 538:ZAG EG687; length of the cartonnage: 162cm; cf. Uranić I. Sarkofag i kartonaža Kaipamau. Summary: The coffin and the cartonnage of Kaipamau, in this volume offrijesrafć

7. Sandison AT. Balsamierung. *Lexikon der Ägyptologie*, vol. I. Wiesbaden 1975, 610-614; Brunner H. Herz. *ibid.* vol II, 1977: 1159; Sternberg H. Mumie. *ibid.*

vol IV, 1982:213-216; David RA ed. *Science in Egyptology*, Manchester 1986.

8. plavšić B, Hrančević, J. X-ray analysis of the Zagreb mummy. (Sažetak:) Analiza klasičnih rendgenograma Zagrebačke mumije. *Vjesnik Arheološkog muzeja u Zagrebu*, 3.S., 19/1986; 99-103.

In most adults the bony pelvis is typical in shape and enables ready determination of sex on radiographs. The pelvis of Kareset was not typical, although the majority of examining radiologists believed the person was female. The inscriptions on the sarcophagi indicate however a "mistress of the house"<sup>4</sup>.

Nothing of particular medical significance that would suggest pathologic changes of the skeleton were seen on the films. We previously reported degenerative processes of the knee and hip of the "Zagreb Mummy" (Neskons, the wife of Pakharekhons, priest of Khnum)<sup>8</sup>.

The mummies had large decorated wooden anthropoid sarcophagi, the contours of one mummy's cartonnage (Kaipamaw) is seen on X-ray films. That sort of care was preserved for the rich. The position of the hands differed for these male and female mummies.

Ali three mummies we studied, and the analysis of the "Zagreb Mummy" reported earlier<sup>8</sup>, had a single metallic spheric object within their skulls. These findings may have religious or cultural significance.

Computed tomography (CT) can also be used in studying mummies without destroying their integrity. It is superior to conventional radiographs in its ability to eliminate superposition of shadows and in its resolution of detail<sup>9</sup>. A three-dimensional CT reconstruction of an ancient human Egyptian mummy has also been successfully performed<sup>3,10</sup>.

Another noninvasive paleoradiologic tool, magnetic resonance imaging has been attempted in examining mummies, but has failed because dehydrated structures produce too weak a signal for processing into an image<sup>9,10</sup>.

A percutaneous biopsy of the mummified body can also be readily performed and can render tissue specimen for microscopic analysis<sup>2,11</sup>.

In the mummies we examined, only plain film radiography was performed. As a result, there was superimposition of radiopaque material with skeletal details.

## DESCRIPTION OF PLATES

### OPIS TABLI

#### Plate 1

A - The mummy of Kareset, 538:ZAG EG668, height: 160 cm; B - Plain X-ray film of the entire body of Kareset.

#### Tabla 1

A - Mumija Kareset, 538:ZAG EG668, visina: 160 cm; B - konvencijski rendgenogram cijele dužine tijela Kareset.

9. Pahl, W.M. Possibilities, limitations and prospects of computed tomography as a non-invasive method of mummystudies. *Science in Egyptology*. Manchester, 1986: 13-24; Strouhal E. - Kvicala, V. - Vyhnanek, L. Computed tomography of a series of Egyptian mummified heads. *Science in Egyptology*. Manchester, 1986: 123-139; Notman, N.H. Computed tomography of Egyptian mummies. *Science in Egyptology*. Manchester, 1986:

251-320; Mare, M. - D'Auria, S.H. CT examination of eleven Egyptian mummies. *Radiographics*, 6/1986: 321.

10. Marx, M. - D'Auria, S.H. Three-dimensional CT reconstructions of an ancient human Egyptian mummy. *AJR*, 150/1988:147.

11. Notman, D.N.H. - Tashjian J. - Aufderheide, A.C. - Cass, O.W. - Shane, O.C. - Berquist, T.H. - Gray J.E. - Gedgaudas, E. Modern imaging and endoscopic biopsy techniques in Egyptian mummies. *AJR*, 146/1986: 96.

Plate 2

A - The mummy of Shepenun, 538:ZAG EG667, height: 163 cm; B - Plain X-ray film of the entire body of Shepenun.

Tabla 2

A - Mumija Šepenun, 538:ZAG EG667, visina: 163 cm; B - Konvencijski rendgenogram cijele dužine tijela Šepenun.

Plate 3

A - The cartonnage containing the mummy of Kaipamaw; 538:ZAG EG687; height: 162 cm; B - Plain X-ray film of the entire body of Kaipamaw.

Tabla 3

A - Kartonaža s mumijom Kaipamau, 538:ZAG EG687; visina: 162 cm; B - Rendgenogram cijele dužine tijela Kaipamau.

Plate 4

A - Detail of the head of Kareset. A metallic foreign body is present (arrow).

B - Detail of the head of Shepenun, with a metallic foreign body (arrow).

C, D - Detail of the head of Kaipamaw. Anterior-posterior projection of the head. A metallic foreign body is present (arrow).

Tabla 4

A - Detalj glave mumije Kareset. Nazočno je strano kovinsko tijelo (strelica).

B - Detalj glave mumije Šepenun. Nazočno je strano kovinsko tijelo (strelica).

C, D - Detalji glave mumije Kaipamau, anteriorna-posteriorna projekcija. Nazočno je strano kovinsko tijelo (strelica).

## SAŽETAK

### RADIOLOŠKA ANALIZA TRIJU EGIPATSKIH MUMIJA

Standardni radiogrami triju egipatskih mumija iz Arheološkog muzeja u Zagrebu snimljeni su u Institutu za radiologiju Sveučilišne bolnice Rebro u Zagrebu 1987. godine. Kako bi se pokrila cijela dužina bile su potrebne tri do pet snimki svake pojedine mumije. Poslije su radiogrami fotografirani, a fotografije skenirane kako bi se ujednačile veličine rendgenografiranih segmenata svake mumije. Uporabom aparata za dijapozitive načinjene su pozitivne slike koje su poslužile za negative i laserske kopije.

Imena mumija nalaze se ispisana hijeroglifima na sarkofazima; to su Kareset, Šepenun i Kaipamau. Pri određivanju spola, uslijed dvoumljenja, pelvički je radiogram mumija, Kareset analiziralo četrnaest radiologa s Odjela za radiologiju Medicinskog centra Tulane sveučilišta u New Orleansu (SAD). Natpisi na sarkofazima svjedoče, međutim, daje riječ o "gospodarici kuće".<sup>4</sup>

Analiza standardnih radiograma mumija dala je slijedeće rezultate:

Kareset: Zamotana se mumija nalazi u dvostrukom antropomorfnom, drvenom obojenom sarkofagu.<sup>4</sup> Oblik zdjelice nije tipičan ni za ženski, ni za muški spol (T.1B). Osmorica od četrnaest radiologa, koliko ih je proučilo radiograme pelvičkih kostiju, mislili su da je mumija ženska. Proksimalni dijelovi potkoljenice nisu ušli u sliku, što se odražava u prividnom skraćivanju nogu. Ruke su prekrížene preko prsa, s dlanovima položenim preko nasuprotnih ramena. Nedostatak dijela čeone i desne tjemene kosti posljedica je postupka vađenja mozga pri balzamiranju. Neprozirni zrnati materijal vidljiv je unutar neurokranija (T.1B). Količina neprozirnog materijala unutar kako toraksa, tako i abdomena relativno je neznatna. Mišići i subkutano tkivo bedara, ali i, u manjem omjeru potkoljenice, prekriveni su neprozirnim materijalom. Obli metalni predmet, promjera 2 mm, vidljiv je u području potiljačne kosti (T.4A).

Šepenun: Dobro sačuvana mumija smještena je u trostrukom drvenom polikromnom antropomorfnom lijesu.<sup>5</sup> Oblik zdjelice tipičan je za ženu. Kostur je dobro sačuvan. Ruke su položene preko natkoljenice (T.2B). Obli kovinski predmet promjera oko 3 mm vidi se u gornjem dijelu lubanje (T.4B). Donji dio neurokranija ispunjen je za rendgenske zrake neprozirnom masom. Prsište i trbušna šupljina osobito lijevo, također su gusto ispunjeni neprozirnim materijalom.

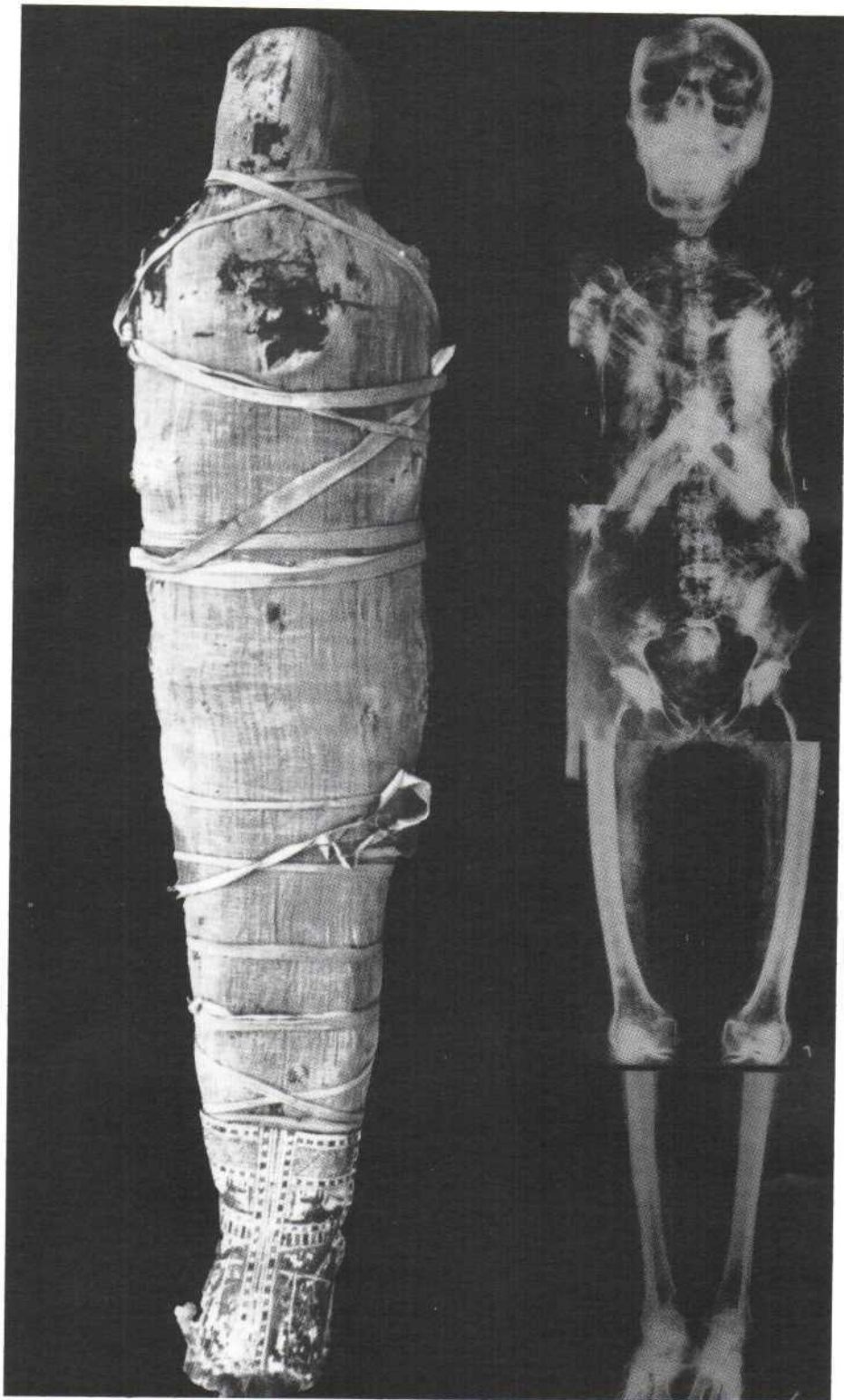
Kaipamau: Mumija je radiografirana u izvornoj obojanoj kartonaži, kojoj pripada odgovarajući drveni obojani antropomorfnu sarkofag.<sup>6</sup> Pelvis je ženski. Nadlaktice leže usporedno s toraksom, a podlaktice i dlanovi usmjereni su prema sredini. Velika količina radiografski neprozirnog materijala utvrđena je u prsnoj i trbušnoj šupljini (T.3B). Strano kovinsko tijelo, 2 mm u promjeru, vidljivo je u lijevom dijelu neurokranija (T.4C,D). Šupljina lubanje bez drugog je sranog neprozirnog materijala. Nikakve anomalije kostiju lubanje nisu uočene.

Nije bilo nikakvih osobitosti koštane strukture i zglobova ma koje od triju mumija. Tjelesne šupljine mumija ispunjene su za rendgenske zrake neprozirnim materijalom, najvjerojatnije je riječ o lanenoj ispuni umočenoj u balzam i natron. Kako tjelesne šupljine Kareset nisu ispunjene neprozirnim materijalom, postoji vjerojatnost da neki od unutrašnjih organa nisu vraćeni. Nema znakova mogućih ozljeda kostiju proučenih mumija, niti uočljivih patoloških promjena kostura. U ranijem izvješću o radiogramima "Zagrebačke mumije" (Neshons, žena Paharenhonsa, svećenika boga Hnuma) uočene su kosti slomljene za života, ali i nakon smrti, ali i degenerativni procesi koljena i kuka.<sup>8</sup>

Kosti lubanje su balzamatori često namjerno lomili, kako bi izvadili mozak. Kod Šepenun i Kaipamau nije bilo takvih tragova, pa smatramo daje mozak najvjerojatnije izvađen kroz nos. Tim postupkom načinjena manja oštećenja mogu lako ostati nezamijećena na konvencijskim rendgenogramima. Kod sve tri mumije, kao i kod "Zagrebačke mumije", o kojoj je već ranije izviješteno<sup>8</sup>, po jedan se obli kovinski predmet nalazi na lubanji.

Rukopis primljen 1. XII. 1994.

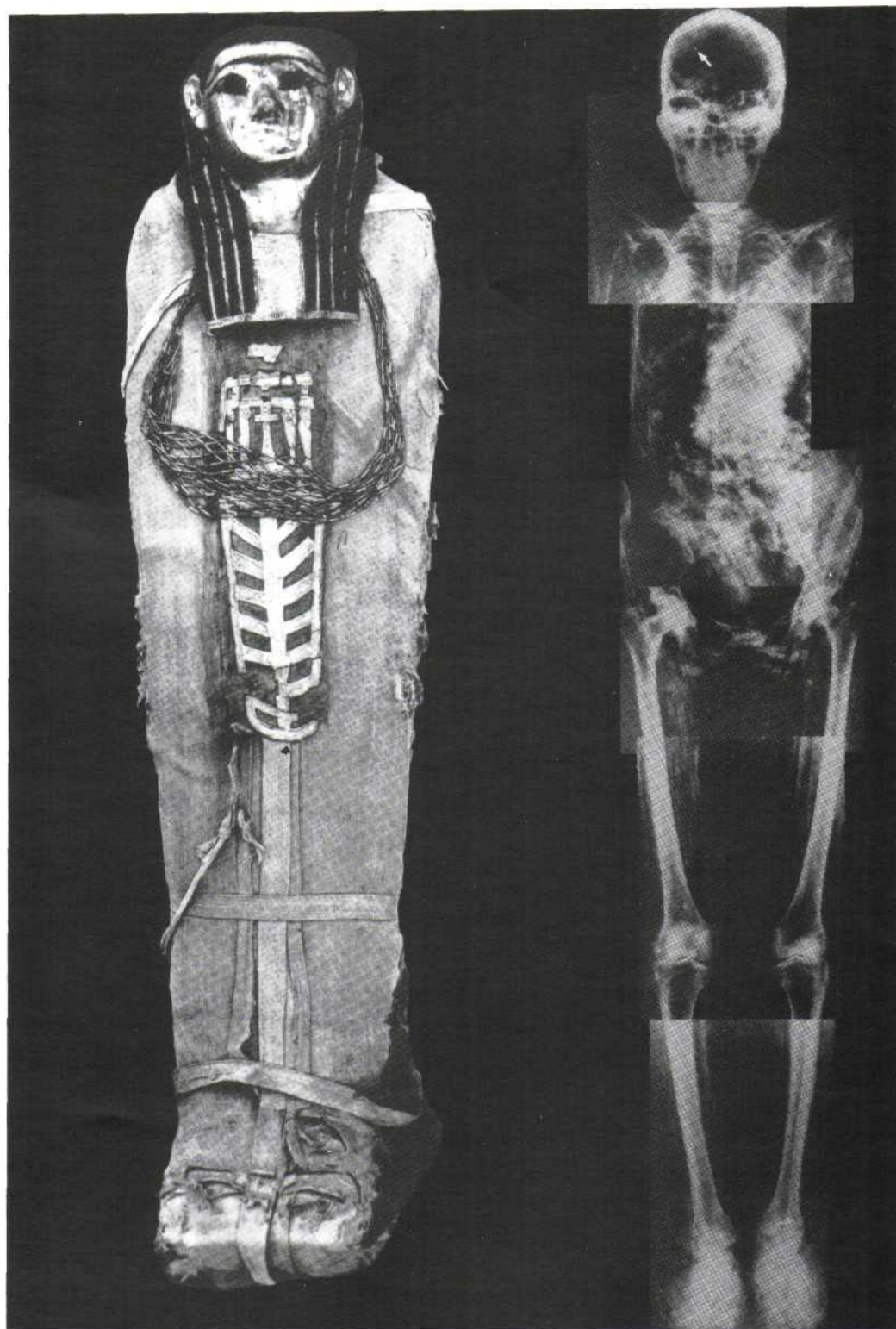
Rukopis prihvaćen 18. XII. 1994.



A

Tabla 1

B

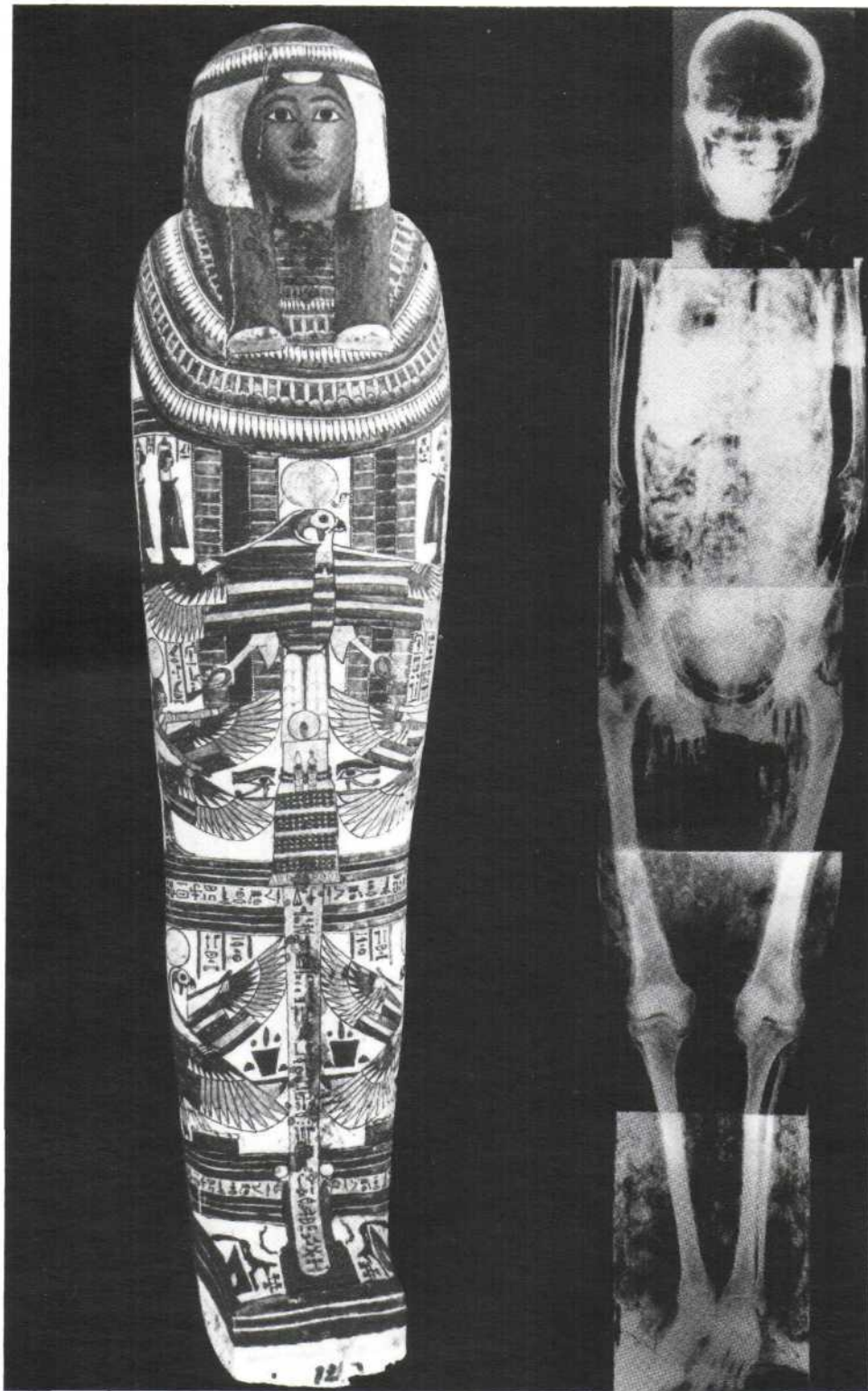


A

Tabla 2

B

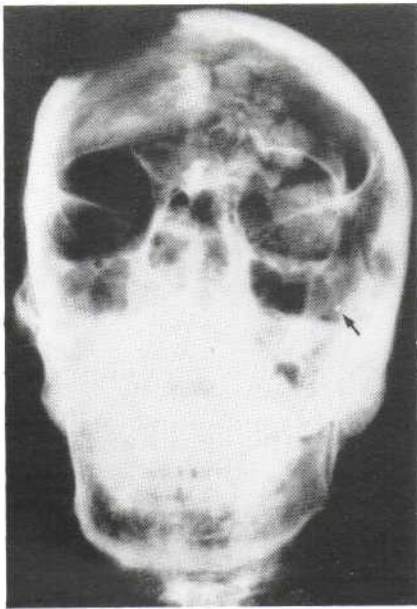




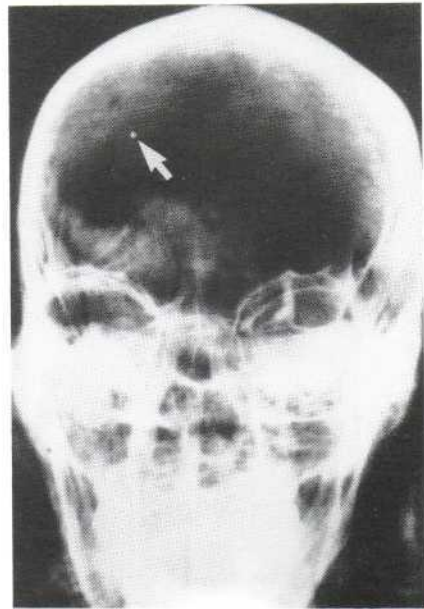
A

Tabla 3

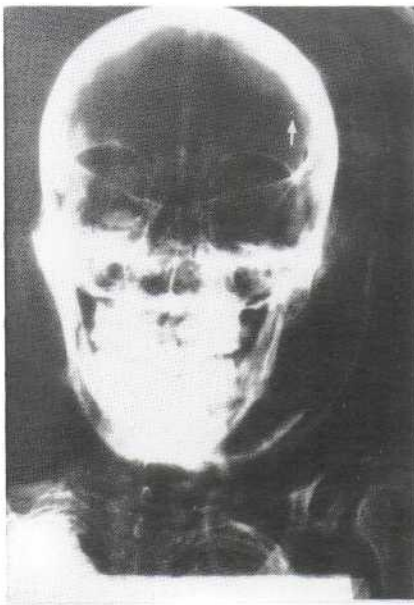
B



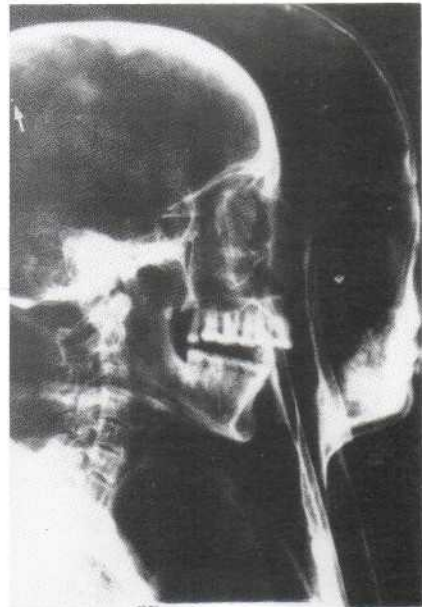
A



B



C



D

Tabla 4