

Luminita Nica<sup>1</sup>, Marius Raica<sup>2</sup>

# Imunohistokemijska lokalizacija dendritičkih stanica u humanoj zubnoj pulpi

## *Immunohistochemical Localization of Dendritic Cells in Human Dental Pulp*

<sup>1</sup> Zavod za restorativnu stomatologiju i endodonciju Stomatološkog fakulteta Medicinskog i farmaceutskog sveučilišta „Victor Babes“, Temišvar, Rumunjska  
*Discipline of Restorative Dentistry and Endodontics, Faculty of Dental Medicine, University of Medicine and Pharmacy “Victor Babes”, Timisoara, Romania*

<sup>2</sup> Zavod za histologiju i citologiju Medicinskog i farmaceutskog sveučilišta „Victor Babes“, Temišvar, Rumunjska  
*Department of Histology- Cytology, University of Medicine and Pharmacy “Victor Babes”, Timisoara, Romania*

### Sažetak

**Svrha:** Svrha istraživanja bila je metodom imunohistokemijskih bojenja locirati dendritičke stanice, te dio imunokompetentnog sustava dentalne pulpe u histološkim uzorcima normalne i ireverzibilno inflamirane ljudske zubne pulpe. **Materijal i metode:** Zbog posebnih svojstava vezivnog tkiva ljudske zubne pulpe, koristila su se sljedeća antitijela: vimentin V9, protein povezan s neurofilamentima (NFAP), protein S 100 te aktin glatkih mišića (klon 1A4). **Rezultati:** Rezultati su pokazali da humana dentalna pulpa ima mnogobrojne stanice s razgranatim citoplazmatskim produžecima u području upalnoga infiltrata. Na temelju imunohistokemijskog bojenja smatramo da je riječ o dendritičkim stanicama. **Zaključak:** Dendritičke stanice u upaljenoj ljudskoj zubnoj pulpi nisu neočekivane s obzirom na veliku gustoću upalnog infiltrata i ulogu koju imaju u upalnom odgovoru. Podtip i značenje tih stanica treba još objasniti.

**Zaprimljen:** 12. travnja 2008.

**Prihvaćen:** 14. kolovoza 2008.

### Adresa za dopisivanje

Luminita Nica  
Ion Ghica 3  
300161 Temišvar  
Rumunjska  
[nical78@yahoo.com](mailto:nical78@yahoo.com)

### Ključne riječi

zubna pulpa; dendritičke stanice;  
imunohistokemija

### Uvod

Zubna pulpa je jedinstveno vezivno tkivo koje se nalazi u siromašnoj okolini. Iako ima mnogo obilježja ostalih vezivnih tkiva u tijelu, njezina lokacija unutar čvrstih dentinskih zidova daje joj nekoliko specijalnih svojstava. Mnoge su vidljive tijekom upalnog procesa u samoj pulpi. Odgovor pulpe na upalne podražaje snažne su dinamičke promjene u lokalnom krvotoku, ali i mobilizacija imunih stanica prema mjestu ozljede.

Imunokompetentni sustav zubne pulpe sastavljen je od limfocita, makrofaga i dendritičkih stanica, a sve su sposobne stvoriti obrambeni mehanizam u slučaju invazije antigena.

### Introduction

Dental pulp is a unique connective tissue that is situated in a low compliance environment. Although dental pulp has many of the properties of other connective tissues of the body, its location between rigid dentin walls endows it with several special characteristics. Many of these characteristics are evident during the inflammatory process of the dental pulp. Dental pulp responds to inflammatory stimuli with great dynamic changes in the local blood flow, and also through the recruitment of immune cells to the site of injury.

The immunocompetent system of human dental pulp is made of cells such as lymphocytes, macro-

Iako imaju sekundarnu ulogu u obrani, dendritičke se stanice nalaze u ljudskoj zubnoj pulpi, posebice u područjima velike gustoće upalnog infiltrata. To nije neočekivano, ali zbuñuju podaci u literaturi.

Dendritičke stanice su hematopoetski leukociti koji naseljavaju periferna nelimfoidna tkiva. Nakon što sazriju u koštanoj srži i cirkuliraju u krvnoj struji, postaju dio obrambenog mehanizma tkiva, zajedno s limfocitima i makrofazima (1). U pulpi je njihova primarna zadaća obraniti to tkivo od invazije antigena. Dendritičke stanice zarobljavaju antigene i predaju ih T-limfocitima (2,3).

Dendritičke stanice uglavnom se nalaze u odontoblastičnom sloju koronalnog dijela pulpe i ispod njega. Također ih je mnogo u perivaskularnom području, gdje su organizirane tako da im je duža os paralelna s endotelnim stanicama (4). Karakterizira ih dendritička morfologija s uskim, zavrnutim citoplazmatskim produžecima, a sadržavaju nježne tubulovesikularne strukture, umjereno razvijen Golgijev aparat i slabo razvijene lizosomne strukture unutar citoplazme (5-7). Dendritičke stanice stvaraju retikularnu mrežu u cijeloj pulpi (8,9).

Imunokompetentne stanice u ljudskoj zubnoj pulpi te njihova distribucija mogu se specifično vizualizirati imunohistokemijskim načinima bojenja (10,11).

Svrha istraživanja bila je imunohistokemijskim tehnikama locirati dendritičke stanice u histološkim uzorcima normalne i ireverzibilno upaljene ljudske pulpe.

## Materijal i metode

Zubna pulpa bila je izvađena iz pet zuba ( $n = 5$ ) - jednoga gornjeg i dvaju donjih molara te dvaju gornjih premolara - pacijenata s dijagnosticiranim ireverzibilnim pulpitisom te od četiriju ( $n = 4$ ) zdravih pojedinca (dva gornja molara i dva gornja premolara) s normalnom pulpom, a pulpotomija je obavljena iz protetskih razloga. Pacijenti su pristanak dali prije svakog postupka. Nakon lokalne anestezije artikainom (Ubistesin forte, 3M Espe, Seefeld, Njemačka), izolacije radnog polja koferdamom (Roeko Dental Dam, Coltene/Whaledent) i otvaranja ulaznoga trepanacijskog otvora, dentalna je pulpa

phages and dendritic cells, which are capable of creating a defense mechanism against antigenic invasion.

Although they play a secondary role in this defense mechanism, dendritic cells are present in inflamed human dental pulp, especially in areas with a great density of inflammatory infiltrate. Their presence in these areas is not unexpected, but there are conflicting reports about it in literature.

Dendritic cells are hematopoetically derived leukocytes that populate peripheral nonlymphoid tissues. After maturation in the bone marrow and circulation in the bloodstream, they are recruited to form part of the defense mechanism of the tissues, together with lymphocytes and macrophages (1). In the dental pulp, their primary function is to defend this tissue from antigenic invasion. The dendritic cells capture invading antigens and present them to T lymphocytes (2, 3).

Dendritic cells are predominantly located in and just beneath the odontoblastic layer of the coronal pulp. These cells are also abundant in the perivascular area, where they are arranged with their longitudinal axes parallel to the endothelial cells (4). They are characterized by dendritic morphology, with narrow, tortuous cytoplasmic processes, and contain fine tubulovesicular structures, a moderately developed Golgi apparatus and poorly developed lysosomal structures within their cytoplasm (5, 6, and 7). Dendritic cells form a reticular network throughout the entire pulp (8, 9).

The presence and distribution of the immunocompetent cells in human dental pulp can be specifically visualized through immunohistochemical staining methods (10, 11).

The aim of this study was to locate the dendritic cells in histological samples of normal and irreversibly inflamed human dental pulp using immunohistochemical techniques.

## Materials and Methods

Human dental pulp was taken from five ( $n=5$ ) patients (one maxillary and two mandibular molars, and two upper premolars) diagnosed with irreversible pulpitis, and from four ( $n=4$ ) healthy individuals (two maxillary molars and two maxillary premolars) with normal pulp, who were undergoing a pulpectomy for prosthodontic reasons. Informed consent was obtained from all patients prior to each procedure. After local anesthesia (local nerve-block) with articaine (Ubistesin forte, 3M Espe, Seefeld, Germany), isolation of the working field with a rubber dam (Roeko Dental Dam, Col-

uklonjena iz pulpne komore te ekstirpirana čeličnim ekstirpatorom (ISO #25) (VDW, München, Njemačka) iz glavnoga korijenskog kanala (Slika 1.).

Svi uzorci isprani su fiziološkom otopinom i odmah uronjeni u četiri postotni paraformaldehid u 0,1 M otopinu fosfatnog praha (pH 7,2). Fiksacija je trajala 24 sata, što je u skladu s imunohistokemijskim protokolima. Nakon uranjanja u parafin napravljeni su rezovi (40-50  $\mu\text{m}$  debljine) mikrorezačem DTK-2000 (Dosaka EM Co., Kyoto, Japan).

Vizualizacija označenim streptavinom biotinom (LSAB 2) i diaminobenzidin-dihidrokloridom (DAB, EnVision Systems, DAKO, Glostrup, Danska) koristila se za imunohistokemijsko bojenje, tako da je konačni rezultat bio obojen smeđe. S obzirom na posebnost vezivnog tkiva dentalne pulpe i okolnih tvrdih tkiva, koristila su se sljedeća antitijela:

- klon vimentina V9 (DAKO) - pozitivna reakcija potvrđuje točnu primarnu obradu, a monoklonsko antitijelo prepoznaje epitop lokaliziran na intermedijarnim filamentima vimentina koji luče stanice mezenhimalnog podrijetla;
- protein povezan s neurofilamentima (NFAP) (DAKO) - on prepoznaje epitope lokalizirane na neurofilamentima te je visoko specifičan za živčane stanice i njihova vlakna - svrha je vizualizirati distribuciju živčanih vlakana u subodontoblastičkom području;
- protein S 100 (DAKO) – javlja se u nespecifičnim Schwannovim stanicama i dendritičkim stanicama;
- klon aktina tipa glatkog mišića 1A4 (DAKO) - prepoznaje nesarkomerne aktinske filamente u svim potencijalno kontraktilnim stanicama - svrha je identificirati stanicu miofibroblastičkog tipa u patološki promijenjenoj pulpi.

Sve analize obavljene su mikroskopom Nikon Eclipse 600 (Nikon Instruments Inc., Melville, SAD) s povećanjima od 200 i 400 puta.

## Rezultati

Bojenje vimentinom bilo je pozitivno te je pokazalo diferencijaciju i u normalnoj i patološki promijenjenoj pulpi. Pozitivni fibroblasti izolirani su u normalnoj pulpi, kao i nespecifične endotelne stanice (epitelne stanice mezodermalnog podrijetla) (Slika 2.a). Pozitivna reakcija pokazuje da je primarna

tene/ Whaledent, Inc) and the creation of the access cavity, dental pulp was removed from the pulp chamber and extirpated with a stainless steel barbed broach (ISO # 25) (VDW, Munich, Germany) from the main root canal, Fig.1.

All samples of dental pulp were washed with a saline solution and immersed immediately in 4% paraformaldehyde in 0.1 M phosphate buffer solution (pH 7.2). The fixation lasted for 24 hours, in accordance with standard immunohistochemical protocols. After embedding in paraffin, serial sections (40-50  $\mu\text{m}$  in thickness) were cut with a Microslicer DTK-2000 (Dosaka EM Co., Kyoto, Japan).

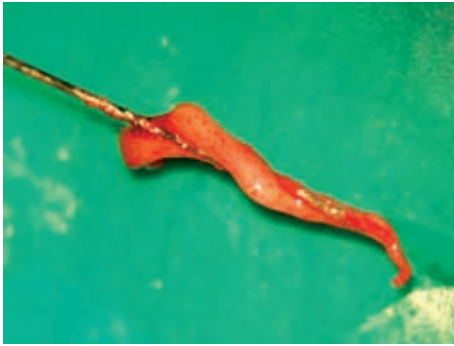Labeled streptavidin biotin (LSAB 2) visualization with diaminobenzidine dihydrochloride (DAB), (EnVision Systems, DAKO, Glostrup, Denmark) was used for immunohistochemical staining, so the final reaction product was therefore stained brown. In consideration of the particular character of the connective tissue of human dental pulp, and that of the hard tissues that surround it, the following antibodies were used:

- Vimentin clone V9 (DAKO): a positive reaction indicates correct primary processing. The monoclonal antibody used recognizes an epitope localized on vimentin intermediate filaments expressed by cells of mesenchymal origin.
- Protein associated with neurofilaments (NFAP), (DAKO): this recognizes epitopes localized in neurofilaments, and is highly specific for nerve cells and their branching fibers. The purpose was to visualize the distribution of nerve fibers in the subodontoblastic domain.
- The S 100 protein (DAKO): this is expressed non-specifically in Schwann cells and in dendritic cells.
- Smooth muscle type actin, clone 1A4 (DAKO): this recognizes non-sarcomeric actin filaments in all potentially contractile cells. The purpose was to identify the presence of myofibroblastic-type cells in the pathological pulp.

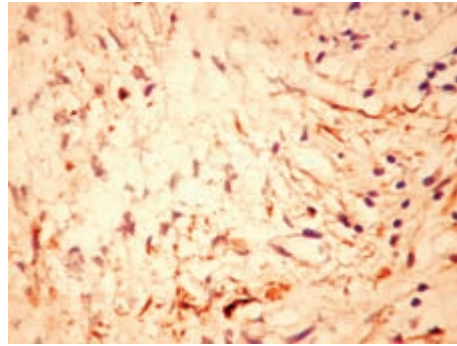
All examinations were made with a Nikon Eclipse 600 microscope (Nikon Instruments Inc, Melville, NY, USA) at magnifications of 200 $\times$  and 400 $\times$ .

## Results

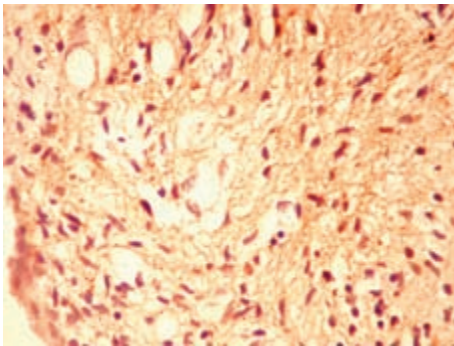
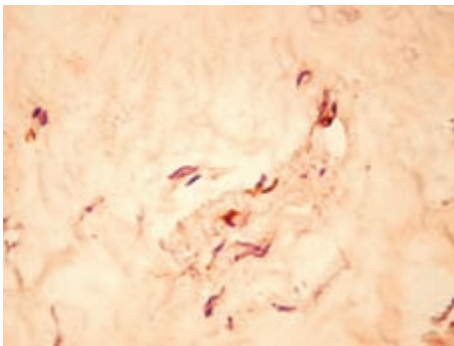
Vimentin staining was positive, showing differentiation in both the normal and the pathological pulp. Positive fibroblasts were isolated in normal pulp, as were non-specific endothelial cells (epithelial cells of mesodermic origin), Fig. 2A. The positive reaction indicates that the primary processing



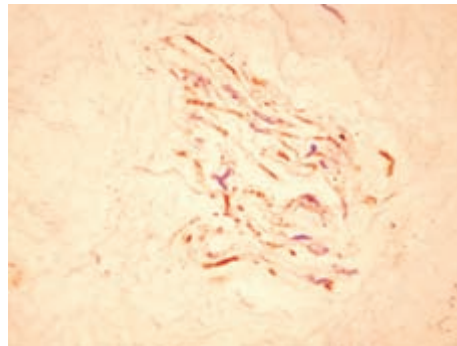
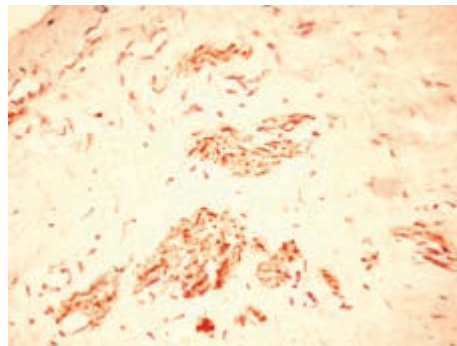
**Slika 1.** Makroskopski izgled ljudske zubne pulpe ekstrahirane iz glavnog korijenskog kanala  
**Figure 1** Macroscopic view of human dental pulp extracted on a barbed broach from the main root canal.



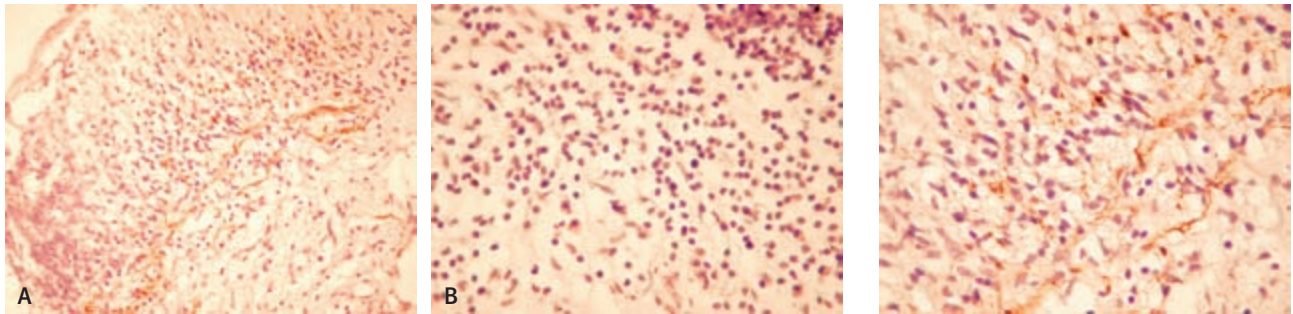
**Slika 3.** Detalj patološki promijenjene pulpe - vidi se da se produžeci stanica pozitivnih na vimentin dodiruju (povećanje 400 puta).  
**Figure 3** Detail of the pathological pulp, in which we observe the contacts among the extensions of the vimentin-positive cells (400× magnification).



**Slika 2.** Imunosna reakcija na klon vimentina V9, vizualizacija s DAB (povećanje 200 puta)  
**a.** Intenzivno-pozitivna reakcija izoliranih stanica u normalnoj pulpi bez kontakata između sebe te predstavljaju fibroblaste  
**b.** Intenzivno-pozitivna i difuzna reakcija u patološki promijenjenoj pulpi; citoplazmatski produžeci difuzne mreže.  
**Figure 2** Immune reaction for vimentin clone V8, visualization with DAB (200× magnification).  
**A.** An intensely positive reaction in isolated cells in the normal pulp, which do not establish contacts amongst themselves and represent fibroblasts.  
**B.** An intensely positive and diffuse reaction in pathological dental pulp; cytoplasmic extensions form a diffuse network.



**Slika 4.** Normalna zubna pulpa (povećanje 200 puta)  
**a.** Živčana vlakna (Schwannove stanice) identificirana proteinom S100  
**b.** Normalni aksoni identificirani NFAP-om  
**Figure 4** Normal dental pulp (200× magnification).  
**A.** Nerve fibers (Schwann cells) identified with the S100 protein.  
**B.** Normal axons identified with NFAP.



**Slika 5a.** Dendritičke stanice identificirane proteinom S100 (povećanje 200 puta)

**Figure 5a** Dendritic cells identified with the S100 protein (200× magnification).

**Slika 5b.** Negativna imunosna reakcija na protein povezan s neurofilamentima (NFAP, povećanje 200 puta).

**Figure 5b** Negative immune reaction for the protein associated with neurofilaments (NFAP) (200× magnification).

**Slika 6.** Detalj dendritičke stanice pozitivne na protein S100 (povećanje 400 puta) - mogu se vidjeti citoplazmatski produžeci koji ulaze između limfocita kroničnog upalnog infiltrata.

**Figure 6** Detail of the dendritic cells, positive for the S100 protein (400× magnification). Branching cytoplasmic extensions can be observed penetrating between the lymphocytes of the chronic inflammatory infiltrate.

obrada uspješna, što omogućuje točniju interpretaciju ostalih rezultata. Imunosna reakcija u patološki promijenjenoj pulpi bila je difuzno pozitivna. Uočena je bila difuzna proliferacija intenzivno pozitivnih stanica s retikularnim aspektom (Slika 2.b).

Gustoća stanica pozitivnih na vimentin bila je znatno veća u blizini upalnog infiltrata. Pozitivne se stanice dodiruju i stvaraju gustu mrežu svojstvenu prema tome što nadomješta klasične karakteristike fibroblasta (Slika 3.).

Zbog toga je imunosna reakcija s antiaktinom (tip glatkog mišića, DAKO) obavljena kako bi se identificirala suokspresija vimentinskih filamenata s kontraktilnim filamentima, svojstvenima za fibroblaste.

Ta je patologija zanimljiva u slučajevima upale, jer je nismo našli u literaturi.

Također smo dobili zanimljive rezultate metodom nespecifičnog pojačavanja proteina S100 i NFAP. Kod proteina S100 u normalnoj pulpi, samo su Schwannove stanice u živčanim vlaknima bile pozitivne (Slika 4.a). Njihova prisutnost bila je pozitivna interna kontrola imunosne reakcije. Dodatno, reakcija s NFAP-om pokazala je da aksoni nisu pozitivni za druge elemente, što je znak visoke specifičnosti (Slika 4.b).

Nakon bojenja patološki promijenjene pulpe proteinom S100, u području upalnog infiltrata identificirane su mnogobrojne stanice s razgranatim citoplazmatskim produžecima (Slika 5.a). Ti su produžeci penetrirali limfocite u upalnom infiltratu. Na

worked, allowing the other results to be interpreted with great precision. The immune reaction in the pathological pulp was diffusely positive. Diffuse proliferation of intensely positive cells with a reticular aspect was observed Fig. 2B.

The density of the vimentin-positive cells was significantly greater in the vicinity of the inflammatory infiltrate. Positive cells contact each other, forming a dense network, a characteristic that supplements the classic description of fibroblast features, Fig. 3.

For this reason, the immune reaction with anti-actin (smooth muscle type, DAKO) was performed in order to identify the co-expression of vimentin filaments with contractile filaments, a characteristic of fibroblasts.

This pathology in cases of inflammation is interesting because we have not found it discussed in the literature.

We also obtained interesting results with methods for the non-specific amplification of the S100 protein and for NFAP. With S100 protein, in the normal pulp, only Schwann cells in nerve fibers became positive, Fig. 4A. Their presence was the internal positive control for the immune reaction. In addition, the reaction for NFAP showed the axons and was not positive for other elements; therefore it has a high degree of specificity, Fig. 4B.

Upon staining the pathological pulp for the S100 protein, in the area of inflammatory infiltrate, numerous cells were identified as presenting branching cytoplasmic extensions, Fig. 5A. These extensions

rezovima obojenima NFAP-om nije bilo identifikacije živčanih vlakana (Slika 5.b).

Smatramo da su to dendritičke stanice te da pripadaju superobitelji stanica prezentera antigena. To što smo ih našli na toj razini (Slika 6.) moglo se očekivati zbog velike gustoće upalnog infiltrata i njihove uloge u obrambenom mehanizmu dentalne pulpe.

## Rasprava

U ovom smo istraživanju imunohistokemijskim metodama bojenja lokalizirali dendritičke stanice u normalnoj i upalom promijenjenoj ljudskoj zubnoj pulpi. Rezultati pokazuju da se te stanice nalaze u subodontoblastičkom sloju dentalne pulpe te da se njihov broj povećava u područjima gdje postoji upalni infiltrat. One imaju istaknute citoplazmatske produžetke koji se probijaju do susjednih stanica i tamo donose svoj bliski dodir. Naši rezultati slični su rezultatima Jontella i suradnika (12), što potvrđuje da dendritičke stanice imaju specifičnu ulogu u nadzoru imunosti.

Uzorci ljudske pulpe bili su zreli (dob pacijenata od 18 do 42 godine), ali stanice s dendritičkim izgledom i distribucijom na periferiji pulpe, opisane su i u mliječnim zubima (13).

Dendritičke stanice privukle su veliku pozornost te su opisane kao ključne u ranoj fazi imunskog odgovora (14,15). Pokazalo se da su povezane s monocitima u krvi i makrofazima u tkivu, ali da potječu iz druge loze stanica (16). Iako ne mogu točno identificirati strane antigene, one daju potrebne signale za aktivaciju T-limfocita koji nakon toga djeluju na druge imunokompetentne stanice odgovorne za lokalni obrambeni odgovor zubne pulpe (12).

## Zaključak

Imunohistokemijsko istraživanje na uzorcima ljudske zubne pulpe, otkrilo je posebna strukturalna svojstva tkiva. Dendritičke stanice, kao imunokompetentni rezidenati dentalne pulpe, pokazuju da veživo tkivo ljudske zubne pulpe aktivno sudjeluje u imunskim reakcijama.

Podtip i značenje dendritičkih stanica u ljudskoj zubnoj pulpi treba objasniti u budućim istraživanjima.

penetrated the lymphocytes of the inflammatory infiltrate. On sections stained for NFAP, no nerve fibers were identified, Fig. 5B.

Thus we consider that these cells are of the dendritic type (dendritic cells), and that they belong to the super-family of antigen-presenting cells. Their presence at this level is to be expected, considering the great density of the inflammatory infiltrate and the role they play in the defense mechanism of the dental pulp, Fig. 6.

## Discussion

In this study we examined by immunohistochemical staining methods the localization of dendritic cells in normal and inflammatory human dental pulp. The results showed that dendritic cells are localized preferably in the subodontoblastic layer of the dental pulp, and their number increases in this area when an inflammatory infiltrate is present. They present pronounced cytoplasmic extensions that penetrate between the surrounding cells and aid their close interaction with these. Our results are similar to that of the study by Jontell et al. (12) that confirms that dendritic cells have a specific function in immunosurveillance.

The samples of human dental pulp used in this study were all mature (age of patients varied from 18 to 42 years old), but cells with dendritic profile and distribution in the periphery of the pulp were also described in deciduous human teeth (13).

The dendritic cell has attracted considerable interest and has been ascribed a key role in the early phases of the immune response (14, 15). It has been shown that the dendritic cells are related to blood monocytes and tissue macrophages but are clearly from a distinct cell lineage (16). Although dendritic cells are not able to identify foreign antigens specifically, they provide necessary signals to activate T-lymphocytes which in turn will orchestrate other immunocompetent cells to mount the local immune defense of the dental pulp (12).

## Conclusions

Immunohistochemical investigations performed on samples of human dental pulp have revealed special structural characteristics of this tissue. The presence of dendritic cells as immunocompetent residents of the dental pulp demonstrates that the connective tissue of human dental pulp is an active participant in immune reactions.

The subtype and significance of dendritic cells in human dental pulp remain to be clarified by future investigations.

**Abstract**

**Objectives:** The aim of this study was to locate the dendritic cells, a part of the immunocompetent system of dental pulp, in histological samples of normal and irreversibly inflamed human dental pulp, using immunohistochemical staining methods. **Material and Methods:** In light of the particular character of the connective tissue of human dental pulp, the following antibodies were used: vimentin clone V9, a protein associated with neurofilaments (NFAP), the S 100 protein, and smooth muscle type actin (clone 1A4). **Results:** The results indicated that human dental pulp has numerous cells with branching cytoplasmic extensions, in areas of inflammatory infiltrate. Based on immunohistochemical staining we consider these to be dendritic cells. **Conclusions:** The presence of dendritic cells in inflamed human dental pulp is not unexpected, considering the great density of the inflammatory infiltrate, and the role they play in the inflammatory response. The subtype and significance of these cells need to be clarified.

Received: April 12, 2008

Accepted: August 14, 2008

**Address for correspondence**

Luminita Nica,  
Ion Ghica St. # 3  
300 161 Timisoara  
Romania- EU  
nical78@yahoo.com

**Key words**

Dental Pulp; Dendritic Cells;  
Immunohistochemistry

**References**

1. Kamal AM, Okiji T, Kawashima N, Suda H. Defense responses of dentin/pulp complex to experimentally induced caries in rat molars: an immunohistochemical study on kinetics of pulpal Ia antigen-expressing cells and macrophages. *J Endod.* 1997;23(2):115-20.
2. Steinman RM. The dendritic cell system and its role in immunogenicity. *Annu Rev Immunol.* 1991;9:271-96.
3. Hart DN. Dendritic cells: unique leukocyte populations which control the primary immune response. *Blood.* 1997;90(9):3245-87.
4. Okiji T, Jontell M, Belichenko P, Bergenholtz G, Dahlström A. Perivascular dendritic cells of the human dental pulp. *Acta Physiol Scand.* 1997;159(2):163-9.
5. Jontell M, Gunraj MN, Bergenholtz G. Immunocompetent cells in the normal dental pulp. *J Dent Res.* 1987;66(6):1149-53.
6. Jontell M, Bergenholtz G, Scheynius A, Ambrose W. Dendritic cells and macrophages expressing class II antigens in the normal rat incisor pulp. *J Dent Res.* 1988;67(10):1263-6.
7. Jontell M, Eklöf C, Dahlgren UI, Bergenholtz G. Difference in capacity between macrophages and dendritic cells from rat incisor pulp to provide accessory signals to concanavalin-A-stimulated T-lymphocytes. *J Dent Res.* 1994;73(5):1056-60.
8. Sakurai K, Okiji T, Suda H. Co-increase of nerve fibers and HLA-DR- and/or factor-XIIIa-expressing dendritic cells in dentinal caries-affected regions of the human dental pulp: an immunohistochemical study. *J Dent Res.* 1999;78(10):1596-608.
9. Pulver WH, Taubman MA, Smith DJ. Immune components in normal and inflamed human dental pulp. *Arch Oral Biol.* 1977;22(2):103-11.
10. Yoshida N, Yoshida K, Nakamura H, Iwaku M, Ozawa H. Immunohistochemical localization of HLA-DR-positive cells in unerupted and erupted normal and carious human teeth. *J Dent Res.* 1996;75(8):1585-9.
11. Zhang J, Kawashima N, Suda H, Nakano Y, Takano Y, Azuma M. The existence of CD11c+ sentinel and F4/80+ interstitial dendritic cells in dental pulp and their dynamics and functional properties. *Int Immunol.* 2006;18(9):1375-84.
12. Jontell M, Okiji T, Dahlgren U, Bergenholtz G. Immune defense mechanisms of the dental pulp. *Crit Rev Oral Biol Med.* 1998;9(2):179-200.
13. Angelova A, Takagi Y, Okiji T, Kaneko T, Yamashita Y. Immunocompetent cells in the pulp of human deciduous teeth. *Arch Oral Biol.* 2004;49(1):29-36.
14. Steinman R, Inaba K. Immunogenicity: role of dendritic cells. *Bioessays.* 1989;10(5):145-52.
15. Yao V, Platell C, Hall JC. Dendritic cells. *ANZ J Surg.* 2002;72(7):501-6.
16. Shortman K, Maraskovsky E. Developmental options. *Science.* 1998;282(5388):424-5.