

---

ISSN: 0001-5113  
AADRAY

ACTA ADRIAT.,  
49(1): 19 - 23, 2008

UDC:593.194:597.5 (663)(261)

---

**Identification of *Myxobolus episquamalis* (Myxozoa, Myxobolidae) in flathead mullet *Mugil cephalus* (Pisces, Teleostei, Mugilidae) from the coast of Senegal (eastern tropical Atlantic Ocean)**

Arfang DIAMANKA, Malick FALL, Cheikhna DIEBAKATE, Ngor FAYE  
and Bhen Sikina TOGUEBAYE\*

*Laboratory of Parasitology and Laboratory of Aquatic Animals Pathologies - Khaled Bin Sultan Living Oceans Foundation, Department of Animal Biology, Faculty of Sciences and Technologies, University Cheikh Anta DIOP of Dakar, Dakar, Senegal*

\* Corresponding author, e-mail: [parasito@refer.sn](mailto:parasito@refer.sn)

---

*Myxobolus episquamalis* (Myxozoa, Myxobolidae), a myxosporidian parasite, was found for the first time infecting scales and fins of flathead mullet (*Mugil cephalus*) from the Senegalese coast. The overall prevalence of infection was 4.7% (25/529), while the highest infection rates were observed in January 2006 (17.1%) and July 2006 (13.9%). This parasite forms large and white cysts which cover a great part of the fish body. According to this new report from African Atlantic coast, *Myxobolus episquamalis* geographical distribution is extended considerably. However, the infection is of little commercial importance and does not cause a significant economic loss in Senegal.

---

**Key words:** Myxosporidia, *Myxobolus episquamalis*, *Mugil cephalus*, cutaneous infection, Senegal

## INTRODUCTION

During a parasitological survey of Mugilid fish along the Atlantic coast of Senegal, we found for the first time *Myxobolus episquamalis* Egusa, Maeno and Sorimachi, 1990 in flathead mullet (*Mugil cephalus* Linnaeus, 1758), which was previously described in *M. cephalus* from Israel, Portugal, Japan, Tunisia and Australia (OVERSTREET & HOWSE, 1977; MENEZES, 1984; EGUSA *et al.*, 1990; BAHRI *et al.*, 1995; ROTHWELL *et al.*, 1997).

Several other *Myxobolus* spp, causing systemic infection, gill and skin lesions have been reported in *Mugil cephalus*. They are: *M. mülleri* Bütschli, 1882; *M. exiguus* Thélohan, 1895; *M. branchialis* Markevitch, 1932; *M. cheni* Schulman, 1962; *M. parvus* Schulman, 1962; *M. achmerovi* Schulman, 1966; *M. cephalus* Iversen, Chitty and Van Meter, 1971, *M. spinacurvatura* Maeno and Sorimachi, 1990; *M. mugcephalus* Landsberg and Lom, 1991; *M. rhodei* Lom and Dyková, 1994; *M. bizerti* Bahri and Marquès,

1996 and *M. ichkeulensis* Bahri and Marquès, 1996 (KUDO, 1919; SCHULMAN, 1966; IVERSEN *et al.*, 1971; EGUSA *et al.*, 1990; MAENO *et al.*, 1990; LANDSBERG & LOM, 1991; LOM & DYKOVÁ, 1992, 1994; BAHRI & MARQUÈS, 1996).

In this paper we describe the pathology and the characteristics of *M. episquamalis* identified in Senegalese waters.

## MATERIAL AND METHODS

Freshly caught flathead mullet (*Mugil cephalus*) from the Senegalese coast were purchased from fishermen during visits between November 2005 and December 2006. Visits were carried out monthly. The collection site was the fishing port of Dakar-Hann. A total of 529 specimens were examined and the sizes (distance from the anterior extremity of the head to the caudal tail fork) of all fish were measured; the fish ranged from 13-49 cm in total length. Fish were necropsied and all organs and the body were examined macroscopically and microscopically for evidence of parasite infection. Parasite cysts and spores were examined in wet mount specimens. The spores were measured with an eyepiece micrometer. All measurements are presented in

$\mu\text{m}$  as the mean  $\pm$  SD followed by the range (in parentheses). For permanent preparation infected material was fixed with absolute methanol and stained with Giemsa. Descriptions of myxosporidia were made according to LOM & ARTHUR (1989) and LOM & DYKOVÁ (1992).

## RESULTS

The infected specimens of flathead gray mullet (*Mugil cephalus*) presented whitish myxosporidian cystic masses, measuring approximately 5-7 mm in length, on their bodies (Fig. 1). The cystic masses were distributed over the entire body and covered 10 to 70% of the body. They were located on the distal part of the scales and also affected the fins causing malformations. Each cyst mass was ovoid, containing numerous spores.

The spores (Fig. 2) were pyriform in front view and measured  $8.17 \pm 0.29$  (8-9)  $\mu\text{m}$  in length and  $5.92 \pm 0.21$  (5-6)  $\mu\text{m}$  in width. Each valve presented 7 to 9 markings along the suture wall. The polar capsules were pyriform and extended half of the spore length. They measured  $4.03 \pm 0.14$  (4-4.5)  $\mu\text{m}$  in length and  $2.17 \pm 0.07$  (2-3)  $\mu\text{m}$  in width. The polar filament




Fig. 1. Flathead mullet (*Mugil cephalus*) showing skin lesions (arrows) caused by myxosporidian *Myxobolus episquamalis* (scale bar = 2.5 cm)

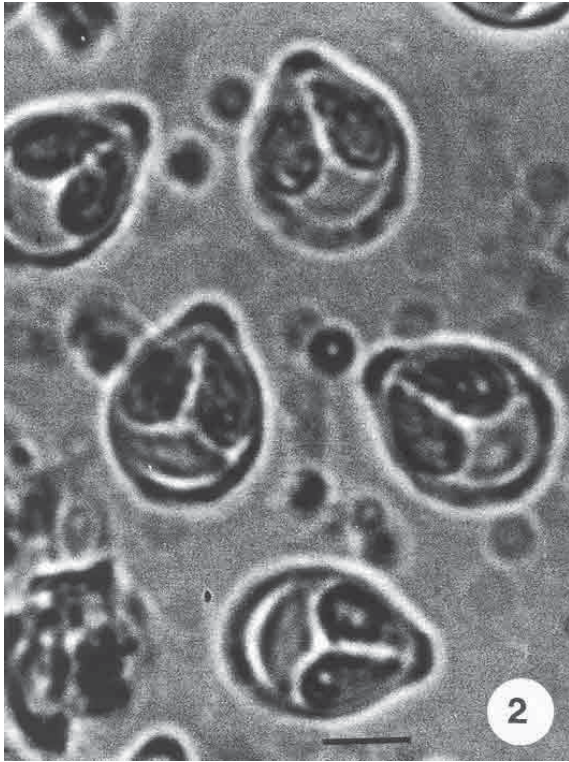


Fig. 2. Fresh smear of *M. episquamalis* spores (scale bar = 4 $\mu$ m)

formed 5 or 6 coils inside the polar capsule. The sporoplasm is binucleate, occupying the posterior part of the spore.

The overall prevalence rate of infection was 4.7% (25/529). The parasite was detected in 9 of 14 months of sampling (Fig. 3). The highest infection rates were observed in January 2006 (17.1%) and July 2006 (13.9%).

## DISCUSSION

The presented myxosporidian species found in *Mugil cephalus* from the Senegalese coast are identified as *Myxobolus episquamalis*, as reported by EGUSA *et al.*, 1990. All characteristics described by these authors coincide with those of the present work: same host species, same sites of infection, same lesions and same shape and size of spores. LOM & DYKOVA, 1994 as well as FALL *et al.*, 1997 considered *Myxobolus episquamalis* as a junior synonym of *Myxobolus exiguus* although BAHRI *et al.* (2003), based on DNA sequence data, confirmed the difference

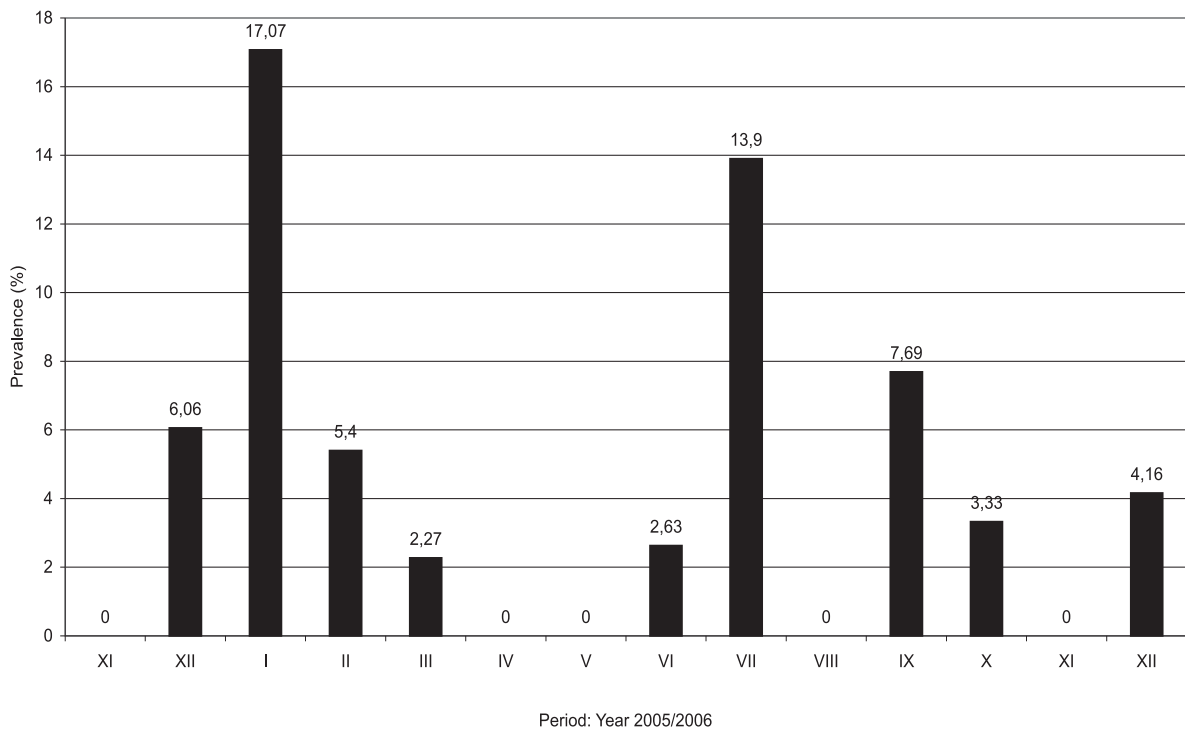


Fig. 3 Monthly prevalence of *M. episquamalis* infection in *M. cephalus* from Senegalese coast

between the two species. The two species also differ by the nature of their host tissue. Indeed, the sites of infection for *M. exiguus* are the connective and epithelial tissues of the gills, intestine and liver while those of *M. episquamalis* are the epithelial tissues of the scales and the fin (FALL *et al.*, 1997; BAHRI *et al.*, 2003).

The presence of *M. episquamalis* on African Atlantic coast off Senegal extends considerably its geographical distribution. This parasite is now known in six widely separated countries: Israel, Portugal, Japan, Tunisia, Australia and Senegal (OVERSTREET & HOWSE, 1977; MENEZES, 1984; EGUSA *et al.*, 1990; BAHRI *et al.*, 1995, 1996, 2003; ROTHWELL *et al.*, 1997).

The infection observed in Senegal is of little commercial importance because the prevalence of infection is low. However, the regular presence of this parasite in the populations of *M. cephalus* is harmful to skin functions and to the health of these fish and, if favourable conditions occur, it may provide the source from which an epizootic could erupt.

## ACKNOWLEDGMENTS

The authors would like to thank KHALED BIN SULTAN LIVING OCEANS FOUNDATION for the financial assistance in making this work possible.

## REFERENCES

- BAHRI, S., A. MARQUES, F. COSTE, G. BOUIX & O.K. BEN HASSINE. 1995. Presence of cutaneous myxosporidian in tunisian *Mugil cephalus* (Linnaeus, 1758). *Bul. Europ. Ass. Fish Pathol.*, 15: 54-57.
- BAHRI, S. & A. MARQUES. 1996. Myxosporean parasites of the genus *Myxobolus* from *Mugil cephalus* in Ichkeul lagoon, Tunisia: description of two new species. *Dis. Aquat. Org.*, 27: 115-122.
- BAHRI, S., K.B. ANDREE & R.P. HEDRICK. 2003. Morphological and phylogenetic studies of marine *Myxobolus* spp. From mullet in Ichkeul Lake, Tunisia. *J. Eukaryot. Microbiol.*, 50: 463-470.
- EGUSA, S., Y. MAENO & M. SORIMACHI. 1990. A new species of Myxozoa, *Myxobolus episquamalis* sp. nov. infecting scales of the mullet. *Fish Pathol.*, 25: 87-91.
- FALL, M., T.K. KPATCHA, C. DIEBAKATÉ, N. FAYE & B.S. TOGUEBAYE. 1997. Observations sur des Myxosporidies (Myxozoa) du genre *Myxobolus* parasites de *Mugil cephalus* (Poisson, Téléostéen) du Sénégal (Observations on Myxosporidia (Myxozoa), *Myxobolus* parasites in *Mugil cephalus* (Pisces, Teleost)). *Parasite*, 2: 173-180.
- IVERSEN, E.S., N. CHETTY & N. VAN METER. 1971. Some myxosporida from marine fishes in South Florida. *J. Protozool.*, 18: 82-86.
- KUDO, R. 1919. Studies on Myxosporidia. A synopsis of genera and species of Myxosporidia. Illinois Biological Monographs 5, 265 pp.
- LANDSBERG, J.H. & J. LOM. 1991. Taxonomy of the genera of Myxobolus/Myxosoma group (Myxobolidae: Myxosporidia), current listing of species and revision of synonyms. *Syst. Parasitol.*, 18: 165-186.
- LOM, J. & J.R. ARTHUR. 1989. A guideline for the preparation of species descriptions in Myxosporidia. *J. Fish Dis.*, 12: 151-156.
- LOM, J. & I. DYKOVÁ. 1992. Protozoan Parasites of Fishes. Development in Aquaculture and Fisheries Sciences, 26. Elsevier, Amsterdam, 315 pp.
- LOM, J. & I. DYKOVÁ. 1994. Studies on protozoan parasites of Australian fishes. III. Species of the genus *Myxobolus* Bütschli, 1882. *J. Protistol.*, 30: 431-439.
- MAENO, Y., M. SORMACHI, K. AGAWA & S. EGUSA. 1990. *Myxobolus spinacurvatura* sp. N. (Myxosporidia: Bivalvalida) parasitic in deformed mullet, *Mugil cephalus*. *Fish Pathol.*, 25: 37-41.
- MENEZES, J. 1984. A case of massive cutaneous myxoboliosis in wild mullet. *Bol. Inst. Nac. Invest. Pesca*, 12: 71-72.
- OVERSTREET, R.M. & H.D. HOWSE. 1977. Some parasites and diseases of estuarine fishes



- in polluted habitats of Mississippi. Ann. N. Y. Acad. Sci., 298: 427-462.
- ROTHWELL, J.T., J.L.VIRGONA, R.B. CALLINAN, P.J. NICHOLLS & S. LANGDON. 1997. Occurrence of cutaneous infections of *Myxobolus episquamalis* (Myxozoa, Myxobolidae) in sea mullet *Mugil cephalus* L, in Australia. Aust. Vet. J., 75: 349-352.
- SCHULMAN, S.S. 1966. Myxosporidian fauna from USSR (In Russian). Nauka: Moscow-Leningrad, 504 pp.

Received: 11 September 2007

Accepted: 23 December 2007

## **Pronalazak nametnika *Myxobolus episquamalis* (Myxozoa, Myxobolidae) kod cipla glavaša, *Mugil cephalus* (Pisces, Teleostei, Mugilidae) u Senegalskom priobalju (istočni tropski Atlantik)**

Arfang DIAMANKA, Malick FALL, Cheikhna DIEBAKATE, Ngor FAYE  
i Bhen Sikina TOGUEBAYE \*

*Laboratorij parazitologije i Laboratorij patologije vodenih životinja*  
- *Fondacija Khaled Bin Sultan, Odsjek biologije životinja, Fakultet znanosti i tehnologije,*  
*Sveučilište Cheikh Anta DIOP u Dakaru, Dakar, Senegal*

\* *Kontakt adresa, e-mail: parasito@refer.sn*

### **SAŽETAK**

*Myxobolus episquamalis* (Myxozoa, Myxobolidae), mikrosporidijski nametnik, pronađen je po prvi put u cipla glavaša (*Mugil cephalus*) u senegalskom priobalju. Sveukupna prevalencija infekcije iznosila je 4.7% (25/529), dok je najveća stopa infekcije zabilježena u siječnju (17.1%) i srpnju (13.9%) 2006 godine. Ovaj nametnik stvara velike bijele ciste koje pokrivaju veliki dio tijela ribe. Prema ovom nalazu s afričke obale Atlantika, njegova zemljopisna rasprostranjenost je znatna. Ipak, infekcija nema veći gospodarski značaj tj. ne uzrokuje značajan ekonomski gubitak u ribarstvu Senegala.

**Ključne riječi:** Myxosporidia, *Myxobolus episquamalis*, *Mugil cephalus*, kožna infekcija, Senegal

