

Elif Bahar Tuna¹, Gulsum Ak², Koray Gencay¹

Ameloblastični fibrom: prikaz slučaja s petogodišnjem praćenjem

Ameloblastic Fibroma: A Case Report With Five Years Follow-Up

¹ Zavod za dječju stomatologiju, Stomatološki fakultet Sveučilište Capa Istanbul
Department of Pedodontics, Faculty of Dentistry Istanbul University, Capa Istanbul

² Zavod za oralnu kirurgiju i medicinu, Stomatološki fakultet Sveučilište Capa Istanbul
Department of Oral Surgery and Medicine, Faculty of Dentistry Istanbul University, Capa Istanbul

Sažetak

Svrha ovog rada bila je opisati rijedak slučaj dugo praćenoga ameloblastičnog fibroma (AF-a) na atipičnoj lokalizaciji. Ameloblastični fibrom dosta je rijedak benigni miješani odontogeni tumor koji se vrlo rijetko može naći u prednjoj regiji gornje čeljusti. Čini samo 1 do 2 posto svih odontogenih tumora i češći je kod muškaraca negoli kod žena. Češći je u donjoj čeljusti negoli u gornjoj. Većina ameloblastičnih fibroma nalazi se u stražnjem području donje čeljusti, bezbolni su, sporo rastu i uglavnom su asimptomatski, ali mogu proširiti čeljust. Prikaz slučaja: trogodišnja djevojčica bila se žalila na bezbolnu oteklinu u području desne gornje čeljusti. Radiološka pretraga pokazala je dobro ograničenu, veliku leziju. Prema histopatološkim nalazima, dijagnosticirana je kao ameloblastični fibrom. Liječena je enukleacijom te nije bio uočen recidiv na kontrolnom pregledu nakon pet godina. Nakon toga razdoblja radiološke snimke pokazale su da se kirurški defekt ispunio novom kosti. Konzervativni pristup, uključujući enukleaciju i mehaničku kiretažu okolnog tkiva, pokazao se uspješnim za pacijenta. Iako je recidiv ameloblastičnog fibroma rijedak, redoviti pregledi – kako bi se pratio rast i razvoj - potrebni su zbog velike mogućnosti recidiva.

Zaprimljen: 27. siječanj 2008.
Prihvaćen: 16. travanj 2008.

Adresa za dopisivanje

Dr. Elif Bahar Tuna
Sveučilište Capa, Istanbul
Stomatološki fakultet
Zavod za dječju stomatologiju
34093 Istanbul, Turkey
ebtuna@istanbul.edu.tr

Ključne riječi

ameloblastični fibrom; gornja čeljust;
rijedak; prikaz slučaja; odontogeni
tumori

Uvod

Ameloblastični fibrom (AF) rijedak je benigni miješani tumor odontogenoga podrijetla, a svojstvena mu je proliferacija odontogenog epitela i mezenhinskog tkiva cakline, dentina ili drugih kalcificiranih zubnih struktura (1-5). Čini samo 1 do 2 posto svih odontogenih tumora (1,4 -6), a javlja se u dva oblika: zrnato staničnom (histopatološki oblik) i perifernom (klinički oblik) (7,8). Ako je u leziji i dentin sa caklinskom formacijom ili bez nje, može se također nazvati ameloblastični fibrodentom (AFD) ili ameloblastični fibroodontom (AFO) (9).

Introduction

The Ameloblastic Fibroma (AF) is a rare benign mixed tumour of odontogenic origin characterized by the proliferation of both odontogenic epithelium and mesenchymal tissue without the formation of enamel, dentine or any calcified dental structures (1-5). It represents only 1-2% of all odontogenic tumours (1,4-6) and there are two forms: granular cell AF (a histopathological variant) and peripheral AF (a clinical variant) (7,8). If the lesion has dentinoid tissue without or with enamel formation, it could be termed as ameloblastic-fibrodentoma (AFD) or ameloblastic-fibroodontoma (AFO) respectively (9).

AF varira prema spolu – neznatno se češće javlja kod muškaraca (1.4:1), negoli kod žena (1,7,8,10). Češće se nalazi u donjoj čeljusti (3.9:1) (2,5,10). Većina AF-a pronalazi se u području kutnjaka u stražnjem dijelu donje čeljusti (5:1) i uglavnom su povezani s neizniknutim ili razmještenim zubima (2,6,8,11). Klinički gledano, tumor raste sporo te bezbolno širi čeljust i pomiče zube. Većinom je asimptomatski, no može se uočiti širenje čeljusti (1,10).

U studijama je navedeno da se AF javlja u dobi od 6 mjeseci do 42 godine, pa je tako prosječna dob 14,6 godina (2,4,7,8,11,12). Zna se za samo nekoliko slučajeva kod osoba mlađih od 5 godina (4,10).

Svrha ovog prikaza bila je opisati klinički slučaj tumora atipične lokalizacije kod trogodišnje djevojčice, a liječnici su ga postoperativno pratili pet godina.

Prikaz slučaja

Trogodišnja djevojčica stigla je na našu kliniku zbog otekline na desnom obrazu koju je imala posljednjih šest mjeseci. Obiteljska i stomatološka anamneza bile su bez osobitosti. Pregledom usne šupljine ustanovili smo potpunu mliječnu denticiju i tvrdi oteklinu na bukalnoj strani gornje čeljusti u području očnjaka i pretkutnjaka (Slika 1.).

Nije bilo ni znakova infekcije, ni povećanih limfnih čvorova na vratu. Panoramska i okluzalna radiološka snimka pokazale su dobro ograničenu, veliku i prozračnu unilokularnu leziju na desnoj strani gornje čeljusti i kongenitalni nedostatak desnoga mliječnog očnjaka i drugoga trajnog kutnjaka (Slike 2. i 3.).

Tumor smo uklonili enukleacijom i kiretažom koštanog ležišta te izvadili prvi mliječni kutnjak. Lezija je bila obavljena ovojnicom koju smo pažljivo izrezali. Postoperativni tijek bio je uredan i pacijentica je istoga dana bila otpuštena iz bolnice. Tumor veličine 4,5 x 0,5 x 0,5 cm bio je povezan s neizniknutim prvim kutnjakom i očnjakom.

Histopatološkom analizom dokazani su epitelni i mezenhimni sastavni dijelovi tumora. Epitelni dio sadržavao je ameloblastima slične stanice koje su okruživale satelitsku jezgru i tvorile otočiće ili proliferativna žarišta. Stroma je bila celularna s minimalnim fibromiksoidnim dijelovima i pleomorfizmom s tipičnim manjkom kolagena bez celularne atipije ili mitoze (Slike 4. i 5.). Taj se nalaz slaže s dijagnozom ameloblastičnog fibroma.

The sex predilection varies from no preference to males slightly more frequently affected than females (1.4:1) (1,7,8,10). It presents more frequently in the mandible than in the maxilla (3.9:1) (2,5,10). The majority of AF's are found in the molar (posterior) area of the mandible (5:1) and are often associated with unerupted or displaced teeth (2,6,8,11). Clinically, the tumor grows slowly and painlessly, expanding the jaw and causing teeth migration, usually asymptomatic, but eventually leading to visible jaw expansion.

AF is reported to occur at an age ranging from 6 months to 42 years with an average age of occurrence of approximately 14.6 years (2,4,7,8,11,12). Only a few cases have been reported under 5 years (4,10).

The objective of this presentation is to describe a clinical case of this tumour with an atypical localization in a 3 year-old girl with long term (five years) postoperative follow-up period.

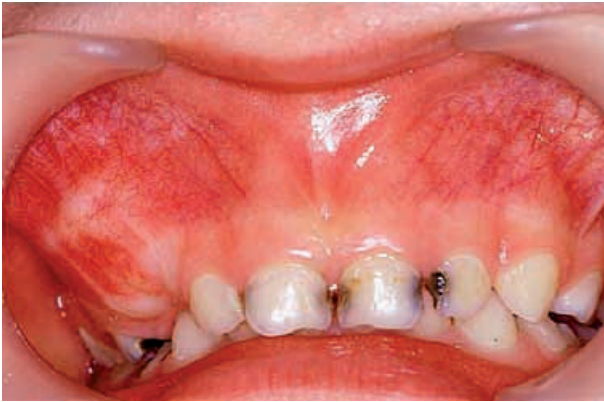Case presentation

A 3 year-old girl was referred to our clinic with a complaint of painless swelling on the right cheek, which had appeared over the previous 6 months. The family past medical and dental histories was uneventful. Intraoral examination revealed the patient had a complete primary dentition and a solid, non-tender swelling on buccal side of maxillary canine and premolar region (Fig. 1).

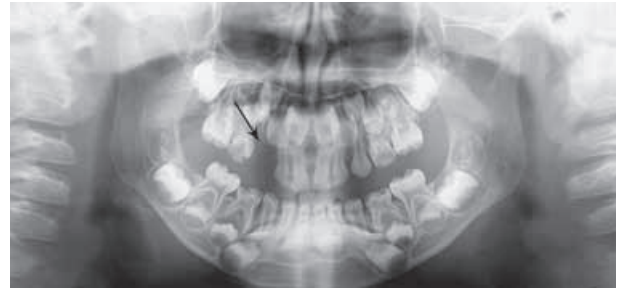No source of infection and no submandibular or cervical lymphadenopathy was evident. Panoramic and occlusal radiograph showed a well-circumscribed large, unilocular radiolucent lesion in the right maxillary region. Radiographic examination also showed that the maxillary right primary canine and permanent second premolar were congenitally absent (Figs. 2 and 3).

Under the general anesthesia the tumour was enucleated via curettage (surgically removed with careful curettage of the bone bed) and the primary first molar teeth were extracted. The lesion was capsulated and easily excised. The postoperative period was uneventful and the patient was discharged from hospital on the same day. The lesion measured 4.5 x 0.5 x 0.5 cm and was associated with unerupted first premolar and canine.

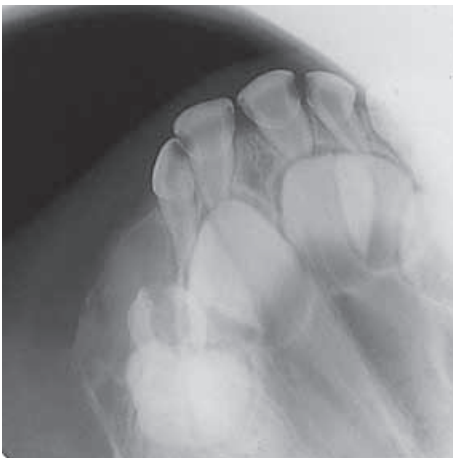
Histopathologic investigation of tissue showed that the tumour had two components, epithelial and mesenchymal. Epithelial part consisted of ameloblast-like cells surrounding a satellite core and formed small islands or cauliflower like proliferations. Stroma was cellular and in some areas fibro-



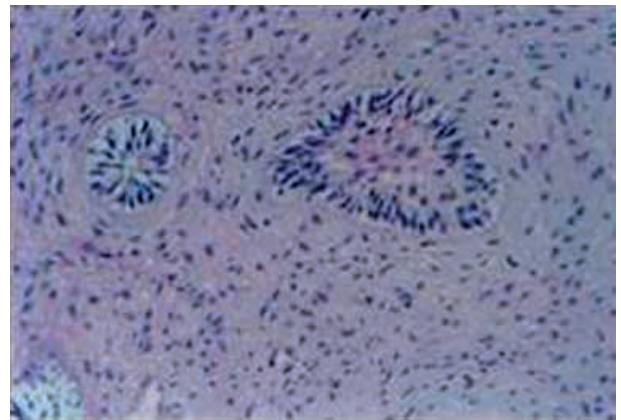
Slika 1. Predoperativna klinička slika – vidi se asimetrija i oteklina na desnoj strani gornje čeljusti
Figure 1 Preoperative clinic appearance showing asymmetry affecting right buccal side (Intraoral view of patient)



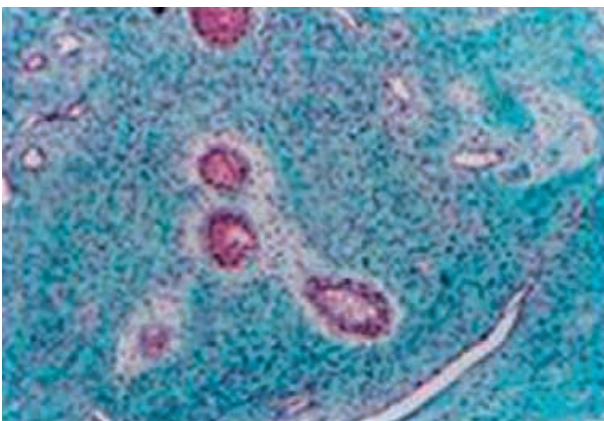
Slika 2. Predoperativni ortopantomogram
Figure 2 Initial panoramic radiograph of patient



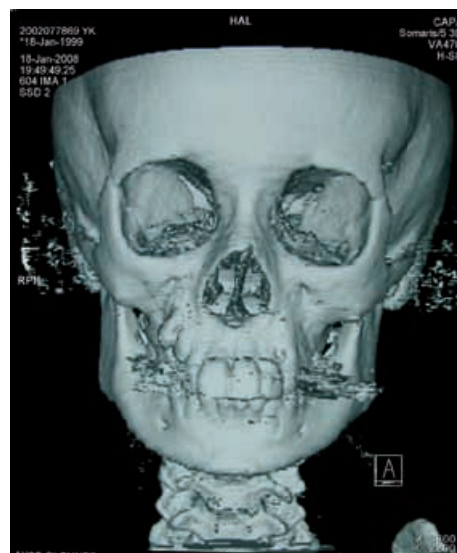
Slika 3. Predoperativna retroalveolarna snimka
Figure 3 Initial occlusal radiograph of patient



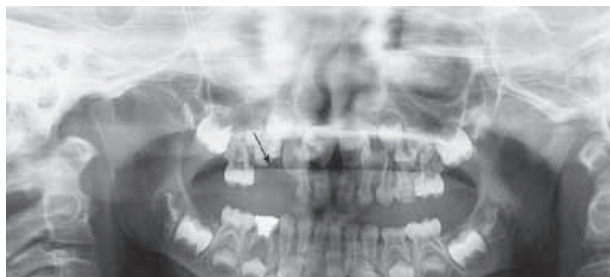Slika 4. Histopatološka nakupina ameloblastima sličnih stanica zaokružena bazalnom membranom u vretenastoj stromi. Nema celularne atipije i mitoze (hematoksilin-eozin, povećanje x 310).
Figure 4 Histopathologic image groups of ameloblast like cells surrounded by a basal membrane in a spindle cell stroma. No cellular atypia nor mitotic figures were assessed (Hematoxylin-eosin stain, original magnification x 310)



Slika 5. Histopatološka slika epitelnih otočića u celularnoj stromi (Masson Trikrom, povećanje x 125)
Figure 5 Histopathologic image of the epithelial islands in a cellular stroma (Masson Trikrom, original magnification x 125)

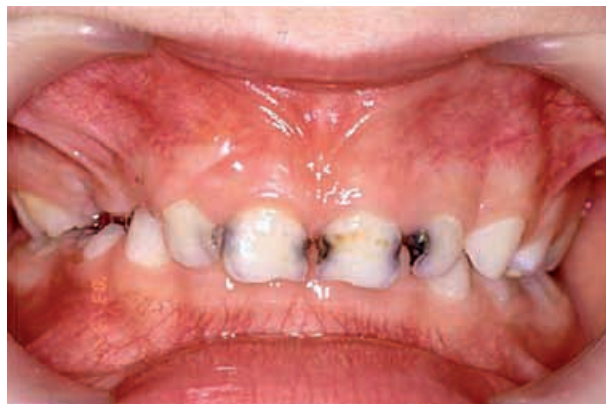

Slika 6. 3D rekonstrukcija pokazuje zubne zametke u kirurškom području
Figure 6 3D reconstruction image showed growing tooth germs at the operation area



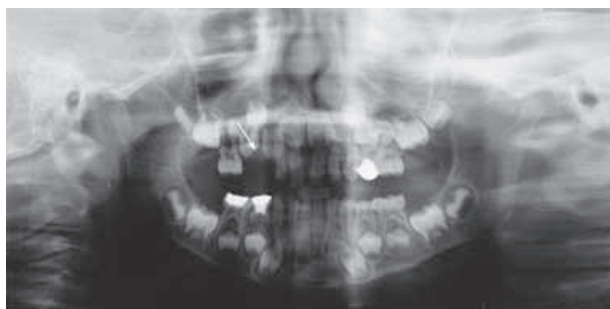Slika 7A. Postoperativna panoramska radiološka snimka šest mjeseci nakon kirurškog postupka

Figure 7A A postoperative panoramic radiograph take at 6 months after surgery



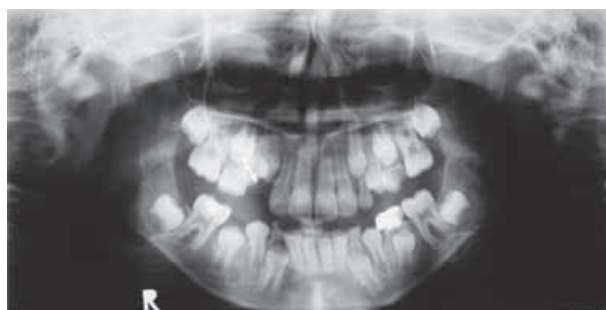Slika 7B. Postoperativni intraoralni izgled pacijenta šest mjeseci nakon kirurškog postupka

Figure 7B Postoperative intraoral view 6 months after surgery



Slika 8. Postoperativna panoramska radiološka snimka – nema dokaza o recidivu dvije godine nakon kirurškog postupka.

Figure 8 A postoperative panoramic radiograph showing no evidence of recurrence 2 years after surgery



Slika 9. Ortopantomogram pokazuje novostvorenu kost u defektu nakon pet godina

Figure 9 Panoramic radiograph showing that surgical defect filled with new bone after 5 years

Nakon šest mjeseci kod pacijentice se obnovila kost u operiranom području, a nakon pet godina nije bilo znakova recidiva. Rekonstrukcija 3D pokazala je da su sve koštane strukture u normalnim granicama (Slika 6.). Prvi trajni pretkutnjak počeo joj je nicati, a uočen je na kontrolnoj panoramskoj snimci nakon pet godina (Slike 7, 8 i 9).

Rasprava

Odontogeni tumori su rijetke lezije, a nastaju iz specijaliziranoga zubnog tkiva (7,12). Ameloblastični fibrom se u 80 do 90 posto slučajeva nalazi u donjoj čeljusti, često u području kutnjaka (4,11). Gornja je čeljust rijetko zahvaćena - samo 12 po-

myxoid and pleomorphism was minimal. There was typical absence of collagen without cellular atypia or mitosis (Figs. 4 and 5). These findings are consistent with a diagnosis of AF.

After 6 months to allow bone regeneration in the region, the patient had no signs of recurrence after 5 years. Panoramic and occlusal radiographs showed that the surgical defect had filled with new bone after surgical operation. 3D reconstruction image showed that all bone structure was within normal limits (Figure 6). The permanent first premolar tooth eruption started spontaneously through the maxillary arch after 5 years follow up panoramic radiograph (Figs. 7, 8 and 9).

Discussion

Odontogenic tumours are uncommon lesions derived from specialized dental tissues (7,12). AF occurs in the mandible in approximately 80-90% of cases, usually being located in the molar region (4,11). The maxilla is also uncommonly affected,

sto (10), te je opisano samo nekoliko tumora u prednjem dijelu gornje čeljusti (2,4). Prva klinička slika najčešće je slučajno otkrivena oteklina, često asimptomatska i to tijekom rutinskoga radiološkog pregleda (1,2,4,8).

AF je rijetka neoplazma i varira od male unilokularne lezije do velike multilokularne (5,7). Opisano je samo nekoliko slučajeva takve oteklina kod djece u dobi od četiri do sedam godina (11,13,14). Girdler i Edwards (11) tvrde da je opisani tumor bio neobično velik za dob pacijentice. Moramo reći da smo sličnu, neobično veliku leziju na gornjoj čeljusti, našli i kod trogodišnje djevojčice.

Radiološki je AF potpuno prozirna i dobro ograničena lezija (15). Može biti unilokularna ili multilokularna, najčešće s dobro izraženom, često sklerotičnom granicom te se može dogoditi da je povezana s neizniknutim ili razmaknutim zubima (1,3,5,7,8,16). Teško ju je razlikovati od drugih mnogobrojnih cista i tumora. Diferencijalno dijagnostički u obzir dolazi ameloblastom, odontogeni miksom, folikularna cista, keratocista, centralni zrnato-stanični tumor i histocitoza (11,15,16). Ameloblastični zrnato-stanični fibrom također je građen od odontogenog epitela i mezenhinskog tkiva. Lezija se pretežno javlja kod starijih bolesnika te bi se trebala dosta lagano razlikovati od AF-a (5). AF sporije raste od ameloblastoma i manje je infiltrativan. Zato je to tumor koji sporo raste i proširuje kost te ima glatke (ravne) rubove (5,6,7).

Bol, osjećaj napetosti i oteklina čeljusti mogu potaknuti pacijenta da zatraži pomoć stomatologa (4). Kod naše je pacijentice oteklina bila glavna tegoba te osnovni klinički nalaz za dijagnozu. Osim toga, tumor je uzrokovao znatnu osteolizu s kongenitalnim nedostatkom mliječnog očnjaka i drugoga trajnog kutnjaka. Premda se tumor obično nalazi u stražnjem dijelu donje čeljusti, kod naše je pacijentice bio na neuobičajenom mjestu s obzirom na dob i spol.

AF se obično smatra enkapsuliranim tumorom i zato je enukleacija čest izbor u postupku kirurškoga liječenja (5,7). Općenito, opisano liječenje je više nego konzervativno, a postoje i proturječni podatci u literaturi o tome koliko su česti recidivi (5). Konzervativno kirurško liječenje ekscizijom, a zatim kiretažom čini se kao prikladan izbor (15). Veliki tumori morali bi se liječiti radikalnije. Neki su autori predložili blok-resekciju kosti sa zdravim rubom od 0,5 do 1 centimetra. Zallen i njegovi suradnici (17) kod većih su lezija pristaše radikalnijeg liječenja od enukleacije te preporučuju modificira-

comprising 12% of cases (10). Only a few tumours have been reported in the anterior maxillar region (2,4). Its initial clinical presentation is most often swelling, however it is not uncommonly asymptomatic, being found accidentally on routine radiographic examination (1,2,4,8).

AF is an uncommon neoplasm and varies from a small unilocular radiolucency to a large multilocular lesion as reported in the earlier literature (5,7). There have been a few reported cases of AF in children. Unusual presentations include an AF in a 5-year-old boy by Chen et al (13), cystic AF in a 7-year-old boy described by Meyers et al (14), and Girdler and Edwards (11) reported a 4-year-old boy diagnosed with AF on the maxilla. Girdler and Edwards (11) state that tumour was also unusually large relative to the patient's age. Similarly, we also found unusually large lesion on the maxillar area in a 3-year-old girl. However, such a large lesion rarely occurs in children.

Radiologically, the AF is a totally radiolucent and well-rounded lesion (15). It may be an uni or multi-locular, radiolucent lesion, usually with well-defined, often sclerotic border and may be found in association with unerupted or displacement teeth (1,3,5,7,8,16).

The radiographic appearance of AF may be identical to that of numerous other cysts and tumours. The main differential diagnosis of the AF must be made with lesions such as the ameloblastoma, odontogenic myxoma, dentigerous and keratocysts, central granular cell tumour and histiocytosis (11,15,16). Ameloblastic granular cell fibroma also consist of odontogenic epithelium and mesenchymal tissue. This lesion occurs mainly in older patients, it should be relatively easy to distinguish from AF (5), AF has a slower growth rate than ameloblastoma and is less infiltrative. This results in a slow growing tumour that may expand bone and have smooth borders (5,6,8).

Pain, tenderness, swelling of the jaw may prompt the patient to seek relief from a dentist (4). In our patient the maxillar swelling was the chief complaint and principal clinical finding for the diagnosis. In addition, the lesion caused a considerable developmental defect with congenital absence of maxillar right primary canine and permanent second molar teeth. Although the tumor localization is commonly on the mandible and molar area, our patient has uncommon findings about tumour localization and also age and sex.

AF has classically been considered an encapsulated tumour, therefore surgical removal or enu-

nu blok-resekciju kosti. Drugi autori daju prednost enukleaciji te predlažu redovite preglede (5,7). Zallen i njegovi kolege (17) istaknuli su u svojoj studiji kumulativnu stopu recidiva tumora od 18,3 posto. Dodali su da je zbog visoke stope lokalnog recidiva moguća maligna transformacija (16). Teško je objasniti ta stajališta, jer nepotpuna kirurška ekscizija može biti glavni razlog za recidiv tumora (5,8).

Suprotno tome, Dallera i suradnici (5) istaknuli su konzervativni pristup, posebice kod djece, zbog reaktivnog stvaranja kosti, što je odgovor na rast tumora te omogućuje da se pažljivo ukloni tumorska masa. U opisanom slučaju primijenili smo taj postupak, tj. enukleaciju i kiretažu okolne kosti.

Chen i suradnici (13) nedavno su dokumentirali 13 slučajeva AF-a kod bolesnika u Kini. Kod četvero je tumor recidivirao (36,4%), a malignu transformaciju pronašli su u dva od četiri slučaja ponovne bolesti. U literaturi se navodi da je kumulativna stopa recidiva AF-a oko 20 posto (3,7,18). To može biti rezultat nepotpunog uklanjanja, pa neki autori preporučuju radikalniji kirurški zahvat (7,9,11,15,18). Te spoznaje ističu koliko je važna temeljita procjena zuba koji nisu izniknuli u razumnom roku (2).

Suprotno radikalnom kirurškom liječenju, kod naše pacijentice prikazali smo konzervativniji pristup - enukleaciju s kiretažom okolne kosti zbog dobi bolesnice i trajnih zametaka u perioperacijskom području, što je u skladu s preporukama u literaturi (5, 7, 19). Kobayashi i suradnici (20) zaključili su da bi znanje o malignom potencijalu ameloblastičnog fibroma trebalo pomoći u odabiru načina kirurškog liječenja inicijalnog tumora, što bi moglo spriječiti malignu transformaciju.

Premda lezije mogu u razdoblju dijagnoze biti dosta velike, stopa recidiva razmjerno je niska ako se otekline pažljivo enukleiraju. Bolesnicu smo klinički i radiološki pratili pet godina svakih šest mjeseci, ponajprije zbog mogućega recidiva. Nicanje trajnih zuba bilo je uobičajeno i dosad nije bilo funkcijskih i estetskih problema. Zbog rezultata našeg liječenja ističemo važnost takvog pristupa, posebice kod djece.

enucleation is recommended for treatment (5,7). The generally described treatment is rather than conservative, but there are conflicting data in the literature on the recurrence rate (5). Surgical conservative treatment with excision followed by curettage seems to be the most appropriate therapeutic option (15). Large tumours may have to be treated more radically. Some authors have suggested a block resection with a security margin of 0.5-1 cm should be made when the lesion is small. Zallen et al (17) advocates a more radical treatment (surgical enucleation) as the modified block resection when the lesion is big. Other authors prefer surgical enucleation in every case, and regular examinations (5,7). Zallen et al (17) found a cumulative recurrence rate of 18.3%. The possibility of malignant transformation was reported (16) because of high rate of local recurrence rate. The main reason for recurrence may be incomplete surgical excision (5,8).

On the contrary, Dallera et al (5) emphasized conservative approach particularly in children due to reactive bone formation as a respond to tumour growth that permitted a careful dissection of the mass. In this presented case, the enucleation and curettage approach of surrounding bone was taken.

Chen et al (13) documented 13 AF cases in Chinese patients recently. They found that four patients (36.4%) had recurrences and malignant transformation was identified in two of the four recurrent tumours (13). Cumulative recurrence rate have been indicated in approximately 20% for AF's (3,7,18). Such recurrences may result from incomplete initial removal and some surgeons recommend more aggressive surgical excision (7,9,11,15,18). It has strengthened the importance of thoroughly evaluating unerupted teeth within a reasonable period of time (2). In contrast to radical surgical therapy, in the case presented here we performed a more conservative approach, that is intraoral enucleation and mechanical curettage of the surrounding bone, because of patient's age and presence of permanent tooth germs on the affected region. Dallera et al (5), Vallejo et al (7) and Monteil et al (19), emphasize the validity of conservative approaches especially in young patients, and we support these authors due to our patient's age and tumour localization. Kobayashi et al (20) conclude that knowledge of the malignant potential of AF will assist in determining the management of initial tumours and may prevent malignant formation.

Although the lesions can be quite extensive at the time of diagnosis, the recurrence rate appears to

be relatively low if the lesions are meticulously enucleated. We monitored our patient in six months intervals clinically and radiologically during 5 years without any suspicion of recurrence. Examinations revealed no residual or recurrent disease on the right maxillar area. The eruption potential of permanent teeth was within normal limits and there were no functional and esthetical problems mentioned by the patient so far. The results of treatment emphasize the validity of this approach particularly in children. Clinically, eruption, unerupted and malpositioned teeth should be evaluated carefully. Although recurrence of AF is not rare, very accurate histopathological examination, a conservative surgical approach, long-term postoperative follow up examinations and regular reviews to monitor growth and development are essential and required in these cases.

Abstract

The purpose of this article is to describe a rare case of Ameloblastic Fibroma (AF) with atypical localization with long term follow-up period. The AF is a relatively rare benign mixed odontogenic tumour, which is extremely uncommon in the anterior maxillary region. It represents only 1-2% of all odontogenic tumors and males are slightly more frequently affected than females. It presents more frequently in the mandible than maxilla. The majority of AF's are found in the posterior area of the mandible and painless, slow growing and usually asymptomatic but eventually expand the jaw. A 3 year-old girl with a chief complaint of painless swelling on the right maxillar area. Radiological evaluation revealed a well-circumscribed large lesion. The lesion was diagnosed as AF according to the histopathological findings. She was treated by enucleation with no recurrence observed after a follow-up period of 5 years. After five years, radiographs showed that the surgical defect had filled with new bone. A conservative approach, including enucleation and mechanical curettage of the surrounding tissue appeared to be successful for the patient. Although recurrence of AF is rare, regular reviews to monitor growth and development are required for the high potential of recurrence rates.

Received: January 27, 2008

Accepted: April 16, 2008

Address for correspondence

Dr. Elif Bahar Tuna
Istanbul University
Faculty of Dentistry
Department of Pedodontics
Capa Istanbul, 34093 Istanbul, Turkey
ebtuna@istanbul.edu.tr

Key words

Ameloblastic Fibroma; Maxilla; Unusual; Case Report; Odontogenic Tumors

References

- Bhaskar SN. Synopsis of oral pathology. 7th ed. St. Louis: C.V. Mosby Company; 1986.
- Hering WW. Ameloblastic fibroma in the anterior maxilla: report of case. ASDC J Dent Child. 1978;45(5):408-11.
- Philipsen HP, Reichart PA, Praetorius F. Mixed odontogenic tumours and odontomas. Considerations on interrelationship. Review of the literature and presentation of 134 new cases of odontomas. Oral Oncol. 1997;33(2):86-99.
- Kim SG, Jang HS. Ameloblastic fibroma: report of a case. J Oral Maxillofac Surg. 2002;60(2):216-8.
- Dallera P, Bertoni F, Marchetti C, Bacchini P, Campobassi A. Ameloblastic fibroma: a follow-up of six cases. Int J Oral Maxillofac Surg. 1996;25(3):199-202.
- Pereira KD, Bennett KM, Elkins TP, Qu Z. Ameloblastic fibroma of the maxillary sinus. Int J Pediatr Otorhinolaryngol. 2004;68(11):1473-7.
- Garcia-Pola Vallejo M, Gonzalez Garcia M, Villalain Alvarez L, Fresno Forcedello M, Lopez-Arranz JS. Ameloblastic fibroma: a case report in a 6 year old. J Clin Pediatr Dent. 2001;25(3):245-8.
- Takeda Y. Ameloblastic fibroma and related lesions: current pathologic concept. Oral Oncol. 1999;35(6):535-40.
- Chen Y, Wang JM, Li TJ. Ameloblastic fibroma: a review of published studies with special reference to its nature and biological behavior. Oral Oncol. 2007;43(10):960-9.
- McGuinness NJ, Faughnan T, Bennani F, Connolly CE. Ameloblastic fibroma of the anterior maxilla presenting as a complication of tooth eruption: a case report. J Orthod. 2001;28(2):115-8.
- Girdler NM, Edwards DM. Ameloblastic fibroma--an unusual case of facial swelling in a young child. Br Dent J. 1990;169(2):57-8.
- Junquera LM, Albertos JM, Floriano P, Calvo N, Santos J. Ameloblastic fibroma: report of two cases. Int J Paediatr Dent. 1995;5(3):181-6.
- Chen Y, Li TJ, Gao Y, Yu SF. Ameloblastic fibroma and related lesions: a clinicopathologic study with reference to their nature and interrelationship. J Oral Pathol Med. 2005;34(10):588-95.
- Meyers AD, Poulson T, Pettigrew J, Clark M. Cystic ameloblastic fibroma. Ear Nose Throat J. 1991;70(10):729-32.
- Martín-Granizo López R, Ortega L, González Corchón MA, Berguer Sández A. Ameloblastic fibroma of the mandible. Report of two cases. Med Oral. 2003;8(2):150-3.
- McDonald JS. Tumors of the oral soft tissues and cysts and tumors of the bone. In: McDonald RE, Avery DR, Dean JA, editors. Dentistry for the child and adolescent. 7th ed. St. Louis: Mosby Inc; 2000. p. 148-73.
- Zallen RD, Preskar MH, McClary SA. Ameloblastic fibroma. J Oral Maxillofac Surg. 1982;40(8):513-7.
- Muller S, Parker DC, Kapadia SB, Budnick SD, Barnes EL. Ameloblastic fibrosarcoma of the jaws. A clinicopathologic and DNA analysis of five cases and review of the literature with discussion of its relationship to ameloblastic fibroma. Oral Surg Oral Med Oral Pathol Radiol Endod. 1995;79(4):469-77.
- Monteil RA, Le Bas V, Favot C, Loubiere R. Stereologic analysis of histologic parameters of a twice-recurrent ameloblastic fibroma. Oral Surg Oral Med Oral Pathol. 1986;61(2):168-72.
- Kobayashi K, Murakami R, Fujii T, Hirano A. Malignant transformation of ameloblastic fibroma to ameloblastic fibrosarcoma: case report and review of the literature. J Craniomaxillofac Surg. 2005;33(5):352-5.