

VETERINARSKI ARHIV 77 (1), 19-27, 2007

## Vitrification of mouse ovaries using ethylene glycol and DMSO as cryoprotectants: histopathological evaluation

Homayoon Babaei<sup>1\*</sup>, Amin Derakhshanfar<sup>2</sup>, and Arash Kheradmand<sup>3</sup>

<sup>1</sup>Department of Clinical Science, Faculty of Veterinary Medicine, Shahid Bahonar University of Kerman, Kerman, Iran

<sup>2</sup>Department of Pathobiology, Faculty of Veterinary Medicine, Shahid Bahonar University of Kerman, Kerman, Iran

<sup>3</sup>School of Veterinary Medicine, Lorestan University, Khorram Abad, Iran

---

**BABAEI, H., A. DERAKHSHANFAR, A. KHERADMAND: Vitrification of mouse ovaries using ethylene glycol and DMSO as cryoprotectants: histopathological evaluation. Vet. arhiv 77, 19-27, 2007.**

### ABSTRACT

Ten, 4- to 6-week-old BALB/c mice were randomly assigned to either control (non-vitrified, n = 5) or treatment (vitrified, n = 5) groups. Ovaries in the vitrified group were frozen sequentially by immersion into two vitrification solutions VS1: 10% ethylene glycol (EG) + 10% DMSO in holding medium (TCM-199 + 20% FBS) and VS2: 20% EG + 20% DMSO in holding medium. After thawing at 37 °C in 1.0 M sucrose, vitrified as well as non-vitrified ovaries were serially sectioned and examined histopathologically. The proportion of atretic follicles between non-vitrified and vitrified samples was significantly different (36.5 vs. 78.9%, P<0.001). No statistical difference due to vitrification was observed for the percentage of small follicles between the two experimental groups. In contrast, the rate of atresia for the growing and antral follicles in the vitrified ovaries was statistically higher than in the non-vitrified group (70.1 vs. 30.6%, P<0.001). Although many antral follicles were atretic following vitrification, sufficient follicles, especially small class, survived. Therefore, vitrification using EG and DMSO is an efficient procedure for cryopreservation of ovaries.

**Key words:** vitrification, ovaries, ethylene glycol, DMSO, mouse

---

\*Contact address:

Assistant Prof. Dr. Homayoon Babaei, Department of Clinical Sciences, Faculty of Veterinary Medicine, Shahid Bahonar University of Kerman, Zip Code: 76169-14111, P.O.Box: 76135-133, Kerman, Iran, Phone: +98 341 3221 450; Phone and Fax: +98 341 3222 047, E-mail: Babaei\_H@mail.uk.ac.ir

## Introduction

The cryopreservation of ovarian tissue is an alternative or supplement to cryopreservation of embryos or oocytes for young female patients suffering from infertility due to iatrogenic loss of ovarian function resulting from chemotherapy and/or radiation therapy (MIGISHIMA et al., 2003). Successful cryopreservation of ovarian tissue was first reported by DEANSELY (1957). Since then, there have been numerous attempts to cryopreserve whole or partial ovaries of several species, such as mice (SZTEIN et al., 1998; CANDY et al., 1997), rats (AUBARD et al., 1998), rabbits (DANIEL et al., 1983), cattle (DANIEL and JUNEJA, 1987) and sheep (GODSEN et al., 1994).

Most previous studies on cryopreservation of ovarian tissue employed slow freezing (AUBARD et al., 1998; SZTEIN et al., 1998; CANDY et al., 1997; COX et al., 1996). This is a time-consuming procedure and needs expensive controlled-rate cooling devices. Vitrification is an alternative cryopreservation method that might be effective for organ cryopreservation. Vitrification, a recently developed technique without the use of expensive freezing machines, involves a physical process by which a highly concentrated solution of cryoprotectants solidifies during cooling without formation of ice crystals (NIEMANN, 1991). Although the technical simplicity of vitrification has revolutionized cryopreservation of oocytes and embryos, its application to whole ovaries has been considered to be difficult (MIGISHIMA et al., 2003). To improve the procedure for vitrification of ovaries there are numerous papers which discuss different cryoprotectants (ISACHENKO et al., 2003; MIGISHIMA et al., 2003; SALEHNIA, 2002; SUGIMOTO et al., 2000). On the other hand, few reports have been published about quantitative evaluation of follicles at different classes immediately following vitrification-warming of whole ovarian tissue. Therefore, the aim of the present study was to evaluate: 1) the efficiency of vitrification solution containing EG and DMSO for cryopreservation of mouse ovaries, and 2) qualitative and quantitative evaluation of different follicular classes following vitrification.

## Materials and methods

*Materials.* Chemicals were purchased from Sigma-Aldrich Company (St. Louis, MO, USA) unless otherwise indicated.

*Animals.* All animals were cared for and utilised in accordance with the International Guiding Principle for Biomedical Research Involving Animals at Kerman University of Medical Science. The mice were housed under a lighting regimen of 12 h light to 12 h dark and temperature-controlled conditions ( $22 \pm 2$  °C). Food and water were available *ad libitum* at all times. Ten 4-6-week-old mice were used in this study.

*Ovary recovery.* The mice (n = 10) were randomly assigned to either control (non-vitrified ovaries, n = 5) or treatment (vitrified ovaries, n = 5) groups. The animals were

superovulated with 10 i.u. PMSG (Folligon<sup>®</sup>, Intervet) and 48 h later the mice were killed by cervical dislocation. The ovaries collected from the control mice were placed directly into the formalin, while ovaries collected from treatment mice underwent vitrification procedure and were then fixed for histopathological evaluation.

*Vitrification and thawing of ovaries.* We modified the simple and efficient vitrification procedure of VAJTA et al. (1998). The vitrification solution consisted of VS1 (10% EG and 10% DMSO in holding medium (HM: TCM-199 + 20% FBS)) and VS2 (20% EG and 20% DMSO in HM). Briefly, the ovaries were equilibrated in VS1 for 15 m at room temperature, and then in VS2 for 2 m. Each ovary was loaded into plastic straw (outer diameter: 5 mm) with the least volume of vitrification solution at room temperature, followed by plunging directly into liquid nitrogen and stored for at least 7 days. The vitrified samples were thawed rapidly by immersing the end of the tubes into a thawing solution composed of 1.0 M sucrose in HM for 10 m. Temperature of the media used for warming was maintained at 37 °C.

*Histopathological evaluation of ovaries.* The fresh (non-vitrified) and the recovered vitrified ovaries were fixed in 10% buffered formalin, embedded in paraffin wax, serially sectioned at 6 µm, stained with haematoxylin & eosin and analyzed under light microscope. Each ovary yielded approximately 600 sections, and differential follicle counts were gathered from every 10<sup>th</sup> section to provide a 10% sample selection (approximately 60 sections per ovary).

Three ovarian follicle classes (small, growing, antral) were identified in the tissue sections according to THOMAS et al. (1997). Briefly, 'small' follicles consisted of an oocyte surrounded by one unbroken monolayer of granulosa cells. 'Growing' follicles had an oocyte surrounded by a multilayered, solid mantle of granulosa cells. 'Antral' follicles were characterized by a central oocyte encircled by a fluid-filled space and bordered by several layers of granulosa cells. The number of normal and atretic follicles in each follicle class was also recorded. In addition, structural normality (follicle and stromal cell morphology, even distribution of granulosa cells, intact theca and appearance of oocytes) were evaluated.

*Statistical analysis.* Data were analyzed by Pearson's chi-square test.

## Results

The proportion of morphologically normal and atretic follicles in each follicular class was calculated for fresh (non-vitrified) and vitrified ovaries. The proportion of atretic follicles in non-vitrified and vitrified ovaries was significantly different (36.5 vs. 78.6%,  $P < 0.001$ ). As shown in Table 1, no statistical difference due to vitrification was observed for the percentage of small follicles between the non-vitrified and vitrified groups (5.9 vs. 7.6%, respectively). In contrast, the rate of atresia in the growing and antral follicles

was statistically higher in the vitrified group than in the non-vitrified group (70.1 vs. 30.6%,  $P < 0.001$ , respectively). However, the rate of atresia in the antral follicles was much greater in comparison to the growing follicles in vitrified ovaries (53.2 vs. 16.9%, respectively).

Table 1. Effect of vitriification of ovarian tissue on follicle quality in different classes

Treatment group	Total N° of follicles	N° of follicles (%)					
		Atretic					Normal
		S	G	G+A	A	S+G+A	S+G+A
Non-vitrified	679	40 (5.9)	66 (9.7)	208 (30.6)	142 (20.9)	248 (36.5)	431 (63.4)
Vitrified	1143 <sup>a</sup>	87 (7.6)	194* (16.9)	802* (70.1)	608* (53.2)	899* (78.6)	244* (21.3)

S - small; G - growing; A - antral; a - In this row \* indicates significance between two groups.  
\* $P < 0.001$  ( $\chi^2$ -test)

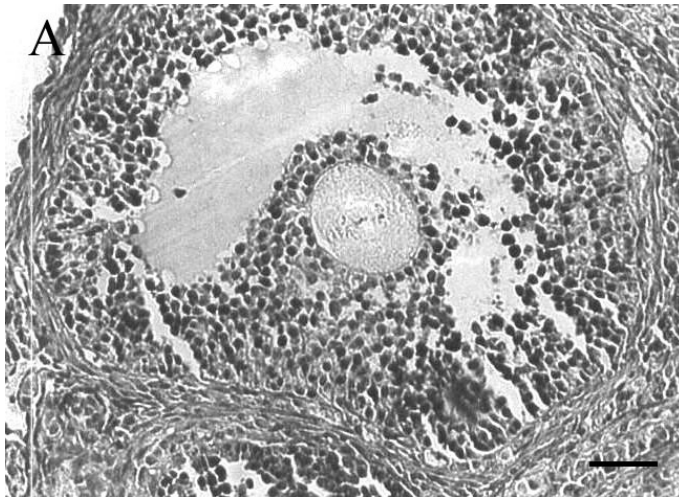


Fig. 1. Non-vitrified, healthy antral follicle. H&E; scale bar = 50  $\mu$ m;  $\times 200$ .

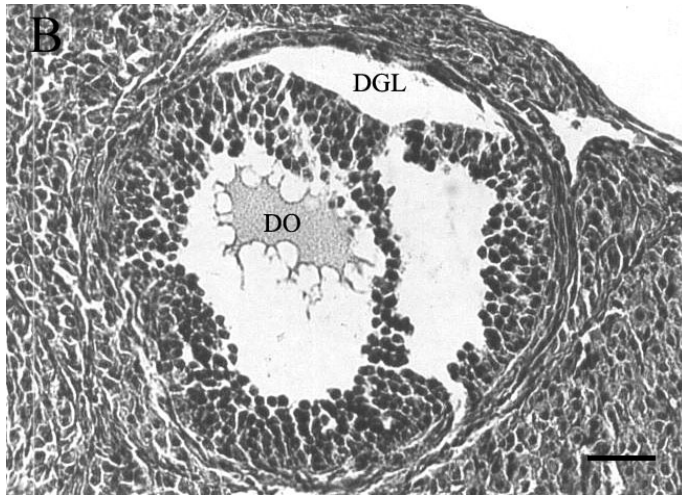


Fig. 2. Typical example of atretic follicle following vitrification (DO, degenerative oocyte; DGL, detachment of granulosa layer). H&E; scale bar = 50  $\mu\text{m}$ ;  $\times 200$ .

Most histopathological features of non-vitrified samples were normal. The cytoplasm of the oocytes was clear and normal, and all granulosa layers and theca interna and externa were intact and firmly attached to the related basement membranes. Stromal cells were normal and with distinct boundaries, prominent nucleus and nucleolus, and pinkish cytoplasm. In contrast, in the most vitrified samples, stromal cells had distinct margins with foamy cytoplasm. Detachment of granulosa layers from the basement membrane and deformity of oocytes were also seen (Fig. 1 and 2).

### Discussion

Development of an efficient method for freezing ovarian tissues to yield high oocyte survival provides an alternative to current procedures for oocyte cryopreservation. Cryopreservation of large tissues and organs becomes problematic in contrast with that of isolated cells (MAZUR et al., 1972). Fixed geometry, high cell density, diversity of cell types and presence of a vascular system are the parameters which can influence the cryostability of tissue (PEGG et al., 1979). In contrast to saturation of isolated cells, saturation of tissues by permeable cryoprotectants requires a lengthy exposure time in cryoprotective solution. It is therefore important to consider the optimal ratios of the equilibration time/toxic effect of cryoprotectant before cooling (PEGG and DIAPER, 1988) as well as the time of removal of cryoprotectant/osmotic injuries after thawing. Toxicity of cryoprotective agents is a key limiting factor in cryobiology (FAHY, 1986).

Cryopreservation by direct plunging into liquid nitrogen requires a pre-treatment of the biological object in media containing a high concentration of permeable cryoprotectants. Ethylene glycol was chosen as a basic permeable cryoprotectant due to its relatively low toxicity (KASAI, 1996). High survival rates of mature or immature mouse oocytes after vitrification using ethylene glycol have been reported (ISACHENKO and NAYUDU, 1999). Furthermore, DMSO was thought to be an effective cryoprotectant for vitrification of mouse oocytes (BOS-MIKICH et al., 1995). We therefore used a combination of EG and DMSO for vitrification of mouse ovaries. The concentrations of EG and DMSO used in the present study were based on those used for the successful vitrification of bovine ova and embryos (VAJTA et al., 1998). The second factor that can potentially decrease the viability of cryopreserved tissues is crystallization at cooling. Acceleration of the speed of temperature changes can help circumvent the problem of crystal formation. Faster rates of cooling and warming can be achieved by minimizing the volume of the solution with which materials are vitrified, i.e. by using open pulled straws (VAJTA et al., 1998), cryoloops (LANE et al., 1999) or electron microscopic grids (MARTINO et al., 1996). In the OPS method, the carriers are narrow plastic tubes (outer diameter: 0.8 mm), but this obviously cannot be used for mouse ovaries. Therefore, we attempted to modify the diameter of the carrier for mouse ovaries.

After vitrification-warming the least damage was observed in the small follicles (Table 1). Primordial follicles have properties that make them less cryosensitive than mature oocytes. So the oocytes and supporting cells are small in size, the tissues have a low metabolic rate, and the cells are at prophase of meiosis I. Furthermore, although there is no zona pellucida, there is a small quantity of cold-sensitive intracellular lipids (SHAW et al., 2000). Histological observation of vitrified ovarian tissues showed significant increase in the proportion of atretic oocytes compared to the non-vitrified group (78.6 vs. 36.5%,  $P < 0.001$ ). The highest rate of damage was related to the antral follicles after vitrification (Table 1). Recently, SUGIMOTO et al., (2000) used the VS1 solution of RALL and FAHY (1985) containing DMSO, propylene glycol, acetamide and EG, observing that rat ovary follicles survived after vitrification and transplantation with about a 50% decrease in number of antral follicles. In many previous studies, viability of cryopreserved ovaries and ovarian tissue was assessed by functional or morphological analysis after transplantation into orthotopic (AUBARD et al., 1998; SZTEIN et al., 1998; COX et al., 1996; GODSEN et al., 1994; DANIEL et al., 1983) or heterotopic sites (CANDY et al., 1997; NEWTON et al., 1996). Transplantation of ovaries following vitrification may decrease such harmful effects of cryopreservation through change in the milieu of follicles (WATERHOUSE et al., 2004) and autorepair of follicles under the control of various tropic factors (OKAMURA et al., 2003). In this study, we did not transplant both vitrified and non-vitrified ovaries, but sufficient follicles survived in comparison to other reports (SZTEIN et al., 1998; COX et al., 1996) relating to transplanted ovaries.

In conclusion, vitrification using EG and DMSO as cryoprotectants is efficient for cryopreservation of small follicles, but similar to the many previous reports the rate of damage to antral follicles is still high. Therefore, further studies are necessary to improve the survival of follicles in the vitrified ovarian tissue.

## References

- AUBARD, H., H. NEWTON, G. SCHEFFER, R. GODSEN (1998): Conservation of the follicular population in irradiated rats by the cryopreservation and orthotopic autografting of ovarian tissue. *Eur. J. Obstet. Gynecol. Reprod. Biol.* 79, 83-87.
- BOS-MIKICH, A., M. J. WOOD, C. J. CANDY, D. G. WHITTINGHAM (1995): Cytogenetical analysis and developmental potential of vitrified mouse oocytes. *Biol. Reprod.* 53, 780-785.
- CANDY, C. J., M. J. WOOD, D. G. WITINGHAM (1997): Effect of cryoprotectants on the survival of follicles in frozen mouse ovaries. *J. Reprod. Fertil.* 110, 11-19.
- COX, S. L., J. SHAW, G. JENKIN (1996): Transplantation of cryopreserved fetal ovarian tissue to adult recipients in mice. *J. Reprod. Fertil.* 107, 315-322.
- DANIEL, J. C. Jr., J. M. FOX, P. RICHARDSON (1983): Return to partial function of rabbit ovaries after cryopreservation in liquid nitrogen. *Theriogenology* 19, 405-412.
- DANIEL, J. C. Jr., S. C. JUNEJA (1987): Cryopreservation of sliced bovine ovaries. *Theriogenology* 27, 220 abstr.
- DEANSELY, R. (1957): Immature rat ovaries grafted after freezing and thawing. *Endocrinol.* 11, 197-200.
- FAHY, G. M. (1986): The relevance of cryoprotectant toxicity to cryobiology. *Cryobiol.* 23, 1-13.
- GODSEN, R. G., D. T. BAIRD, J. C. WADE, R. WEBB (1994): Restoration of fertility to oophorectomized sheep by ovarian autografts stored at -196 °C. *Hum. Reprod.* 9, 597-603.
- KASAI, M. (1996): Simple and efficient method for vitrification of mammalian embryos. *Anim. Reprod. Sci.* 42, 67-75.
- ISACHENKO, E. F., P. L. NAYUDU (1999): Vitrification of mouse germinal vesicle oocytes: effect of treatment temperature and egg yolk on chromatin and spindle normality and cumulus integrity. *Hum. Reprod.* 14, 400-408.
- ISACHENKO, E., V. ISACHENKO, G. RAHIMI, F. NAWROTH (2003): Cryopreservation of human ovarian tissue by direct plunging into liquid nitrogen. *Eur. J. Obstet. Gynecol. Reprod. Biol.* 108, 186-193.
- LANE, M., B. D. BAVISTER, E. A. LYONS, K. T. FOREST (1999): Containerless vitrification of mammalian oocytes and embryos. *Nature Biotechnol.* 17, 1234-1236.
- MARTINO, A., N. SONGSASEN, S. P. LEIBO (1996): Development into blastocysts of bovine oocytes cryopreserved by ultra-rapid cooling. *Biol. Reprod.* 54, 1059-1069.
- MAZUR, P., S. P. LEIBO, E. H. Y. CHU (1972): A two-factor hypothesis of freezing injury. *Exp. Cell. Res.* 71, 345-351.

- MIGISHIMA, F., R. SUZUKI-MIGISHIMA, S. Y. SONG, T. KURAMOCHI, S. AZUMA, M. NISHIJIMA, M. YOKOYAMA (2003): Cryopreservation of mouse ovaries by vitrification. *Biol. Reprod.* 68, 881-887.
- NEWTON, H., Y. AUBARD, A. RUTHERFORD, V. SHARMA, R. GODSEN (1996): Low temperature storage and grafting of human ovarian tissue. *Hum. Reprod.* 11, 1487-1491.
- NIEMANN, H. (1991): Cryopreservation of ova and embryos from livestock: current status and research needs. *Theriogenology* 35, 109-124.
- OKAMURA, H., H. KATABUCHI, T. OHABA (2003): What we have learned from isolated cells from human ovary? *Mol. Cell. Endocrinol.* 202, 37-45.
- PEGG, D. E., I. A. JACOBSEN, W. J. ARMITAGE, M. J. TAYLOR (1979): Mechanisms of cryoinjury in organs. In: *Organ Preservation*. (Pegg, D. E., I. A. Jacobsen, Eds.). Edinburgh, Churchill Livingstone. pp. 132-146.
- PEGG, D. E., M. P. DIAPER (1988): On the mechanism of injury to slowly frozen erythrocytes. *Biophys. J.* 54, 471-488.
- RALL, W. F., G. M. FAHY (1985): Ice-free cryopreservation of mouse embryos at -196 °C by vitrification. *Nature* 313, 573-575.
- SALEHNIA, M. (2002): Autograft of vitrified mouse ovaries using ethylene glycol as cryoprotectant. *Exp. Anim.* 51, 509-512.
- SHAW, J., A. ORANRATNACHAI, A. TROUNSON (2000): Fundamental cryobiology of mammalian oocytes and ovarian tissue. *Theriogenology* 53, 59-72.
- SUGIMOTO, M., S. MAEDA, N. MANABLE, H. MIAMOTO (2000): Development of infantile rat ovaries autotransplanted after cryopreservation by vitrification. *Theriogenology* 53, 1093-1103.
- SZTEIN, J., H. SWEET, J. FARLEY, L. MOBRAATEN (1998): Cryopreservation and orthotopic transplantation of mouse ovaries: new approach in gamete banking. *Biol. Reprod.* 58, 1071-1074.
- THOMAS, J. B., B. BRAD, R. W. ALEN, J. C. JAMES, L. H. JERROLD (1997): Influence of sampling on the reproducibility of ovarian follicle counts in mouse toxicity studies. *Reprod. Toxicol.* 11, 689-696.
- VAJTA, G., P. HOLM, M. KUWAYAMA, P. J. BOOTH, H. JACOBSEN, T. GREVE, H. CALLESEN (1998): Open pulled straw (OPS) vitrification: a new way to reduce cryoinjuries of bovine ova and embryos. *Mol. Reprod. Dev.* 51, 53-58.
- WATERHOUSE, T., S. L. COX, M. SNOW, G. JENKIN, J. SHAW (2004): Offspring produced from heterotopic ovarian allografts in male and female recipient mice. *Reproduction* 127, 689-694.

Received: 4 April 2005

Accepted: 21 December 2006



---

**BABAEI, H., A. DERAKHSHANFAR, A. KHERADMAND: Vitrifikacija mišjih jajnika primjenom krioprotektora etilen glikola i DMSO: patohistološka procjena. Vet. arhiv 77, 19-27, 2007.**

**SAŽETAK**

U istraživanje su uzete dvije skupine BALB/c miševa u dobi od četiri do šest tjedana. Ukupno je bilo 10 miševa podijeljenih u pokusnu (n=5) i kontrolnu skupinu (n=5). Jajnici vitrificirane skupine bili su smrznuti sekvencionirano koristeći se uranjanjem u dvije vitrificacijske otopine. Jedna otopina sadržavala je 10% etilen glikola (EG) + 10% DMSO u mediju za održavanje (TCIM-199 + 20% fetalnoga govedega seruma), a druga otopina sadržavala je 20% EG + 20% DMSO u mediju za održavanje). Nakon odmrzavanja na 37 °C u 1,0 M otopini saharoze, jajnici obje skupine (vitrificirani i nevitificirani) bili su serijski rezani i patohistološki pretraženi. Udio atretičnih folikula između vitrificirane i nevitificirane skupine značajno se razlikovao (36,5 prema 78,9%,  $P < 0,001$ ). Nije ustanovljena statistički značajna razlika s obzirom na vitrifikaciju za udio malih folikula između obje skupine. Suprotno tome, postotak atrezije za rastuće i antralne folikule u vitrificiranim jajnicima bio je značajno veći nego u skupini u kojoj nije provedena vitrifikacija (70,1 prema 30,6%,  $P < 0,001$ ). Usprkos tome što su mnogi antralni folikuli bili atretični nakon vitrifikacije, preživjela je dovoljna količina folikula, osobito malih. Stoga se zaključuje da je vitrifikacija primjenom EG i DMSO učinkovit postupak za čuvanje smrznutih jajnika.

**Ključne riječi:** vitrifikacija, jajnici, etilen glikol, DMSO, miš

---

