

VETERINARSKI ARHIV 77 (2), 167-175, 2007

Clinico-pathological, histochemical and therapeutic studies on concurrent sarcoptic and notoedric acariosis in rabbits (*Oryctolagus cuniculus*)

Mohammed Maqbool Darzi^{1*}, Masood Saleem Mir¹, Rafiq Ahmed Shahardar², and Basharat Ahmed Pandit²

¹Division of Veterinary Pathology, Faculty of Veterinary Sciences and Animal Husbandry, SKUAST-K, Shuhama, Kashmir, India

²Division of Veterinary Parasitology, Faculty of Veterinary Sciences and Animal Husbandry, SKUAST-K, Shuhama, Kashmir, India

DARZI, M. M., M. S. MIR, R. A. SHAHARDAR, B. A. PANDIT: Clinico-pathological, histochemical and therapeutic studies on concurrent sarcoptic and notoedric acariosis in rabbits (*Oryctolagus cuniculus*). Vet. arhiv 77, 167-175, 2007.

ABSTRACT

Concurrent acariosis due to *Sarcoptes scabiei* var *cuniculi* (*Sarcoptes scabiei*) and *Notoedres cati* var *cuniculi* (*Notoedres cuniculi*) was observed in Angora and New Zealand white rabbits belonging to the University rabbitry at Srinagar in Jammu and Kashmir (India). Clinically, the affected rabbits revealed scales, lichenification, scab formation, alopecia and pruritis initially on the face near the upper lip which later extended to the full face, ear pinnae, eyelids and lower jaw, developing into hemorrhagic crusts. Skin scrapings from the affected rabbits revealed both types of mites. Additionally, in one scraping mites of *Cheyletiella* sp. were recognized. Seven of the 35 affected rabbits died of severe mange, histologically showing lesions characterized by hyperkeratosis, acanthosis and subepidermal dermatitis. Staining with toluidine blue showed negative metachromasia, while alcian blue-PAS staining revealed increased acid mucopolysaccharides in epidermis and hair follicles. A single intramuscular dose of doramectin 400 µg decreased the number of mites and their developmental stages with nil concentration in skin scrapings by day 10 post-treatment. Supplemental disinfection of the rabbit cages and house with a blowlamp helped control the acariosis within 3 to 4 weeks.

Key words: rabbit, concurrent acariosis, *Sarcoptes scabiei*, *Notoedres cuniculi*, pathology, histochemistry

Introduction

Mange has become a common and major constraint in rabbit production in India (SINGH and GILL, 1989; RAVINDRAN and SUBRAMANIAM, 2000). The scourge has been

*Contact address:

Dr. Mohammed Maqbool Darzi, Division of Veterinary Pathology, Faculty of Veterinary Sciences and Animal Husbandry, Sher-e-Kashmir University of Agricultural Sciences and Technology of Kashmir, Shuhama, Alusteng, Srinagar- 190 006, Jammu and Kashmir, India, Phone: +91 0194 226 2536; Fax: +91 0194 226 2211; E-mail: darzi_maqbool@rediffmail.com

attributed to two astigmatid mites, *Sarcoptes scabiei* (SAHA and MUKAERJEE, 1998) and *Notoedres cuniculi* (AULAKH et al., 2003). Various ectoparasiticides have been used to control the disease, of which Ivermectin has been successfully used in treatment of acariosis (MBUYA-MIMBANGA and GAMPERL, 1988; WANI et al., 1989; AULAKH et al., 2003).

Concurrent occurrence of these mites in the host does not seem to have been reported. The present study reveals the clinical, histopathological and histochemical changes in skin resulting from simultaneous presence of these two mites on the same hosts - Angora and New Zealand white rabbits in the University rabbitry in Kashmir Valley. Additionally, the study reveals the therapeutic efficacy of doramectin, a genetically engineered avermectin (WALL and SHEARER, 1997), which of late has been used in sheep (SEKIN et al., 1996) and in pigs (JACOBSON et al., 2000).

Materials and methods

An outbreak of acariosis was observed in the University rabbitry in the months April to August 2004. Thirty-five rabbits in a group of 290 maintained in cages showed mange, of which 7 died. Clinical signs, morbidity and mortality were recorded. Deep skin scrapings from the affected areas were collected in 10% KOH and heated to dissolve the debris. After centrifugation the sediment was examined under low and high power of microscopy for presence and identification of mites. Gross lesions in the affected skin were studied on necropsy of the dead rabbits. Tissue specimens were collected in 10% buffered formalin and processed for routine Weigert's haematoxylin and eosin. Duplicated sections were stained with Toluidine Blue to study metachromasia (HUMASON, 1979), with Combined Alcian Blue-PAS technique for acid and neutral mucins (MOWRY, 1956), and compared with normal skin sections. Following confirmation, the affected rabbits were given a single intramuscular dose of doramectin 400 µg kg⁻¹. Concentration of mites, their developmental stages and eggs were studied in a 1 cm² area in the periphery of the lesion pre- and post-treatment on the 5th and 10th days in 10 selected rabbits. Clinical recovery was evaluated on the basis of improvement in clinical signs and disappearance of the mites, as well as their developmental stages in material scraped from the affected areas. Additionally, after removal of rabbits from the house, the cages and the house were disinfected with a blowlamp.

Results

Clinical signs. Thirty-five rabbits (21 Angora and 14 New Zealand whites) of 290 rabbits (12.07%) of both sexes, ranging in age from 7 to 12 months, showed mange. Seven affected rabbits died (20%). The lesion started on the face near the upper lip, later

extending to the full face and lower jaw, and involved ear pinnae, and lips and both eyelids, which were then closed and contained thick whitish exudates (Fig. 1). The affected regions showed scales, lichenification, alopecia and scab formation. The rabbits showed pruritis and were intermittently scratching the area with front paws. Later, hemorrhagic crusts with fissures developed, even becoming eroded in places. The condition of the affected rabbits was weak and body coat was ruffled.

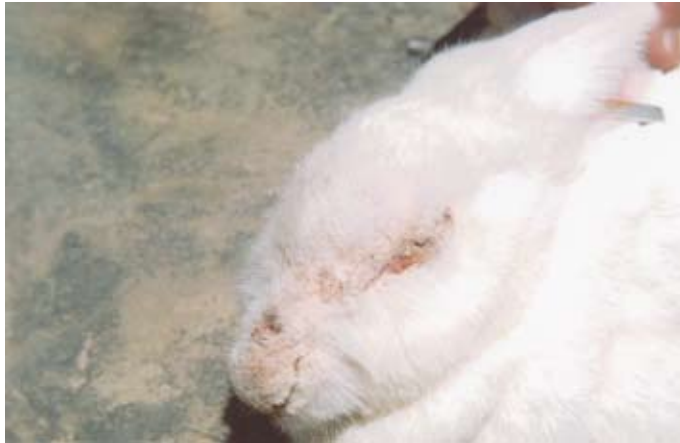

Fig. 1. New Zealand white rabbit affected with concurrent acariosis of face involving upper lip to eyelids, which are closed. The area shows scaly skin and alopecia.

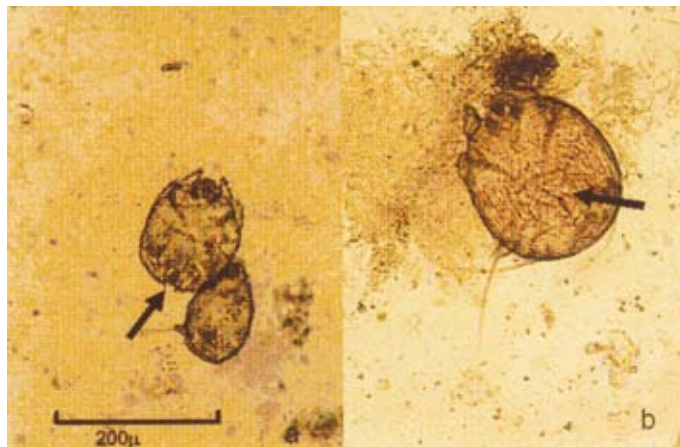


Fig. 2. Skin scraping smear of rabbit showing (a) *Sarcoptes scabiei* var *cuniculi* mite. Note triangular scales on dorsal surface and terminal anus (arrow); (b) *Notoedres cuniculi* having concentric rings and distinct anus on dorsal surface (arrow). Scale bar = 200 µm

Skin scrapings. Scrapings showed presence of mites and their numerous developmental stages. These were identified as *Sarcoptes scabiei* var *cuniculi* (*Sarcoptes scabiei*) (Fig. 2a) and *Notoedres cati* var *cuniculi* (*Notoedres cuniculi*) (Fig. 2b) with predominance of the former. *Sarcoptes scabiei* was identified on the basis of a round body with transverse ridges and triangular scales on dorsal surface and terminal anus. *Notoedres cuniculi* was defined on the basis of having concentric rings (thumbprint-like) on dorsal surface, absence of dorsal scales and distinct dorsal anus. Two mites of *Cheyletiella* sp. were

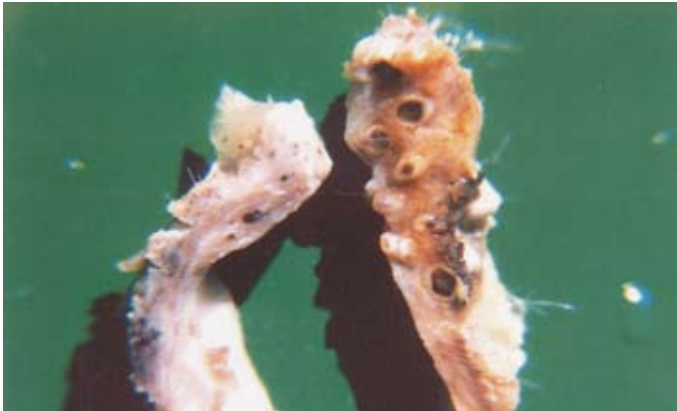

Fig. 3. Cut section of the skin affected with acariosis showing thickening, and dilatation of hair follicles with dark centres

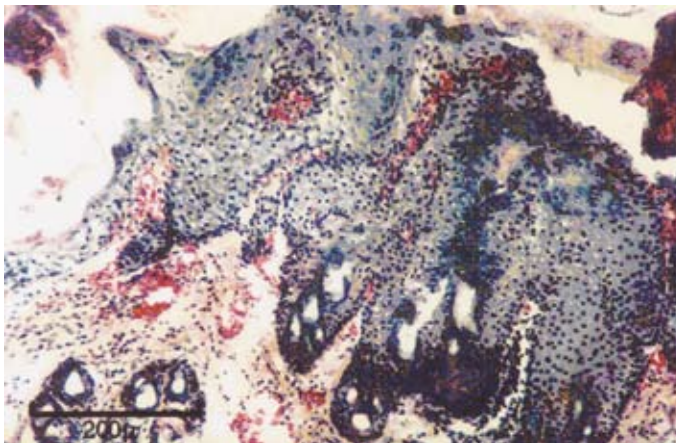


Fig. 4. Section of skin of rabbit affected with concurrent acariosis revealing severe acanthosis with formation of rete ridges. Weigert's H&E; scale bar = 200 μ m.

observed in a scraping from one rabbit, having an elongated, waist-like body, blade-like chelicerae and curved palpal claws. Overall, the females were more predominant than males in their scrapings.

Necropsy. Cut surface of the skin revealed thickness of its layers and dilatation of the hair follicles with dark centres giving appearance of tunnels (Fig. 3). Haemorrhages were evident in those having crusts.

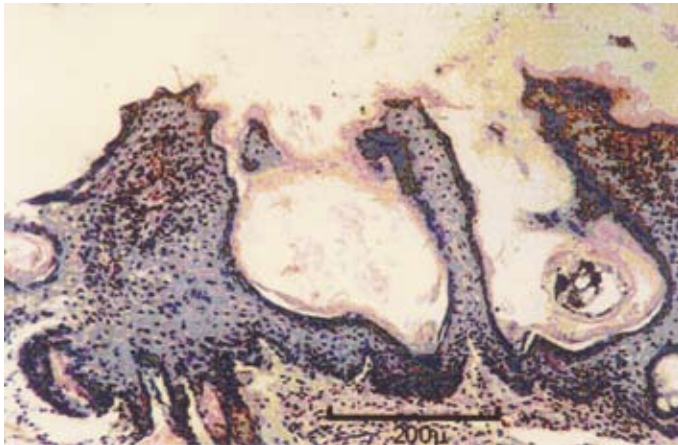


Fig. 5. Section of skin showing presence of mites (arrow) in burrows in the epidermis; the epithelium reveals rete papillae formation. Weigert's H&E; scale bar = 200 μ m.

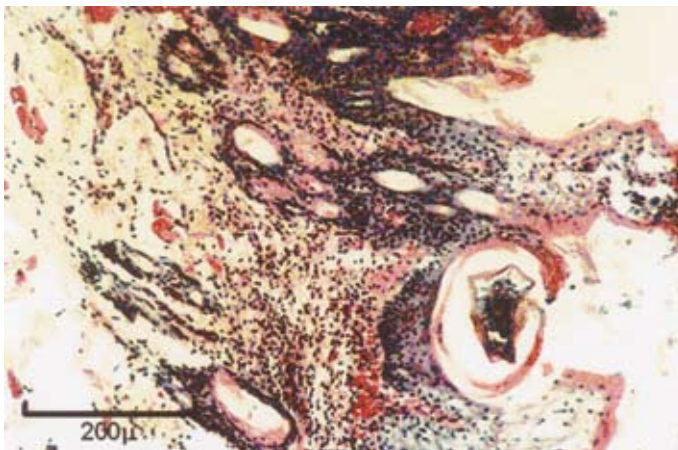

Fig. 6. Section of skin showing sub-epidermal dermatitis with infiltration of mononuclear cells and heterophils. Weigert's H&E; scale bar = 200 μ m.

Histopathology and histochemistry. Lesions were characterized by hyperkeratosis with both ortho- and parakeratosis, acanthosis with formation of rete ridges projecting downward into the underlying dermis (Fig. 4). Cross- sections of the mites were seen in niche-like burrows in the epidermis, and the adjacent epidermis had grown in the form of rete papillae on the sides of the mites (Fig. 5). A few mites were in malphigian layer and had even penetrated the dermis, localizing in hair follicles. Some acanthotic tissue revealed hydropic degeneration. Formation of keratin cysts was noted in the epidermis. Subepidermal dermatitis was characterized by infiltration of mononuclear cells of macrophages and lymphocytes, as well as heterophils (Fig. 6). The sinus hair follicles were engorged with blood. Exfoliation of epidermis, with congestion and haemorrhages, was noted in dermis (Fig. 7). The sections were negative for metachromasia, and the epidermis and hair follicles revealed an increase in acid mucopolysaccharides.

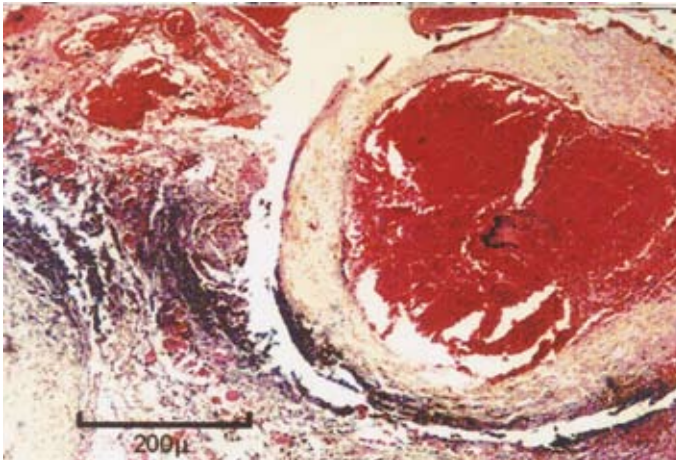


Fig. 7. Section of skin revealing engorgement of sinus hair follicles with blood and haemorrhages in the dermis. Weigert's H&E; scale bar = 200 μ m.

Treatment. Of the ten rabbits selected for study of alterations in mite concentrations, two severely affected rabbits died, one on the 3rd day and the other on the 7th day post-treatment. Remaining rabbits showed an improvement from the 3rd day onwards. On average the number of mites/nymphs/larvae and eggs in material was 25.4 and 19.5, respectively, pre-treatment, which decreased to 8.77 (65.50%) and 3.77 (80.77%) on the 5th day post-treatment. On the 10th day no mites or their developmental stages were demonstrated in the scrapings from the affected areas. Clinically, a significant improvement was noted from the 7th day and rabbits recovered completely within 3 to 4 weeks.

Discussion

Acariotic mange in rabbits due to *Sarcoptes scabiei* and *Notoedres cuniculi* was reported earlier (SAHA and MUKHERJEE, 1998; RAJI et al., 1997; KUIZHENG et al., 1994; AULAKH., 2003). Both belong to the family *Sarcoptidae* and are highly contagious and burrowers (WALL and SHEARER, 1997). The present observation indicates that both types can infest rabbits concurrently. However, *Sarcoptes scabiei* predominated. *Cheyletiella* sp. mite, observed in one case, might have contributed to scaly dermatosis. Concurrent Sarcoptic and Chorioptic acariasis has been reported earlier in a British llama (CURTIS et al., 2001). The present outbreak was observed during the months of April to August 2004, when unseasonal rainfalls during summer caused sudden fluctuations in environmental temperatures. ZELEKE and BEKELE (2001) found a high prevalence of acariasis during rainy seasons in camels, whereas RAVINDRAN and SUBRAMANIAN (2000) found the highest prevalence in the months of August, associated with low atmospheric temperatures, high mean relative humidity and high mean rainfall.

The pathogenic effects of these mites have been attributed to their burrowing activity and mechanical damage caused by the parasites during excavation, irritant action of their secretions and excretions, allergic reactions to some of their extracellular products and especially cytokine release, IL-1 (HENRY, 1996; WALL and SHEARER, 1997). Hypersensitivity is thought to be involved in clinical manifestation. However, the present observation reveals that physical damage predominates, as evidenced by negative metachromasia on toluidine blue staining. Negative metachromasia and increase in acid mucopolysaccharides due to *Sarcoptes scabiei* infestation has been reported in goats (ROUT et al., 1995). Severely crusted lesions with a large number of *Sarcoptes scabiei* below the crusts is thought to be due to weak hypersensitivity reactions (HENRY, 1996). Development of scales, scabs, keratinisation, acanthosis and hyperkeratosis due to mites have been reported in animals (ORAON et al., 2000; CHANDEY et al., 2000).

Doramectin® 400 µg kg⁻¹ introduced intramuscularly was found to be an effective treatment. SINGARI et al. (2001) found a single dose of doramectin at the same dose rate, along with the supportive treatment of anti-histaminics for three days, to be 100% effective in control of notoedric mange in rabbits, whereas AULAKH et al. (2003) reported that 200 µg kg⁻¹ introduced subcutaneously once a week for 2 weeks was an effective treatment for the same type of mange. The present observation indicates that doramectin therapy coupled with disinfection of the rabbit cages and their houses with a blowlamp is effective in control of mange in rabbits.

References

- AULAKH, G. S., S. SINGH, L. D. SINGLA, N. SINGLA (2003): Pathology and therapy of natural notoedric acariasis in rabbits. *J. Vet. Parasitol.* 17, 127-129.

M. M. Darzi et al.: Clinico-pathological, histochemical and therapeutic studies on concurrent sarcoptic and notoedric acariosis in rabbits (*Oryctolagus cuniculus*)

- CHANDEY, J., A. P. NAMBI, K. JEYARAJA, B. GOWRI (2000): Clinicopathological and biochemical studies in scabies in dogs. *Indian Vet. J.* 77, 755-757
- CURTIS, C. F., S. J. CHAPPELL, R. LAST (2001): Concurrent sarcoptic and chorioptic acariosis in British llama (*Lama glama*). *Vet. Rec.* 149, 208-209.
- HENRY, J. B. (1996): Clinical diagnosis and management by laboratory methods. 9th ed. WB Saunders Company Philadelphia London, Toronto, Montreal, Sydney, Tokyo.
- HUMASON, G. L. (1979): Animal tissue techniques. 4th ed. WH Freeman and Co., San Francisco.
- JACOBSON, M., S. BORNSTEIN, E. PALMER, P. WALLGREN (2000): Elimination of *Sarcoptic scabiei* in pig herds by single or double administration of an avermectin. *Acta Vet. Scand.* 41, 227-23.
- KUIZHENG, C., L. ZUOMIN, B. JAIMING, S. RONGBIN, L. CHANG CAI, Z. YOUNGSEN, Z. GONG QIONG (1994): Preliminary investigations of ectoparasitic infestation in domestic rabbits. *Chinese J. Vet. Sci. Technol.* 24, 16-17.
- MBUYA-MIMBANGA, M., H. J. GAMPERL (1988): Treatment of sarcoptic mange in rabbits with ivermectin. *Revue d'Élevage et de Médecine Vétérinaire de Pays Tropicaux* 41, 55-58.
- MOWRY, R. W. (1956): Combined alcian blue-PAS technique for acid and neutral mucins, In: *Theory and Practice of Histological Techniques.* (Bancroft, J. D., Gamble M., Eds.). 5th ed., 2002. Churchill Livingstone, London, Edinburgh, New York, Philadelphia, St Louis, Sydney, Toronto. pp. 181-182
- ORAON, B., D. K. THAKUR, S. K. SINGH, M. K. GUPTA (2000): Clinicopathological changes in pigs experimentally infected with *Sarcoptes scabiei*. *Indian J. Anim. Sci.* 70, 405-406.
- RAJI, M. A., B. D. GEORGE, S. B. OLEDELE (1997): Survey of mite species causing mange in rabbits in Zaria environs. *Nigerian Vet. J.* 18, 97-98.
- RAVINDRAN, R., H. SUBRAMANIAN (2000): Effect of seasonal and climatic variations on the prevalence of mite infestation in rabbits. *Indian Vet. J.* 77, 991-992.
- ROUT, S., D. N. PANDA, S. C. MISRA, S. PARIDA (1995): Histochemical study of *Sarcoptic scabiei* infested skin of experimental goats. *Indian Vet. J.* 72, 647-649.
- SAHA, S. B., S. MUKHERJEE (1998): Sarcoptic mange in domestic rabbits. *Indian J. Anim. Hlth.* 37, 73.
- SEKIN, S., H. VAYVODA, H. TESTERECI (1996): Therapeutic efficacy of doramectin as a new endectocide on natural scab and trichostrongylosis and changes in some blood parameters of Akkaranan sheep in Van. *Tur Veterinerlik Ve Hayvancilik Dergisi* 20, 325-330.
- SINGARI, N. A., V. R. KASARALIKAR, B. SHOBHAMANI, P. C. CHOUDHURI (2001): Notoedric mange in rabbits and its treatment with doramectin. *J. Vet. Parasitol.* 15, 77-78.
- SINGH, J., B. S. GILL (1989): Treatment of mange of rabbits with ivermectin. *Indian J. Parasitol.* 13, 115-118.
- WALL, R., D. SHEARER (1997): *Veterinary Entomology.* 1st ed. Chapman and Hall, London, UK.

M. M. Darzi et al.: Clinico-pathological, histochemical and therapeutic studies on concurrent sarcoptic and notoedric acariasis in rabbits (*Oryctolagus cuniculus*)

WANI, G. A., S. A. WANI, A. S. BUCHH, N. SUDHAN (1989): Treatment of mange in rabbits with ivermectin. *J. Vet. Parasitol.* 3, 75-76.

ZELEKE, M., T. BEKELE (2001): Effect of season on the productivity of camels (*Camelus dromedarius*) and the prevalence of their major parasites in eastern Ethiopia. *Trop. Anim Hlth. Prod.* 33, 321-329.

Received: 27 April 2005

Accepted: 2 March 2007

DARZI, M. M., M. S. MIR, R. A. SHAHARDAR, B. A. PANDIT: Kliničko-patološka, histokemijska i terapijska istraživanja šuge kunića (*Oryctolagus cuniculus*) uzrokovane šugarcima roda *Sarcoptes* i *Notoedres*. *Vet. arhiv* 77, 167-175, 2007.

SAŽETAK

Šuga uzrokovana šugarcima *Sarcoptes scabiei* var. *cuniculi* (*Sarcoptes scabiei*) i *Notoedres cati* var. *cuniculi* (*Notoedres cuniculi*) bila je otkrivena u angora i novozelandskih bijelih kunića iz sveučilišne kunićarnice u Srinagaru, Jammu i Kashmir (Indija). Klinički znakovi u invadiranih kunića bili su u početku ljuštenje kože, stvaranje krasta, alopecija i svrbež na licu kod gornje usne što se kasnije proširilo na cijelo lice, vrhove uški, vjede i donju čeljust pa su se razvile hemoragične kraste. U strugotinama kože invadiranih kunića nađene su obje vrste šugaraca. Također, u jednoj strugotini nađene su i grinje roda *Cheyletiella*. Sedam od 35 invadiranih kunića uginulo je od jake šuge, a histološki nalaz je pokazao hiperkeratozu, akantozu i subepidermalni dermatitis. Bojenje toluidinskim modrilom dalo je negativan nalaz na metakromaziju, dok je bojenje alcijanskim modrilom-PAS pokazalo povišene kisele mukopolisaharide u epidermisu i dlačnim folikulima. Jednokratna intramuskularna doza doramektina od 400 µg smanjila je broj i dovela do nestajanja grinja i njihovih razvojnih oblika u strugotinama kože 10 dana poslije primjene. Dodatna dezinfekcija kunićjih kaveza i opaljivanje nastambe pomoglo je u suzbijanju šuge u tijeku tri do četiri tjedna.

Ključne riječi: kunić, šuga, *Sarcoptes scabiei*, *Notoedres cuniculi*, patologija, histokemija
