

## Technical Note

# Modified Elmslie-Trillat Procedure for Distal Realignment of Patella Tendon

Ricardo Bastos Filho, M.D., Ph.D., Alberto Monteiro, M.D., Renato Andrade, B.Sc., M.J.S. Fredrick Michael, M.S., Nuno Sevivas, M.D., Bruno Pereira, M.D., André Sarmiento, M.D., and João Espregueira-Mendes, M.D., Ph.D.

**Abstract:** Patellofemoral dysfunction, due to either a patellofemoral malalignment or patellar instability, is a complex and debilitating condition that significantly decreases the knee function. Conservative management may yield significant clinical outcomes; however, when morphologic anomalies are identified, the surgical approach should be employed. Hence, several surgical procedures have been described in the scientific literature aiming the correction of underlying extensor mechanism malalignments. Still, the rate of complications is higher than desirable. The described technique is based on the principles of transferring the tibial tubercle medially as described in the Elmslie-Trillat technique. However, a curvilinear horizontal cut is made prior to the vertical cut, which raises a thick osseous fragment and allows the formation of a gutter when the osseous fragment is moved medially. Whereas the horizontal gutter provides stability to the bone fragment, the thicker dimension of the osseous fragment and retention of the distal attachment significantly enhances the osteotomy union. Hence, adequate pain relief and stability with very low postoperative morbidity could be achieved. The purpose of this surgical note is to describe a modification to the Elmslie-Trillat technique to treat patellofemoral dysfunctions, achieving a higher osseous stability and decreased postoperative morbidity.

*Clínica do Dragão, Espregueira-Mendes Sports Centre—FIFA Medical Centre of Excellence (R.B.F., A.M., R.A., N.S., B.P., A.S., J.E-M.); and Dom Henrique Research Centre (R.B.F., A.M., R.A., N.S., B.P., A.S., J.E-M.), Porto, Portugal; Fluminense Federal University (R.B.F.), Niteroi, Rio de Janeiro, Brazil; Faculty of Sports, University of Porto (R.A.), Porto, Portugal; Ortho-One Orthopaedic Speciality Centre (M.J.S.F.M.); and St. Isabel's Hospital (M.J.S.F.M.), Chennai, India; Orthopaedics Department, Hospital de Braga and Hospital Privado de Braga (N.S.), Braga; 3B's Research Group—Biomaterials, Biodegradables and Biomimetics, University of Minho, Headquarters of the European Institute of Excellence on Tissue Engineering and Regenerative Medicine (N.S., J.E-M.), Barco, Guimarães; ICVS/3B's—PT Government Associate Laboratory (N.S., J.E-M.), Braga/Guimarães; Department of Orthopaedics, University of Minho (J.E-M.), Braga; and Orthopaedics Department, Hospital de Braga (B.P.), Braga, Portugal; Facultad de Medicina, University of Barcelona (B.P.), Barcelona, Spain; and Orthopaedic Department, Centro Hospitalar Vila Nova de Gaia (A.S.), Vila Nova de Gaia, Portugal.*

The authors report that they have no conflicts of interest in the authorship and publication of this article. Full ICMJE author disclosure forms are available for this article online, as [supplementary material](#).

Received March 31, 2017; accepted August 17, 2017.

Address correspondence to João Espregueira-Mendes, M.D., Ph.D., Via Futebol Clube do Porto—F.C. Porto Stadium, Porto, Portugal. E-mail: [espregueira@dlresearchcentre.com](mailto:espregueira@dlresearchcentre.com)

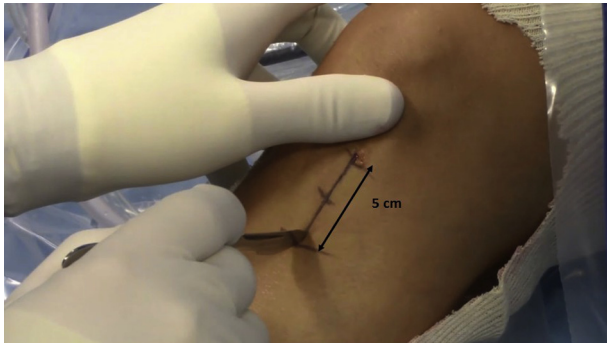
© 2017 by the Arthroscopy Association of North America. Published by Elsevier. This is an open access article under the CC BY-NC-ND license (<http://creativecommons.org/licenses/by-nc-nd/4.0/>).

2212-6287/17465

<http://dx.doi.org/10.1016/j.eats.2017.08.037>

Patellofemoral dysfunction is a debilitating condition that significantly affects knee function. It could be caused by either a patellofemoral malalignment or patellar instability. Two clinical groups may be identified. The first one is composed of painful knees without any patellar displacement episodes. The patient typically describes the pain as arising from the front of the knee after a prolonged duration of sitting with the knees bent, kneeling, or climbing stairs. The second group refers to patients with objective instability (one or more episodes) presented by a history of dislocation or subluxation. Contributing factors to the development of patellofemoral dysfunction include trochlear dysplasia, excessive tibial tubercle—trochlear groove distance (TT-GT), high patella, excessive lateral patellar tilt, ligamentous laxity, increased quadriceps angle (Q-angle), femoral anteversion, and vastus medialis oblique dysplasia.<sup>1,2</sup>

Conservative methods for patellofemoral dysfunctions include quadriceps rehabilitation (i.e., vastus medialis oblique) and hip internal rotators strengthening. Surgical treatment is indicated when morphologic anomalies are identified and are susceptible to be corrected. Moreover, patients with 1 or more episodes of patellar nontraumatic dislocation with knee anatomic disorders (trochlear dysplasia, patella alta, increased TT-GT, and



**Fig 1.** With the patient positioned supine (left leg), a vertical skin incision is made laterally to the anterior tibial tubercle, extending 5 cm from patellar tendon insertion. The arrow line indicates the length of the incision.

patellar tilt) are candidates for surgical treatment. Other indications include anterior knee pain with associated lateral or distal patellofemoral cartilage lesions and conservative treatment failure.<sup>3</sup>

Over the years, various surgical procedures have been described in the literature, such as lateral retinacular release,<sup>4</sup> reconstruction of the medial patella femoral ligament<sup>5</sup> and/or distal realignment of patellar tendon involving tibial tubercle osteotomy.<sup>6-9</sup> The aim of this procedure is the correction of the underlying malalignment of the extensor mechanism. In particular, procedures involving tibial tubercle osteotomy have the objective of correcting an excessive Q-angle and TT-GT distance that cause maltracking of the patella in the trochlear groove, leading to unbalanced cartilage loads, incongruity, instability, and, consequently, pain. Several distal realignments have been described, including Elmslie-Trillat, Roux Goldthwait, Fulkerson, and Maquet procedures. Despite the evolutions concerning indications and surgical techniques, complications are not uncommon.<sup>3</sup> Hematoma, infection, nonunion, fracture of the tibia, overmedialization of the anterior tibial tubercle, and low patella are among them.<sup>10-12</sup>

We describe a technique of medial realignment of the patellar tendon involving the medial rotation of the osseous fragment while retaining its distal attachment.

## Surgical Technique

### Surgical Approach

The patient is positioned supine on the operating table and examined under general anesthesia for patellar instability. A tourniquet is placed ipsilaterally at the proximal thigh. Arthroscopy is performed to manage any suspected cartilage lesion and evaluate the patellar tracking and relative positioning. After this, the knee is placed in full-extension position. A vertical incision is made laterally to the anterior tibial tubercle (Video 1, Fig 1), from the patellar tendon insertion and extending 5 cm distally. Patellar tendon should be well individualized and its attachments accurately identified (Table 1).

### Osteotomy Procedures

The proposed osteotomy is carried out through the same incision. Using a 1-cm flat osteotome, the first cut is made horizontally in a downward curvilinear fashion, 1 cm distal and parallel to the joint line up to a depth of 1 cm (Fig 2).

The second cut is made using a saw blade (Stryker Instruments, Kalamazoo, MI) from the lateral to the medial side in an obliquely elevating manner, along a vertical line that extends for 6 cm from the horizontal cut to a point distal to the tibial tubercle. The thickness of the osteotomy fragment should be 8 to 10 mm, which tapers anteriorly toward the tibial tuberosity (Fig 3). Care should be taken to preserve the distal attachment of the osteotomy fragment.

Then the osseous fragment, with the distal attachment still intact, is rolled medially in the gutter created by the horizontal curvilinear cut, using a flat osteotome to lever the fragment (Fig 4). The final goal is to medialize the anterior tibial tubercle and achieve a final tibial tubercle–trochlear groove (TT-TG) of 12 mm. For example, in a TT-GT of 22 mm, a medialization of 10 mm should be performed.

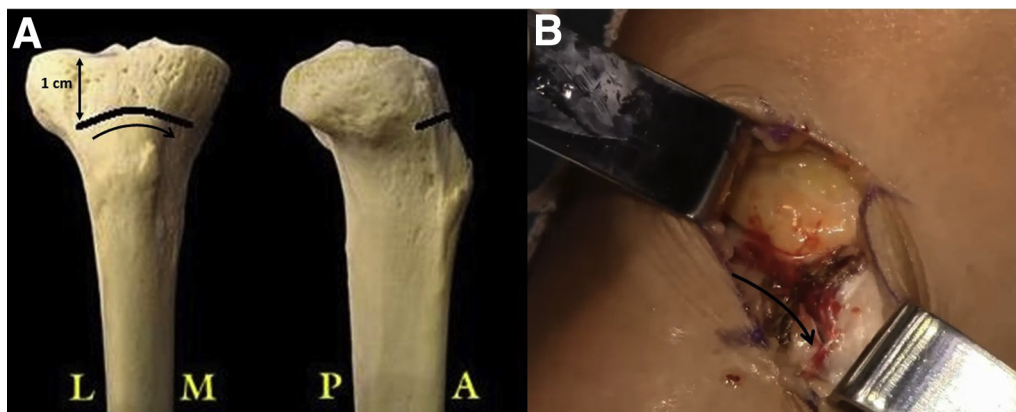
### Fixation and Closure

After this, patellar tracking is tested through a full range of passive motion of the knee, while holding the osseous fragment in place with a lever. Once patellar tracking is found to be satisfactory, the osteotomized bone fragment is held in place with a Kirschner wire and fixation is completed with one 4-mm cancellous lag screw (DePuy Synthes, West Chester, PA) and a washer (DePuy Synthes) at the proximal part of the osseous fragment (Fig 5). The screw is directed parallel to the joint line to achieve maximum compression while avoiding penetration of the posterior cortex.

A lateral retinacular lengthening is indicated when there is a medial hypomobility of the patella and when

**Table 1.** Surgical Procedure Key Points

Osteotomy procedure
A vertical incision, lateral to the anterior tibial tubercle, from patellar tendon insertion and extending 5 cm distally. Patellar tendon must be individualized and its origin well identified.
First cut: horizontal downward curvilinear cut 1 cm deep and 1 cm distal and parallel to the joint line.
Second cut: vertical cut from the lateral to the medial side in an obliquely elevating manner, which extends for 6 cm from the horizontal cut to a point distal to the tibial tubercle.
Preserve the distal attachment of the osteotomy fragment.
Medialization and fixation procedures
The osseous fragment is rolled medially in the gutter created by the horizontal curvilinear cut using an osteotome to lever the fragment.
Once the fragment reaches its desirable position (tibial tubercle–trochlear groove of 12 mm), impaction of the bone fragment is performed against the gutter wall, providing additional stability.
Fixation is done with one 4-mm cancellous lag screw and a washer at the proximal part of the osseous fragment.



**Fig 2.** Patient supine, left leg. The first cut is made horizontally in a downward curvilinear fashion (curvilinear arrows), 1 cm distal and parallel to the joint line (vertical arrow line) up to a depth of 1 cm. (A) Phantom view; (B) open view.

lateral retinacular tightness is noted. The surgical wound is closed in layers, a local anesthetic injection is administered and a sterile dressing is applied. An antibiotic prophylactic is prescribed for the 24 hours after the surgery. Additionally, antithrombotic prophylaxis is recommended for 10 days.

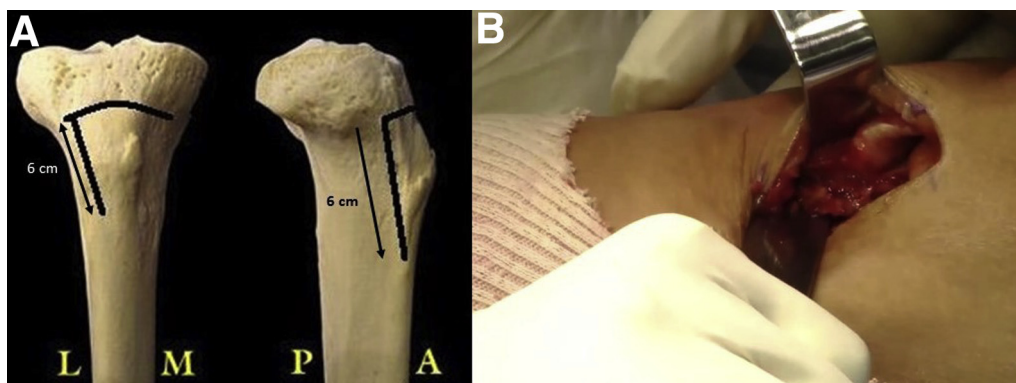
### Postoperative Rehabilitation

After surgery, patients are allowed to be full weight-bearing, and no immobilizer is used. Rehabilitation starts in the following day (3-5 times a week) and is focused on quadriceps strengthening and patellar mobilization. Passive range-of-motion knee flexion is restricted to 95° (first 2 weeks) and increased as tolerated. Consolidation is expected at around 45 days. As soon as the consolidation is achieved, patients are allowed normal gait, avoiding stair descending for around 1 month. Return to sports is allowed at 4 to 6 months.

### Discussion

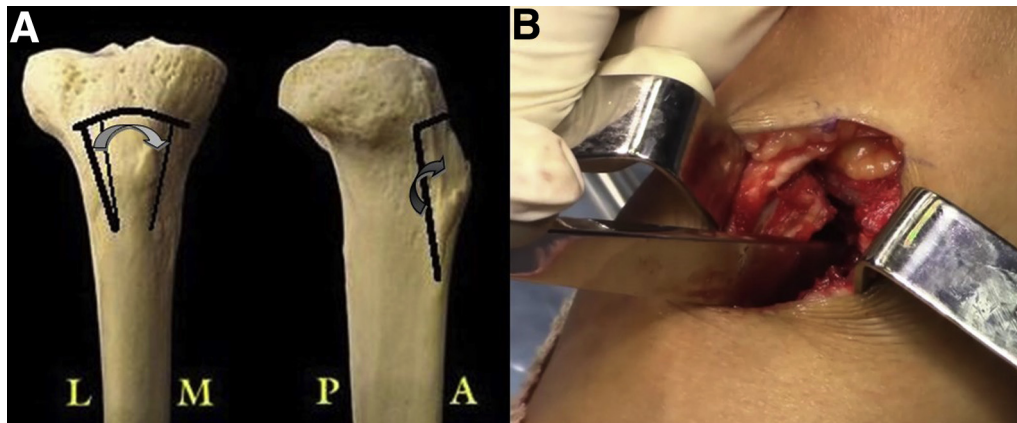
Anterior knee pain caused by patellofemoral malalignment is mainly due to cartilage damage, often seen in the lateral facet of the patella and the trochlear groove. This is

primarily due to an abnormal overload of the lateral retinaculum, cartilage, and subchondral bone.<sup>13,14</sup> Dejour et al.<sup>2</sup> categorized patellofemoral disorders as objective patellar instability where a true patellar dislocation or subluxation with trochlear dysplasia is present, potential patellar instability in which trochlear dysplasia is present but patellar dislocation or subluxation has not occurred, and patellofemoral pain syndrome, characterized by anterior knee pain without any knee joint anatomic dysfunction. Choosing the correct surgical procedure for each of these categories is based on various factors, including severe patella alta, trochlear dysplasia, quadriceps dysplasia, increased TT-TG distance, and specific anatomy of the patellofemoral joint of the patient.<sup>11</sup> The initially described distal realignment procedures mainly employed the principle of transferring the tibial tubercle either medially or distally or both to achieve normal patellofemoral alignment.<sup>6-8</sup> The osseous fragment needs to be detached, though the periosteal flap may be reattached. Although the patellofemoral malalignment may be corrected, these procedures prolong the postoperative recovery time and increase the risk of complications. Potential complications have been



**Fig 3.** Patient supine, left leg. The second cut is made vertically, from the lateral to the medial side, in an obliquely elevating manner, extending for 6 cm from the horizontal cut to a point distal to the tibial tubercle, indicated by the vertical diagonal arrow lines (A). (A) Phantom view; (B) open view.





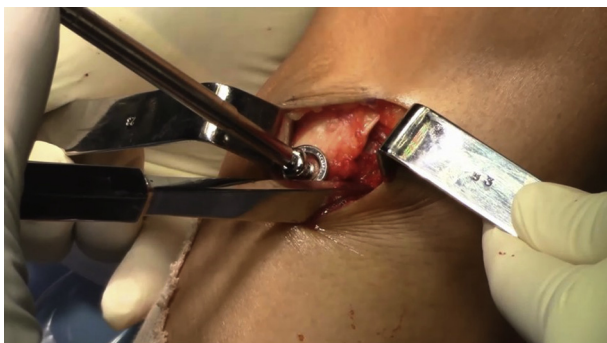**Fig 4.** Patient supine, left leg. Maintaining the tibial tubercle distal attachment intact, the osseous fragment is rolled medially throughout the gutter; this is indicated by a curved arrow (A). The medialization should be performed to achieve a TT-TG of 12 mm. (A) Phantom view; (B) open view. (TT-TG, tibial tubercle–trochlear groove.)

reported by various authors, the most severe being a tibial fracture and an osteotomy nonunion.<sup>10,12</sup> Also, degenerative joint disease has been noted as a result of tibial tubercle transfers.<sup>15</sup>

The Elmslie-Trillat procedure was described by Trillat et al.<sup>16</sup> in 1964, as a minimal distal advancement of the patellar tendon for the correction of patellofemoral malalignment. It involves lateral retinacular release, medial capsulorrhaphy, and medial transfer of the anterior tibial tuberosity on a distal periosteal hinge.<sup>16</sup> Of the 64 operated patients, Trillat reported 78% good to excellent results on follow-up for at least 1 year. However, although results were good initially, deterioration was observed on following up to 7 years.<sup>17</sup> Since then, multiple authors have described various complications from superficial wound infections and skin irritation to major complications such as tibial fracture, osteotomy nonunion, neurovascular damage,

deep infection, and degenerative arthritis.<sup>10,12</sup> Shelbourne et al.<sup>18</sup> proposed a modification to the Elmslie-Trillat procedure that involved raising a flat osteoperiosteal flap and rotating it medially. Although there was an improvement in the congruence angle postoperatively, residual instability was observed on follow-up because of the flat nature of the osteoperiosteal flap. Fulkerson et al.<sup>9</sup> described an oblique osteotomy to include an anterior displacement of the tibial tubercle along with medial transfer.

In our proposed technique, a horizontal curvilinear cut to a depth of 1 cm is made prior to the vertical cut. Owing to this horizontal curvilinear cut, a thick osseous fragment is raised, and a gutter is created in which the fragment is levered medially. While the horizontal gutter provides an inherent stability to the bone fragment, the thicker dimension of the osseous fragment and retention of the distal attachment significantly enhance the osteotomy union. The V-shape and the anterior tapering nature of the osseous fragment along with the obliquely elevating manner of the vertical cut prevent posterior displacement of the tibial tuberosity (Table 2). This, in turn, reduces the contact between the lateral facet of the patella and the trochlear groove. Reduced contact, along with realignment of the patellar tendon, drastically reduces the abnormal overload of the lateral retinaculum and prevents cartilage damage. The stability provided by this fixation promotes quickened postoperative rehabilitation. Because of the early mobilization, complications due to prolonged immobilization are avoided. Thus, the presented technique provides adequate pain relief and stability with very low postoperative morbidity. We conclude that our modification of the Elmslie-Trillat distal realignment procedure is an effective method for the treatment of patellofemoral dysfunction.



**Fig 5.** Patient supine, left leg. Fixation of the levered osseous fragment is made at the proximal part of the osteotomized fragment, using a 4-mm cancellous lag screw and a washer. Additional stability is obtained by V-shape and anterior tapering of the performed horizontal and curvilinear gutter, preventing proximal displacement and, consequently, patella alta.

**Table 2.** Surgical Procedure Pearls and Pitfalls

Pearls	Pitfalls
Patellar tendon must be individualized and its origin well identified to avoid patellar tendon injury and to correctly identify the osteotomy cut placement.	Placing the skin incision too medial or too lateral may result in soft tissue dissection.
Horizontal curvilinear cut enables to raise a thick osseous fragment, and the gutter created allows the leverage of the fragment medially.	While performing the vertical cuts (second cut), care should be taken toward the tibial tubercle to preserve the distal attachment of the osteotomy fragment.
Horizontal gutter provides an inherent stability to the osseous fragment.	The osteotomized bone block should be 8-10 mm thick to avoid fracture.
Thicker dimension of the osseous fragment and the distal soft-tissue attachments should always be preserved to enhance osteotomy union.	
The V-shape and anterior tapering nature of the osseous fragment, and the obliquely elevating manner of the vertical cut, prevents posterior displacement of the tibial tuberosity.	
The medialization should be performed to obtain a 12-mm TT-TG. Thus, if you have a TT-TG of 24 mm, a medialization of 12 mm should be performed.	
Advantages	Risks
A single-stage procedure is performed.	Potential complications of detachment of the tibial tubercle may occur including tibial fracture, osteotomy nonunion, and degenerative joint disease.
The stability provided by the osseous fixation promotes quickened postoperative rehabilitation.	
Osteotomized bone impaction against the gutter wall created by the first horizontal curvilinear cut provides greater stability, complemented with a cancellous lag screw and a washer.	
Impaction leads to a better contact between the fragment and consequently reduces the risk of nonunion and loss of correction.	
TT-TG, tibial tubercle–trochlear groove.	

## Acknowledgment

The authors sincerely acknowledge André Silva for his valuable help in the construction and management of the video and figures.

## References

- Dejour DH. The patellofemoral joint and its historical roots: The Lyon School of Knee Surgery. *Knee Surg Sports Traumatol Arthrosc* 2013;21:1482.
- Dejour H, Walch G, Nove-Josserand L, Guier C. Factors of patellar instability: An anatomic radiographic study. *Knee Surg Sports Traumatol Arthrosc* 1994;2:19-26.
- Longo UG, Rizzello G, Ciuffreda M, et al. Elmslie-Trillat, Maquet, Fulkerson, Roux Goldthwait, and other distal realignment procedures for the management of patellar dislocation: Systematic review and quantitative synthesis of the literature. *Arthroscopy* 2016;32:929-943.
- Fulkerson JP, Schutzer SF, Ramsby GR, Bernstein RA. Computerized tomography of the patellofemoral joint before and after lateral release or realignment. *Arthroscopy* 1987;3:19-24.
- Muneta T, Sekiya I, Tsuchiya M, Shinomiya K. A technique for reconstruction of the medial patellofemoral ligament. *Clin Orthop Relat Res* 1999;359:151-155.
- Roux C. Luxation habituelle de la rotule: Traitement opératoire. *Rev Chir (Paris)* 1888;8:682-689 [in French].
- Hausser ED. The classic: Total tendon transplant for slipping patella: A new operation for recurrent dislocation of the patella. *Clin Orthop Relat Res* 2006;452:7-16.
- Goldthwait JE. Dislocation of the patella. *Trans Am Orthop Assoc* 1896;1:237-238.
- Fulkerson JP. Anteromedialization of the tibial tuberosity for patellofemoral malalignment. *Clin Orthop Relat Res* 1983;177:176-181.
- Harrison RK, Magnussen RA, Flanigan DC. Avoiding complications in patellofemoral surgery. *Sports Med Arthrosc* 2013;21:121-128.
- Payne J, Rimmke N, Schmitt LC, Flanigan DC, Magnussen RA. The incidence of complications of tibial tubercle osteotomy: A systematic review. *Arthroscopy* 2015;31:1819-1825.
- Tompkins M, Arendt EA. Complications in patellofemoral surgery. *Sports Med Arthrosc* 2012;20:187-193.
- Fulkerson JP. Diagnosis and treatment of patients with patellofemoral pain. *Am J Sports Med* 2002;30:447-456.
- Hungerford DS, Barry M. Biomechanics of the patellofemoral joint. *Clin Orthop Relat Res* 1979;144:9-15.

15. Amis AA. Current concepts on anatomy and biomechanics of patellar stability. *Sports Med Arthrosc* 2007;15: 48-56.
16. Trillat A, Dejour H, Couette A. Diagnostic et traitement des subluxations récidivantes de la rotule. *Rev Chir Orthop Reparatrice Appar Mot* 1964;50:813-824 [in French].
17. Cox JS. Evaluation of the Roux-Elmslie-Trillat procedure for knee extensor realignment. *Am J Sports Med* 1982;10: 303-310.
18. Shelbourne KD, Porter DA, Rozzi W. Use of a modified Elmslie-Trillat procedure to improve abnormal patellar congruence angle. *Am J Sports Med* 1994;22: 318-323.