

VETERINARSKI ARHIV 77 (5), 463-467, 2007

## Hypertrophic osteopathy secondary to oesophageal foreign body in a dog - a case report

**Modesta Makungu<sup>1\*</sup>, Joshua Malago<sup>2</sup>, Amandus Pachificus Muhairwa<sup>3</sup>,  
Donald Gregory Mpanduji<sup>1</sup>, and Magwishi Nkwabi Mgasal**

<sup>1</sup>*Department of Veterinary Surgery and Theriogenology, Faculty of Veterinary Medicine, Sokoine University of Agriculture, Morogoro, Tanzania*

<sup>2</sup>*Department of Veterinary Pathology, Faculty of Veterinary Medicine, Sokoine University of Agriculture, Morogoro, Tanzania*

<sup>3</sup>*Department of Veterinary Medicine and Public Health, Faculty of Veterinary Medicine, Sokoine University of Agriculture, Morogoro, Tanzania*

---

**MAKUNGU, M., J. MALAGO, A. P. MUHAIRWA, D. G. MPANDUJI, M. N. MGASA: Hypertrophic osteopathy secondary to oesophageal foreign body in a dog - a case report. Vet. arhiv 77, 463-467, 2007.**

### ABSTRACT

Hypertrophic osteopathy is a pathological disease process that occurs secondary to intra thoracic lesions that are either pulmonary or non pulmonary in origin. A 6-year-old female German shepherd cross was presented with complaints of losing body condition, anorexia, lameness, and swollen limbs. Clinical examination revealed swelling of all four limbs which were hard and painless on palpation. Radiographic examination of the limbs and the thoracic cavity revealed, irregular periosteal new bone formation along the shafts of most of the long bones and an oval-shaped 6 cm diameter radio dense caudal mediastinal mass. At post-mortem examination, an oesophageal diverticulum was found, filled with foul smelling creamy exudates and a bone foreign body firmly adherent to the wall. Hypertrophic osteopathy secondary to oesophageal foreign body was diagnosed based on history, clinical examination, radiography, post-mortem picture and histopathology.

**Key words:** hypertrophic osteopathy, oesophagus, bony, foreign body, dog

---

### Introduction

Hypertrophic osteopathy was initially described in humans in the late 1800s by Marie and Bamberger (LENEHAN and FETTER, 1985). Ever since, the disease has been reported to be common in humans and dogs, but rare in other animals (LENEHAN and FETTER,

---

\*Contact address:

Dr. Modesta Makungu, Department of Veterinary Surgery and Theriogenology, Faculty of Veterinary Medicine, Sokoine University of Agriculture, P. O. Box 3020, Morogoro, Tanzania, Phone: +255 713 212 885; Fax: +255 23 2604 647; E-mail: [modesta\\_makungu@yahoo.com](mailto:modesta_makungu@yahoo.com)

ISSN 0372-5480  
Printed in Croatia

1985). This clinical communication reports clinical case of hypertrophic osteopathy secondary to oesophageal foreign body in a dog in Tanzania.

### Case history

A 6-year old female German shepherd cross was referred to Sokoine University of Agriculture Veterinary Clinic with complaints of loss of body condition, anorexia, lameness and swollen limbs (all four limbs). Two months earlier, the dog had been presented at a private clinic with signs of pyrexia, lameness, vomiting, respiratory distress, and ocular discharges. The dog was treated with oxytetracycline hydrochloride (Oxyetra5coophavet; Coophavet) at a dosage of 10 mg/kg body mass intravenously, but with no improvement.

At referral a thorough clinical examination was conducted, the dog was sedated with Xylazine (Xylaject; Dopharma) at a dosage of 2 mg/kg body mass intravenously and radiography of the limbs and the thorax was taken. Because of the deteriorating condition, the dog was euthanized by intravenous injection of sodium pentobarbitone (Euthatal; Rhône Merieux/Dublin).

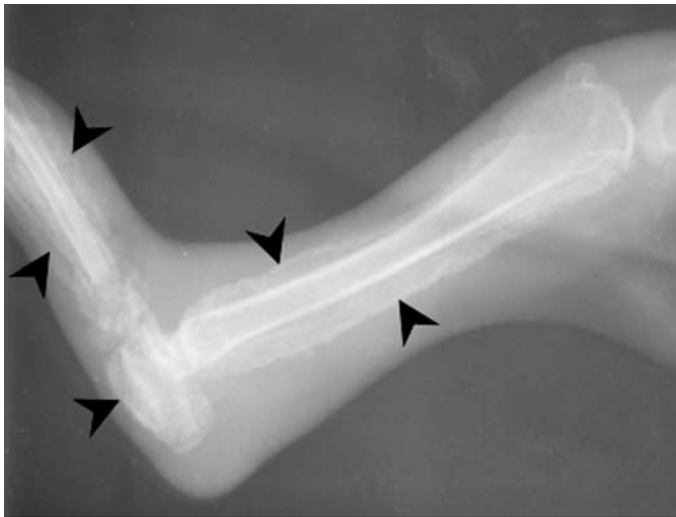


Fig. 1. Mediolateral view of the tibia, tarsus and proximal metatarsal bones of a dog with hypertrophic osteopathy. Note the typical periosteal new bone around the tibia, calcaneus, tarsal and metatarsal bones (arrow heads).

*Clinical findings.* Clinical examination revealed pyrexia (40.1 °C), tachycardia (132 beats per minute) and tachypnoea (40 breaths per minute), poor body condition, bilateral mucopurulent ocular discharges and hard, painless swelling of all four limbs. Haematological parameters showed a decreased in Packed Cell Volume of 32% (normal is 37-55%) and neutrophilia at 87% (60-77% is normal).

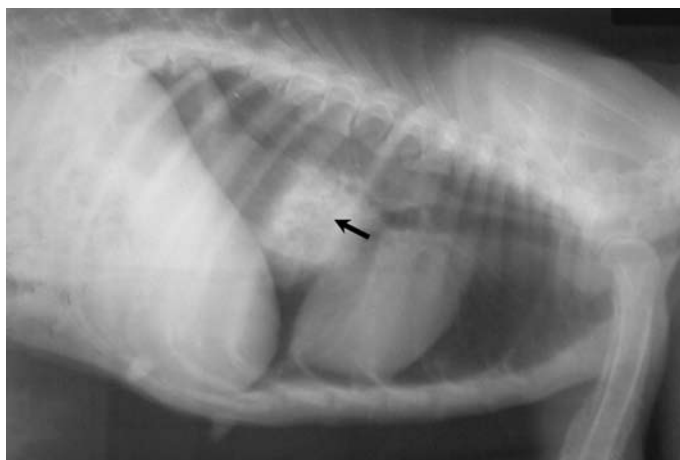

Fig. 2. Left lateral thoracic view of a dog with hypertrophic osteopathy. An oval, radio dense mass located in the caudal thoracic oesophagus, immediately caudal to the heart (arrow).

*Radiographic findings.* Radiographic examination of the limbs and the thoracic cavity revealed irregular periosteal new bone formation along the shafts of most of the long bones (Fig. 1) and an oval-shaped 6 cm diameter radio dense caudal mediastinal mass (Fig. 2).

*Post-mortem findings.* Post-mortem examination showed distension of the caudal thoracic part of the oesophagus forming a hard oval mass 6 cm in diameter, which on opening was found to be an oesophageal diverticulum filled with foul smelling creamy exudates. A hard foreign body was firmly adherent to the wall of the oesophagus (Fig. 3). A tissue sample of this foreign body was fixed in 10 per cent formalin, decalcified and processed for histopathological examination. The histopathological picture was that of a mature bone tissue with central canal surrounded by bony lamellae and osteocytes in lacunae.

A diagnosis of hypertrophic osteopathy secondary to oesophageal foreign body was made based on all the findings.

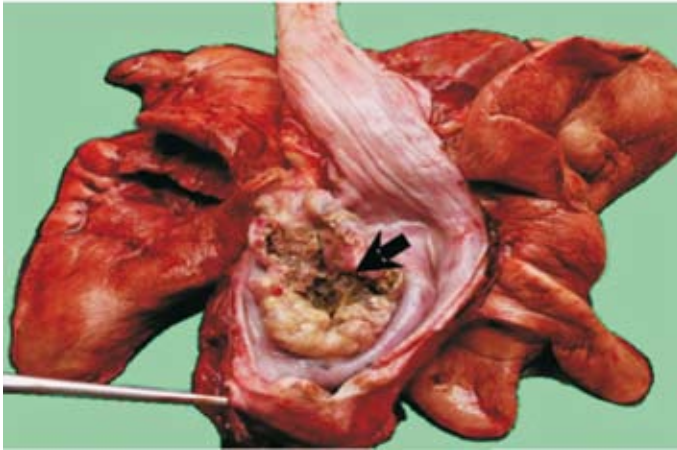


Fig. 3. Opened post-mortem specimen of the oesophagus. An oesophageal diverticulum with creamy exudates and a hard foreign body (bone) adherent to the oesophageal wall (arrow).

### Discussion

Hypertrophic osteopathy is a pathological disease process that occurs secondary to intra thoracic lesions that are either pulmonary or non pulmonary in origin (LENEHAN and FETTER, 1985). Oesophageal foreign body, as a cause of hypertrophic osteopathy has not been reported before. Hypertrophic osteopathy has been reported previously in dogs associated with bronchial foreign body (CAYWOOD et al., 1985). Consistently, the clinical signs observed in our case, (i.e. anorexia, ocular discharges, loss of body condition, lameness of all four limbs and firm swelling of the long bones) and the periosteal new bone formations observed radiographically, have also been reported in other dogs with hypertrophic osteopathy (LENEHAN and FETTER, 1985; KIRIN et al., 1993; HARA et al., 1995; PANCIERA et al., 2000).

The pathophysiology of hypertrophic osteopathy is not well known (KIRIN et al., 1993; PANCIERA et al., 2000). Increase in peripheral blood flow in the distal half of the extremities and subsequent formation of excessive amount of highly vascular connective tissue is responsible for periosteal bone formation (PALMER, 1993). Neuronal and humoral theories have been suggested to explain the pathogenesis of hypertrophic osteopathy (PALMER, 1993).

Hypertrophic osteopathy in dogs may be treated by removal of the primary underlying cause (CAYWOOD et al., 1985; LENEHAN and FETTER, 1985). Although successful surgical management of hypertrophic osteopathy has been described (HARA et al., 1995), treatment

in this case was not considered because of the deteriorated body condition of the dog. It is believed that early diagnosis and removal of the oesophageal foreign body may have assisted in the successful management of this case.

## References

- CAYWOOD, D. D., B. A. KRAMEK, D. A. FEENEY, G. R. JOHNSTON (1985): Hypertrophic osteopathy associated with a bronchial foreign body and lobar pneumonia in a dog. *J. Am. Vet. Med. Assoc.* 186, 698-700.
- HARA, Y., M. TAGAWA, H. EJIMA, H. ORIMA, T. YAMAGAMI, M. UMEDA, S. KOMORI, M. WASHIZU (1995): Regression hypertrophic osteopathy following removal of intrathoracic neoplasia derived from vagus nerve in a dog. *J. Vet. Med. Sci.* 57, 133-135.
- KIRIN, B. W., D. L. DANIEL, D. P. ROBERT, C. DOO-YOUN, B. S. ALMAROY (1993): Hypertrophic osteopathy associated with *Mycobacterium fortuitum* pneumonin in a dog. *J. Am. Vet. Med. Assoc.* 202, 1986-1988.
- LENEHAN, T. M., A. W. FETTER (1985): Hypertrophic osteopathy. In: *Textbook of small animal orthopaedics.* (Newton, C. D., D. M. Nunamaker, Eds.). J B Lippincott Company, Philadelphia. pp. 603-609.
- PALMER, N. (1993): Bones and joints. In: *Pathology of the domestic animal.* (Jubb, K. V. F., P. C. Kennedy, W. Palmer, Eds.). Academic press Inc. California. pp. 109-118.
- PANCIERA, R. J., J. S. MATHEW, S. A. EWING, C. A. CUMMINGS, W. T. DROST, A. A. KOCAN (2000): Skeletal lesions of canine hepatozoonosis caused by *Americanum hepatozoon.* *Vet. Pathol.* 37, 225-230.

Received: 26 August 2006

Accepted: 28 September 2007

---

**MAKUNGU, M., J. MALAGO, A. P. MUHAIRWA, D. G. MPANDUJI, M. N. MGASA: Hipertrofična osteopatija kao posljedica stranoga tijela u jednjaku psa - prikaz slučaja. *Vet. arhiv* 77, 463-467, 2007.**

### SAŽETAK

Hipertrofična osteopatija patološki je proces koji se javlja sekundarno kao posljedica intratorakalnih lezija plućnog ili neplućnog podrijetla. Njemačka ovčarka u dobi od šest godina bila je primljena sa znakovima gubitka težine, anoreksije, šepanja i otečenih nogu. Kliničkom pretragom ustanovljene su tvrde, na palpaciju bezbolne otekline nogu. Radiografskom pretragom nogu i prsne šupljine ustanovljene su nepravilne periostealne novotvorine u većine dugih kostiju i ovalna radiološki gusta masa promjera šest cm u kaudalnom medijastinumu. Pri razudbi je ustanovljen divertikul jednjaka ispunjen pjenušavim eksudatom neugodna mirisa i koštano strano tijelo koje je čvrsto prianjalo na stijenku. Na osnovi anamneze, kliničke pretrage, radiografije, razudbe trupa i patohistološkoga nalaza dijagnosticirana je sekundarna hipertrofična osteopatija kao posljedica stranoga tijela u jednjaku.

**Ključne riječi:** hipertrofična osteopatija, jednjak, kost, strano tijelo, pas

---

