

Sterile neutrophilic dermatitis in a cat - a case report

Nikša Lemo^{1*}, Florence Bernex², Celine Hadjaje², and Genevieve Marignac²

¹*Faculty of Veterinary Medicine, Clinic of Internal Medicine, Zagreb, Croatia*

²*Ecole Nationale Vétérinaire d'Alfort, Maisons-Alfort, France*

LEMO, N., F. BERNEX, C. HADJAJE, G. MARIGNAC: Sterile neutrophilic dermatitis in a cat - a case report. Vet. arhiv 78, 261-267, 2008.

ABSTRACT

A 6.7 kg 7 year-old castrated male domestic short hair cat was presented with several dermatological lesions on the ventral abdomen. The skin of the abdomen and inner thighs was affected. Both inner thighs were equally involved. They were covered with thick and folded, "card-board" devitalised skin. Some ulcerative haemorrhagic lesions were coated by greyish pseudomembranes of necrotic epithelium and fibrin. There was a distinctive margin between normal and affected skin. On the abdomen there was patchy erythema and papules. No other skin lesions were found on the rest of the body. Differential diagnoses for the lesions included: drug reaction, erythema multiforme, toxic epidermal necrolysis, vasculitis, and impetigo. Histopathology revealed different lesions: superficial pustules, ulceration and fibrin exudation, pustule disease with hair follicle destruction. There was no evidence of bacteria on cytology and histopathology. All previously prescribed drugs were stopped. On the day after initial proceeding lesions become less haemorrhagic and less thick. On the fourth day skin lesions were dry. Local therapy (povidone iodine) was maintained and the cat was sent home on day 5. Conclusion of case is sterile neutrophilic dermatitis.

Key words: cat, drug reaction, erythema multiforme, sterile neutrophilic dermatitis

Introduction

Skin reaction during hospitalization was seen in a cat. It was interesting to find the cause of the grave skin lesions, especially due to the high suspicion of cutaneous drug reaction. Neutrophilic infiltration of skin is a rare condition in cat specially without evidence of bacterial presence (YAGER and WILCOCK, 1994).

Case description

A 6.7 kg 7 year-old castrated male domestic short hair cat was presented for 24 h vomiting, hypothermia and dehydration. Biochemistry and haematology were

*Contact address:

Dr. Nikša Lemo, DVM, MSc, PhD, The Clinic for Internal Diseases, The Faculty of Veterinary Medicine, University of Zagreb, Heinzelova 55, Zagreb 10 000, Croatia, Phone: +385 1 2390 355; Fax: +385 1 2441 390; E-mail: nlemo@vef.hr

unremarkable except hyperkalemia, leucocytosis and normochromic anaemia. Ultrasound examination showed a calculus in the urinary bladder. The cat was hospitalised and treated by cefalexin 20 mg/kg (Rilexine, Virbac), spasmoglucinol 4 ml and rehydrated by infusion of NaCl. Surgical removing of calculus was performed 4 days after it was first presented. Anaesthesia consisted of propofol (3.2 mL) + valium (0.5 mL) and maintenance with isoflurane. Table 1 shows all medication prescribed in therapy as potential cause of drug reaction.

Table 1. Medications prescribed in therapy

Drug and doses	Market name	Period of treatment, day 0 is marked as the day of dermatology exam
Cefalexin 20mg/kg	Rilexine (Virbac)	13 days up to day 0
Phloroglucinol 4 mL	Spasmoglucinol (Vetoquinol)	13 days up to day 0
Propofol 3,2 mL	Rapinovel (Shering-Plough)	Once, 5 days before day 0
Diazepam 0,5 mL	Valium	Once, 5 days before day 0
Isoflurane	Isoflurane Belamont S inh: FI/100 mL	Once, 5 days before day 0

The day after surgery, the cat presented several dermatological lesions on the ventral abdomen. Continued antibiotic treatment resulted in no improvement. The cat was presented for dermatology consultation.

Clinical findings

On presentation, the skin of the abdomen and inner thighs was affected. Both inner thighs were equally involved. They were covered with thick and folded, “card-board” devitalised skin. When removed, this left multifocal vesicular lesions, erythematous, oozing erosions and ulcers. Some ulcerative haemorrhagic lesions were coated by greyish pseudomembranes of necrotic epithelium and fibrin (Fig. 1). There was a distinctive margin between normal and affected skin. On the abdomen there were patchy erythema and papules. No other skin lesions were found on the rest of the body.

Differential diagnoses for the lesions included: drug reaction, erythema multiforme, toxic epidermal necrolysis, vasculitis, and impetigo. Initial diagnostic testing included: a complete blood count, chemistry panel, cytology and skin biopsies from the affected areas (Table 2). Impression cytology retrieved only red blood cells which was inconclusive. There was no evidence of bacteria.

Histopathology revealed different lesions: superficial pustules, ulceration and fibrin exudation, pustule disease with hair follicle destruction. Superficial pustules contain serum and degenerated neutrophils, there was visible spongiosis of the epidermis and neutrophils

exocytosis. Dermis oedema presented with neutrophils diapedesis in vessels (Fig. 2). Also ulceration with fibrin exsudation and degenerated neutrophils embedded inside were seen. The dermis was reactive with numerous neutrophils in vessels (diapedesis).

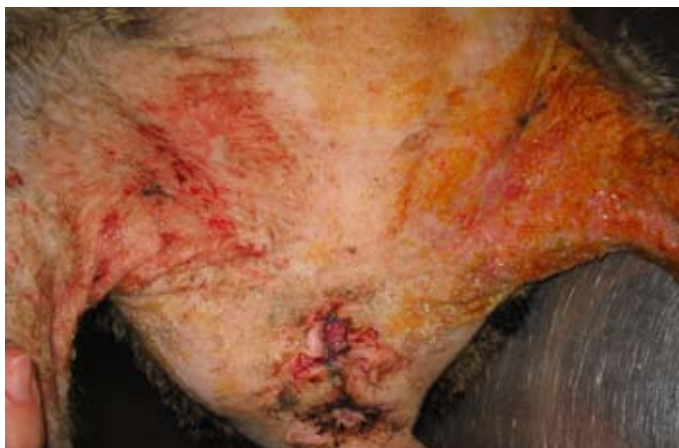

Fig. 1. Abdominal and inner thighs affected skin

Table 2. Complete blood count

Parameter	results	range
RBC	4.6	5-10 $10^{12}/l$
HGB	5.1	8-15 g/dl
HMT	0.17	0.24-0.45
WBC	54.2	6-16 $10^9/l$
neutrophiles	80	% 35-77
eosinophiles	4	% 2-10
basophiles	0	% 0-1
lymphocytes	14	% 20-55
monocytes	2	% 1-4
PLT	694	300-700 $10^9/l$

Due to the absence of bacteria on cytology and the open lesions, culture and sensitivity of the skin were not performed. At this stage, a tentative diagnosis of drug reaction was made because of the sudden onset, dramatic lesions, and drug history mainly considering: surgical scrubbing and the presence of cefalexine in the urine.

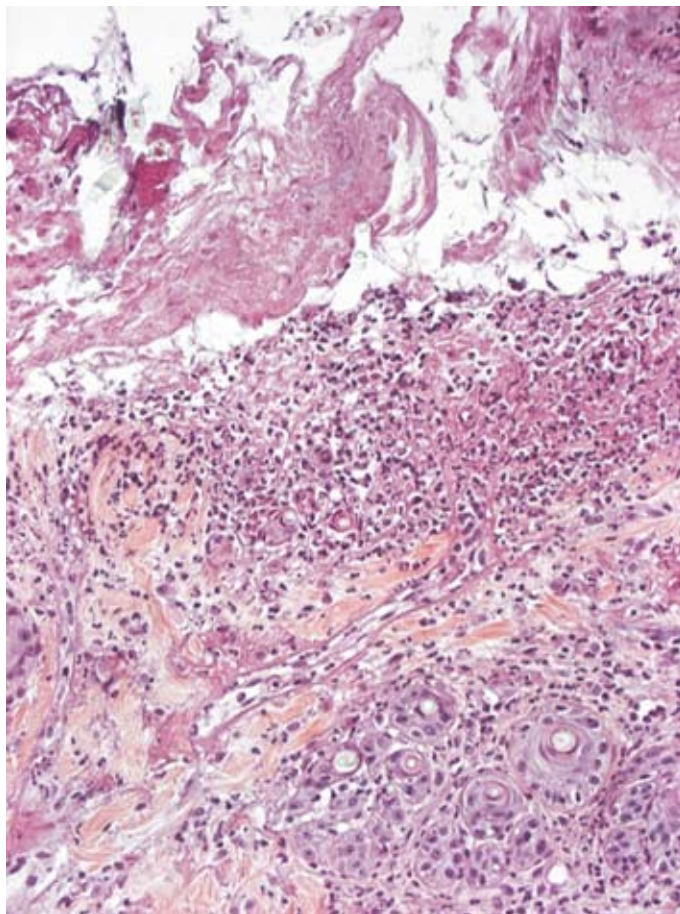


Fig. 2. Ulceration, fibrin exsudation, degenerated neutrophils embedded inside

Treatment and outcome

All previously prescribed drugs were stopped. Considering the depth of the lesions, secondary bacterial infection was treated locally (povidone iodine solution diluted) and systemically amoxicillin clavulonic acid (Synulox-Pfizer) because feline isolates of *S. aureus* and *S. intermedius* have been shown to be highly susceptible *in vitro* to this antibiotic (MEDLEAU, 1988).

On the day after the initial procedure, the lesions became less haemorrhagic and less thick. On the second day there was no evidence of haemorrhage and the skin lesions

become less dramatic, the lesions involved were less reddish and became dry. On the third day, the cat was better and started eating without manual feeding. On the fourth day the skin lesions were dry. Local therapy (povidone iodine) was maintained and the cat was sent home on day 5 (Fig. 3). Treatment was continued at home by the cat's owner. Control exam was on 10th day.

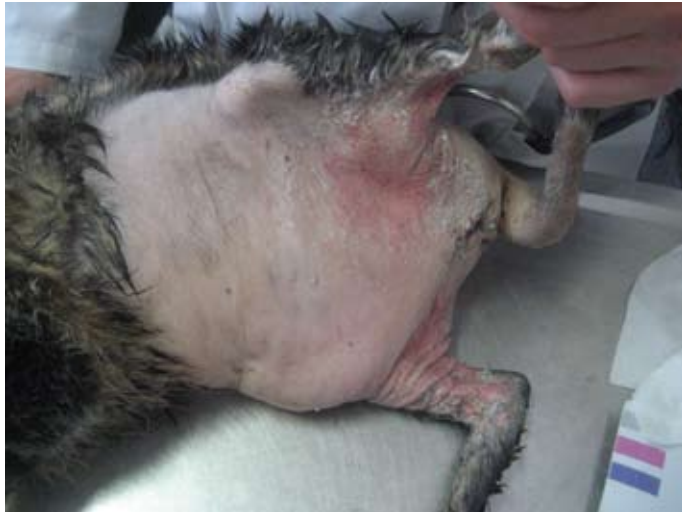

Fig. 3. Five days after initial proceeding

Clinical relevance

The cat had been hospitalized for severe urologic obstruction associated with hyperkalemia. Hyperkalemia is a potentially life-threatening illness that can be difficult to diagnose because of the paucity of specific clinical signs. In this case, other differential diagnoses for decreased or impaired potassium excretion could have been acute or chronic renal failure (most common), Addison disease, and systemic lupus erythematosus (SLE).

The dermatologic condition appeared 5 days after hospitalization. The first hypothesis was drug reaction because the observed reaction occurred in relation to multiple drug exposure (MASON, 1990; UETRECHT, 2006), nature of the lesions (erythema, erosion, ulceration) and sudden onset (IHRKE, 1997; MASON and ROSSER, 1990; THIEN, 2006; SCOTT and MILLER, 1999). We rated cephalexin with the highest suspicion index because of its presentation in the urine and contact with skin. Therapeutic criteria were also in favour of a drug reaction as eruptions typically regressed 5 days after the discontinuation of the putative offending drug and treatment of associated infections.

As early lesions were symmetrical annular and erythematous macules, papules, and plaques that enlarged centrifugally within a few hours and often coalesced to become polycyclic, our main clinical differential was erythema multiforme (MEDLEAU et al., 1990; NELSON and COUTO, 1999). In literature, erythema multiforme has often been hypothesised to be drug related, even though more recent data suggest a viral trigger in most cases in both humans and cats (FAVROT and WILHELM, 2006).

Another differential to be considered is pyotraumatic dermatitis or 'hot-spot'. This primarily sterile condition is very common in dogs and associated with hypersensitivity (FAD mainly) or trauma (including self trauma). Onset is acute (less than 12 hours), displaying as in this case, intense oozing, erythema, erosion and pain. Resolution of skin lesions occurs within days (HOLM et al., 2004). Pyotraumatic dermatitis has been rarely described in cats (SCOTT et al., 1995).

Usually skin biopsies in erythema multiforme cases are characterized by an interface inflammatory reaction with marked apoptosis of keratinocytes at all levels of the epithelium and variable epithelial necrosis in dogs (AFFOLTER and VON TSCHARNER, 1993). In this case inflammatory reaction was seen but without apoptosis of keratinocytes. Erythema multiforme was excluded because there was no apoptosis of keratinocytes, nor lymphocyte satellitosis, no interface dermatitis or oral and lingual lesions. Superficial pyoderma as diagnosis was on the hypothesis list but the symptoms were severe, there were no bacteria found in the cytology and pathology results, only neutrophil infiltration. There are vesico-pustules in the epidermis which usually persist in superficial pustular drug reactions in dogs as described in a dog by WHITE et al. (2002). Also in both cases there was observed ulceration exudation and crusts with severe neutrophils diapedesis.

Finally, histopathology revealed different lesions: superficial pustules, ulceration and fibrin exudation, pustule disease with hair follicle destruction. Dermis oedema was presented with neutrophils diapedesis in vessels.

Conclusion of case is sterile neutrophilic dermatitis.

References

- AFFOLTER, V. K., C. VON TSCHARNER (1993): Cutaneous drug reactions: a retrospective study of histopathological changes and their correlation with the clinical disease. *Vet. Dermatol.* 4, 79-86.
- FAVROT, C., S. WILHELM (2006): Viral dermatoses of the dog and cat. *Tierärztl. Prax.* 34, 307-318.
- HOLM, B. R., J. R. REST, W. SEEWALD (2004): A prospective study of the clinical findings, treatment and histopathology of 44 cases of pyotraumatic dermatitis. *Vet. Dermatol.* 15, 369-376.
- IHRKE, P. J. (1997): Cutaneous adverse drug reactions. *Compend. Contin. Educ. Pract. Vet.* 19, 87-93.
- MASON, K. V., E. J. ROSSER (1990): Cutaneous drug eruptions. In: *Advances in Veterinary Dermatology*. (Von Tscharnier, C., Ed.). R. E. W. Halliwell, Vol. 1. Baillière Tindall, Philadelphia, pp. 426-433.

- MASON, K. V. (1990): Cutaneous drug eruptions. *Veterinary Clinics of North America: JSAP* 20, 1633-1653.
- MEDLEAU, L. (1988): Frequency and antimicrobial susceptibility of *Staphylococcus spp.* isolated from feline skin lesions. *J. Am. Vet. Med. Assoc.* 193, 1080-1081.
- MEDLEAU, L., K. J. SHANLEY, P. M. RAKICH, M. H. GOLDSCHMIDT (1990): Trimethoprim-sulfonamide-associated drug eruptions in dogs. *J. Am. Anim. Hosp. Assoc.* 26, 305-311.
- NELSON, R. W., C. G. COUTO (1999): *Small Animal Internal Medicine*, 3rd ed. Mosby, pp. 832-834.
- SCOTT, D. W., W. H. MILLER (1999): Erythema multiforme in dogs and cats: literature review and case material from the Cornell University College of Veterinary Medicine (1988-96) Volume 10, 297.
- SCOTT, D. W., W. H. MILLER, C. E. GRIFFIN (1995): *Mullers and Kirk's Small Animal Dermatology*, 5th ed. Philadelphia, W.B. Saunders, pp. 595-596.
- UETRECHT, J. (2006): Role of animal models in the study of drug-induced hypersensitivity reactions. *AAPS J.* 7, 914-921.
- THIEN, F. C. (2006): 3. Drug hypersensitivity. *Med. J. Aust.* 185, 333-338.
- WHITE, S. D., D. N. CARLOTTI, D. PIN, T. BONENBERGER, P. J. IHRKE, E. MONET, K. NISHIFUJI, T. IWASAKI, M. G. PAPICH (2002): Putative drug-related pemphigus foliaceus in four dogs. *Vet. Dermatol.* 13, 195-202.
- YAGER J. A., B. P. WILCOCK (1994): *Color Atlas and Text of Surgical Pathology of the Dog and Cat: Dermatopathology and Skin Tumors*, Mosby-Year Book.

Received: 23 January 2007

Accepted: 2 May 2008

LEMO, N., F. BERNEX, C. HADJAJE, G. MARIGNAC: Sterilni neutrofilni dermatitis u mačke. *Vet. arhiv* 78, 261-267, 2008.

SAŽETAK

Kastrirani mačak, kratkodlake domaće pasmine, u dobi od 7 godina, mase 6,7 kilograma dobio je nekoliko lezija na trbušnoj koži. Koža je bila debela i naborana poput kartona. Nekoliko ulcerativnih hemoragičnih lezija bilo je pokriveno sivim pseudomembranoznim nekrotizirajućim epitelom i fibrinom. Granica između normalne i promijenjene kože bila je jasna. Na trbuhu je uočen eritem i papule. Druge lezije na koži nisu uočene. Diferencijalno-dijagnostički u obzir je uzeta reakcija na lijekove, erythema multiforme, toksična epidermalna nekroza, vaskulitis i impetigo. Patohistološkom pretragom uočene su površinske pustule, ulceracija i eksudacija fibrina, destrukcija dlačnih folikula. Citološkom i patohistološkom pretragom nisu uočene bakterije. Sva do tada propisana terapija je prekinuta, dan nakon prvog pregleda lezije su postale manje hemoragične i koža nešto manje zadebljala. Četvrtoga dana kožne leziju bile su suhe, lokalna terapija je nastavljena 1 %-tnim povidone jodom i mačak je pušten na kućnu njegu petoga dana. Postavljena dijagnoza bila je sterilni neutrofilni dermatitis.

Ključne riječi: mačak, reakcija na lijekove, erythema multiforme, sterilni neutrofilni dermatitis
