

Department of Obstetrics and Gynecology,
Elias Emergency University Hospital, Bucharest, Romania

ULTRASOUND IN PRENATAL DIAGNOSIS OF TRIPLOIDY AND TURNER SYNDROME

PRENATALNA DIJAGNOZA TRIPLOIDIJE I TURNEROVA SINDROMA ULTRAZVUKOM

*Radu Vladareanu, Daniel Tutunaru, Bogdan Alexandru,
Alina Veduta, Mona Zvanca*

Review

Key words: ultrasound, prenatal diagnosis, triploidy, Turner syndrome

SUMMARY. Triploidy means that there is a complete extra set of chromosomes in every cell of affected fetus. Instead of having 46 chromosomes, one set of 23 chromosomes from each parent, an individual with triploidy has 69 chromosomes. Triploidy can be detected prenatally by cytogenetic analysis of fetal cells obtained by chorionic villous sampling (CVS) or by amniocentesis. Postnatal diagnosis is based on phenotype of the proband with cytogenetic confirmation by karyotyping. Triploidy is lethal, most fetuses are miscarried, while some die within a few hours or days after birth. Turner syndrome is a form of primary ovarian insufficiency, called also gonadal dysgenesis. Both, triploidy and Turner syndrome should be taken into consideration if sonography reveals minor or major abnormalities of the fetus in the first or in the second trimester of pregnancy. Active screening of these conditions is not justified in the general population. In rare occasions, both conditions can be diagnosed prenatally by ultrasound. The aim of this paper is to underline the importance of accurate prenatal ultrasonic diagnosis in everyday professional work, even though the conditions which are searched for are rare and exotic.

Pregled

Ključne riječi: ultrazvuk, prenatalna dijagnoza, triploidija, Turnerov sindrom

SAŽETAK. Triploidija označava postojanje još jednog kompleta kromosoma u svakoj stanici oboljeloga ploda. Umjesto 46 kromosoma odnosno jednog kompleta po 23 kromosoma od svakog roditelja, jedinka s triploidijom ima 69 kromosoma. Triploidija se može otkriti prenatalno citogenetskom analizom stanica ploda dobivenih biopsijom korionskih resica ili amniocentezom. Postnatalna dijagnoza se zasniva na fenotipu probanda uz citogenetsku potvrdu određivanjem kariotipa. Triploidija je letalna, većina se plodova spontano pobaci, dok ostali umiru tijekom prvih nekoliko sati ili dana po rođenju. Turnerov sindrom je oblik primarne insuficijencije jajnika koji se naziva i gonadalna disgeneza. Na postojanje bilo triploidije bilo Turnerova sindroma valja posumnjati ako se ultrazvukom u ploda otkriju male ili velike malformacije tijekom prvoga ili drugog tromjesečja trudnoće. Aktivni probir ovih stanja nije opravdan u općoj populaciji. Rijetko se i jedna i druga bolest mogu dijagnosticirati prenatalno ultrazvukom. Cilj ovoga članka je ukazati na važnost pravilne prenatalne ultrazvučne dijagnoze u svakodnevnom radu čak i u slučajevima kad su bolesti za kojima se traga rijetke i egzotične.

Introduction

Turner syndrome (Ullrich-Turner) is a genetic disorder characterized by low stature, with exclusively feminine phenotype and gonadal dysgenesis (gonadal streaks) in over 90% of the cases. Triploidy is a chromosomal abnormality where three instead of two haploid sets of chromosomes are present. In other words, in humans there are 69 instead of 46 chromosomes. Triploidy is a rare syndrome estimated to occur in about 2% of conceptuses.¹ Prevalence of Turner syndrome is about 1/1200 at 12 weeks and less than 1/4000 at 40 weeks of gestation. Prevalence of triploidy is 1/2000 at 12 weeks, and very rare at term.

Clinical features in *Turner syndrome* are due to defect of the sexual X chromosome which can be absent in all cells of the respective organism, or only some cells are

affected, while the others are normal. The classical karyotype is aneuploid 45,XO, but it can also be a mosaicism: 45,XO/46,XX; 45,XO/47,XXX; 45,XO/46,XX/47,XXX (Turner like gonadal dysgenesis – with positive sex chromatin); or 45,XO/46,XY; 45,XO/47,YYY; 45,XO/46,XY/47,YYY mosaicism (Turner like gonadal dysgenesis – with negative sex chromatin and very often with deletion of the SRY gene of the testicular determination factor from Y chromosome). Besides, any structural defect of the X chromosome like 46,XXq1 and 45,XO/46,XXq1; 46,XXr and 45,XO/46,XXr; 46,XXp and 45,XO/46,XXp; 46,XXq and 45,XO/46,XXq, X isodiscentric, translocation X – autosome or even isochromosome for the short arm of the X chromosome Xpi may result in Turner phenotype. The classical karyotype is detected in approximately 60% of the patients and it seems to correlate with the typical clinical phenotype of

the syndrome.² The percentage of probands with mosaicism depends on the methods used in genetic analysis. Sometimes, rarely in the cases with 45,XO karyotype, more frequently in the cases with partial deletions of X chromosome, the non-degenerated ovarian follicles persist until puberty and determine the partial onset of the secondary sexual characteristics.

The incidence of X chromosome defects is estimated to be 1:2,000–2,500 of live births; more recently controlled studies revealed incidence of about 1:5,000–6,000 of the female live births.³

Monosomy of the X chromosome is probably the most frequent genetic abnormality in human species, but it is accompanied by very high embryo-fetal lethality. The incidence of 45,XO zygotes is almost 2%, but less than 1% of them survive till term; 7 to 15% of all the spontaneous abortions have 45,XO karyotype. The products of conception with mosaicism or with structural defects of X chromosome survive more frequently than those with 45,XO karyotype.

About 50% of patients apparently have the full monosomy 45,XO while the rest of them have mosaicism. In about 2/3 of patients maternal X is present, while 1/3 of them have the paternal X. Advanced maternal age is not a risk factor in this syndrome. Only one X is normal and functioning; the other X is not present at all, or only a part of the chromosome is missing due to the structural abnormality, deletion or translocation. Mosaicism 45,XO/46,XX or 45,XO/46,XX/47,XXX may also be present. In 10% of Turner mosaics Y chromosome is present (45,XO/46,XY), which increases the risk of gonadoblastoma.⁴ These patients may require a prophylactic gonadectomy to prevent death from malignancy.

The most frequent karyotype in triploidy is 69,XXY, while other karyotypes like 69,XXX are present in 60% to 37%, and 69,XYY in only 3%. Triploidy is known as probably the most frequent human genetic defect. It is estimated that over 25% of genetic abortions are being triploid. There is no correlation with maternal age. The incidence of liveborn triploid newborn is about 1/50000.⁵

Table 1. The incidence of chromosomal abnormalities in early spontaneous abortion (adapted from reference⁵)

Tablica 1. Učestalost kromosomskih anomalija u plodova nakon ranog spontanog pobačaja (prilagođeno prema referenci⁵)

Chromosomal anomaly	Incidence (%)
Turner syndrome, 45,X0 – Turnerov sindrom	18
Triploidy – Triploidija	17
Trisomy 16 – Trisomija 16	16
Other polyploidies – Ostale poliploidije	6.1
Trisomy 22 – Trisomija 22	5.7
Trisomy 21 – Trisomija 21	4.7
Trisomy 15 – Trisomija 15	4.2
Trisomy 14 – Trisomija 14	3.7
Trisomy 13 – Trisomija 13	3.5
Trisomy 18 – Trisomija 18	3.1
Other trisomies – Ostale trisomije	14

Prenatal diagnosis

The main screening methods of prenatal diagnosis are *ultrasound* and *serological tests*, which are also used in prenatal screening of Turner syndrome and triploidy. The diagnosis is confirmed by *amniocentesis* or *chorionic villi sampling* in order to determine karyotype in fetuses with high risk for chromosomopathies. Spencer et al.⁶ in one of their studies stated that a large proportion of triploidy cases of both phenotypes could be identified in the first trimester using nuchal translucency (NT), maternal serum free beta-hCG and PAPP-A while investigating the risk for trisomy 21.

Echographic Screening

The »first trimester« ultrasound (11 – 14 weeks)

Ultrasound examination in this period is not specific for Turner syndrome and triploidy, while it detects only signs indicating possibility of any aneuploidy. The ultrasound in Turner syndrome at the end of the first trimester of gestation detects increased nuchal translucency (*Figure 1*), fetal tachycardia and early intrauterine growth restriction.⁷

Increased NT is the most important echographic sign for all chromosomal abnormalities, between 10 and 14 weeks of gestation. The cut-off value for establishing the pathological NT is in general about 3 mm.

Increased NT in Turner syndrome is observed in 85% of fetuses, while moderate intrauterine growth restriction and tachycardia are observed in 50% of cases.⁷ Increased NT appears in 60% of triploidy cases. Early and asymmetric growth restriction, bradycardia, holoprosencephaly, exomphalos, cyst of the posterior fossa, cerebral anomalies, abdominal wall defects are found in 40% of fetuses, while in 30% of them molar changes in the placenta are present.⁸ Cardiac anomalies seem to be the most important major structural abnormalities linked to increased NT, with the exponential raising of

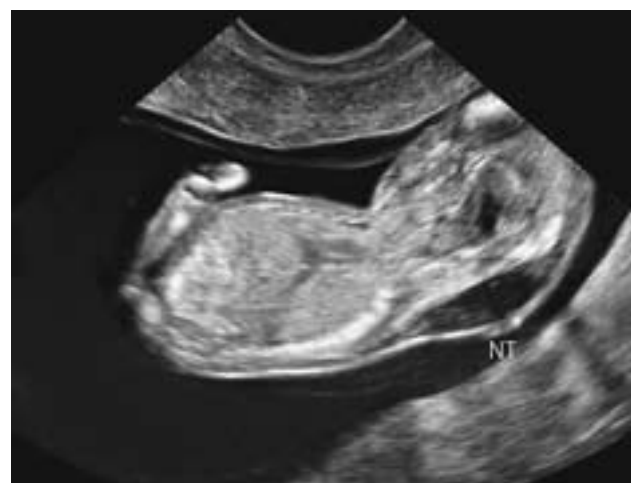

Figure 1. Increased nuchal translucency at 12 weeks of gestation
Slika 1. Povećana nuhalna prozračnost u ploda od 12 tjedana

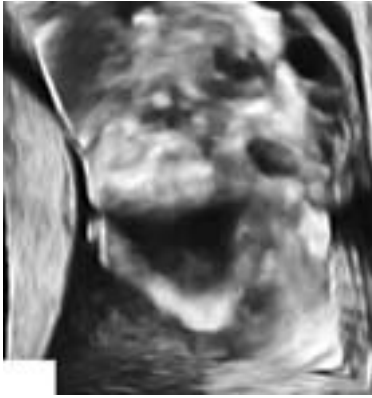

Figure 2. Cystic hygroma in fetus with Turner syndrome. 3D view with clearly depicted septum

Slika 2. Cistični higrom vrata u ploda s Turnerovim sindromom. 3D prikaz jasno vidljivog septuma

their prevalence if the NT increases over 3,5 mm.^{9,10} Although increased NT has been described occasionally in all major cardiac defects, it is strongly associated with anomalies of the left heart such as the left ventricular hypoplasia or coarctation of the aorta. When narrowing of the aortic isthmus is present and associated with wide ascending aorta (trisomies-18 or -21), nuchal edema can be explained by insufficient blood flow in the region perfused by ascending aorta. In the Turner syndrome the narrowing of entire aortic arch is present and the increased NT cannot be explained by the above mentioned mechanism. Increasing NT in fetuses with Turner syndrome is explained by the defect in the formation of the lymphatic vessels in the region of the thorax and the neck, caused by the insufficiency of the lymphogenic genes in the monosomy X, which determines development of nuchal edema. The primary defect of the formation of the lymphatic vessels is included in a larger phenomenon of abnormalities of the cellular migration in embryogenesis. *Figure 2* is showing 3D view of the cystic hygroma in a fetus of 12 weeks.

In the second trimester nuchal edema presenting as cystic hygroma with septa is most frequently associated with Turner syndrome, while the first trimester increased NT is most frequently associated with trisomy-21. In a large controlled study, nuchal translucency over 5 mm was associated with a 28 times increase in the incidence of Down syndrome and only 9 times increase in the incidence of Turner syndrome compared to the general population.¹¹ Falcon et al. in the study failed to prove that the measurement of the gestational sac volume (GSV) at 11 to 13⁺⁶ weeks of gestation is a good screening tool for detection of chromosomal defects.¹² In trisomy-13 and triploidy the small GSV may be due to early onset of fetal growth restriction and reduced amniotic fluid volume. In trisomy-18 the increase of GSV is probably due to the presence of associated fetal abnormalities which interfere with impaired fetal swallowing.¹²

The statistical analysis shows that the majority of the girls (approximately 85%) with monosomy X have mar-

kedly increased NT in the first trimester, compared with trisomy-21 cases where increase of NT is not so striking.^{13,14} In trisomy-21 the NT increases on average 2 mm above the normal value, while in monosomy X it increases 7 mm above the normal value. Besides that, the first trimester hypoechogenic nuchal region in fetuses with Turner syndrome, often persist in the second trimester as cystic hygroma.

Fetal tachycardia, occasionally observed in the first trimester in fetuses with Turner syndrome, is the consequence of delayed maturation of parasympathetic system, can cause fetal heart failure.¹⁵

Intrauterine growth restriction (IUGR) in the first trimester of fetuses with Turner syndrome is moderate, and, according to some studies, insignificant.^{14,16} Bronstein et al. studied 40123 consecutive pregnant women at 14 to 16 weeks of gestation, with fetal karyotyping performed in 9348.¹⁷ Turner syndrome was detected in 13 fetuses (0.03%, 1/3086 of early pregnancies).¹⁷ Huge septated cystic hygroma, severe subcutaneous edema, and hydrops were observed in all cases.¹⁷ Short femur was detected in 12 out of 13 fetuses.¹⁷ A narrow aortic arch was visualized in all 8 fetuses scanned after 1995, when scanning of the aortic arch became mandatory in their institution.¹⁷ Four other fetuses had three or four of the five markers, 2 of the fetuses had trisomy-21, 1 fetus was normal, and one case of missed abortion occurred in a fetus in whom karyotyping was not performed.¹⁷ They concluded that a reliable diagnosis of Turner syndrome by ultrasound is possible in early pregnancy.¹⁷

The »second trimester« ultrasound (18 – 23 weeks)

The fetuses with 45,XO Turner syndrome develop in the second trimester severe lymphatic abnormalities visible by ultrasound. The most typical almost characteristic sign is septated cystic hygroma (*Figures 3 and 4*). Of the fetuses with cystic hygroma 75% have chromosomal

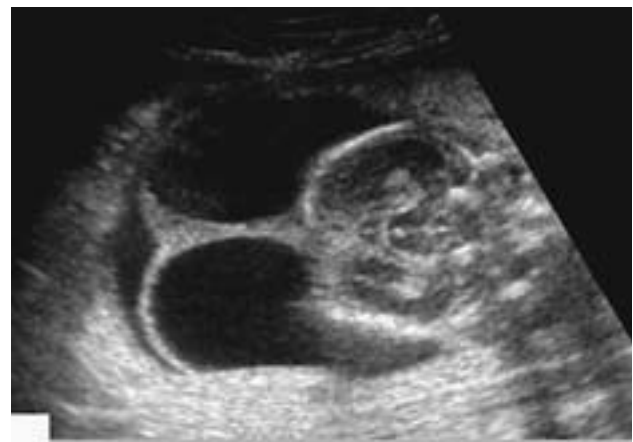

Figure 3. Septated cystic hygroma in fetus with Turner syndrome in the 2nd trimester of pregnancy

Slika 3. Cistični higrom s pregradama u ploda s Turnerovim sindromom u drugom tromjesečju trudnoće

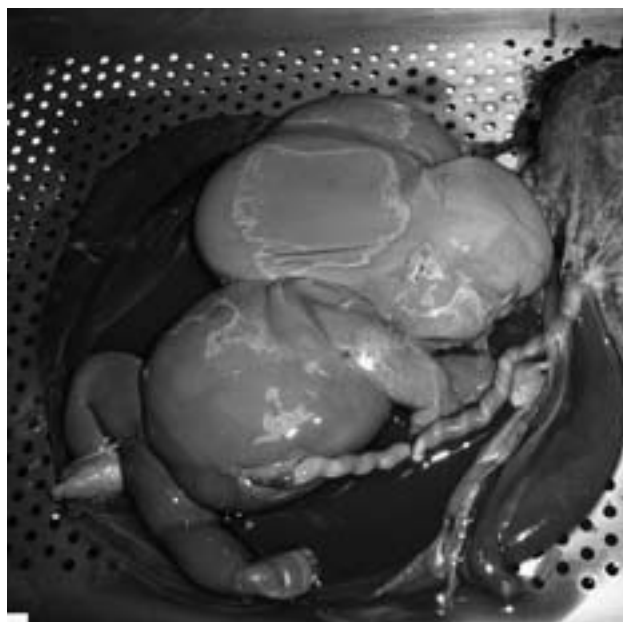


Figure 4. Cystic hygroma in the hydropic fetus after abortion at 19 weeks
Slika 4. Cistični higrom u pobačenog hidropičnog ploda od 19 tjedana

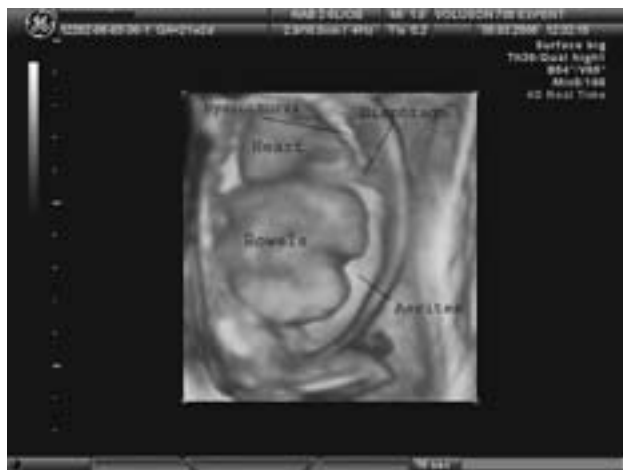
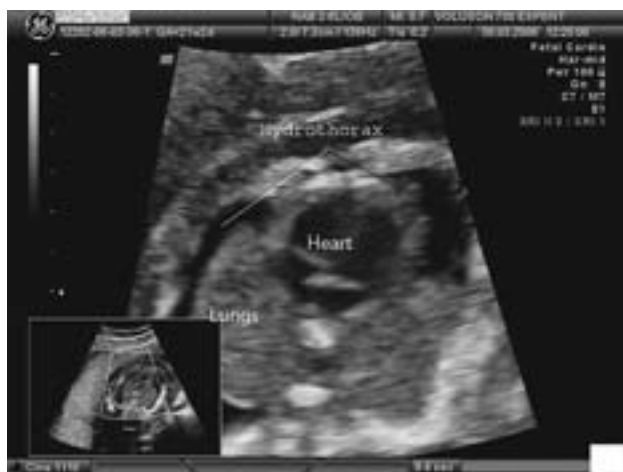
Figure 6. 3D ultrasound of hydropic fetus with ascites and hydrothorax at 22 weeks of gestation
Slika 6. 3D ultrazvučni prikaz hidropičnog ploda s ascitesom i hidro-toraksom nakon 22. tjedna trudnoće



Lungs = pluća; Heart = srce; Hydrothorax = hidrotoraks
Figure 5. Ultrasound of fetus with hydrothorax at 22 weeks of gestation
Slika 5. Ultrazvuk ploda s hidrotoraksom nakon 22. tjedna trudnoće

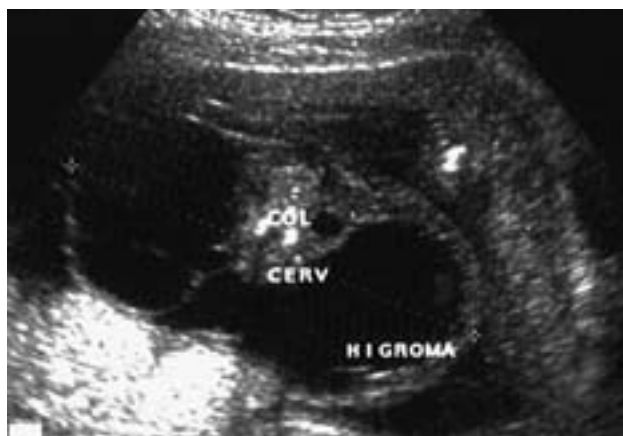

Figure 7. Cystic hygroma in fetus with Turner syndrome at 18 weeks of gestation
Slika 7. Cistični higrom u ploda od 18 tjedana s Turnerovim sindromom

abnormalities, and over 95% of them having Turner syndrome.¹⁸ Other echographic findings usually found in Turner syndrome in the second trimester include: lymphedema of the limbs, hydrothorax and ascites (Figure 5). The intrauterine death is usually caused by fetal hydrops with characteristic ultrasound finding resembling space suit (Figures 6, 7 and 8).

Turner syndrome is also associated with other abnormalities visible on the ultrasound like: cardiac abnormalities, especially of the left heart (coarctation of the aorta, defects of the aortic valve); renal abnormalities; skeletal dysplasia (shorten of the femoral bone), and some unspecific minor defects. All ultrasound signs presenting in fetuses with Turner syndrome (»sonographic

syndrome«) in the second trimester are more suggestive for the diagnosis than in other aneuploidies (especially in Down syndrome) (Figures 9 and 10). This is the reason why some authors believe that the diagnosis of Turner syndrome can rely on ultrasonic findings alone which is not the case in the diagnosis of Down syndrome.¹⁷ Whenever major anomalies are identified by ultrasound, even if they are isolated as in the case of severe hydrops, then karyotyping is indicated.

So called »sonographic syndrome« in the second trimester is also present in fetuses with triploidy. Ultrasound findings in triploidy include minor facial anomalies, facial asymmetry, low set ears, mild ventriculomegaly, multiple major structural defects of the internal organs, IUGR (asymmetric most frequently), oligohydramnios, placental abnormalities, cyst of the posterior fossa and syndactily (most frequently of the third and the fourth finger). Other possible ultrasound findings in triploidy are: hypertelorism and microphthalmos, micro-

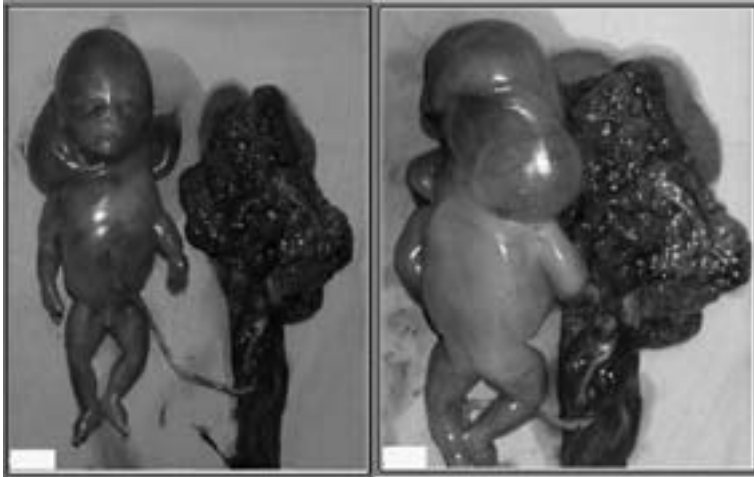

Figure 8. Image of aborted fetus with Turner syndrome at 18 weeks of gestation

Slika 8. Prikaz pobačenog ploda s Turnerovim sindromom nakon 18 tjedana trudnoće

gnathia, major facial anomalies (cleft), agenesis of corpus callosum, cardiac malformations, single umbilical artery, omphalocele, renal anomalies (Figures 11 and 12).

Jauniaux et al. investigated the role of ultrasonography and maternal serum human chorionic gonadotropin in the early prenatal diagnosis of triploid pregnancies.⁸ There were 18 cases of triploidy identified in the population of 58 862 singleton pregnancies giving a prevalence of 1 in 3270. Fetal defects were observed in 8 (44.4%) of these cases: holoprosencephaly in 4, exomphalos in 3, and posterior fossa cyst in 1. In 6 (33.3%) pregnancies the placenta showed molar changes. Fetal crown-rump length was below the 5th percentile in 10 out of the 16 (62.5%) cases for which the menstrual age was also available. Fetal nuchal translucency thickness was above the 95th percentile in 12 (66.7%) fetuses, and the fetal heart rate was below the 5th percentile in 4 out of the 13 (30.8%) examinees. The maternal human chorionic gonadotropin level was high in 11 out of the 13 (84.6%) cases, with similar distribution of the high values in molar and nonmolar triploidies. They concluded that the combination of ultrasonographic examination of

the fetoplacental features and measurement of the maternal serum level of human chorionic gonadotropin enable the diagnosis of triploidy at 10 to 14 gestational weeks in the majority of affected fetuses.⁸

Specific prenatal diagnosis of the Turner syndrome and perspectives for the direct non-invasive prenatal diagnosis of the chromosomal defects

The ultrasonically suspected diagnosis of monosomy X is confirmed by determination of karyotype of fetal cells obtained by amniocentesis or chorionic villi sampling of the product of conception in high risk pregnancies. The risk for miscarriage is 0,5% after chorionic villi sampling and amniocentesis in general, while it is 5% for early amniocentesis. To increase the detection rate and to decrease the loss of normal products of conception with optimal cost/benefit ratio, 5% of pregnancies with the highest genetic risk found by prenatal screening should be investigated invasively.

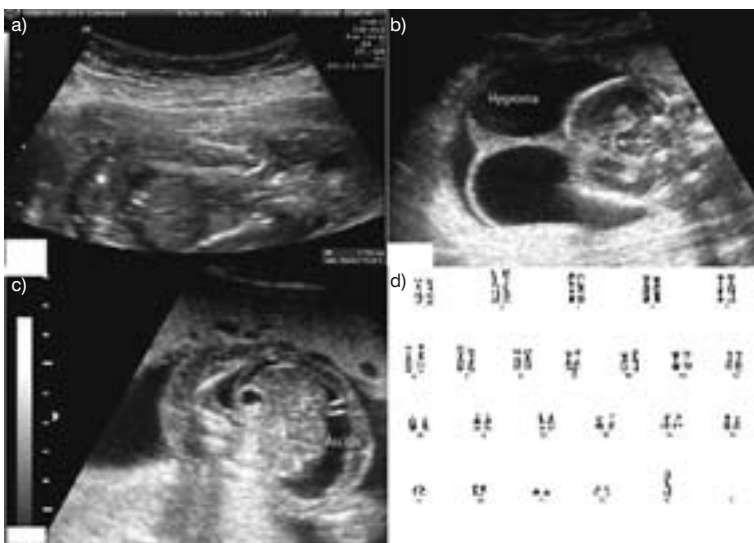

Figure 9. Sonographic markers of Turner syndrome in a fetus at 17 weeks of gestation

Slika 9. Ultrazvučni biljezi Turnerova syndrome u ploda sa 17 tjedana

a: short femur below the 5th percentile – kratak femur ispod 5. percentile; b: cystic hygroma – cistični higrom; c: ascites – ascites; d: karyotype – kariotip

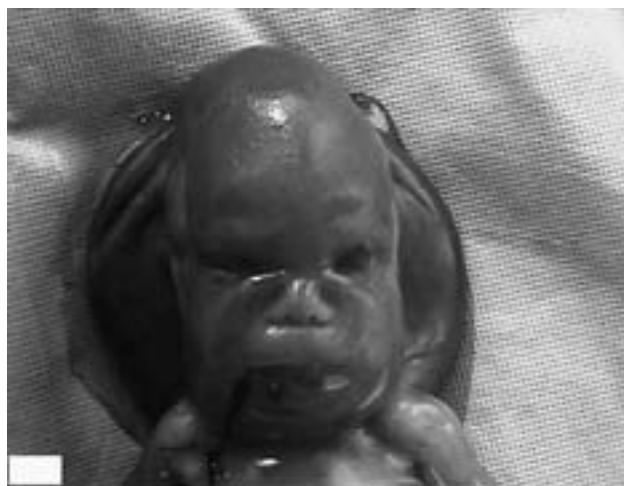

Figure 10. Appearance of aborted fetus from the Figure 9 with hydrops, cystic hygroma and morphological changes of the face

Slika 10. Izgled ploda sa slike 9 koji ima hidrops, cistični higrom i morfološke promjene na licu

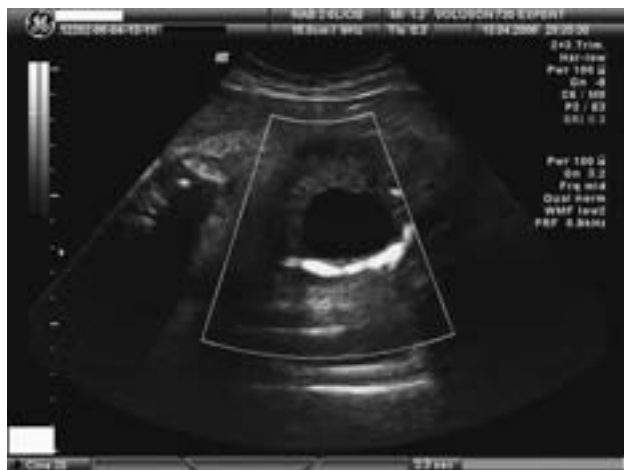

Figure 11. Fetus with triploidy at 22 weeks of gestation. Typical depiction of single umbilical artery

Slika 11. Plod gestacijske dobi od 22 tjedna s triploidijom. Vidljiva je jedna pupčana arterija

The risk of invasive procedures for prenatal diagnosis of fetal chromosomopathies is considered unacceptably high, which prompt the investigators to search for non-invasive methods of fetal genetic diagnosis. DNA analysis of fetal cells from maternal blood might be theoretically performed by fluorescent in situ hybridization

(FISH). It is necessary to concentrate fetal cells from maternal blood from 10^{-5} , to at least 10^{-2} , which can be experimentally done by magnetic or fluorescent activated cell sorting (MACS, respectively FACS) enabling separation of acceptable number of fetal cells from maternal blood for the analysis. Analysis of free fetal DNA from the maternal blood seems to be easier than the molecular genetic analysis of fetal cells. For the diagnosis of aneuploidy the quantitative analysis of free fetal DNA from maternal blood seems to be sufficient, as it was proved that free fetal DNA is significantly decreased in Turner syndrome and significantly increased in trisomies, compared with normal pregnancy.

Clinical aspects

From the point of view of the general practitioner and pediatrician, the diagnosis of *Turner syndrome* is usually simple, because of very suggestive phenotype of the female patients. Although some usual symptoms could be absent, if the female patients are presenting at puberty for the lack of onset of the secondary sexual characteristics, primary amenorrhea or even secondary amenorrhea, than Turner syndrome should be suspected. From the obstetrician's point of view, prenatal diagnosis of Turner syndrome is not so obvious and simple. The management of the pregnancy with affected fetus may create problems in practice, which should be solved in a tertiary perinatal center.

Triploidy syndrome is characterized by general dysmaturity, muscular hypotonia, large posterior fontanelle, low set dysmorphic auricles, hypertelorism, microphthalmia and coloboma, cutaneous syndactily of the third and the fourth finger, simian crease, micrognathia, major facial anomalies (cleft), holoprosencephly, agenesis of the corpus callosum, cardiac malformations, omphalocele, renal hypoplasia and other anomalies, hypospadias and/or maldeveloped external genitalia.²⁰

There were several studies presenting detection of structural fetal abnormalities in the first trimester by ultrasound. Malone and al.²¹ studied prevalence, natural history, and outcome of septated cystic hygroma in the first trimester of the general obstetric population, in order to differentiate this finding from the simple increased nuchal translucency. There were 134 cases of cystic hygroma (2 lost to follow-up) among 38 167 screened patients (1 in 285). Chromosomal abnormali-

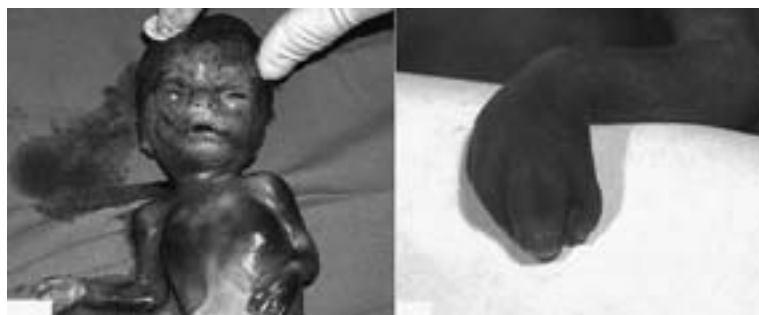

Figure 12. Appearance of aborted fetus with triploidy. Hypertelorism, microphthalmos, micrognathia, facial asymmetry, low set ears, syndactily of the 3rd and the 4th finger of the left hand should be noticed

Slika 12. Izgled ploda s triploidijom nakon pobačaja. Vidljive su sljedeće malformacije: hipertelorizam, mikroftalmija, mikrognatija, asimetrija lica, nisko položene uške, sindaktilija 3. i 4. prsta na lijevoj šaci

Table 2. Ultrasound findings in triploidy (adapted from reference¹⁹)
 Tablica 2. Ultrazvučni nalazi u triploidiji (prilagođeno prema referenci¹⁹)

Characteristic Osobina	Jauniaux 1996	Rijhisingai 1997	Mittal 1998	De Vigan 2001	Combined data Različiti podatci
Number of fetuses – Broj plodova	70	17	20	4444	151
Increased NT/hygroma – Proširen nuchalni nabor/higrom	11%	–	5%	7%	9%
Holoprosencephaly – Holoproencefalija	3%	–	–	4%	3%
Ventriculomegaly – Ventrikulomegalija	34%	23%	25%	21%	23%
Facial cleft – Rascjep lica	1%	–	–	2%	1%
Micrognathia – Mikrognatija	24%	–	–	–	24%
Abnormal limbs – Nakaznosti okrajina	49%	–	5%	–	38%
Abdominal wall defect – Defekti trbušne stjenke	6%	12%	0	4%	5%
Central nervous system abnormality Nakaznosti središnjeg živčanog sustava	29%	41%	45%	30%	35%
Cardiac defect – Srčane greške	31%	6%	5%	11%	20%
Intrauterine growth restriction – Intrauterini zastoj rasta	–	71%	55%	32%	44%
Urinary tract anomaly – Nakaznosti mokraćnoga sustava	11%	23%	15%	7%	13%
Myelomeningocele – Mijelomeningocela	7%	–	25%	–	9%
Oligohydramnios – Oligohidramnij	44%	59%	60%	–	50%
Posterior fossa anomaly – Nakaznosti stražnje lubanjske jame	7%	12%	0	–	7%
>1 anomaly – >1 nakaznosti	100%	94%	85%	79%	92%

ties were diagnosed in 67 (51%), including 25 trisomy-21, 19 Turner syndrome, 13 trisomy-18, and 10 others. Major structural fetal malformations (primarily cardiac and skeletal) were diagnosed in 22 of the remaining 65 cases (34%). There were 5 cases (8%) of fetal deaths and 15 cases of elective pregnancy termination without evidence of abnormality. Their opinion was that the first trimester cystic hygroma was a frequent finding in a general obstetric screening population. It has the strongest prenatal association with aneuploidy described to date, with significantly poorer outcome compared with simple increased nuchal translucency. Most pregnancies with normal evaluation at the completion of the second trimester resulted in a healthy infant with a normal pediatric outcome.²¹

The primary defect in the formation of the lymphatic vessels is a part of a larger phenomenon of the cell migration in embryogenesis and it seems to determine many defects including cardiovascular,²² which are described in the syndrome. Fetal tachycardia seems to be caused by the delay in the maturation of the parasympathetic system, which resulted with the lack of the physiological decrease in the heart rate after 9 weeks.¹⁵

In the newborn, the consequences of the defects in the formation of the lymphatic vessels are clinically relevant, presenting as:

- Lymphedema, generalized or localized on the dorsal part of the hands and feet;
- Pterygium colli (webbed neck), as a result of the resorption of the cystic hygroma from the intrauterine life; in 40% of the cases, the neck is short, with hypoplasia of the cervical vertebrae;
- Distortion and characteristically low set ears;
- Distortion of the nails in 70% of the cases.

The eponym Bonnevie-Ullrich refers to the cases with lymphedema of the extremities, significant nuchal

fold and pleural effusion/ascites/pericardial effusion, which resolve spontaneously.

In girls with Turner syndrome, the following observations can be found:

- Low stature with impaired relation between height and weight. Normal levels of GH and IGF1 in the childhood could be found. The improper somatic development is one of the definitive phenotypic characteristics of the female patients with Turner syndrome correlating with 45,XO karyotype, practically present in 100% of these patients. If in the first years of life in the patient with Turner syndrome the levels of GH and IGF1 are normal, from the age of 8 to 10 years it is decreasing probably due to the lack of estrogens to induce the normal dynamics of the puberty;²³
- Skeletal deformations: scoliosis, cubitus valgus, shortening of the 4th and the 5th metacarpal bone, high arched palate;
- Characteristic aspect of the face, with low set ears, low posterior hairline, thick eyebrows, micrognathia;
- Pectus excavatum with widely spaced nipples;
- Loss of hearing with progressive neuro-sensorial impairment, recurrent otitis media, defects in the formation of the temporal bone and of the synchondrosis between the sphenoid and the occipital bones, which lead to the abnormal positioning of the external hearing meatus and of the middle ear;
- Lack of initiation or slowly initiating puberty, primary amenorrhea, or even secondary amenorrhea in the patients in whom the primordial follicles remain undeveloped until the adolescence (rarely occurring in the 45,XO patients). 5–10% of the female patients with gonadal dysgenesis with 45,XO karyotype have in adolescence enough undeveloped ovarian follicles (approximately 10000) to

initiate the development of the breast and, less frequently, the menstruation;

- The cardiovascular disorders represent the major morbidity influencing prognosis in the patients with Turner syndrome. The cardiovascular defects resulting from the defective formation of the lymphatic system are present in almost 30% of these female patients. The left heart is most frequently affected, presenting as coarctation of the aorta (present in 10% of 45,XO patients), aortic valve defects, aortic valve atresia. Aortic dissection, which develops in relation to the coarctation or other defects in the formation of the aorta, is a well-known cause of death in Turner syndrome. Over 30% of the female patients with Turner syndrome, regardless of the age, have moderate arterial hypertension;
- Renal abnormalities, although present in more than one third of the female patients with Turner syndrome, have limited clinical relevance because they usually do not significantly influence the renal function;
- The cognitive function is generally normal in the female patients with Turner syndrome.

Pathophysiology

45,XO karyotype may theoretically result from non-disjunction in the meiosis in one of the parental gametogenetic lines, but it is possible to result from a mitosis defect i.e. the loss of a chromosome either during the germinal cell mitoses in the parental gametogenetic lines or between fertilization and the first mitotic division of the cells in the newly formed organism. It seems that these errors in the cellular division appear more frequently when one of the parental sexual chromosomes is abnormal. The chromosomal defect would determine the cellular division defect. At the first mitotic division, the phenomenon of the delay in anaphase (anaphase lag) may result in the loss of a sexual chromosome (which may be abnormal). The loss of the abnormal sexual chromosome is a phenomenon which may appear in the prenatal as well as in the postnatal period.

The hypothesis of the mitotic error involved in the onset of Turner syndrome is supported by clinical observations:

- Sporadic occurrence of the phenomenon, regardless of the maternal age (unlike Down syndrome or Klinefelter syndrome);
- High percentage of mosaicism cases;
- Existence of monozygotic twin pregnancies with 45,XO of one fetus and 46,XY of the other fetus.

The incidence of subjects with genetic mosaicism is dependent on the used analytical method. It ranges from 30–40% when conventional karyotyping techniques were used, or up to 75% when PCR amplification and *in situ* hybridization with specific Y probes were applied.²⁴ According to the recent investigations extremely high rate of in utero mortality of products of conception with pure 45,XO karyotype raised hypothesis that all survi-

vors with Turner syndrome have mosaicism. The hypothesis that all subjects with Turner syndrome, who survive till term have, at least initially, mosaic karyotype is supported by the following considerations:

- The existence of euploid cellular line in fetal membranes where selective imprinting phenomenon of the both sexual chromosomes takes place is required.
- The fact that at birth in most girls with Turner syndrome variable number of undegenerated follicles can be found, which means that two active X chromosomes were present to maintain the gametogenetic line.

Familial cytogenetic studies showed more frequent loss of X chromosome of paternal than maternal origin. It seems that in over 2/3 of the patients with Turner syndrome paternal X chromosome is lost, which is hard to explain. Although the influence of the specific imprinting of the remained X chromosome on the Turner phenotype was proved, it was not possible to demonstrate the advantage concerning the survival of the product of conception with X chromosome of maternal origin.²⁵ The identification and localization of the genes on X chromosome (»Turner genes«), whose haploid insufficiency leads to the Turner phenotype, started from the idea that these genes should exist also on the Y chromosome.²⁶ The most logical localization for these genes would be the pseudo-autosomal region of the short arms of the sex chromosomes, because it is the region participating in the crossing-over of the sex chromosomes during meiosis, and where most of the genes are not affected by the X-inactivation phenomenon. The cytogenetic study of the subjects with the karyotype 46,XYp revealed lack of the testicular determination factor SRY, which is the reason why they develop female phenotype, either with normal height or with Turner-like phenotype, depending on the additional deletions on Y chromosome. This fact enabled identification of a 700 kb segment in the pseudo-autosomal region at the end of the short arms of the sex chromosomes. The gene situated in this region, whose haploid insufficiency would determine the short stature in Turner syndrome, is known as short stature homeobox – gene on X chromosome (SHOX). Despite the fact that SHOX is involved in chondrogenesis, the lack of one of two active copies of the gene normally found in the cells of the normal individual, are (partially) responsible for the short stature in the female patients with Turner syndrome.

SHOX is just one of the »Turner genes« responsible for Turner phenotype which is determined by multiple factors. According to Ogata and Matsuo²⁷ there are at least three factors involved in the development of clinical features in Turner syndrome:

- Quantitative loss or impairment of the euchromatin from extensive regions of the X chromosome (up to the absence of the entire chromosome), with global and unspecific developmental deficiency of the organism;

- Haploid insufficiency of the growth pseudo-autosomal genes, normally active on both sex chromosomes and of the lymphogenic genes, with the appearance of the growth retardation and other »Turner marks«;
- Defective coupling of the sex chromosomes in the prophase of the first meiosis, with loss of the gametogenetic line and gonadal dysgenesis.

Three different mechanisms may produce triploidy: 1) nondisjunction in the first or in the second meiosis of spermatogenesis, resulting in an extra set of paternal chromosomes (diandry); 2) nondisjunction in the first or in the second meiosis of oogenesis, resulting in an extra set of maternal chromosomes (digyny); 3) double fertilization of a normal egg, resulting in an extra set of paternal chromosomes (dispermy).

The first mechanism accounts for 23,6% of triploidy cases, the second mechanism accounts for 10%, and the third mechanism for 66.4% of triploidy patients.²⁸ Type I (diandry) triploid pregnancy presents with large placenta, partial molar changes, severe symmetric growth restriction, elevated levels of maternal hCG, AFP, inhibin A, and rarely survives beyond the first trimester. Type II (digyny) pregnancy has a small placenta, asymmetric growth restriction, decreased levels of maternal hCG, AFP, inhibin A, and more often survives till the second trimester and eventually near term. No matter that incidence of digyny is decreased compared to diandry, it is more important for the diagnosis by ultrasound.

Defects of lymphogenesis in Turner syndrome develop due to the deficiency of the receptor for vascular endothelial derived growth factor 3 (VEGFR-3), protein whose production is controlled by the gene on X chromosome. The gene controlling production of BMX tyrosine-kinase enzyme involved in the mediation of the VEGF effects at intracellular level, whose deficiency affects early embryonic development, is also placed on the X chromosome. Turner syndrome is also characterized by defect of the great lymphatic vessel formation. Malformed lymphatic vessels are dilated due to the lack of their communication with the veins. Lymphatic vessel dilatation and intra-thoracic compression seem to determine the entire range of cardiovascular and other defects of the head and upper extremities described in the syndrome.

Gonadal dysgenesis in Turner syndrome is due to the fact that both X active chromosomes are required for the formation and maintaining of the gametogenetic line. Genes from both arms of the X chromosomes are involved in normal ovarian development. Primary germinal cells reach the gonadal ridge, but after the third month of gestation, the oocytes and the primordial follicles suffer an accelerated process of atresia, probably due to the impossibility to correctly perform the prophase of the first meiosis. Therefore, the ovaries undergo a fibro-connective degeneration resulting in their transformation into gonadal streaks. The fact that the

gonadal dysgenesis is caused by the accelerated atresia and not by the abnormal formation in the germinal cells was documented in the first studies about Turner syndrome. More recent studies show that in many cases this process of atresia is not that fast to be complete at birth, because almost one third of newborn girls with Turner syndrome have at birth ovaries which are visible on ultrasound with undegenerated follicles. These follicles may persist until after the puberty, determining the onset of the secondary sexual features, menarche and even fertility in the female patients with Turner syndrome. There is inter-individual variability of the speed of follicular atresia probably dependent on the specific X chromosome defect. The spontaneous onset of pregnancies in female patients with Turner syndrome can be explained by mosaicism or by the non-disjunction mitosis of germinal 45,XO cells, with the formation of 46,XX oocytes. The women with 45,XO cell lines have a higher rate of spontaneous abortions and children with chromosomal abnormalities, than the general population.

The consequences of the deletions of X chromosome are very variable providing to death in utero or to normal female phenotype, with menarche and even fertility, with the possibility of development of the secondary amenorrhea. The incidence of the mosaic karyotype with 45,XO lines in women with normal menstruation and fertility is unknown. The understanding of the phenotypic consequences of the genotypic abnormalities in Turner syndrome is the subject of detailed recent studies.²⁹

Because of the high death rate in the embryonic and fetal period, the majority of the Turner syndrome cases are diagnosed in the prenatal period. The prenatal diagnosis of the live fetuses with Turner syndrome, as well as the prenatal diagnosis of the non-lethal chromosomal defects in general, is important from social, ethical, medical and economical point of view.

Conclusions

The importance of a correct diagnosis for any child, in particular for families who are faced with »dysmorphic« baby, and who are planning to have further healthy children, cannot be overemphasized. According to our experience, pregnancies with malformed fetuses in our institution were terminated on time, and the families were correctly counseled that there is no recurrence risk of triploidy in the next pregnancy. This approach enabled parents to plan their next pregnancy after appropriate counseling provided by general practitioner and pediatrician. Pregnancies having the fetus with Turner syndrome are characterized by very high rate of in utero fetal mortality and spontaneous abortions. More than 99% of the pregnancies with conceptive product of conception with 45,XO karyotype have such fatal outcome.

In fetuses with ultrasonographically proved defects of the lymphatic circulation in the early pregnancy and/or intrauterine growth restriction associated with cardiovascular, renal or complex malformations later in preg-

nancy, Turner syndrome should be suspected. Ultrasound examination in Turner syndrome shows: increased NT at the end of the first trimester, cystic hygroma or even severe generalized lymphedema, moderate growth retardation and fetal tachycardia later in pregnancy. Almost all fetuses with Turner syndrome have septated cystic hygroma and hydrops, but not all fetuses with cystic hygroma and hydrops are Turners.

As a conclusion both triploidy and Turner syndrome must be taken in consideration if minor or major abnormalities in the first or in the second trimester of pregnancy are revealed on ultrasound. Active screening in the general population should be focused on the detection of all congenital anomalies and it is not justified for only these two conditions.

References

1. Jones KL. Triploidy syndrome and diploid/triploid mixoploidy syndrome. In: Smith's Recognizable Patterns of Human Malformation, 4th ed. Philadelphia: WB Saunders Company, 1988;32–3.
2. Hook EB, Warburton D. The distribution of chromosome genotypes associated with Turner's syndrome. *Hum Genet* 1993;64:24–7.
3. Nielsen J, Wohler M. Chromosome abnormalities found among 34910 newborn children: results of a 13-year study in Denmark. *Hum Genet* 1991;87:81–3.
4. Won J. Common Chromosomal Disorders. In: Case Based Pediatrics For Medical Students and Residents. An Online Introductory Pediatrics Textbook 2004; ch IV.3.
5. Goldberg JD, Norton ME. Genetics and Prenatal Diagnosis. In: Callen Ultrasonography in Obstetrics and Gynecology 4th ed. 2000:18–38.
6. Spencer K, Liao AW, Skentou H, et al. Screening for triploidy by fetal nuchal translucency and maternal serum free beta-hCG and PAPP-A at 10–14 weeks of gestation. *Prenat Diagn* 2000;20:495–9.
7. Sebire NJ, Snijders R, Brown R. Detection of sex chromosome abnormalities by nuchal translucency screenig at 10–14 weeks. *Prenat Diagn* 1998;18:581–4.
8. Jauniaux E, Brown R, Snijders RJ, et al. Early prenatal diagnosis of triploidy *Am J Obstet Gynecol* 1997;176:550–4.
9. Hyett J, Perdu M, Sharland G. Using fetal nuchal translucency to screen for major cardiac defects at 10–14 weeks. *Br Med J* 1999;318:81–5.
10. Zosmer N, Nicolaides KH et al. Early diagnosis of major cardiac defects in chromosomally normal fetuses with increased nuchal translucency. *Br J Obstet Gynecol* 1999;106:829–33.
11. Pandya PP, Kondylios A, Hilbert L. Chromosomal defects and outcome in 1015 fetuses with increased nuchal translucency. *Ultrasound Obstet Gynecol* 1995;5:15–9.
12. Falcon O, Wegrzyn P, Faro C, et al. Gestational sac volume measured by three-dimensional ultrasound at 11 to 13¹⁶ weeks of gestation: relation to chromosomal defects. *Ultrasound Obstet Gynecol* 2005;25:546–50.
13. Van Vugt JMG, Van Zalen RM, Kostense PJ. First trimester nuchal translucency: a risk analysis on fetal abnormality. *Radiology* 1996;200:537–40.
14. Nadel A, Bromley B, Benacerraf BR. Nuchal thickening or cystic hygromas in first and early second trimester fetuses: prognosis and outcome. *Obstet Gynecol* 1993;82:43–8.
15. Hyett JA, Brizot ML, McKie AT. Cardiac gene expression of atrial natriuretic peptide and brain natriuretic peptide in trisomic fetuses. *Obstet Gynecol* 1996;87:506–10.
16. Schemmer G, Wapner RJ, Johnson A. First-trimester growth patterns of aneuploid fetuses. *Prenat Diagn* 1997;17:155–9.
17. Bronshtein M, Zimmer EZ, Blazer S. A characteristic cluster of fetal sonographic markers that are predictive of fetal Turner syndrome in early pregnancy. *Am J Obstet Gynecol* 2003;188:1016–20.
18. Azar G, Snijders RJM, Gosden CM. Fetal nuchal cystic hygromata: associated malformations and chromosomal defects. *Fetal Diagn Ther* 1991;6:46–57.
19. Nyberg DA, Souter VL. Chromosomal abnormalities. In: Diagnostic Imaging of Fetal Anomalies. Philadelphia: Lippincott and Wilkins 2003;869.
20. Leisti JT, Raivio KO, Rapola MH, Saksela EJ, Aula PP. The phenotype of human triploidy. *Birth Defects Orig Artic Ser* 1974;10:248–53.
21. Malone FD, Ball RH, Comstock CH, et al. First-trimester septated cystic hygroma: prevalence, natural history, and pediatric outcome. *Obstet Gynecol* 2005;106:288–94.
22. Lacro RV, Jones KL, Benirschke K. Coarctation of aorta in Turner syndrome: a pathologic study of fetuses with nuchal cystic hygromas, hydrops fetalis and female genitalia. *Pediatrics* 1988;81:445–51.
23. Lippe BM. Turner syndrome. In: Sperling M (ed.). *Pediatric Endocrinology*. Philadelphia: WB Saunders, 1996;384–421.
24. Binder G, Koch A, Wajs E. Nested polymerase chain reaction study of 53 cases with Turner syndrome. *Clin Endocrinol Metab* 1995;80:3532–6.
25. Lorda-Sanchez I, Binkert F, Maechler M. Molecular study of 45X conceptuses: correlation with clinical findings. *Am J Med Genet* 1992;42:487–90.
26. Fergusson-Smith AC, Surani MA. Imprinting and the epigenetic asymmetry between parental genomes. *Science* 2001;293:1086–9.
27. Ogata T, Matsuo N. Turner syndrome and female sex chromosome aberrations: deduction of the principal factors involved in the development of clinical features. *Hum Genet* 1995;95:607–29.
28. Jacobs PA, Angell RR, Buchanan IM, Hassold TJ, Matsuyama AM, Manuel B. The origin of human triploids. *Ann Hum Genet* 1978;42:49–57.
29. Zinn AR. Growing interest in Turner syndrome. *Nat Genet* 1997;16:3–4.

Paper received: 10. 05. 2006.; *accepted:* 25. 08. 2006.

Address for correspondence: Professor Radu Vladareanu M.D. PhD, Department of Obstetrics and Gynecology, Carol Davila Medical School, Elias University Emergency Hospital, 17, Marasti Blvd, SE 1, 020322, Bucharest, Romania; E-mail: vladareanu@gmail.com