

Acute Appendicitis and Ileal Perforation with a Toothpick Treated by Laparoscopy

Zdravko Perko, Kanito Bilan, Zenon Pogorelić, Nikica Družijanić, Darko Sršen, Damir Kraljević, Joško Juričić and Dragan Krnić

Department of Surgery, University Hospital and School of Medicine, Split, Croatia

ABSTRACT

A 69-year-old man underwent an emergency laparoscopic procedure after the acute appendicitis diagnosis has been established. Laparoscopic exploration showed inflamed appendix and perforation of terminal ileum with a swallowed part of the wooden toothpick. The treatment consisted of typical laparoscopic appendectomy and laparoscopic removal of the foreign body, followed by laparoscopic closure of the perforation site and lavage of the abdominal cavity. The postoperative course was uneventful and the patient was discharged from the hospital on day 3 after the operation.

Key words: toothpick, laparoscopy, appendicitis, ileal perforation

Introduction

Only a few patients develop a bowel perforation after the ingestion of foreign bodies (four patients of 542 reported cases, or 0.7%)¹. Ingested foreign bodies are common clinical problem that requires endoscopic intervention in 10–20% of all cases; in addition, nearly 14% of all patients require emergency surgery^{1–4}.

Toothpick ingestion has been reviewed by Li and Ender, who reported that only 12% of all patients remember swallowing a toothpick, thus only a few such patients will present for endoscopic removal or radiological observation⁵. The review showed that toothpicks most frequently caused injury to the duodenum (25%); injury of the ileum was observed in only 9% of all patients⁵. Overall reported mortality after toothpick perforation of the intestines is 18%, indicating that toothpicks, which are generally regarded as relatively benign objects, may cause severe, sometimes even fatal, internal injuries⁵.

In this article we present a first case of the asymptomatic intestinal perforation with toothpick and acute appendicitis treated laparoscopically.

Case Report

A 69-year-old man presented to the emergency department with right lower quadrant abdominal pain. He reported a dull lower abdominal pain that lasted for sev-

eral days and sudden onset of the right lower quadrant pain 12 h prior to hospital admission. The pain increased during physical exertion.

Abdominal examination showed irritation of peritoneum within the right lower abdominal quadrant and tenderness all over abdominal wall.

Laboratory studies showed elevated leukocyte counts (15.0 G/L; normal range, 4–11 G/L). All other laboratory studies showed normal values.

After physical and laboratory examination, the patient underwent plain abdominal radiographic evaluation that showed no pathological changes. Subsequently, the patient underwent abdominal ultrasound that showed cholelithiasis and no free fluid in abdominal cavity.

The patient underwent laparoscopy with diagnosis of acute appendicitis. A pneumoperitoneum was installed through Veress needle and three trocars were inserted. The first 10 mm trocar was inserted supraumbilically and other two 5 mm trocars were inserted in left lower and right upper quadrant. Laparoscopic exploration revealed inflamed appendix and a part of toothpick sticking from the intestinal wall (Figure 1) – perforated terminal ileum toward mesentery, but toothpick was not in contact with appendix (Figure 2). There were no adhesions and no signs of peritonitis due to intestinal perforation. We performed typical laparoscopic appendectomy with

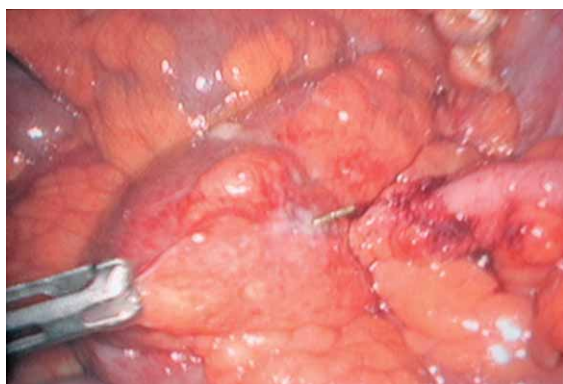


Fig. 1. Acute appendicitis and sticking toothpick.

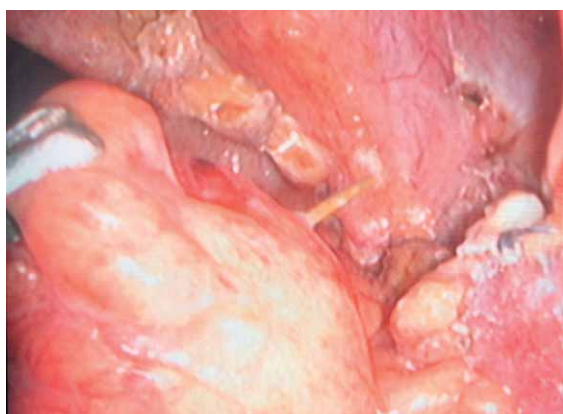


Fig. 2. Appendiceal stump and toothpick.

mesoappendix division using harmonic scalpel (UltraCision[®], Ethicon Endo Surgery, J&J, USA). The base of appendix was ligated with endo-loop. Resected appendix was sent for pathohistological analysis that showed acute inflammation. Finally the part of a toothpick sticking from ileal wall was pulled out (Figure 3 and 4). The site of perforation was sutured with two polyglactin intracorporally knotted stitches. Subsequently we performed a thorough lavage of abdominal cavity.

After the operation, the patient was treated on a general surgical ward. On the first postoperative day the patient was febrile, up to 38.2 °C and treated with two antibiotics (metronidasole and ceftriaxone sodium). After second day the patient was afebrile and completely tolerated peroral diet. On postoperative day 3 the patient was released from the hospital and fully recovered without complications.

Discussion

After the ingestion of foreign bodies only a few patients develop a bowel perforation, and nearly 14% of all patients require emergency surgery¹⁻⁴.

The toothpicks most frequently caused injury to the duodenum, and injury of the ileum was observed in 9% of

all patients only⁵. But, mortality after toothpick perforation of the intestines is quite high, up to 18%⁵.

In our case intestinal perforation was completely asymptomatic. The patient had acute appendicitis and ileal perforation was discovered during laparoscopic exploration in the beginning of laparoscopic appendectomy. Despite the high mortality rates reported after toothpick perforation of the intestines, published cases and our experience indicate that small bowel perforation following the ingestion of a toothpick or other foreign bodies can safely be treated via minimally invasive approach, even in patients with peritonitis or comorbid diseases⁶⁻¹⁰.

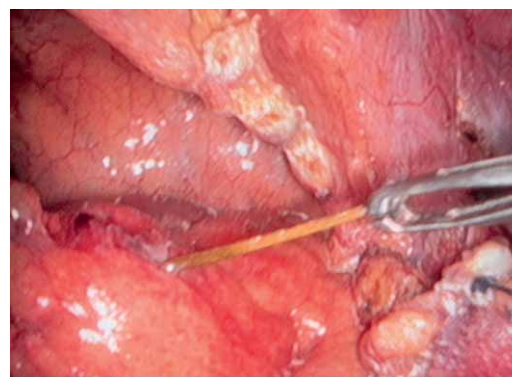


Fig. 3. A pulling out of a toothpick.

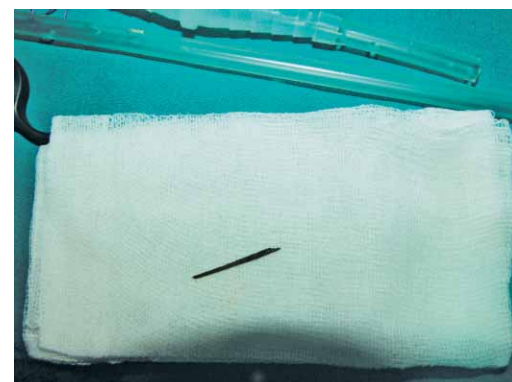

Fig. 4. A pulled out toothpick.

Conclusion

In our opinion, laparoscopic approach is the best way for treatment of acute appendicitis and, like in this case, it gives you the opportunity to diagnose and treat other diseases and conditions that may have been overlooked¹¹. We propose that diagnostic laparoscopy should be considered in all patients presenting with acute abdominal pain that requires surgical intervention. Nonetheless, emergency laparoscopy should only be performed by experienced surgeons in several laparoscopic procedures because different diseases can be diagnosed during routine laparoscopic exploration or procedure¹².

REFERENCES

1. VELITCHSKOV NG, GRIGOROV GI, LOSANOFF JE, KJOSSEV KT, World J Surg, 20 (1996) 1001. — 2. SCHWARTZ GF, POLSKY HS, Ann Surg, 42 (1976) 236. — 3. SELIVANOV V, SHELDON GF, CELLO JP, CRASS RA, Ann Surg, 199 (1984) 187. — 4. WEBB WA, Gastrointest Endosc, 41 (1995) 39. — 5. LI SF, ENDER K, J Emerg Med, 23 (2002) 35. — 6. HEBRA A, DAVIDOFF AM, AHMAD S, STOCKMANN PT, STAFFORD PW, J Laparoendosc Surg, 968 (1996) S95. — 7. IANNELI A, SIOU P, SPINELLI R, ANDRESCU F, BLOCH P, Surg Endosc, 16 (2002) 538. — 8. NEUMANN U, FIELITZ J, EHLERT HG, Chirurg, 71 (2000) 1405. — 9. ZINGG U, VORBURGER S, METZGER U, Chirurg, 71 (2000) 841. — 10. WICHMANN MW, HÜTTL TP, BILLING A, JAUCH KW, Surg Endosc, 18 (2004) 717. — 11. PERKO Z, ČALA Z, KOŠUTA D, VELNIC D, BAKULA B, ZORIČIĆ I, RASIĆ Z, Lijec Vjesn, 118 (1996) 291. — 12. MEYER G, HÜTTL TP, Surg Endosc, 15 (2001) 229.

Z. Perko

Department of Surgery, University Hospital and Medical School Split, Spinčićeva 1, 21000 Split, Croatia
e-mail: zperko@kbsplit.hr

LAPAROSKOPSKO LIJEČENJE AKUTNOG APENDICITISA I PERFORACIJE ILEUMA UZROKOVANE ČAČKALICOM

SAŽETAK

69. godišnji muškarac doveden je na hitan laparoskopski zahvat, nakon postavljene dijagnoze akutnog apendicitisa. Laparoskopskom eksploracijom nađe se upaljeni crvuljak i perforacija terminalnog ileuma progutanom čačkalicom. Učini se tipična laparoskopska apendektomija i u istom aktu odstrani se strano tijelo. Laparoskopski se zašije mjesto perforacije i učini lavaža trbušne šupljine. Pacijent se otpušta trećeg dana nakon operacije u dobrom općem stanju, bez komplikacija.