

Dexeus Institute, Barcelona, Spain

## MANAGEMENT OF COMPLICATED PULMONARY SEQUESTRATION IN TWIN PREGNANCY

### POSTUPAK KOD KOMPLICIRANE PLUĆNE SEKVESTRACIJE U BLIZANAČKOJ TRUDNOĆI

*Pilar Prats, Alberto Vásquez, Margarita Torrents, Bernat Serra, Jose M. Carrera*

*Professional paper*

*Key words:* pulmonary sequestration, fetal therapy, twins

**SUMMARY.** It is well established that fetal pulmonary sequestration complicated by non-immune hydrops fetalis is associated with a high risk of mortality; however, antenatal management remains controversial in these rare cases. The main therapeutic strategies aim to drain the effusions *in utero*, although there is still debate as to the most adequate drainage route. The two main options are thoracoamniotic shunting and serial thoracocenteses. Others include medical inotropic therapy, alcohol ablation of the vascular pedicle, open fetal surgery and ablation of the feeding vessel with laser surgery. We report the case of a twin pregnancy in which one of the fetuses was affected by an extralobar pulmonary sequestration with large hydrothorax that was successfully treated with serial thoracocenteses.

*Stručni članak*

*Ključne riječi:* pulmonalna sekvestracija, fetalna terapija, blizanci

**SAŽETAK.** Poznato je da je fetalna plućna sekvestracija komplicirana neimunološkim hidropsom povezana s visokim rizikom mortaliteta; prenatalni postupak je u tim rijetkim slučajevima proturječan. Glavna terapijska strategija je u *in utero* drenaži izljeva, a još se raspravlja o najprikladnijem načinu drenaže. Dvije su glavne mogućnosti: torako-amniotska prijemnica i ponovljene serijske torakocenteze. Druge mogućnosti su medikamentozna inotropna terapija, ablacija vaskularne peteljke alkoholom, otvorena fetalna kirurgija i laserska ablacija opskrbe krvne žile. Prikazana je blizanačka trudnoća s ekstralobarnom plućnom sekvestracijom i jakim hidrotoraksom u jednoga fetusa, uspješno liječena serijskom torakocentezom. U 35. tjednu trudnoće je počeo spontani porod, dovršen carskim rezom. Nezahvaćeni fetus je bio težine 1800 grama, a zahvaćeni 2700 grama. Zahvaćeno novorođenče je trebalo ventilatornu potporu, a s 26 dana života učinjen je kirurški zahvat. Nakon jedne godine života oba su novorođenčeta zdrava.

## Introduction

Bronchopulmonary sequestration is a mass of abnormal, non-functioning pulmonary tissue that does not communicate with the normal tracheobronchial tree and whose blood supply is from the systemic circulation. Lesions receive systemic arterial blood supply from an aberrant aortic branch.<sup>1</sup> Venous drainage is typically through the azygous system or the inferior vena cava; however, in 25% of cases the venous drainage is through the pulmonary veins. Anatomically, there are two subtypes of pulmonary sequestration: the intralobar mass located within the substance of a lung lobe, and an extralobar one, which has its own pleural investment.<sup>2</sup> On prenatal ultrasonography, an extralobar pulmonary sequestration appears as a well-defined, echodense, homogeneous mass. The detection by colour flow Doppler ultrasonography of a systemic artery arising from the aorta to the fetal lung lesion is a pathognomonic feature of this pathology.<sup>3,4</sup> Rarely, sonographic findings may also include pleural effusion, mediastinal compression, hydrops and polyhydramnios.<sup>5</sup>

In cases with hydrops the prognosis is poor and associated with a high rate of perinatal mortality and severe

respiratory insufficiency in the newborn.<sup>6</sup> The prognosis depends on the size of the lung mass and the secondary pathophysiological effects: mediastinal shift, polyhydramnios, hypoplasia and cardiovascular compromise leading to fetal hydrops and death. However, the management of fetal hydrothorax is controversial given the fact that *in utero* spontaneous resolution has been described.<sup>7</sup> Draining these effusions *in utero*, and thereby decompressing the fetal thorax, can improve survival, although the best means to effect adequate drainage remains controversial.<sup>8</sup> Some authors advocate serial thoracocenteses, whereas others recommend thoracoamniotic shunting.<sup>9</sup>

We report the case of a twin pregnancy in which one of the fetuses was affected with a pulmonary sequestration.

## Case report

A 35-year-old woman (gravida 4, para 0) achieved pregnancy after IVF using frozen donor semen. At 8 weeks gestation a diagnosis of bichorial diamniotic twin pregnancy was made. At 20 weeks ultrasound scan was completely normal, and showed a first fetus that was female and a second one male, with normal development. At 25 weeks of amenorrhea ultrasound scan revealed a

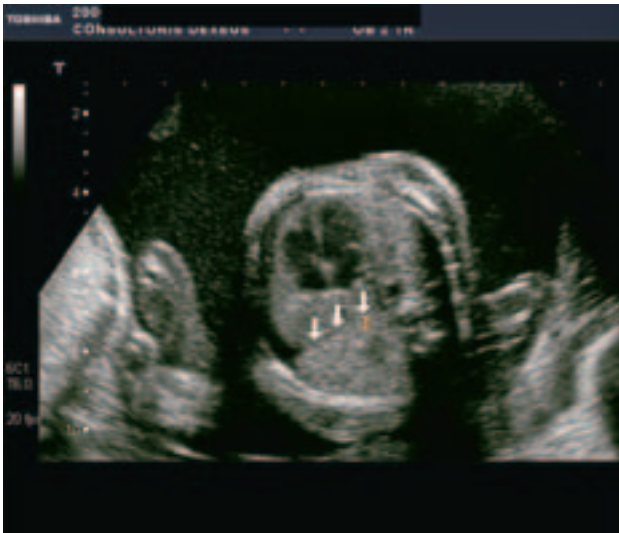

Figure 1. Right echogenic lung mass and hydramnios  
Slika 1. Desna ehogena plućna masa i hidramnios

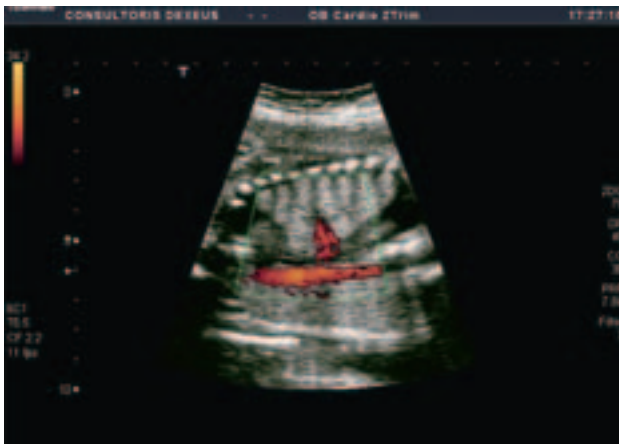

Figure 2. Feeding vessel arising from the thoracic aorta  
Slika 2. Opskrbna krvna žila iz torakalne aorte

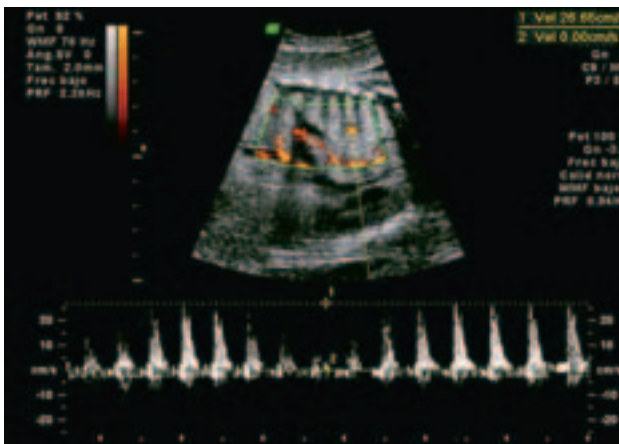


Figure 3. Feeding vessel arising from the thoracic aorta with power Doppler (pulse waved)  
Slika 3. Opskrbna krvna žila koja polazi iz torakalne aorte. Prikaz osnaženim doplerom

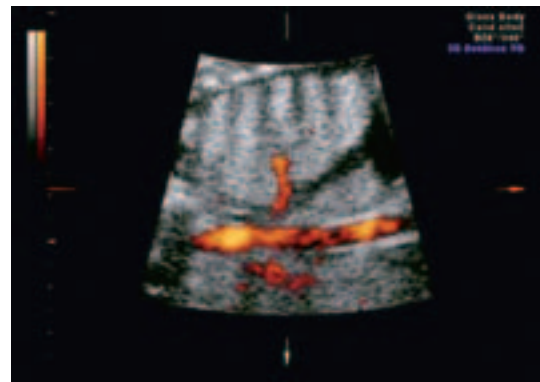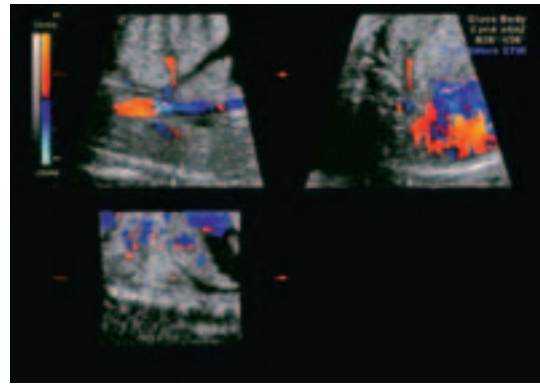


Figure 4. Feeding vessel arising from the thoracic aorta with 3D sonography  
Slika 4. Opskrbna krvna žila iz torakalne aorte prikazana 3D ultrazvukom

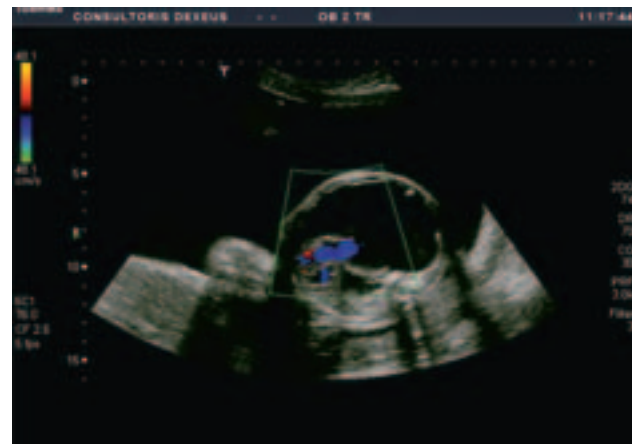

Figure 5. Fetal echocardiography: heart, unilateral right hydrothorax and polyhydramnios  
Slika 5. Fetalna ehokardiografija: srce, jednostrani desni hidrotoraks i polihidramnion

second fetus (male) with mild hydramnios and a right echogenic lung mass of 39×27 mm (Figure 1).

Colour flow Doppler and 3D sonography showed a systemic artery arising from the thoracic aorta feeding the mass (Figures 2, 3, 4).

Echocardiography was also performed and showed unilateral right hydrothorax due to the presence of a lung mass, and agenesis of right pulmonary veins. Heart and vessels appeared as normal (Figure 5).

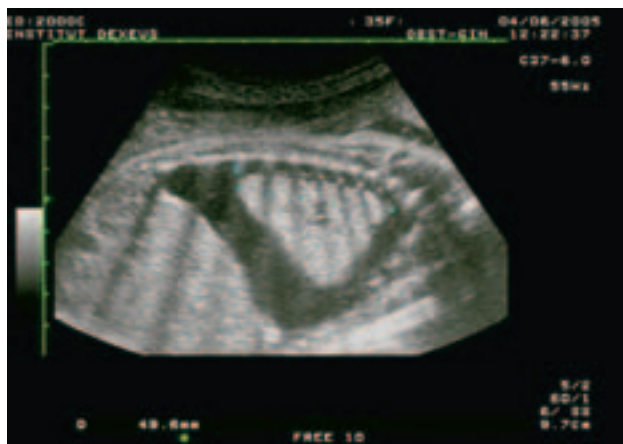

Figure 6. Large unilateral hydrothorax and solid lung mass  
Slika 6. Veliki jednostrani hidrotoraks i solidna plućna masa

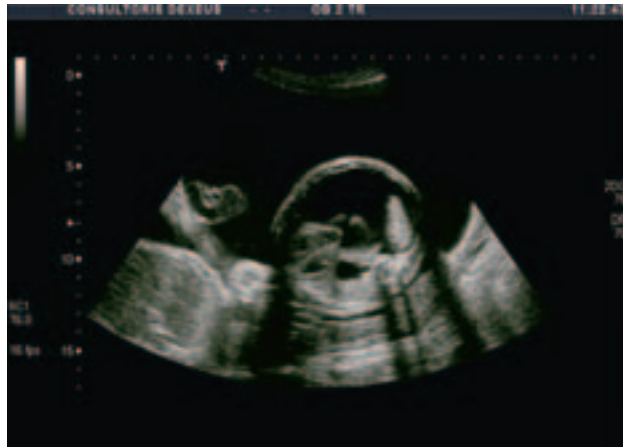
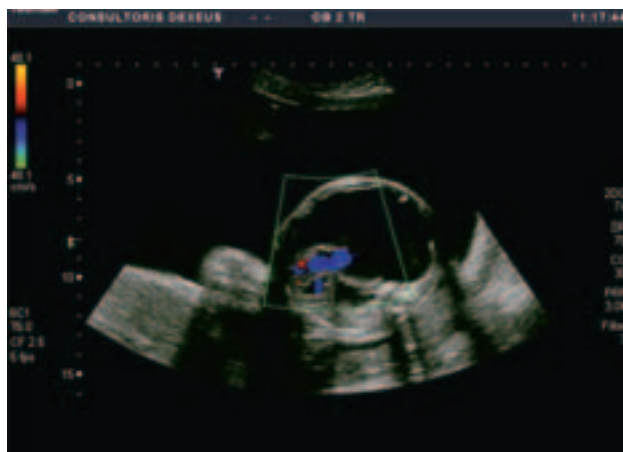
Figure 7. Mediastinal, cardiac and diaphragmatic shift  
Slika 7. Pomak mediastinuma, srca i ošita

We also performed magnetic resonance imaging (MRI) in an attempt to diagnose the aetiology of the lung mass, in the event that this would provide further information. However, the MRI only revealed a solid lung mass with a feeding vessel, with no other associated pathology. We thus considered *pulmonary sequestration* as the most feasible diagnosis due to the presence of a solid chest

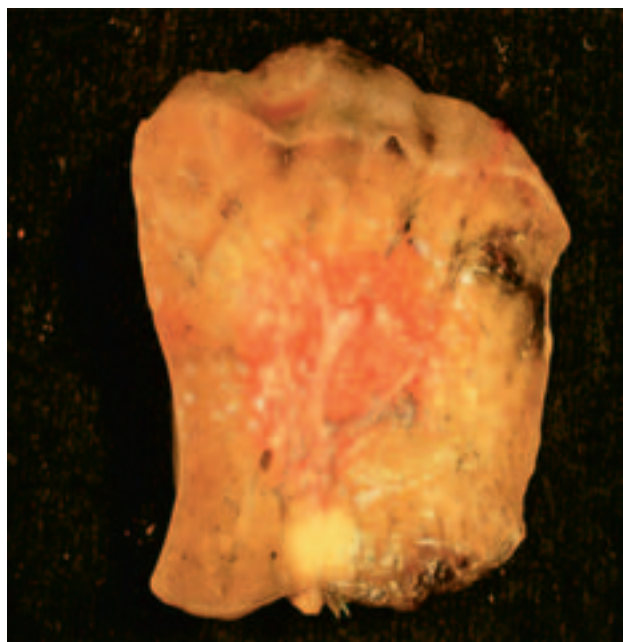


Figure 8. Macroscopic view of the pulmonary sequestration after surgical removal  
Slika 8. Makroskopski izgled plućne sekvestracije nakon kirurškog odstranjenja

Table 1. Amniodrainages and thoracocenteses. Fluid drained in each manoeuvre  
Tablica 1. Drenaže amniona i torakocenteze. Tekućina crpljena pri svakom postupku

	Amniodrainage	Fetal Thoracocentesis
29 weeks	2,000 ml	100 ml
30 weeks	1,400 ml	50 ml
31.3 weeks	3,000 ml	90 ml
32.5 weeks	3,000 ml	90 ml
34 weeks	2,000 ml	–
34.3 weeks	2.750 ml	–

mass with a lobar shape and a feeding vessel arising from the aorta.

Follow-up scans at 26 and 28 weeks revealed a first fetus with oligohydramnios and a second fetus with increased polyhydramnios, large unilateral hydrothorax of 65×45mm (Figure 6), mild ascites, mediastinal, cardiac and diaphragmatic shift (Figure 7), and a right echogenic pulmonary mass of 45 mm.

The first fetus showed intrauterine growth retardation at 30 weeks gestation. The patient was under tocolysis treatment from 28 to 34 weeks. Ultrasonographic follow up of cervix measurement changes showed this to be reduced during the pregnancy, thus threatening a premature labour. Fetal maturation with β-methasone was administered at 28 weeks.

Due to the increasing polyhydramnios and large hydrothorax, amniodrainage and thoracocentesis were performed at 29 weeks. This manoeuvre was repeated weekly until 34 weeks gestation due to the increasing



hydramnios and hydrothorax over time. *Table 1* shows the amounts of amniotic and thoracic fluid drained in each serial manoeuvre.

The patient went into spontaneous labour at 35 weeks and a caesarean delivery was performed; this produced a first fetus weighing 1980 g and a second fetus (affected) weighing 2700 g. The affected fetus required ventilatory support and surgery was performed at 26 days of life. The pathologist confirmed the diagnosis of extralobar pulmonary sequestration (*Figure 8*). Surgery was very successful. The fetus showed no effects of pulmonary compression, and both neonates are now healthy at one-year follow up.

## Discussion

Routine application of ultrasonography enables a more frequent antenatal diagnosis of congenital lung malformations, particularly pulmonary sequestration and cystic adenomatoid malformation. Lung masses represent an important and diverse group of fetal anomalies. The two most common are congenital cystic adenomatoid malformation (CCAM) and bronchopulmonary sequestration (BPS), which seem to be pathologically and clinically distinct but frequently overlap.<sup>4</sup>

BPS involves a developmental mass of non-functioning bronchopulmonary tissue that is separated from the tracheobronchial tree and receives arterial blood from the systemic circulation. Pryce was the first to coin the term »sequestration« (from Latin »sequestra«, meaning to remove or separate) to describe this disconnected bronchopulmonary mass or cyst with an anomalous systemic arterial supply.<sup>10</sup> Two subtypes were primarily defined: the intralobar mass located within the substance of the lung lobe, and the extralobar one, which has its own pleural investment. The extralobar subtype can occur in the chest, including the pericardial sac, or in the abdomen, whereas the intralobar subtype is limited to the lung.<sup>4</sup>

Intralobar sequestrations account for 75–85% of all sequestrations diagnosed in adults and are rarely detected in fetuses. In contrast, nearly all the sequestrations diagnosed prenatally are extralobar. While they are reported to account for 0.5 to 6% of all congenital lesions of the thorax,<sup>11</sup> extralobar sequestrations are known to account for a greater proportion of lung masses detected before birth. In one series, pulmonary sequestration accounted for at least 12–16% of fetal chest masses misdiagnosed as CCAMs,<sup>12</sup> and in another series published by Adzick extralobar sequestration accounted for 23% of the 175 fetal chest masses reported.<sup>8</sup>

According to Achiron et al.,<sup>4</sup> CCAM and BPS frequently overlap and terms such as »hybrid form« and »missing link« are confused, although they often appear in the literature.<sup>13,14</sup> These new conflicting data are the tip of the iceberg of conjecture and controversy surrounding the aetiology and pathogenesis of fetal lung lesions. Achiron et al.<sup>4</sup> state that the classification of lung anomalies according to traditional criteria has become

irrelevant. They review the latest pathological and pathogenic aspects of CCAM and BPS in an attempt to draw a parallel with prenatal ultrasound diagnosis, and propose a new classification system based on the pathogenesis of these malformations and their two-dimensional and colour Doppler ultrasound characteristics. They demonstrated the applicability of this new classification in a clinical setting.<sup>15</sup>

## Diagnosis

Extralobar pulmonary sequestrations are detected sonographically as well-circumscribed echogenic masses, lobar or triangular in shape, and mostly in the base of the left fetal chest. They tend to be small or moderately sized lesions. Large sequestrations may occur and can cause mediastinal shift and hydrops. The echotexture of the mass is usually homogeneous, although cysts are occasionally observed.

Visualization of a systemic artery arising from the thoracic or abdominal aorta feeding the mass strongly favours the diagnosis of extralobar pulmonary sequestration. The introduction of new technologies, such as three-dimensional power Doppler ultrasound, has been shown to be useful in identifying the feeding vessel and thus establishing the diagnosis of pulmonary sequestration.<sup>16</sup> In the case we report, colour flow Doppler and three-dimensional power Doppler imaging showed a systemic artery arising from the thoracic aorta feeding the lung mass at 25 weeks of gestation. We believe that demonstration of the vascular supply to the lesion is probably the most important clue to the diagnosis of BPS.

A hydrothorax ipsilateral to the mass may occur in 5–10% of cases of extralobar pulmonary sequestration. In a series published by Illanes,<sup>17</sup> the median gestational age at diagnosis was 21 weeks. In this series the association with mediastinal shift, hydrothorax and hydrops fetalis was the most predictive of prognostic factors. The association with hydrops fetalis and poor outcome in the presence of an echogenic lung is well-known. There are several publications confirming high rates of intrauterine or neonatal death with hydrops, even as high as 100%.<sup>8,18</sup> According to Illanes et al.,<sup>24</sup> in spite of the assessment of other prenatal markers, fetal hydrops proved to be the single most useful predictor of fetal death.

The likelihood of other anomalies is increased slightly in association with extralobar pulmonary sequestration. Some authors report an associated anomaly rate as high as 50–65%.<sup>19,13</sup> There are few reports associating lung masses with aneuploidy.<sup>20,21</sup> However, because of the low incidence of chromosomal abnormalities, karyotyping is only recommended in cases with associated abnormalities.<sup>24</sup>

## Prognosis and Management

There is a wide spectrum of clinical severity for fetuses with a lung mass such as pulmonary sequestration;

this includes lesions that remain stable in size as the pregnancy progresses, those that decrease or even disappear<sup>3,7,22</sup> and others associated with the development of hydrops. However, spontaneous regression occurs much less frequently for lesions with hydrops and therefore hydropic cases require fetal intervention. Indeed, the association between hydrops fetalis and poor outcome in the presence of pulmonary sequestration is well established.

Pulmonary sequestrations may compromise the prenatal development of functioning parenchymal lung tissue, and the resultant pulmonary hypoplasia at birth leads to significant perinatal morbidity and mortality. Hydrops fetalis may develop and the association with polyhydramnios may also increase the risk of prematurity, furthering the risk of perinatal loss. As pulmonary sequestration can now be readily diagnosed the question arises as to whether any *in utero* intervention can improve prognosis.<sup>30</sup> We have found that the overall prognosis depends on the size of the lung mass and secondary pathophysiological effects. If the pleural effusion is small and no mediastinal shift is demonstrated intervention might not be justified; on the other hand, if significant mediastinal shift or hydrops develop, intervention is warranted.<sup>8,23,24</sup>

The main treatment consists in decompressing the fetal hydrothorax by *in utero* thoracoamniotic shunting or repeated thoracocentesis, which have been reported to improve the prognosis.<sup>9,25–29</sup> There are also reports of successful expectant management in hydropic fetuses with lung sequestration. Other therapeutic options include medical inotropic therapy,<sup>30</sup> alcohol ablation or laser ablation of the vascular pedicle. These various strategies of *in utero* management have been designed to relieve mediastinal compression, thus allowing subsequent *ex utero* surgical treatment.

Open fetal surgery and immediate delivery is not well considered due to the high risk of neonatal death in hydropic infants, in whom resuscitation manoeuvres are particularly difficult.<sup>31</sup>

In 2006, Know et al.<sup>30</sup> published a review about *in utero* management of primary hydrothorax and congenital cystic lung lesions complicated with pleural effusion. They selected the most relevant papers about the effect of prenatal pulmonary drainage (shunt, drainage or surgery) on perinatal survival and compared them with papers that reported cases with lung pathology that underwent no treatment. They concluded that in fetuses affected with hydrops fetalis, *in utero* drainage improved their perinatal survival. However, the authors highlight the absence of randomized studies and long-term follow-up. Otherwise, there is no agreement as to the timing and exact clinical presentation which would benefit from *in utero* treatment.

The present case is interesting because of the coexistence of a normal fetus and an affected fetus with a lung abnormality, the latter with poor prognosis due to the presence of increasing and enlarged hydrothorax and

polyhydramnios. We have only found two papers in the literature reporting cases of twin pregnancies in which one fetus was affected with increasing pleural effusion.<sup>32,33</sup> In both cases one fetus was affected by primary pleural effusions and treated with thoracoamniotic shunting. The shunt was inserted successfully before twenty weeks gestation, subsequent to which the lungs re-expanded and the hydrops resolved.

We have not found any reports of twin pregnancy in which one fetus was affected with a lung mass complicated with hydrothorax and polyhydramnios, as in our case. Fetal therapy such as shunting was the best choice to treat the affected fetus, but in our case the pregnancy was threatened by preterm labour at the moment the hydrops and polyhydramnios were diagnosed. Because of this, thoracoamniotic shunting was not considered as a possibility. A preterm delivery could have complicated the outcome of both fetuses, the one affected with pulmonary sequestration and the other healthy one; indeed, the main morbidity associated with fetal surgery is preterm delivery (71% incidence has been reported).<sup>35</sup> The increasing hydrothorax and polyhydramnios meant that spontaneous regression of the symptoms was highly unlikely, and thus conservative management (no treatment) was also ruled out.

Given the above, and after consulting with fetal surgery specialists, we decided to perform amniodrainage and single needle pleural fluid aspirations. Thoracocentesis alone often results in rapid reaccumulation of fluid, because the underlying pathophysiological cause of the effusion has not been corrected. We thus had to perform serial amniodrainage and thoracocentesis to avoid the accumulation of fluid and prevent fetal lung hypoplasia.

## Conclusion

We believe that each case should be evaluated in an individual and integral way. The survival rate in cases of pulmonary sequestrations may be improved with the appropriate investigation and therapy. The decisive criteria are the underlying defect as well as the severity and progression of the hydrothorax. The choice of which therapy should be performed remains controversial, although thoracoamniotic shunting appears as the first strategy.<sup>34</sup> Twin pregnancies make the decision more difficult because of the presence of a healthy and an affected fetus.

## References

1. Savic B, Birtel FJ, Tholen W, Funke HD, Knoche R. Lung sequestration: report of seven cases and review of 540 published cases. *Thorax* 1979;34:96–101.
2. Jones DA, Vill MD, Izquierdo LA. Lung sequestration, extralobar intrathoracic. [www.thefetus.net](http://www.thefetus.net)
3. Lopoo JB, Goldstein RB, Lipshutz GS, Goldberg JD, Harrison R, Albanese CT. Fetal pulmonary sequestration: a favorable lung lesion. *Obstet Gynecol* 1999;94:567–71.

4. Achiron R, Heges J, Yagel S. Fetal lung lesions: a spectrum of disease. New classification based on pathogenesis, two-dimensional and color Doppler ultrasound. *Ultrasound Obstet Gynecol* 2004;24:107–14.
5. Dolkart LA, Reimarers FT, Helmut WV, Porte MA, Eisinger G. Antenatal diagnosis of pulmonary sequestration: a review. *Obstet Gynecol Surv* 1992;47:515–20.
6. Nicolini U, Cerri V, Groli C, Poblete A, Mauro F. A new approach to prenatal treatment of extralobar pulmonary sequestration. *Prenatal Diagn* 2000;20:758–60.
7. Langer B, Donato L, Riethmuller C, Cecmeur F, Dreyfus M, Favre R, Schlaeder G. Spontaneous regression of fetal pulmonary sequestration. *Ultrasound Obstet Gynecol* 1996;5:33–9.
8. Adzick NS, Harrison MR, Crombleholme TM, Flake AW, Howell LJ. Fetal lung lesions: management and outcome. *Am J Obstet Gynecol* 1998;179:884–9.
9. Salomon LJ, Audibert F, Dommergues M, Vial M, Frydman R. Fetal thoracoamniotic shunting as the only treatment for pulmonary sequestration with hydrops: favorable long-term outcome without postnatal surgery. *Ultrasound Obstet Gynecol* 2003;21:299–301.
10. Pryce DM. Lower accessory pulmonary artery with intralobar sequestration of lung: a report of 7 cases. *J Pathol* 1946;58:457–67.
11. Levi A, Findler MI, Dolfin T, Di Segni E, Vidne BA. Intrapericardial extralobar pulmonary sequestration in a neonate. *Chest* 1990;98:1014–5.
12. Dommergues ML, Sylvestre C, Mandelbrot L, Aubry MC, Revillon Y. Congenital adenomatoid malformation of the lung: when is active fetal therapy indicated? *Am J Obstet Gynecol* 1997;177:953–8.
13. Cass DL, Crombleholme TM, Howell LJ, Stafford PW, Ruchelli ED, Adzick NS. Cystic lung lesions with systemic arterial blood supply: a hybrid congenital adenomatoid malformation and bronchopulmonary sequestration. *Pediatr Surg* 1997;37:986–90.
14. MacKenzie TC, Guttenberg ME, Nisenbaum HL, Johnson MP, Adzick NS. A fetal lung lesion consisting of bronchogenic cyst, bronchopulmonary sequestration and congenital cystic adenomatoid malformation: the missing link. *Fetal Diagn Ther* 2001;16:193–5.
15. Achiron R, Zalel Y, Lipitz S, Hegesh J, Mazkerereth R, Kuint J, Jacobson J, Yagel S. Fetal lung dysplasia: clinical outcome based on a new classification system. *Ultrasound Obstet Gynecol* 2004;24:127–33.
16. Ruano R, Benachi A, Aubry MC, Revillon Y, Emond S, Dumez Y. Prenatal diagnosis of pulmonary sequestration using three-dimensional power Doppler ultrasound. *Ultrasound Obstet Gynecol* 2005;25:128–33.
17. Illanes S, Hunter A, Evans M, Cusick E, Soothill P. Prenatal diagnosis of echogenic lung: evolution and outcome. *Ultrasound Obstet Gynecol* 2005;26: 145–9.
18. Miller JA, Corteville JE, Langer JC. Congenital cystic adenomatoid malformation in the fetus: natural history and predictors of the outcome. *J Pediatr Surg* 1996;31:805–8.
19. Piccione W Jr, Burt ME. Pulmonary sequestration in the neonate. *Chest* 1990;97:244–6.
20. Heling KS, Tennstedt C, Chaoui R. Unusual case of a fetus with congenital cystic adenomatoid malformation of the lung associated with trisomy 13. *Prenat Diagn* 2003;23:315–8.
21. Roberts D, Sweeny E, Walkinshaw S. Congenital cystic adenomatoid malformation of the lung coexisting with recombinant chromosome 18. A case report. *Fetal Diagn Ther* 2001;16:65–7.
22. Da Silva OP, Ramanan R, Romano W, Bocking A, Evans M. Non immune hydrops fetalis, pulmonary sequestration and favorable neonatal outcome. *Obstet Gynecol* 1996;88:681–3.
23. Knox EM, Kilby MD, Martin WL, Khan KS. In utero pulmonary drainage in the management of primary hydrothorax and congenital cystic lung lesion: a systematic review. *Ultrasound Obstet Gynecol* 2006;28:726–34.
24. Achiron R, Strauss S, Seidman DS, Lipitz S, Mashiach S, Goldman B. Fetal lung hyperechogenicity: prenatal ultrasonographic diagnosis, natural history and neonatal outcome. *Ultrasound Obstet Gynecol* 1995;6:40–2.
25. Becmeur F, Horta-Geraud P, Donato L, Sauvage P. Pulmonary sequestrations: prenatal ultrasound diagnosis, treatment and outcome. *J Pediatr Surg* 1998;33:492–6.
26. Gallardo JM, Guzman ME, Acevedo S, Velazquez B, Zapien AL. Thoracoamniotic shunts and thoracocentesis in fetal therapy. *Ginecol Obstet Mex* 2005;73:579–90.
27. Smith RP, Illanes S, Denbow ML, Soothill PW. Outcome of fetal pleural effusions treated by thoracoamniotic shunting. *Ultrasound Obstet Gynecol* 2005;26:63–6.
28. Picone O, Benachi A, Mandelbrot L, Ruano R, Dumez Y, Dommergues M. Thoracoamniotic shunting for fetal pleural effusions with hydrops. *Am J Obstet Gynecol* 2004;191:2047–50.
29. Hamada H, Yasuoka M, Urushigawa K, Watanabe H, Sohda S, Kubo T. Successful treatment of primary fetal hydrothorax with hydrops with pleuroamniotic shunt placement. *Arch Gynecol Obstet* 2001;256:53–4.
30. Morrow RJ, Macphail S, Johnson JA, Ryan G, Farine D, Knox Ritchie JW. Midtrimester thoracoamniotic shunting for the treatment of fetal hydrops. *Fetal Diagn Ther* 1995;10: 92–4.
31. Anandakumar C, Biswas A, Chua TM, Choolani M, Chia D, Wong YC, Gole L. Direct intrauterine fetal therapy in a case of bronchopulmonary sequestration associated with non-immune hydrops fetalis. *Ultrasound Obstet Gynecol* 1999;13: 263–5.
32. Prontera W, Jaeggi ET, Pfsenmaier M, Tassaux D, Pfister RE. Ex utero intrapartum treatment (EXIT) of severe fetal hydrothorax. *Arch Dis Child Fetal Neonatal Ed* 2002;86:F58–60.
33. Lam H, Yates R, Jauniaux E. Successful early in utero management of fetal hydrothorax in a twin pregnancy. *Prenat Diagn* 2003;23:221–4.
34. Greisaru-Granovsky S, Seaward PG, Windrim R, Wyatt P, Nelly EN, Ryan G. Mid-trimester thoracoamniotic shunting for the treatment of fetal primary pleural effusions in a twin pregnancy. A case report. *Fetal Diagn Ther* 2000;15:209–11.
35. Cortes RA, Farmer DL. Recent Advances in Fetal Surgery. *Seminars in Perinatology*, 2004;28:199–211.

*Paper received: 14.07.2007; accepted: 25.10.2007.*

*Address for correspondence:* Pilar Prats, MD, Department Obstet. Gynaecol. & Reprod. Medicine, Institut Universitat Dexeus, C / Calatrava 83, 08017 Barcelona, Spain