

BLEPHAROPLASTY: RADIOSURGERY *VERSUS* CONVENTIONAL SURGERY

Ivana Merc, Renata Iveković and Zdravko Mandić

University Department of Ophthalmology, Sestre milosrdnice University Hospital, Zagreb, Croatia

SUMMARY – The aim of the study was to evaluate the efficacy of a monopolar radiosurgery for blepharoplasty. This was a prospective trial in which upper eyelids of 28 patients were treated. Patients underwent a single treatment session: one eyelid was performed with monopolar radiosurgery while contra-lateral eyelid was performed with conventional surgery. The follow-up was 6 months. Assessments were made by the surgeon and by masked physician. The majority of patients, till 3th months postoperatively achieved the slightly better aesthetic results at radiosurgery sides, but no achieved dramatic results were acived. There were no serious adverse sequelae. Human eyelids can be safely treated with monopolar radiosurgical device. Using this technology healing were the same or slightly better on side treated with radiosurgery.

Key words: *Radiosurgery; Monopolar radiosurgical device; Blepharoplasty*

Introduction

Blepharoplasty has been employed for functional and cosmetic purposes. Different modalities have been utilized to incise and remove excess eyelid tissue in an attempt to improve surgical technique. Peer-reviewed literature indicates that radiofrequency has many advantages over the cold knife in this kind of procedure, including better handling, extreme rapidity and precision in cutting the skin, and finally reduced tissue damage with a subsequently quicker repair process and less fibrous scarring¹⁻⁶.

Till now, we did not have personal experience using radiosurgery on performing cosmetic surgery. So, we wanted to discover the advantages of radiosurgery through the use of high-frequency low temperature Erbotom unit from Erbe® (Germany).

Erbotom is a radiosurgical device with high frequencies (4 MHz) for use in oculoplastic surgery. Four different operational functions are available: cutting with minimal coagulation, combined cutting and coagulation,

and coagulation and fulguration. The high frequency, low temperature radiosurgical device generates high voltage on monopolar electrodes to convert a conductive irrigant such as normal saline into an ionized vapor or plasma. This induces molecular dissociation in the adjacent tissue, the short half-life of the ions limiting tissue damage. The electrodes and high voltages allow for the process to occur at a relatively low temperature (100-160 °C). When the electrosurgical device is used to treat articular cartilage, the residual thermal damage in surrounding tissue has been shown to be as little as 100 μm^7 .

Methods

This was a prospective trial conducted at our department. Twenty eight Caucasian patients were enrolled (23 women and 5 men; age range 60-75 years). Inclusion criteria were eyelid laxity, moderate blepharochalasis, minimum age 60, and willingness to participate in the study. Exclusion criteria were previous eyelid surgery and unwillingness to complete the follow up.

After undergoing a screening baseline ophthalmic examination, the subjects underwent radiosurgery in

Correspondence to: *Ivana Merc, MD*, Ivana Trnaskog 12, HR-10000 Zagreb, Croatia

E-mail: sobotai@net4u.hr

one upper eyelid and conventional surgery in the contralateral eyelid. Simulated markings were measured and drawn in the following manner. From the medial edge of the supratarsal crease, a line is drawn at 45 degrees, ending at a point 6 mm from the angular vein of the nose. From the lateral edge of the supratarsal crease, a line is drawn at 45 degrees within a skin crease, ending at a point 12 mm from the lateral palpebral fissure. The inferior marking follows the existing or desired supratarsal crease (8-10 mm above the lid margin), and the superior marking allows for axial skin excision (as determined by 'pinch test') while respecting a 10-mm minimum requirement for infrabrow supratarsal eyelid skin.

All subjects received local subcutaneous injection with 4 cc of 2% lidocaine with 1/200,000 adrenaline, using a 27-gauge needle. The sides were alternately assigned to be treated with either radiosurgery or conventional surgery. Incisions on one side were performed with the use of the high-frequency 4.0 MHz, low temperature Erbotom ICC 50 unit from Erbe® (Germany), in monopolar, cut and coagulate mode, with the scalpel electrode. The electrode was applied firmly enough to just indent the premarked skin. Dissection was then performed with fine curved scissors. Incisions on the other side were made superficially with a fresh No. 15 blade through the epidermis, and premarked strip of skin was resected with the fine curved scissors. Incisions were closed with 6-0 nylon interrupted simple sutures. Patients underwent post-treatment ophthalmic examination. Photographic documentation was obtained at conclusion of treatment on day 1 and 5 (for suture removal), then at 1, 2, 3 and 6 months of treatment. At each follow up visit, patients were assessed for wound healing by side-by-side comparison by the surgeon and by masked physician. Results were assessed as No difference, Minimally/moderately better radiosurgery side, or Minimally/moderately better conventional surgery side.

The primary endpoints studied were cosmetic result and visibility of the scars. Secondary endpoints in-

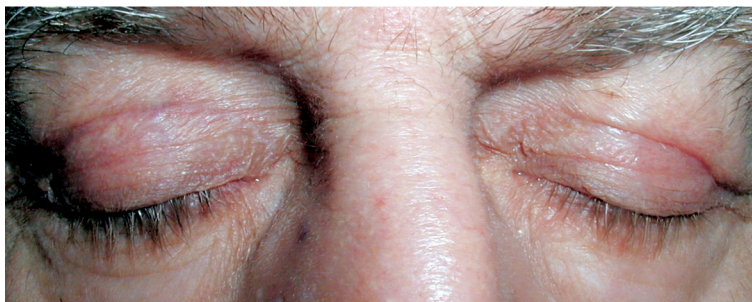


Fig. 1. Scar quality one month after blepharoplasty: right eyelid – radiosurgery; left eyelid – conventional surgery.

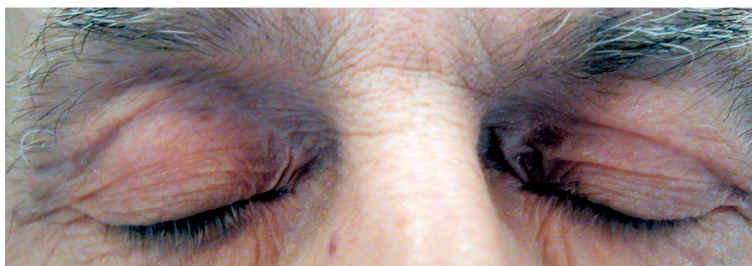


Fig. 2. Scar quality three months after blepharoplasty: right eyelid – radiosurgery; left eyelid – conventional surgery.

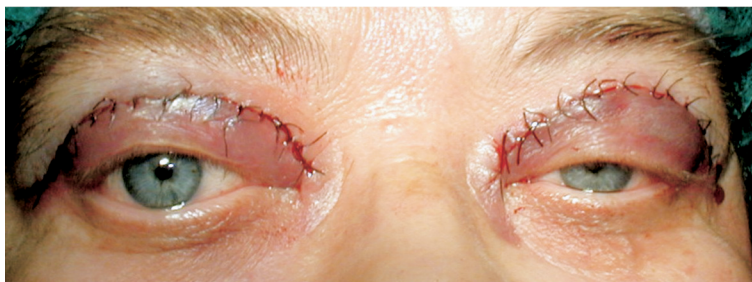


Fig. 3. Post-treatment swelling and ecchymosis less pronounced on the side treated with radiosurgery (right eyelid).

cluded intraoperative time, hemostasis, swelling and ecchymosis.

Results

There were 23 (82.1%) female and five (17.8%) male subjects, age range 60 to 81 (mean age 72) years. All subjects completed the study.

The 3-month pooled data collected from investigator assessment revealed approximately 80% of subjects to have a minimally better radiosurgery side (Figs. 1 and 2). Six months after treatment there was no difference between the two sides (Fig. 2).

Mild post-treatment swelling and ecchymosis developed in all study subjects, however, in all patients it was less pronounced on the side treated with radiosurgery (Fig. 3). The use of the radiosurgical device resulted in a reduced operative time (4 ± 1.3 min).

Discussion and Conclusion

Although the aim of the study was primarily to assess the cosmetic result of the procedure performed by use of the radiosurgical device, the patients served as their own controls on comparison with conventional surgery widely used in blepharoplasty. In our hands and used as described, the radiosurgical device produced minimal collateral tissue damage, wound healing was relatively short and the degree of ecchymosis relatively low. We found that radiosurgery caused minimal tissue damage and only slightly modified superficial epithelial cell layer without causing it to slough. The tissue was cut cleanly, with less bleeding than with scissors incision.

The 3-month follow up showed a significantly better wound healing. In most patients, the scar was not visible on the side treated with radiosurgery as compared with the side treated with conventional surgery. However, we have to admit that the difference in wound healing was subtle.

This study demonstrated that the radiosurgical device resulted in slightly enhanced wound healing, while producing almost bloodless field and reducing operative time. It is concluded that radiosurgery facilitates performance of blepharoplasty. Collateral damage is minimal allowing for rapid healing and cosmetically acceptable scar.

References

1. RITLAND JS, TORKZAD K, JUUL R LYDRSEN S. Radiosurgery *versus* conventional surgery for dermatochalasis. *Ophthal Plast Reconstr Surg* 2004;20:423-5.
2. ROHRICH RJ, COBERLY DM, FAGIEN S, STUZIN JM. Current concepts in aesthetic upper blepharoplasty. *Plast Reconstr Surg* 2004;113:32e-42e.
3. MORAX S, TOUITOU V. Complications of blepharoplasty. *Orbit* 2006;25:303-18.
4. HALVORSON EG, HUSNI NR, PANDYA SN, SEKEL BR. Fali naslov članka. *Ann Plast Surg* 2006;56:569-72.
5. BIESMAN BS, BAKER SS, CARRUTHERS J, SILVA HL, HOLLMAN EL. Monopolar radiofrequency treatment of human eyelids: a prospective, multicenter, efficacy trial. *Lasers Surg Med* 2006;38:890-8.
6. HURWITZ JJ, JOHNSON D, HOWARTH D, MOLGAT YM. High-frequency radio wave electrosection of full-thickness eyelid tissues. *Can J Ophthalmol* 1993;28:28-31.
7. ACLAND KM, CALONJE E, SEED PT, C STAT, BARLOW RJ. A clinical and histologic comparison of electrosurgical and carbon dioxide laser peels. *J Am Acad Dermatol* 2001;44:496-6.

Sažetak

BLEFAROPLASTIKA: RADIOKIRURGIJA PREMA KONVENCIONALNOJ KIRURGIJI

I. Merc, R. Iveković i Z. Mandić

Cilj ove studije bio je istražiti učinkovitost monopolarne radiokirurške tehnike kod operacije blefaroplastike. Radilo se o prospektivnom istraživanju gdje su operirane gornje vjeđe 28 bolesnika. Bolesnici su podvrgnuti jednoj operaciji, jedna vjeđa je operirana monopolarnom radiokirurškom tehnikom, dok je druga operirana klasičnom kirurškom metodom, a zatim su bolesnici praćeni u seriji do 6 mjeseci. Operater i liječnik koji nije znao koja je strana operirana određenom tehnikom ocjenjivali su kvalitetu ožiljka. Većina bolesnika imala je do trećeg mjeseca praćenja nešto bolji izgled ožiljka na strani operiranoj radiokirurškom tehnikom, ali ta razika nije bila znatna. Nisu zabilježene veće komplikacije. Gornje vjeđe mogu se sigurno operirati monopolarnom radiokirurškom tehnikom. Uz primjenu radiokirurške tehnologije cijeljenje je jednako ili nešto bolje na strani operiranoj radiokirurškom tehnikom.

Ključne riječi: *Radiokirurgija; Monopolarna radiokirurška tehnika; Blefaroplastika*



TRAVATAN

(travoprost 0,004%, kapi za oči)

Cjelokupni odobreni sažetak svojstava lijeka te cjelokupna odobrena uputa sukladni su člancima 16. i 22. Pravilnika o načinu oglašavanja i obavješćivanja o lijekovima, homeopatskim i medicinskim proizvodima ("Narodna pravina" broj 62/05).

... a jedan
se izdvaja iz grupe:

**NIŽI INTRAOKULARNI
TLAK NA KRAJU DANA**

Alcon PRIJE PROPISIVANJA MOLIMO PROUČITE SAŽETAK OPISA SVOJSTAVA LIJEKA.