

BACTERIAL KERATITIS – EMPIRICAL TREATMENT OR THERAPY ACCORDING TO ANTIBIOTIC SENSITIVITY REPORT

Rajko Kordić, Shkelqim Kica and Irena Vladušić

University Department of Ophthalmology, Zagreb University Hospital Center, Zagreb, Croatia

SUMMARY – Despite a wide spectrum of antibiotics available, bacterial keratitis remains one of the leading causes of blindness in the world. The aim of this report is to give an account of patients with initial treatment modification according to antibiotic sensitivity report. Records of 44 keratitis patients treated during the 2005-2006 period were retrospectively analyzed. There were 32, three and nine patients with a clinical picture bacterial, fungal and viral keratitis, respectively. Corneal scrapings were obtained in 28 patients, and positive results were recorded in only five cases. The initial antibiotic therapy was modified in three patients with fungal agents identified.

Key words: *Bacterial keratitis; Antibiotic sensitivity report; Therapy modification*

Introduction

Despite a wide spectrum of antibiotics available, infectious keratitis remains one of the leading causes of blindness in the world. Bacterial keratitis is considered the leading cause of monocular blindness in the developing world¹. Since these infections in most cases represent preventable or treatable ophthalmic disease, thorough understanding of the epidemiology, diagnosis and treatment of various forms of keratitis is essential for eye-care practitioners and public health officials. If defense mechanisms are compromised, for instance, lid abnormalities, poor tear production, epithelial problems or trauma, microorganisms can penetrate in the cornea and the infection appears². In developing countries, corneal infections often follow a trauma, while in western world there are ever more reports of corneal infections after transplant and refractive procedures on the cornea^{3,4}.

A variety of agents, e.g., gram positive cocci (*Staphylococcus*, *Streptococcus*, *Pneumococcus*), gram positive bacilli

(*B. cereus*, *Corynebacterium*), filamentous bacteria (*Actinomyces*, *Nocardia*), gram negative cocci (*N. gonorrhoeae*, *N. meningitidis*), and *Mycobacteria* spp., can cause corneal infections⁵.

The key features of corneal infection are cellular infiltration of the corneal epithelium and/or stroma, corneal inflammation and necrosis. Associated features are lid edema, injection and chemosis of the conjunctiva, mucous discharge and anterior chamber reaction (Figs. 1 and 2). For all these reasons, appropriate initial treatment is of utmost importance⁶.

The aim of this report is to give an account of patients with infectious keratitis and those with bacterial keratitis where initial treatment was modified according to antibiotic sensitivity report.

Patients and Methods

Records of patients treated at Department of Anterior Eye Segment Diseases, University Department of Ophthalmology, Zagreb University Hospital Center, during the 2005-2006 period were retrospectively analyzed. There were 44 patients with clinical diagnosis of infectious keratitis (20 female and 24 male) aged 20-75 (mean 45) years, 32 of them with clinical diagnosis of

Correspondence to: *Head Doctor Rajko Kordić, MD, PhD*, University Department of Ophthalmology, Zagreb University Hospital Center, Kišpatičeva 12, HR-10000 Zagreb, Croatia

E-mail: rajko.kordic@zg.t-com.hr

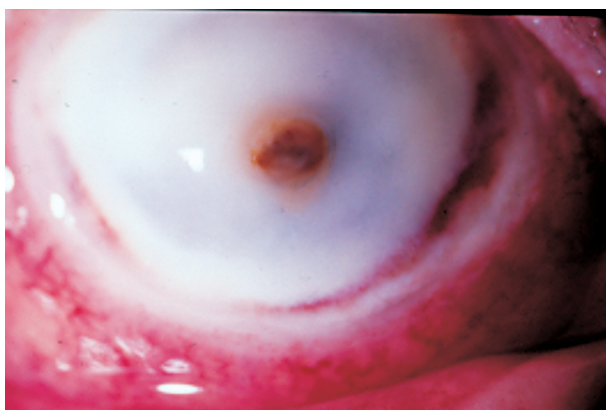


Fig. 1. Keratitis with descemetocoele (*Pseudomonas*).

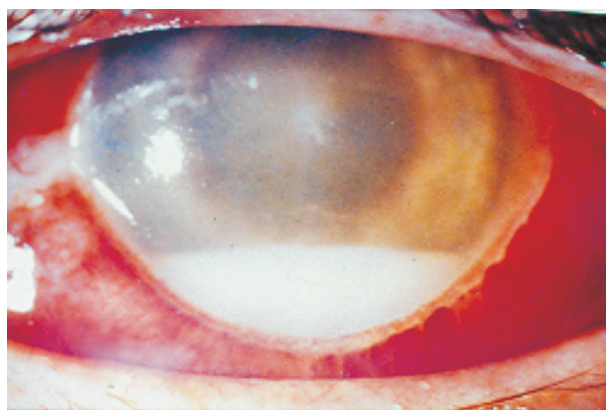


Fig. 2. Keratitis with hypopyon (*Staphylococcus aureus*).

bacterial keratitis (14 female and 18 male) aged 24-75 (mean 49) years.

Results

A total of 44 patients were admitted with a clinical diagnosis of infectious keratitis. Clinical picture indicated bacterial keratitis in 32 (72.7%), viral keratitis in nine (20.5%) and fungal keratitis in three (6.8%) patients. Scrapings were obtained in 28 patients: ten in 2005 and 18 in 2006. Positive results were recorded in only five (18%) patients, i.e. two in 2005 and three in 2006. *Pseudomonas* and *Staphylococcus aureus* were detected in one patient each, whereas *Candida* was diagnosed in three patients. Thirty-five patients had already received antibiotic therapy before hospital admission (aminoglycoside in 31 patients and a combination of aminoglycoside and sulfafurazole in four patients). Initial treatment was only modified in the three patients with scrapings positive for *Candida* because a fungal agent was identified. Results are summarized in Tables 1 and 2.

Discussion and Conclusion

Bacterial keratitis is an ocular emergency and antibiotic treatment should be promptly initiated⁷. The

Table 1. Patients with infectious keratitis

Causative agent	2005	2006	Total
Bacterial	9	23	32 (72.7%)
Fungal	1	2	3 (6.8%)
Viral	7	2	9 (20.5%)
Total	17	27	44

treatment is initiated with empirical therapy that can subsequently be modified according to antibiotic sensitivity report. If clinical signs subside, the treatment can be continued despite negative scraping result⁶. A broad spectrum coverage can be achieved either with the use of a fluoroquinolone antibiotic (monotherapy) or by a combination of an aminoglycoside with a cephalosporin or vancomycin (dual therapy)⁸⁻¹⁰.

In our group of 44 patients with infectious keratitis, clinical picture indicated bacterial infection in 32 (72.7%), viral infection in nine (20.5%) and fungal infection in three (6.8%) patients. Scrapings were obtained in 28 patients and proved positive in only five patients (*Pseudomonas* and *Staphylococcus aureus* in one patient each, and *Candida* in three patients).

In our patient population, the rate of positive scrapings was very low, i.e. 5 (18%) of 28 cases where scrapings were obtained. Because of the low rate of positive scrapings, we applied empirical topical dual treatment with cephalosporin and aminoglycosides (tobramycin 1.5% and cefazolin 5%-7.5%) in patients with bacterial keratitis. We modified treatment in the three patients where a fungal agent was identified.

That low rate of positive scrapings, only 5 (18%) of 28, could be explained by the fact that all patients where

Table 2. Five (18%) positive of 28 scrapings tested in two groups (10 in 2005 and 18 in 2006)

Verified agent	2005	2006	Total
<i>Pseudomonas</i>	1	0	1
<i>Staphylococcus aureus</i>	0	1	1
<i>Candida</i>	1	2	3
Total	2	3	5

scrapings were obtained had already been on initial antibiotic therapy.

References

1. PEPOSE JS, WILHELMUS KR. Divergent approaches to the management of corneal ulcers. *Am J Ophthalmol* 1992;114:630-2.
2. WHITCHER JP. Corneal ulceration. *Int Ophthalmol Clin* 1990;30:30-2.
3. WOODWARD M, RANDLEMAN B. Bilateral methicillin-resistant *Staphylococcus aureus* keratitis after phorefractive keratectomy. *J Cataract Refract Surg* 2007;33:316-9.
4. SRINIVASAN S, McALLUM P, POUTANEN S, SLOMOVIC AR. Bilateral simultaneous *Achromobacter xyloxidans* keratitis following penetrating keratoplasty. *J Cataract Refract Surg* 2006;32:2149-52.
5. SCHAEFER F, BRUTTIN O, ZOGRAFOS L, GUEX-CROSIER Y. Bacterial keratitis: prospective clinical and microbiological study. *Br J Ophthalmol* 2001;85:842-7.
6. KOWAL VO, LEVEY SB, LAIBSON PR, RAPUANO CJ, COHEN EJ. Fali naslov članka. *Arch Ophthalmol* 1997;115:462-5.
7. McLEOD SD, La BREE LD, TAYYANIPOUR R. The importance of initial management in the treatment of severe infectious corneal ulcers. *Ophthalmology* 1995;102:1943-8.
8. McLEOD SD, KOLAHDOUZ-ISFAHANI A, ROSTAMIAN K. The role of routine smears, cultures and antibiotic sensitivity testing in management of suspected infectious keratitis. *Ophthalmology* 1996;103:23-8.
9. O'BRIEN TP, MAGUIRE MG, FINK NE. Efficacy of ofloxacin vs cefazolin and tobramycin in the therapy for bacterial keratitis: report from the bacterial keratitis study research group. *Arch Ophthalmol* 1995;113:1257-65.
10. CHARUKAMNOETKANOK P, PINEDA RII. Controversies in management of bacterial keratitis. *Int Ophthalmol Clin* 2005;45:199-210.

Sažetak

BAKTERIJSKI KERATITIS – EMPIRIJSKO LIJEČENJE ILI TERAPIJA PREMA NALAZU ANTIBIOGRAMA

R. Kordić, Sh. Kica i I. Vladušić

Bakterijski keratitis je i uz širok spektar dostupnih antibiotika još uvijek jedan od vodećih uzroka sljepoće u svijetu. Cilj ovoga rada je prikazati broj bolesnika od bakterijskog keratitisa kojima je modificirana početna antibiotska terapija prema nalazu antibiograma. Za razdoblje 2005.-2006. godine analizirane su povijesti bolesti 44 bolesnika s kliničkom dijagnozom keratitisa. Nađena su 32 bolesnika s kliničkom slikom bakterijskog keratitisa, 3 bolesnika s kliničkom slikom gljivičnog keratitisa i 9 bolesnika s kliničkom slikom virusnog keratitisa. Bris rožnice uzet je u 28 bolesnika, ali je samo u 5 zabilježen pozitivan nalaz. Početna antibiotska terapija modificirana je u 3 bolesnika s gljivičnom etiologijom.

Ključne riječi: *Obostrani keratitis, antibiogram, terapijska modifikacija*

