

LASER MANAGEMENT OF PERSISTENT PUPILLARY MEMBRANE PRIOR TO CATARACT SURGERY

Kajo Bučan¹, Ljubo Znaor¹, Karmen Jurašin¹, Diana Bučan², Davor Galetović¹ and Mladen Lešin¹

¹University Department of Ophthalmology, Split University Hospital Center; ²Dr. Diana Bučan Clinic of Occupational Medicine, Split, Croatia

SUMMARY – Persistent pupillary membrane (PPM) is a consequence of incomplete involution and atrophy of the pupillary membrane. Most PPMs require no treatment because they rarely cause visual impairment. Remnant structures vary from a few non-pigmented threads to a thick membrane covering the entire pupil. The aim of this case report is to show the advantages of Nd-YAG laser lysis of PPM prior to phacoemulsification cataract surgery. We describe a case of a patient with bilateral PPM and cataract of the right eye having significant visual loss in bright light that underwent Nd-YAG laser lysis and experienced visual acuity improvement from 0.1 to 0.9 after phacoemulsification surgery, without any complications. We conclude that in PPM patients scheduled for cataract surgery, laser lysis of PPM prior to cataract surgery is preferable to surgical excision of PPM that is associated with complications such as infection, hyphema, and risk of anesthesia. Laser lysis of pupillary membranes is a relatively simple procedure. There is less discomfort than with surgical excision, and the procedure results in a perfectly round pupil, thus facilitating cataract surgery while also preventing intraoperative hemorrhage during surgical excision that may complicate the scheduled phacoemulsification cataract surgery.

Key words: *Hyperplasia, iris; Surgery; Laser surgery methods; Membranes; Ophthalmologic surgical procedures*

Introduction

Persistent pupillary membrane (PPM) is a condition of the eye that results from an incomplete involution of the tunica vasculosa lentis. It represents a source of blood supply for the lens during fetal development. The membrane central portion atrophies by the seventh gestational month and its involution is completed between the eighth and ninth month¹. PPM occurs when this atrophy is incomplete. Some pupillary remnants can remain; however, most forms do not adversely affect visual acuity^{2,3}. Remnant structures vary from a few non-pigmented threads to a thick membrane covering the entire pupil, causing amblyopia⁴. The threads can connect to the cornea or lens, but most commonly to other parts of the iris. Attachment to the cornea can cause small

corneal opacities, while attachment to the lens can cause small cataracts⁵. PPMs covering most of the pupil are a rare clinical finding. Although familial forms have been reported, most cases are sporadic in nature². The incidence of persistent papillary membrane ranges from 30% to 95% in normal individuals⁶.

A histopathologic study of a surgically removed hyperplastic PPM revealed an increased number of fibrocytes and collagen in the stroma of the iris, which might prevent its atrophy during normal development⁷.

Using topical atropine to dilate the pupil may help break down PPMs. Surgical and laser intervention may be required for extensive opaque membranes⁸. Some authors report that according to their experience with these patients, a more conservative management with Nd-YAG laser rather than intraocular surgery is an acceptable and safe way of treating patients with similar clinical findings⁹.

We report on a case of a patient with binocular PPM and cataract having significant visual loss in bright light

Correspondence to: *Kajo Bučan, MD*, University Department of Ophthalmology, Split University Hospital Center, Spinčičeva 1, HR-21000 Split, Croatia

E-mail: kajo.bucan@st.t-com.hr

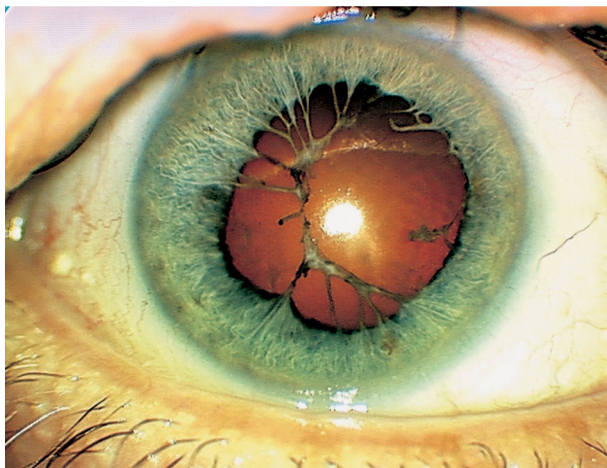


Fig. 1. Persistent pupillary membrane with a network of pigmented tissue and cataract in a 73-year-old woman.

on the right eye, who underwent Nd-YAG laser lysis of the PPM before lens phacoemulsification.

Case Report

A 73-year-old woman presented to our hospital with bilateral PPM and cataract of the right eye. There was no family history of ocular disease or anomaly. Best-corrected visual acuity was 0.1. The intraocular pressure was 16 mm Hg. Examination revealed the pupil to be covered with a network of pigmented tissue (Fig. 1). Predominantly nuclear and posterior subcapsular cataract was present in this eye. There were no iridolenticular synechiae and gonioscopy results were normal.

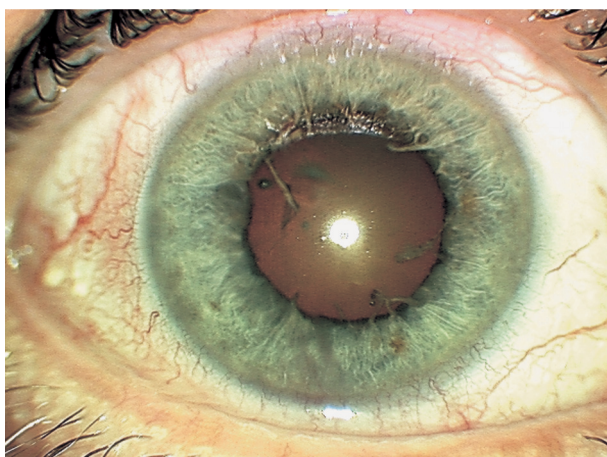


Fig. 2. The right eye after Nd-YAG laser lysis of persistent pupillary membrane with a perfectly round pupil.

Initial treatment with medical therapy (mydriatics) was ineffective in our patient, so we decided to manage the PPM with the Nd-YAG laser. The eye was dilated with 2% homatropine and 1% tropicamide. We used an Abraham contact lens with 0.5% tetracaine for topical anesthesia. Nd-YAG laser (Alcon 3000 LE) was used in single-pulse mode with energies ranging from 1.4 mJ to 2.2 mJ.

Laser energy was directed at the attachment of the membrane to the iris collarette. After surgery, 0.1% dexamethasone solution was administered to the eye four times daily, 1% cyclopentolate solution twice daily and oral acetazolamide (250 mg) twice daily (Fig. 2).

After Nd-YAG laser lysis of the membrane, the pupil was perfectly round and visual acuity improved to 0.9 on the day after phacoemulsification (Fig. 3). No intraocular pressure elevation or other complications were recorded.

Discussion

PPM is usually a common finding that requires intervention only when adversely affecting visual acuity. PPMs generally undergo significant atrophy during the first year of life. Primary indications for the treatment of PPM are restoration of vision, especially in bright light, and prevention of amblyopia in children^{7,10}.

Initial treatment in patients with vision impairment generally consists of medical therapy with mydriatic agents. In cases like our patient, in which medical ther-

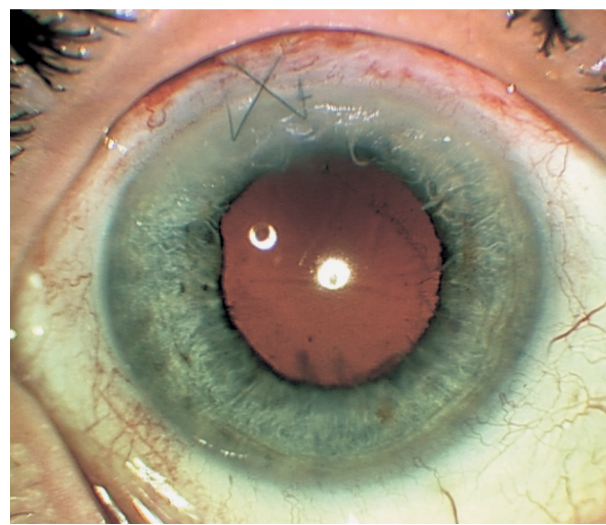


Fig. 3. The right eye after Nd-YAG laser lysis of persistent pupillary membrane and phacoemulsification procedure.

apy is ineffective, surgical removal is a valid alternative^{2,3,7}. However, surgical excision is associated with complications apart from anesthesia, such as cataract, infection and hyphema¹¹. Apart from other complications of surgical removal of PPM, hyphema was the most important reason for us to choose Nd-YAG laser lysis of PPM prior to phacoemulsification. Although complications like microhemorrhages and pigment dispersal after Nd-YAG laser lysis of PPM have been reported¹², by separating the treatment of PPM from the cataract treatment we managed to prevent the possible intraoperative bleeding from surgically resected PPM strands that could consequently complicate or postpone phacoemulsification surgery.

In this case, the eye had successful laser disruption of PPM, thus achieving perfectly round pupil that facilitated subsequent cataract surgery, which resulted in great visual acuity recovery.

In conclusion, laser lysis of PPM is a relatively simple procedure and can be performed on an outpatient basis. In our opinion, it should be done in all adult patients with clinically important PPM every time when cataract surgery is scheduled, in order to prevent intraoperative hemorrhage during surgical excision of PPM that can hamper the planned cataract extraction.

References

1. LEE SM, YU YS. Outcome of hyperplastic persistent pupillary membrane. *J Pediatr Ophthalmol Strabismus* 2004;41:163-71.
2. MERIN S, CRAWFORD JS, CARDARELLI J. Hyperplastic persistent pupillary membrane. *Am J Ophthalmol* 1971;72:717-9.
3. LEVY WJ. Congenital iris lesion. *Br J Ophthalmol* 1957;41:120-3.
4. MILLER SD, JUDISCH GF. Persistent pupillary membrane: successful medical management. *Arch Ophthalmol* 1979;97:1911-3.
5. ROBB RM. Fibrous congenital iris membranes with pupillary distortion. *Trans Am Ophthalmol Soc* 2001;99:45-50.
6. WAARDENBURG PJ. Gross remnants of the pupillary membrane, anterior polar cataract and microcornea in a mother and her children. *Ophthalmologica* 1949;118:828-42.
7. REYNOLDS JD, HILES DA, JOHNSON BL, BIGLAN AW. Hyperplastic persistent pupillary membrane – surgical management. *J Pediatr Ophthalmol Strabismus* 1983;20:149-52.
8. GUPTA R, KUMAR S, SONIKA, SOOD S. Laser and surgical management of hyperplastic persistent pupillary membrane. *Ophthalmic Surg Lasers Imaging* 2003;34:136-9.
9. KIM SK, QUINN GE, ZAIDMAN GW, ORLIN SE. Congenital hyperplastic persistent pupillary membranes: a conservative approach in management. *J AAPOS* 2005;9:391-3.
10. KUMAR H, SAKHUJA N, SACHDEV MS. Hyperplastic pupillary membrane and laser therapy. *Ophthalmic Surg* 1994;25:189-90.
11. CASSADY JR, LIGHT A. Familial persistent pupillary membranes. *AMA Arch Ophthalmol* 1957;58:438-48.
12. PANDEY SK, RAM J, JAIN A, SINGH U, GUPTA A, APPLE DJ. Surgical management of complete hyperplastic persistent pupillary membrane. *J Pediatr Ophthalmol Strabismus* 1999;36:221-3.

Sažetak

LASERSKO LIJEČENJE TVRDOKORNE PUPILARNE MEMBRANE PRIJE OPERACIJE KATARAKTE

K. Bučan, Lj. Znaor, K. Jurašin, D. Bučan, D. Galetović i M. Lešin

Perzistentna pupilarna membrana (PPM) nastaje kod nedovoljne involucije i atrofije pupilarne membrane. Većina PPM ne traži nikakvo liječenje, jer samo rijetko uzrokuje pad vida. Tvrdokorne strukture membrane variraju od nekoliko nepigmentiranih tračaka do debele membrane koja prekriva cijelu zjenicu. Cilj je pokazati prednosti laserskog liječenja PPM kod kojih se planira fakoemulzifikacijska operacija katarakte. Opisuje se slučaj bolesnice s obostranom PPM i kataraktom, kod koje je nastupio znatan pad vida kod vanjskog svjetla na desnom oku i koja je liječena Nd-YAG laserom. Nakon laserske terapije i fakoemulzifikacije katarakte vid se poboljšao s 0,1 na 0,9 bez ikakvih komplikacija. Kao zaključak, ako se planira fakoemulzifikacija, prednost dajemo laserskoj terapiji PPM pred kirurškom ekscizijom PPM koja je udružena s komplikacijama poput infekcije, hifeme, rizika kod anestezije. Lasersko liječenje je relativno jednostavno, ugodnije od kirurškog, nakon zahvata je zjenica savršeno okrugla, što olakšava operaciju katarakte, a uz to se izbjegavaju intraoperacijska krvarenja tijekom kirurškog zahvata koja bi komplicirala fakoemulzifikaciju katarakte.

Ključne riječi: Hiperplazija, šarenica; Kirurgija; Laserske kirurške metode; Membrane; Oftalmološki kirurški zahvati

