

SIGNA VITAE 2008; 3(1): 55 - 56

CASE REPORT

Difficult airway management in the emergency room using an airway scope

MASATOMO KITAMURA • HIROSHI DOHGOMORI • KAZUFUMI OKAMOTO

MASATOMO KITAMURA • HIROSHI DOHGOMORI (✉) • KAZUFUMI OKAMOTO
Department of Emergency Medicine and Critical Care
Shinshu University Hospital
3-1-1, Asahi, Matsumoto, 390-0802, Japan
Phone: +81-263-37-2222
Fax: +81-263-37-3028
E-mail: hd5621hd@yahoo.co.jp

ABSTRACT

In the emergency room, some cases need adequate airway management. We present a patient whom we intubated using a new device. This device might be an option in airway management but some considerations should also be taken into account.

Key words: airway management, scope, secretions, bleeding

Introduction

Adequate airway management is important in all medical fields, especially in the emergency room, where airway problems are frequently encountered. We encountered a man with severe dyspnea due to severe swelling of the neck associated with jaw lesions.

Case Report

A thirty-five year old man had undergone extraction of three teeth and was prescribed antibiotics. Three days later, he complained of pain and swelling of the lower jaw. In spite of additional antibiotics and incision of the lesions, his complaints worsened with time, and he was transferred to our emergency room. It was necessary for his airway to be secured. Under oxygen supple-

mentation and ECG and oxygen saturation monitoring, we examined his inner mouth using the Airway Scope (Pentax Ltd, Tokyo, Japan). This device provides good views that make it possible for the physician to observe the airway as well as video views in real time. The patient's tongue was swollen, especially on the right side. Although secretions were present, they were suctioned and the blade could be moved deeper into

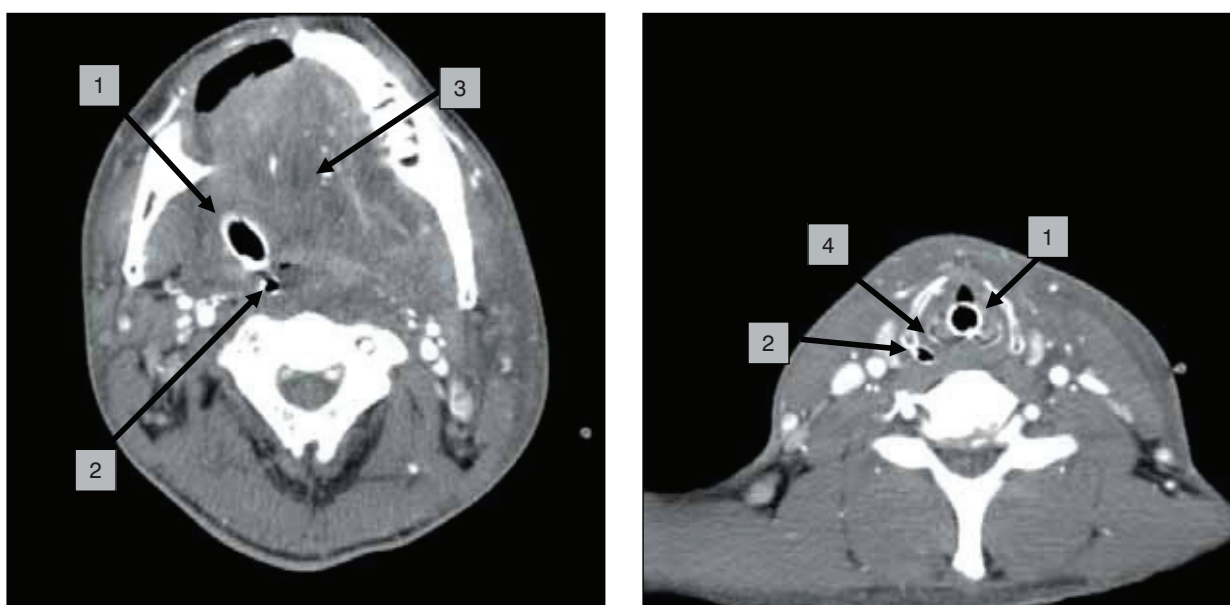


Figure 1.

A. Swollen soft tissues (arrow 3) around the submaxilla protruding into the oral cavity. Arrow 1 tracheal tube, arrow 2 nasogastric tube.

B. Relatively intact tissues around the vocal cords. Arrow 1 tracheal tube, arrow 4 arytenoid cartilage.

the mouth and the vocal cords could be observed easily under the Macoi Grade 1 condition. Tracheal intubation was then performed. Marked swelling of the neck was noted and CT showed swelling of the tissues in the submandibular region (figure 1). Therefore, an adequate view may not have been obtained for successful tracheal intubation with the conventional laryngoscope blade.

Discussion

The Airway Scope was developed and launched onto the market last year for

use in tracheal intubation. (1) It has been well evaluated in the field of anesthesia and in a study using a manikin. (2,3) It provides a good view of the glottis and is useful even when airway management conditions are difficult. (2,3) However, its usefulness in the emergency room had not been evaluated.

In our case, in the emergency room, we could observe the glottis with relative ease, in spite of the swollen tongue and surrounding tissues. Our experience suggests the usefulness of the scope even in the emergency room and in

cases with airway problems caused by obstruction. The ability to handle the device directly and move it straight ahead may be one of the merits of this scope as compared with the flexible fiberscope. The sheath is hard and the device can be moved straight with the operator's hand under observation more easily than with the flexible fiberscope. However, the presence of excessive secretions and blood, as in this case, may make intubation difficult. (4) Further studies addressing these issues are warranted.

REFERENCES

1. Koyama J, Aoyama T, Kusano T, Sekiguchi T, Kawagishi K, Iwashita T, et al, editors. Description and first clinical application of Airway Scope for tracheal intubation. *J Neurosurg Anesthesiol* 2006;18:247-50.
2. Asai T, Enomoto Y, Okuda Y. Airway Scope for difficult intubation. *Anaesthesia* 2007;62:199.
3. Hirabayashi Y. Ease of Use of the Airway Scope vs the Bullard Scope: a manikin study. *Can J Anesth* 2007;54:397-8.
4. Lutes M, Hopson LR. Tracheal intubation. In: Roberts JR, Hedges JR, editors. *Clinical procedures in Emergency Medicine*. 4th ed. Philadelphia: Saunders; 2004. p. 69-99.