

Sertan Ergun<sup>1</sup>, Mine G Güllüoğlu<sup>2</sup>, Melike O Subay<sup>1</sup>, Kemal R Subay<sup>3</sup>, Hakki Tanyeri<sup>1</sup>

# Kirurški postupak kod prekomjerno napunjenog korijenskog kanala: prikaz slučaja

## *Surgical Management of Overfilling of a Root Canal Filling Material: a Case Report*

<sup>1</sup> Sveučilište u Istanbulu Stomatološki fakultet, Zavod za oralnu medicinu i oralnu kirurgiju  
*Istanbul University, Faculty of Dentistry, Department of Oral Medicine and Surgery*

<sup>2</sup> Sveučilište u Istanbulu Stomatološki fakultet, Zavod za patologiju  
*Istanbul University, Faculty of Medicine, Department of Pathology*

<sup>3</sup> Sveučilište u Istanbulu, Stomatološki fakultet, zavod za endodonciju  
*Istanbul University, Faculty of Dentistry, Department of Endodontics*

### Sažetak

U radu je predstavljeno kirurško liječenje u slučaju kad su bol i oteklina bili uzrok izlaska materijala za punjenje korijenskog kanala u veliku periapikalnu leziju između lateralnog sjekutića i očnjaka lijeve maksile. Oteklina je bila bolna na dodir. Lezija i materijal kirurški su uklonjeni. Da je sve potpuno zacijelilo, zaključeno je radiološki na postoperativnom pregledu godinu dana nakon zahvata. Kirurška intervencija velikih periapikalnih lezija indicirana je ako se nehotice dogodi da izađu velike količine materijala za punjenje korijenskih kanala, kako bi se omogućilo cijeljenje periradikularnog tkiva.

Zaprimljen: 30. siječnja 2007.

Prihvaćen: 10. lipnja 2007.

### Adresa za dopisivanje

Dr. Sertan Ergun  
Istanbul University Faculty of Dentistry  
Department of Oral Medicine and Surgery  
Capa, 34393 Istanbul, Turkey  
[sertanergun@gmail.com](mailto:sertanergun@gmail.com)

### Ključne riječi

materijali za punjenje korijenskih kanala, periapikalna gnojna upala

### Uvod

Hermetično punjenje korijenskih kanala do dentinsko-caklinskog spojišta vrlo je važno za njihovo uspješno liječenje. Glavni razlog što materijal za punjenje korijenskih kanala izlazi u periapikalne lezije su instrumentacija kroz apikalni foramen, neočekivana komunikacija zbog resorptivnih defekata u kanalnom sustavu, defekti uključeni u kanalni sustav tijekom preparacije kanala, pretjerana sila kondenzacije, korištenje prevelike količine materijala za brtvljenje s lentulo spiralom tijekom punjenja te nevitalni i nezreli zubi s periapikalnim lezijama. (1) Za većinu komplikacija krivi su stomatolozi. Na sreću, većina takvih slučajeva ne pokazuju klinič-

### Introduction

Hermetic filling of the root canals to the level of dentin-cementum junction is the key for a successful root canal therapy. The major causes of the extrusion of the root canal filling material into the periapical lesions are instrumentation through the apical foramen, unanticipated communicating resorptive defects anywhere in the canal system, defects incorporated into the canal system during cleaning and shaping, excessive condensation force, use of excessive amounts of sealer with lentulo spiral during the filling and non-vital immature teeth with periapical lesions (1). Most of these complications result from errors of the dental clinician. Fortunately,

ke simptome nakon liječenja te zadovoljavajuće zacjeljuju. No, nakon takvog endodontskog neuspjeha mogu se dogoditi i izrazite upalne komplikacije. (2-5)

Prepunjenost može završiti reakcijom na strano tijelo i nepotpunim cijeljenjem oko periapikalnog područja, s bolom i oteklinom kao kliničkim simptomima. Zatim, prepun korijenski kanal s materijalom za brtvljenje, polutvrdih ili tvrdih punila kao što su gutaperka ili srebreni štapići, može biti etiološki čimbenik za aspergilozu maksilarnog sinusa kod zdravih pacijenata. Osim toga, anestezija, parestezija, hipoestezija, hiperestezija i distezija mogu nastati zbog toga što materijal za brtvljenje izlazi u mandibularni kanal (8, 9). Ako tijekom liječenja korijenskog kanala prevelika količina materijala za punjenje izlazi u periapikalnoj leziji, potrebno ga je kirurški ukloniti da bi se omogućilo cijeljenje periapikalnog tkiva.

Ovaj rad predstavlja kirurško vođenje slučaja s prevelikim izlaskom materijala za punjenje korijenskih kanala u veliku periapikalnu leziju, što je uzrokovalo izrazitu periapikalnu upalu s bolom i oteklinom.

## Prikaz slučaja

Dvadesetogodišnja pacijentica stigla je iz privatne stomatološke ordinacije u Zavod za oralnu kirurgiju i medicinu Sveučilišta u Istanbulu. Najprije je posjetila svojega stomatologa zbog boli i otekline u prednjem području lijeve maksile. Istaknula je da je njezin liječnik najprije počeo liječiti korijenski kanal, ali se tijekom njegova punjenja pojavila izrazita bol. Stomatolog je objasnio da je njezin uzrok nenačajno izazvan izlazak materijala za punjenje korijenskog kanala preko apeksa korijena.

Klinički se oteklina nalazila u prednjem području lijeve maksile između vestibularnog sulkusa i podonosne šupljine, pola centimetra od granice pričvrstne gingive (Slika 1.). Na dodir je bila bolna. Ortopantomogram i radiološka snimka područja periapeksa pokazali su da je u periapikalnu leziju između apeksa lateralnog sjekutića i očnjaka lijeve maksile izašao materijal za punjenje korijenskog kanala. (Slika 2. i 3.). Razgovarali smo sa stomatologom i doznali da je materijal za brtvljenje bio Forfenan (Septodont), a u kanal je bio postavljen lentulo spiralom.

Plan liječenja bio je da se kirurški uklone lezija i materijal za endodontsko punjenje te da se obavi apikoetomija u lokalnoj anesteziji. Tijekom zahvata bio je odignut veliki bukalni mukoperiostalni režanj te je uklonjena tanka kortikalna kost iznad lezije ka-

ly, most of the overfilled cases do not show clinical symptoms after the treatment and may heal satisfactorily. But severe inflammatory complications may occur following this endodontic mishap (2-5).

Overfilling may result in a persistent foreign body reaction and incomplete healing around the periapical area with clinical symptoms of pain and swelling. Furthermore, overfilling of the root canal by using of a sealer or solid materials such as gutta-percha or silver cones into the sinus might be an etiological factor for aspergillosis of the maxillary sinus in healthy patients (6, 7). Additionally, anesthesia, paresthesia, hypoesthesia, hyperesthesia and dysesthesia may occur as a result of extrusion of a canal sealer into the mandibular canal (8, 9). If excessive root filling material is extruded into the periapical lesion during root canal therapy, it should be removed surgically to provide the healing of the periapical tissues.

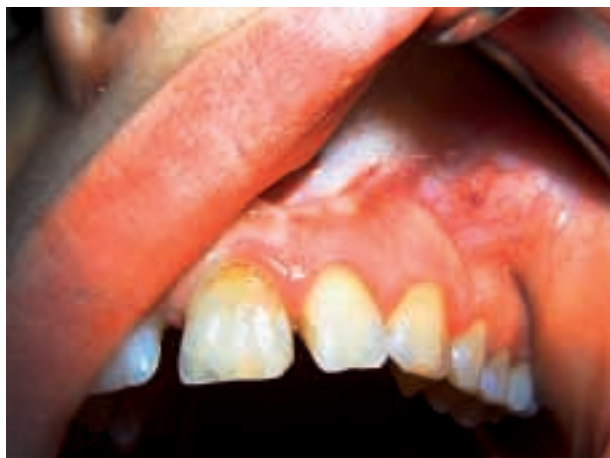The present report demonstrates the surgical management of a case of excessive extrusion of root canal filling into a large periapical lesion which caused severe periapical inflammation with pain and swelling.

## Case report

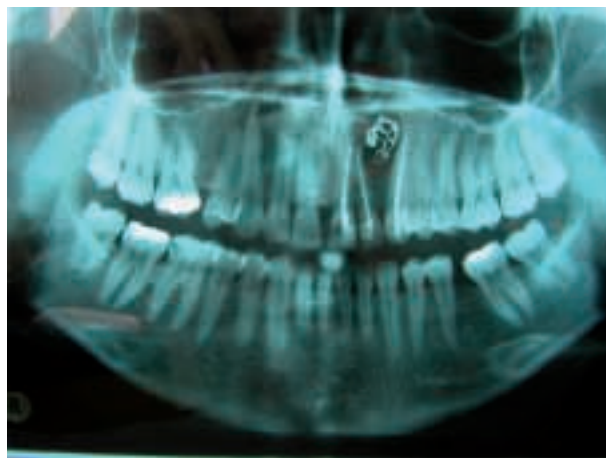A 20-year-old female patient was referred from a private dental office to the Department of Oral Surgery and Medicine, Istanbul University. She had first visited her dentist because of pain and swelling in the left maxillary anterior region. She stated that the dentist had started the root canal treatment but severe pain had occurred during the root canal filling procedure. The dentist had explained that the cause of severe pain was due to the extrusion of root canal filling beyond the root tip unintentional.

Clinically, there was a swelling located in the left anterior maxillary area between vestibular sulcus and nasal floor, 0.5 cm beyond the border of attached gingiva (Fig.1). The swelling was painful on palpation. The orthopantomograph and periapical radiography showed the presence of overfilling of a root canal filling material in the periapical lesion between the apices of the left maxillary lateral and canine (Figs. 2, 3). We contacted with the patient's dentist and learned that the root canal sealer was Forfénan (Septodont®) and the sealer was placed into the canal using a lentulo spiral.

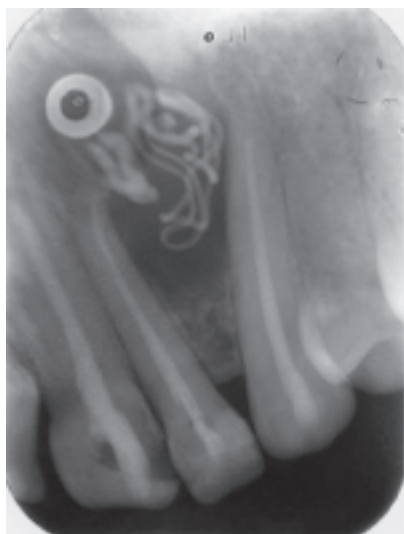The treatment plan was to remove the lesion and endodontic filling material surgically and to perform apicoectomy under local anesthesia. A large buccal mucoperiostal flap was raised and thin cor-



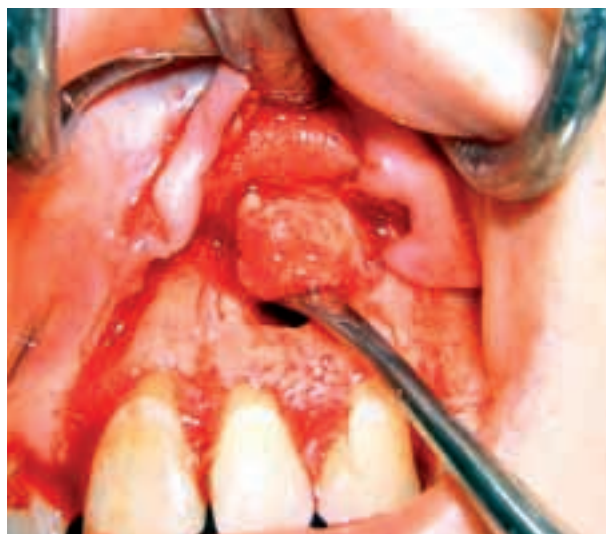Slika 1. Oteklina u prednjem području lijeve maksile  
Figure 1 Swelling located in the left anterior maxillary area



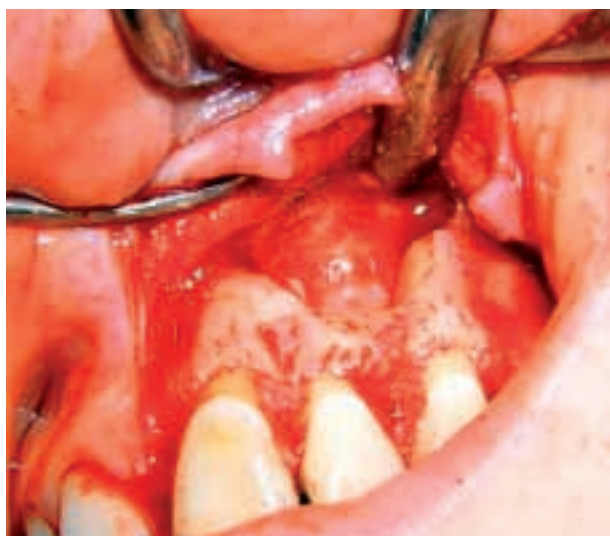Slika 2. Radiološki prikaz lezije  
Figure 2 Radiographical view of the lesion



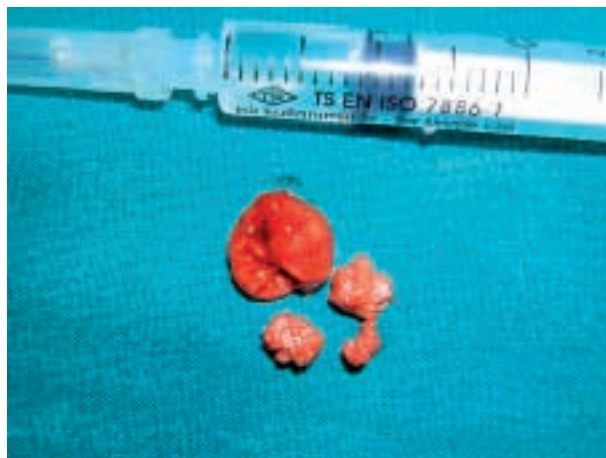Slika 3. Radiološki prikaz lezije  
Figure 3 Radiographical view of the lesion



Slika 4. Intraoperativna slika  
Figure 4 Intraoperative view

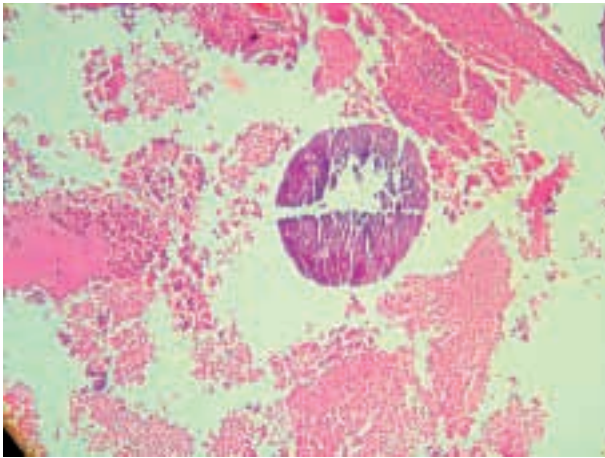


Slika 5. Intraoperativna slika  
Figure 5 Intraoperative view



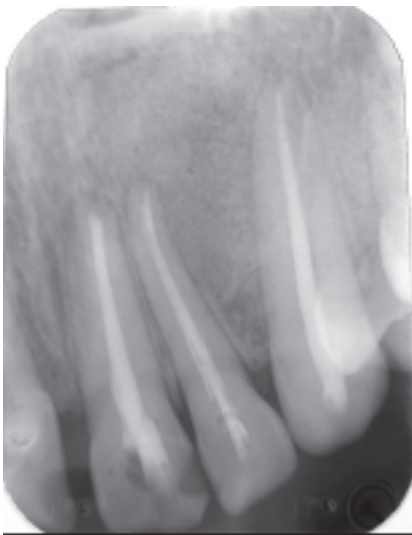
Slika 6. Resecirano tkivo  
Figure 6 Resected tissues





**Slika 7.** Strano tijelo zajedno s fibrinom, upalnim stanicama i stanični debris (HE, 100X originalna magnifikacija)

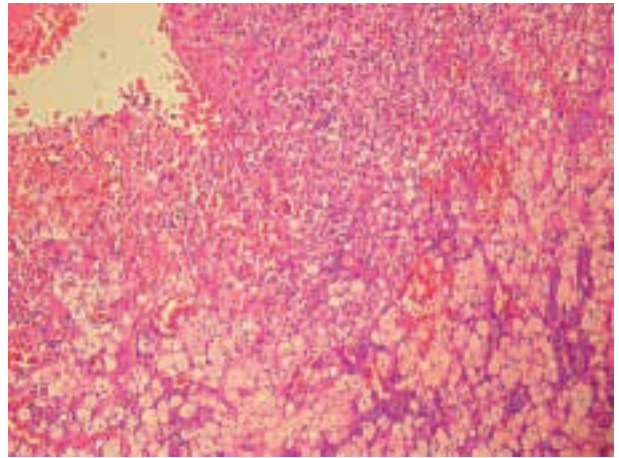
**Figure 7** The foreign material together with fibrin, inflammatory cells and cellular debris (HE, 100X original magnification)



**Slika 9.** Cijeljenje kod postoperativnog pregleda nakon dva mjeseca

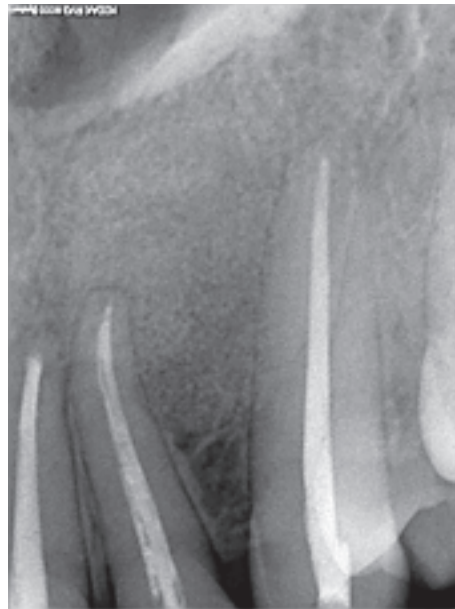
**Figure 9** Healing at the post-operative second month

ko bi se omogućio pristup oteklini. Zatim su lezija i materijal uklonjeni i poručje je kiretirano. (Slika 4. i 5). Obavljene su apikotomije lateralog sjeckutića i očnjaka, koštana šupljina je napunjena resorbirajućim materijalom (Unilab Surgibone®) te je režanj zatvoren. Pacijentu su ordinirani antibiotici (klindamicin, 1200mg/dan) i analgetici (naproksen natrij, 1100 mg/dan). Većina reseciranog tkiva bila je dimenzija 0,5x0,7x0,3 cm (Slika 6.). Histopatološki se lezija sastojala od šupljine sa stranim tijelom, fibrinom, staničnim nekrotizirajućim debrisom te upalnim stanicama. Šupljina je bila okružena po-



**Slika 8.** Ksantogranulomatозна upala infiltrira šupljinu (HE, 200X originalna magnifikacija)

**Figure 8** Xanthogranulomatous inflammatory infiltrating the cavity (HE, 200X original magnification)



**Slika 10.** Cijeljenje kod postoperativnog pregleda nakon godinu dana

**Figure 10** Healing at the post-operative first year

tical bone over the lesion was removed to allow access to the lesion. The lesion and the material were removed and curetted (Figs. 4, 5). Apicoectomies of lateral incisor and canine teeth were performed, the bone cavity was packed with a resorbable graft material (Unilab Surgibone®) and the flap was closed. The patient was prescribed antibiotics (clindamycin, 1200 mg/day) and analgesics (naproxen sodium, 1100 mg/day).

The size of the resected tissues was 0.5x0.7x0.3 cm in dimension (Fig 6). Histopathologically, the lesion was composed of a cavity containing foreign

dručjem zahvaćenim ksantogranulomatoznom upalom i prikazivala je skupine pjenastih histocita (Slika 7. i 8.)

Dva tjedna nakon zahvata klinički je bila prisutna blaga bol i osjetljivost oko operiranog područja. Dva mjeseca kasnije tijekom postoperativnog pregleda na zubima nije bilo nikakvih kliničkih simptoma niti je bilo radiološkog dokaza o koštanom cijeljenju oko apeksa korijena. (Slika 9.). Na postoperativnom pregledu godinu dana kasnije radiološki je uočeno potpuno koštano zacjeljenje (Slika 10.).

## Rasprava

Etiološki čimbenici perzistirajućih periapikalnih lezija indiciranih za periradikularnu kirurgiju su: periradikularne prave ciste, intrakanalne infekcije rezistentne na liječenje, ekstrakanalne infekcije, prepunjenost materijalom za punjenje korijenskog kanala, kristali kolesterola te ostali materijali koji klinički uzrokuju takve reakcije na strano tijelo (10-14).

Istraživanja su pokazala da su tri čimbenika kriva za neuspješno liječenje nakon što se prepuni korijenski kanal (15-17). Prvi je citotoksičnost materijala za punjenje koji iritira periradikularno tkivo te je povezan s reakcijom stranog tijela. Drugi je čimbenik perzistirajuća intrakanalna infekcija ili ponovna infekcija korijenskih kanala zbog koronarnog propuštanja, a treći stvaranje biofilma na prepunjenim korijenskim kanalima koji pružaju sigurnu okolinu za skupljanje i rast bakterija. U slučajevima s prepunjenim korijenskim kanalima intraradikularni i ekstraradikularni rast bakterija ima veći učinak na perzistenciju lezija nego sama toksičnost materijala za brtvljenje.

Sa stajališta statistike mala količina prepunjenog materijala (0-2 mm), u slučajevima periradikularne lezije nema utjecaj na ishod liječenja (19). No, Yusuf (15) je otkrio da u slučajevima neuspjelog liječenja korijenskog kanala ili periapikalnoga kirurškog zahvata, 96 od 284 (33 %) periapikalna granuloma sadržava strana tijela kao što su dentin i strugotine cementa, zatim amalgam te materijale za punjenje korijenskih kanala. To se sve može vidjeti na histološkoj slici. Ako se dogodilo da je izašla prevelika količina materijala za brtvljenje, citotoksičnost materijala može biti glavni razlog za perzistirajuće periradikularne lezije s akutnim simptomima. Konkretno, za materijale za brtvljenje koji sadržavaju formaldehid istaknuto je da djeluju citotoksično na stanične linije između materijala za brtvljenje korijenskih kanala koji se koriste u endodontskoj terapiji (20). Osim toga, i stručnjaci za životinje dokazali su da materija-

material, fibrin and necrotic cellular debris as well as inflammatory cells. The cavity was lined by a zone consisting of xanthogranulomatous inflammation displaying groups of foamy histiocytes (Figs.7, 8).

Clinically, there was mild pain and sensitivity around the operated area two weeks after surgery. At the post-operative second month recall, the teeth showed no clinical symptoms, and there was radiographic evidence of bony healing around the root ends (Fig.9). Complete healing was observed at the postoperative first year radiographically (Fig. 10).

## Discussion

Etiological factors of persistent periapical lesions which do indicate the periradicular surgery are periradicular true cysts, therapy resistant intracanal infection, extraradicular infection, overfilled root canal filling materials, cholesterol crystals and other materials which cause persistent foreign body reaction clinically (10-14).

Studies showed that three factors may play role in the treatment failures reported after the overfilling (15-17). First is the filling material cytotoxicity causing irritation in the periradicular tissues associated with foreign body reaction. Second is the persistent intracanal infection or reinfection in the root canals due to the coronal leakage. Thirdly, the formation of biofilms on the overfillings which was shown to provide a protected environment for bacterial accumulation and growth. In overfilling cases, the intraradicular and extraradicular bacterial growth seem to be more effective in the persistency of lesions than the toxicity of the sealers (18).

Small amount of overfilling (0-2mm) in cases with a periradicular lesion was reported to have no influence on the treatment outcome statistically (19). On the other hand, Yusuf (15) found that 96 out of 284 (33%) periapical granulomas in cases of failed root canal treatment or periapical surgery contained foreign materials such as dentin and cementum chips, amalgam and root canal fillings in histological sections. In cases with excessive amount of root canal sealer extrusion, the material cytotoxicity may be the major cause of persistent periradicular lesions showing acute symptoms. Specifically, formaldehyde containing root canal sealers were reported to be cytotoxic to the cell lines among the root canal sealers used in the endodontic therapy (20). Moreover, animal experiments showed that the formaldehyde containing sealers produced coagulation necrosis in the bone and soft tissues.

li za brtvljenje s formaldehidom uzrokuju koagulacijsku nekrozu kosti i mekih tkiva.

U opisanom slučaju dogodila se velika prepunjenost materijala za brtvljenje s formaldehidom (Forfénan, Septodont®) u veliku periapikalnu leziju. Histopatološki pregled otekline otkrio je ksantogranulomatozno upalno tkivo s nekrotičnim stanicama tkiva, strani materijal te upalne stanice. Na upaljenom mjestu bile su mnogobrojne stanice bogate lipidima to jest pjenaste stanice, a to su zapravo histociti. Ti nalazi mogu indicirati da je periapikalna upala najvjerojatnije reakcija na strano tijelo koje je iritiralo oboljelo tkivo zbog previše materijala za brtvljenje korijenskih kanala. Nehotično korištenje lentulo spirala tijekom punjenja korijenskih kanala može prouzročiti prepunjenost materijala za brtvljenje korijenskih kanala u periradikalnim lezijama, kao što se dogodilo u opisanom. Ovaj prikaz pokazuje da punjenje korijenskih kanala s lentulo spiralom i korištenje materijala za brtvljenje s formaldehidom treba izbjegavati tijekom liječenja kanala zuba s velikim periapikalnim lezijama. U takvim slučajevima mora se obaviti periapikalni kirurški zahvat kako bi tkivo moglo zacijeliti.

In the present case, there was gross overfilling of a formaldehyde containing root canal sealer (Forfénan, Septodont®) into a large periapical lesion. Histopathological examination of the lesion revealed that it was a xanthogranulomatous inflammatory tissue with necrotic tissue cells, foreign material and inflammatory cells. Lipid-containing foamy cells which are histiocytes were numerous in the inflammatory site. These findings may indicate that the periapical inflammation in this case is possibly a foreign body reaction due to the irritation of the overfilling of the root canal sealer in the diseased tissue. The inadvertent use of lentulo spiral during the root canal obturation can cause gross overfilling of sealers into the periradicular lesions as it occurred in this case. This case report shows that the root canal obturation with the lentulo spiral and the use of paraformaldehyde containing sealers must be avoided during root treatment of teeth with large periapical lesions. The periapical surgery must be performed in these cases for the healing of periradicular tissues.

#### Abstract

The surgical treatment of a case presenting pain and swelling due to the extrusion of the root canal filling into a large periapical lesion between left maxillary lateral and canine teeth is presented in this report. The swelling was painful on palpation. Removal of the lesion and the material was made surgically. Complete healing was observed at the postoperative first year radiographically. Surgical intervention of large periapical lesions is indicated in cases in which the extrusion of large amount of root canal filling material occurred inadvertently to provide healing of the periradicular tissues.

Received: January 30, 2007

Accepted: June 10, 2007

#### Address for correspondence

Dr. Sertan Ergun  
Istanbul University Faculty of Dentistry  
Department of Oral Medicine and  
Surgery  
Capa, 34393 Istanbul, Turkey  
sertanergun@gmail.com

#### Key words

Root Canal Filling Materials; Periapical  
Abscess

#### References

1. Forman GH, Rood JP. Successful retrieval of endodontic material from the inferior alveolar nerve. *J Dent.* 1977;5(1):47-50.
2. Alantar A, Tarragano H, Lefevre B. Extrusion of endodontic filling material into the insertions of the mylohyoid muscle. A case report. *Oral Surg Oral Med Oral Pathol.* 1994;78(5):646-9.
3. Yaltirik M, Ozbas H, Erisen R. Surgical management of overfilling of the root canal: a case report. *Quintessence Int.* 2002;33(9):670-2.
4. Koppang HS, Koppang R, Solheim T, Aarnes H, Stølen SO. Cellulose fibers from endodontic paper points as an etiological factor in postendodontic periapical granulomas and cysts. *J Endod.* 1989;15(8):369-72.
5. Yaltirik M, Koçak Berberoglu H, Koray M, Dulger O, Yildirim S, Aydil BA. Orbital pain and headache secondary to overfilling of a root canal. *J Endod.* 2003;29(11):771-2.
6. Khongkhunthian P, Reichart PA. Aspergilloidosis of the maxillary sinus as a complication of overfilling root canal material into the sinus: report of two cases. *J Endod.* 2001;27(7):476-8.
7. Legent F, Billet J, Beauvillain C, Bonnet J, Miegerville M. The role of dental canal fillings in the development of Aspergillus sinusitis. A report of 85 cases. *Arch Otorhinolaryngol.* 1989;246(5):318-20.
8. Koseoglu BG, Tanrikulu S, Subay RK, Sencer S. Anesthesia following overfilling of a root canal sealer into the mandibular canal: a case report. *Oral Surg Oral Med Oral Pathol Oral Radiol Endod.* 2006;101(6):803-6.

9. Gatot A, Tovi F. Prednisone treatment for injury and compression of inferior alveolar nerve: report of a case of anesthesia following endodontic overfilling. *Oral Surg Oral Med Oral Pathol.* 1986;62(6):704-6.
10. Sundqvist G, Figdor D, Persson S, Sjogren U. Microbiologic analysis of teeth with failed endodontic treatment and the outcome of conservative re-treatment. *Oral Surg Oral Med Oral Pathol Oral Radiol Endod.* 1998;85(1):86-93.
11. Nair PN, Sjogren U, Krey G, Sundqvist G. Therapy-resistant foreign body giant cell granuloma at the periapex of a root-filled human tooth. *J Endod.* 1990;16(12):589-95.
12. Nair PN, Sjogren U, Krey G, Kahnberg KE, Sundqvist G. Intraradicular bacteria and fungi in root-filled, asymptomatic human teeth with therapy-resistant periapical lesions: a long-term light and electron microscopic follow-up study. *J Endod.* 1990;16(12):580-8.
13. Nair PN. New perspectives on radicular cysts: do they heal? *Int Endod J.* 1998;31(3):155-60.
14. Peciuliene V, Reynaud AH, Balciuniene I, Haapasalo M. Isolation of yeasts and enteric bacteria in root-filled teeth with chronic apical periodontitis. *Int Endod J.* 2001;34(6):429-34.
15. Yusuf H. The significance of presence of foreign material periapically as a cause of failure of root canal treatment. *Oral Surg Oral Med Oral Pathol.* 1982;54(5):566-74.
16. Bergenholtz G, Lekholm U, Milthon R, Engstrom B. Influence of apical overinstrumentation and overfilling on re-treated root canals. *J Endod.* 1979;5(10):310-4.
17. Noiri Y, Ehara A, Kawahara T, Takemura N, Ebisu S. Participation of bacterial biofilms in refractory and chronic periapical periodontitis. *J Endod.* 2002;28(10):679-83.
18. Lin LM, Rosenberg PA, Lin J. Do procedural errors cause endodontic treatment failure? *J Am Dent Assoc.* 2005;136(2):187-93.
19. Sjogren U, Hagglund B, Sundqvist G, Wing K. Factors affecting the long-term results of endodontic treatment. *J Endod.* 1990;16(10):498-504.
20. Meryon SD, Brook AM. In vitro comparison of the cytotoxicity of twelve endodontic materials using a new technique. *Int Endod J.* 1990;23(4):203-10.
21. Guttuso J. A histopathological study of rat connective tissue responses to endodontic materials. *Oral Surg Oral Med Oral Pathol.* 1962;16:713-9.