

Lipa Bodner<sup>1</sup>, Netta Sion-Vardy<sup>2</sup>, Esther Manor<sup>3</sup>

# Metastatske lezije u mandibuli: primjena citogenetike

## *Metastatic Lesion to the Mandible: The Use of Cytogenetics*

<sup>1</sup> Zavod za oralnu i maksilofacijalnu kirurgiju, Medicinski fakultet Soroka i Sveučilište Ben Guriona Negev, Beer-Sheva, Izrael  
*Department of Oral and Maxillofacial Surgery, Soroka University Medical Center and Ben Gurion University of the Negev, Beer-Sheva, Israel*

<sup>2</sup> Zavod za patologiju, Medicinski fakultet Soroka i Sveučilište Ben Guriona Negev, Beer-Sheva, Izrael  
*Department of Pathology, Soroka University Medical Center and Ben Gurion University of the Negev, Beer-Sheva, Israel*

<sup>3</sup> Citogenetski laboratorij Instituta za genetiku, Medicinski fakultet Soroka i Sveučilište Ben Guriona Negev, Beer-Sheva, Izrael  
*Cytogenetic Laboratories, Genetic Institute, Soroka University Medical Center and Ben Gurion University of the Negev, Beer-Sheva, Israel*

### Sažetak

Postaviti dijagnozu metastatske lezije mandibule velik je izazov, a temelj se nalazi poglavito u histopatologiji. Rijetkima se smatraju udaljene metastaze adenokarcinoma bazalnih stanica (AKBS) u mandibuli iz tumora žlijezda slinovnica. Prijavljen je slučaj mandibularne metastaze AKBS-a iz parotidne žlijezde. Opisana je primjena citogenetike u postavljanju dijagnoze. Citogenetska se analiza može koristiti i kao dodatni postupak u dijagnosticiranju metastaza i preporučuje se kod suspektne metastatske lezije čeljusti.

Zaprimljen: 18. lipanj 2007.

Prihvaćen: 11. listopada 2007

### Adresa za dopisivanje

Prof. Lipa Bodner,  
Soroka University Medical Center,  
Department of OMF Surgery,  
P.O. Box 151,  
Beer-Sheva 84101, Israel.  
Fax: 972-8-6403651  
[lbodner@bgu.ac.il](mailto:lbodner@bgu.ac.il)

### Ključne riječi

adenokarcinom; mandibula; karcinom,  
metastaze

### Uvod

Metastatski tumori u oralnoj regiji su rijetki i čine samo 1 do 3 posto svih malignih oralnih neoplazmi. Rana dijagnoza tih tumora klinički je vrlo važna, jer njihov izgled može biti prva indikacija neotkrivene malignosti na udaljenoj primarnoj lokaciji, ili pak prvi dokaz o diseminaciji poznatoga tumora s primarne lokacije. Uobičajeni primarni izvori metastatskih tumora u oralnoj regiji su dojke, pluća i bubrezi. Pluća su najčešći izvor metastaza u oralnim mekim tkivima, a dojke metastatskih tumora čeljusti. U čeljustima je mandibula najčešća loka-

### Introduction

Metastatic tumors to the oral region are uncommon, comprising only 1%-3% of all malignant oral neoplasms. The early diagnosis of these tumors, however, is of great clinical significance, as their appearance may be the first indication of an undiscovered malignancy at a distant primary site, or the first evidence of dissemination of a known tumor from its primary site. The common primary sources of metastatic tumors to the oral region are the breast, lung and kidney. The lung is the most common source of metastases to the oral soft tissues,

cija gdje se javljaju metastaze. One salivarnog podrijetla smatraju se rijetkima (1,2).

Adenokarcinom bazalnih stanica (AKBS) velikih žlijezda slinovnica rijedak je oblik tumora. Smatra se da pripada razredu niske stope malignosti. Lokalni recidiv razmjerno je čest, ali je metastaza manje uobičajena te se obično nalazi u regionalnim limfnim čvorovima (3). Mandibularna metastaza AKBS-a iz salivarne žlijezde smatra se rijetkom. Dijagnosticiranje metastatske lezije složen je i izazovan postupak. Kliničar treba razmotriti mogućnost da ona nije primarna lezija čeljusti, nego metastaza, a patolog histopatološkim tehnikama određuje mjesto izvora tumora.

Svrha je članka predstaviti primjenu citogenetike kao dodatnog postupka u uspostavljanju dijagnoze parotidne metastaze u mandibulu.

### Prikaz slučaja

Žena u dobi od 80 godina javila se zbog boli na desnoj strani mandibule za koju je tvrdila kako traje nekoliko mjeseci. Iz povijesti bolesti bilo je jasno da je godinu dana prije bila podvrgnuta totalnoj parotidektomiji zbog AKBS-a na desnoj podušnoj žlijezdi.

Kliničkim pregledom ustanovljena je submukozna lezija uključena u desnu mandibulu (Sl.1). Nije bilo cervikalne limfadenopatije, a primarna lokacija i vrat bili su pod kontrolom te su laboratorijski nalazi bili uredni. Obavljena je aksijalna CT-snimka mandibula te je otkrivena unilokularna, radiopropusna lezija uključena u desnu stranu mandibule (Sl.2). Uzeta je i incizijska biopsija te postavljena nesigurna dijagnoza parotidne metastaze u mandibulu.

Uzorci incizijske biopsije iz mandibularne lezije testirani su rutinskim metodama u patologiji i citogenetskom analizom. Preparati iz parafinskih blokova tkiva ispitani su hematoksilin-eozinskim bojenjem, imunohistokemijski na CK 8/18, CK/903, vimentin i aktin. U oba preparata pronađena je karakteristična histološka arhitektura AKBS-a. Imunohistokemijskim metodama demonstrirana je snažna pozitivna reakcija na CK 8/18, CK/903, vimentin i aktin u oba preparata (Tabl.1., Sl.3.). Dakle, lezija je u mandibuli dijagnosticirana kao moguća metastaza primarne parotidne lezije.

Klasičnim citogenetskim tehnikama ispitan je svjež uzorak i to fluorescencijom *in situ* hibridizacijom (FISH-om) pomoću centromeričnih sonda za kromosome 4,8,10,18 i 22. Obavljena je i FISH-

whereas the breast is the most common source for metastatic tumors to the jawbones. In the jawbones the mandible is the most common location for metastasis. Mandibular metastasis from salivary origin is considered rare (1,2).

Basal cell adenocarcinoma (BCAC) of the major salivary glands is a rare tumor. It is considered a low grade malignancy. Local recurrence is relatively frequent but metastasis is less common, usually to the regional lymph nodes (3). Mandibular metastasis from salivary gland BCAC is considered very rare. The diagnosis of a metastatic lesion is difficult and challenging. The clinician has to raise the possibility that a lesion is not a primary jaw lesion but rather a metastasis, and the pathologist, by using histopathologic techniques, should be able to tell the site of tumor origin.

The purpose of this article is to present the use of cytogenetics as an additional tool in the diagnostic work-up of parotid metastasis to the mandible.

### Case Report

An 80-year-old female presented with a tenderness in the right mandible of several months duration. The medical history revealed that one year earlier she underwent a total parotidectomy due to BCAC of the right parotid gland.

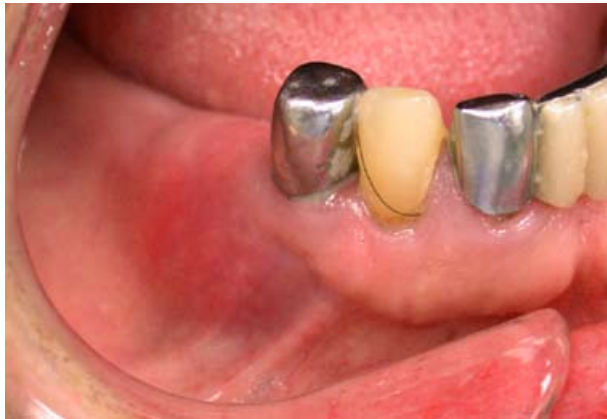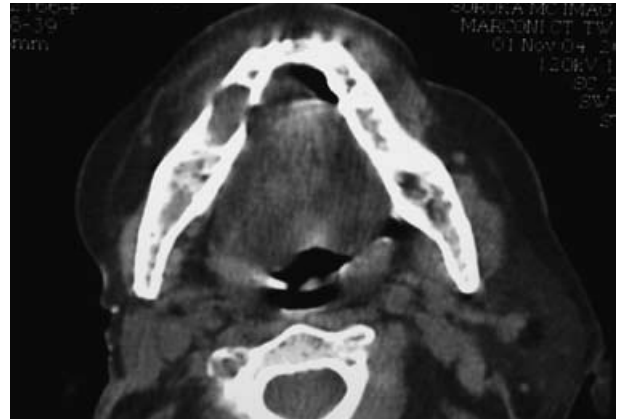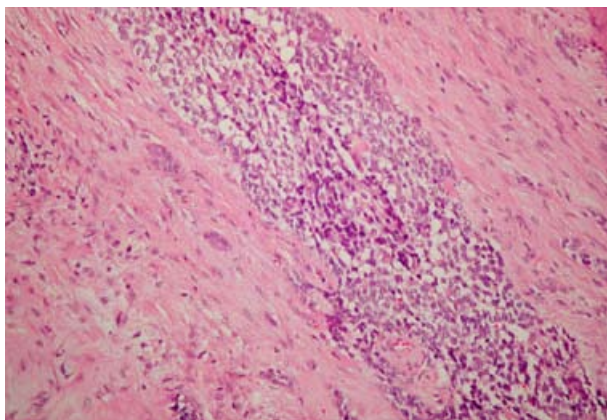
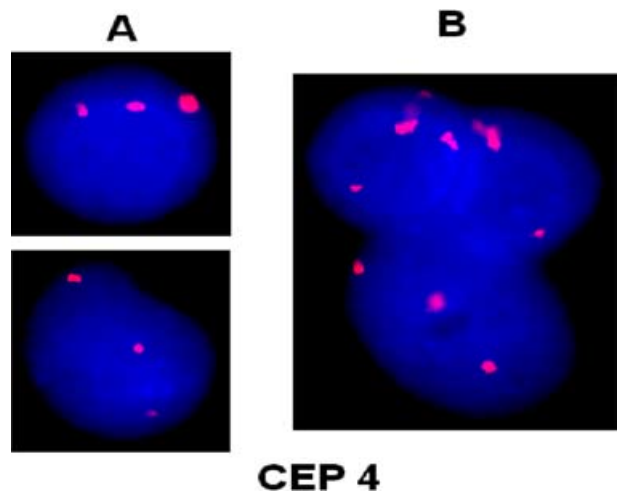
Physical examination revealed a submucosal lesion involving the right mandible (Fig 1). There was no cervical lymphadenopathy, the primary site and neck remained controlled and the laboratory data were unremarkable. Axial CT scan of the mandible revealed a unilocular, radiolucent lesion affecting the right body of the mandible (Fig 2). Incisional biopsy was taken and a tentative diagnosis of parotid metastasis to the mandible was made.

The incisional biopsy specimens from the jaw lesion were tested by routine pathologic methods and by cytogenetic analysis. Paraffin embedded tissue specimens from the archival primary BCAC and from the metastatic jaw lesion were tested by hematoxylin-eosin, immunohistochemistry for CK 8/18, CK / 903, vimentin and actin. The characteristic histologic architecture of BCAC was found in both tissue specimens. Immunohistochemistry demonstrated that the cells were strongly positive for CK 8/18, CK/903, vimentin and actin in both tissue samples (Table 1, Fig 3). Therefore, the mandibular lesion was diagnosed as a possible metastasis of the primary parotid lesion.

A fresh sample of the mandibular lesion was examined by classic cytogenetic techniques and by

**Tablica 1.** Histopatološka, imunohistokemijska i citogenetska/FISH-analiza primarnog tumora parotide i mandibularne metastatske lezije.**Table 1** Histopathology, Immunohistochemistry and Cytogenetic/FISH analysis of the primary parotid tumor and the mandibular metastatic lesion.

Analiza • Analysis	Parotidni tumor • Parotid tumor	Mandibularni tumor • Mandibular tumor
Histopatologija • Histopathology	Karakteristična histološka arhitektura AKBS-a • Characteristic histologic architecture of BCAC	Karakteristična histološka arhitektura AKBS-a • Characteristic histologic architecture of BCAC
Imunohistokemija • Immunohistochemistry	Pozitivna na CK8/18, CK/903, vimentin i aktin • Positive for CK8/18, CK/903, vimentin and actin	Pozitivna na CK8/18, CK/903, vimentin i aktin • Positive for CK8/18, CK/903, vimentin and actin
Citogenetska analiza • Cytogenetic analysis	Nije učinjena. Može se obaviti isključivo na svježem uzorku. • Not done. Can be done on fresh sample only.	Pericentrična inverzija kromosoma 17. • Pericentric inversion of chromosome 17.
FISH-analiza • FISH analysis	Trisomija kromosoma 4 • Trisomy of chromosome 4	Trisomija kromosoma 4 • Trisomy of chromosome 4

**Slika 1.** Klinička slika desne strane mandibule s laganom oteklinom u bezubom području, posteriorno na prvom pretkutnjaku.**Figure 1** Clinical view of the right mandible demonstrate a mild swelling in the edentulous area, posterior to the first premolar tooth.**Slika 2.** Aksijalna CT-snimka prikazuje osteolitičnu koštanu leziju s dobro definiranim rubovima - zahvaćaju desnu stranu korpusa mandibule.**Figure 2** Axial CT scan demonstrate an osteolytic bone lesion with well defined margins affecting the right body of the mandible.**Slika 3.** Mandibularna lezija. Solidno gnijezdo adenokarcinoma bazalnih stanica od malih tamnih i većih svijetlih bazaloidnih stanica. Tumor infiltrira okolno meko tkivo. (H&E x 100). Identična je arhitektura uočena i kod parotidnog tumora (fotomikrograf nije prikazan).**Figure 3** Mandibular lesion. Solid nest of basal cell adenocarcinoma composed of both small dark and larger pale basaloid cells. The tumor infiltrates into the surrounding soft tissue. (H&E x 100). Identical architecture was seen in the parotid tumor (photomicrograph not shown).**Slika 4.** FISH-analiza parotidne lezije (A) i mandibularne lezije (B) pomoću centromerične sonde kromosoma 4 (CEP 4) - prikazuje tri signala u svakoj stanici (trisomija 4) i u parotidnom i u mandibularnom uzorku.**Figure 4** FISH analysis of the parotid lesion (A) and the mandibular lesion (B), using centromeric probe of chromosome 4 (CEP 4), demonstrating three signals in each cell (trisomy 4), in both the parotid and mandibular samples.

analiza na arhiviranim preparatima iz parafinskog bloka iz primarnog AKBS-a parotidne žlijezde.

Citogenetska i FISH-analiza ispitanih stanica metastaze upućivale su na klon s pericentričnom inverzijom na kromosomu 17 i trisomiju na kromosomu 4 (Tabl.1., Sl.4.). Na kromosomima 8,10,18 i 22 nije bilo nikakvih alteracija. Propisana je radioterapija mandibule od 30 Gy u 10 frakcija.

## Rasprava

Oralna šupljina i čeljusti povremeno su lokacija metastatskih lezija malignih primarnih tumora koji se nalaze drugdje u organizmu. Organi iz kojih tumori tipično metastaziraju u čeljust, u nizu od najčešćega prema najrjeđem su: dojka, pluća, bubreg, debelo crijevo, prostata i štitnjača. Rijetke su udaljene metastaze primarnog tumora žlijezda slinovnica u čeljusti (1).

Klinička patološka obilježja AKBS-a salivarnih žlijezda definirali su Ellis i Wiscovitch (4). Dob oboljelih je u rasponu od nekoliko mjeseci do 92 godine, a najviše je onih između šestog i sedmog desetljeća života. Čini se da nema spolne predileksije. Gotovo svi tumori javljaju se u velikim žlijezdama slinovnicama, a parotida je najčešće implementirana žlijezda. Histološko obilježje koje karakterizira AKBS te ga razlikuje od benigne inačice - adenoma bazalnih stanica, jest invazivni rast. Tumorske stanice često su uočene u blizini živaca i u prodoru unutar živaca, krvnih žila ili susjednih žlijezda slinovnica te ostalih tkiva (4).

U većini slučajeva indeks mitoze nije visok, a dijagnoza malignog tumora ne može se uvijek temeljiti isključivo na tome. Citološka obilježja nisu uvijek ni konkretna ni pouzdana indikacija malignoga potencijala toga tumora (3,5).

Dakle, citogenetika se može smatrati dodatnim alatom (6).

U ovom je slučaju pronađena trisomija na kromosomu 4 i u primarnoj i u metastatskoj leziji, a inverzija kromosoma 17 uočena je samo u metastatskoj leziji. Trebalo bi promatrati točnu ulogu tih kromosomskih alteracija u većoj skupini slučajeva.

Citogenetiku se smatra standardom u skrbi u sklopu hemato-onkologije već dva desetljeća i to u razdoblju postavljanja dijagnoze te u evaluaciji protokola liječenja i prognoze (7).

fluorescence in situ hybridization (FISH), using centromeric probes for chromosome 4, 8, 10, 18 and 22. FISH analysis was also performed on archival paraffin embedded samples from the primary BCAC of the parotid gland.-

Cytogenetic and FISH analyses of the metastasis revealed a clone with pericentric inversion of chromosome 17 and trisomy of chromosome 4 was found in the examined cells. FISH analyses of the primary BCAC performed on paraffin embedded slides, also revealed trisomy of chromosome 4 in the examined cells (Table 1, Fig 4). No alterations were found in chromosomes 8,10,18 and 22. Radiation therapy to the mandible, consisting of 30 Gy in 10 fractions, was provided.

## Discussion

The oral cavity and the jawbones are occasionally the site for metastatic lesions from primary malignant tumors elsewhere in the body. The typical tumors that metastasize to the jaws in order of decreasing frequency are: breast, lung, kidney, colon, prostate and thyroid. Distant metastasis to the jaws from salivary gland tumor is rare (1).

The clinicopathologic features of salivary gland BCAC were defined by Ellis and Wiscovitch (4). The age ranges from a few month to 92 years with a peak incidence in the sixth and seventh decades of life. Apparently, there is no sex predilection. Almost all the tumors occur in the major salivary glands, and the parotid is the most frequently involved gland. The histologic feature that characterizes BCAC and distinguishes it from the benign counterpart, the basal cell adenoma, is the invasive growth. Tumor cells can often be seen surrounding and invading nerves and blood vessels or adjacent salivary gland or other tissues (4).

The mitotic index is not high in most cases and the diagnosis of malignant tumor can not always be considered on this basis alone. The cytologic features may not be always a solid and reliable indicator of the malignant potential of this tumor (3,5).

Therefore, cytogenetics may be considered as an additional tool (6).

In the present case trisomy of chromosome 4 was found in both the primary and metastatic lesions, whereas, inversion of chromosome 17 have been found in the metastatic lesion. The exact role of these chromosomal alterations in the tumorigenesis of BCAC is not known and should be further studied in a larger group of cases.

Cytogenetics is considered standard of care in hemato-oncology for about two decades, at the stage



Ipak, uloga citogenetike u solidnim tumorima nije toliko istaknuta u usporedbi s hemato-onkologijom, ali neprestance se razvija (8). Na primjer, alteraciju kromosoma 4 dovodimo u vezu s oralnim karcinomom pločastog epitela (9,10), a kromosom 17 obično je vezan uz rak dojke i mnoge druge solidne tumore (11). Objavljena je citogenetska analiza mandibularnih tumora kod cementificirajućih fibroma i rhabdomyosarkoma (12,13).

Genetska nestabilnost česta je kod raka. Ona može prouzročiti nakupljanje mutacija koje predstavljaju čimbenik rasta za tumorske stanice. Pomak od premaligne lezije prema malignom tumoru također je vezan za napredovanje genetske nestabilnosti (14).

Identični citogenetski nalazi u primarnom tumoru i u metastatskoj tumorskoj leziji u mandibuli, doveli su nas do zaključka da su obje lezije istog postanka. To je važan doprinos te može pojačati histopatološku dijagnozu mandibularne lezije kao metastatske tvorbe.

Obrada nalaza u ovom slučaju može upozoriti na sljedeće:

- a) citogenetika može pomoći u uspostavljanju dijagnoze oralnog solidnog tumora;
- b) citogenetika može poslužiti kao dodatan postupak u dijagnostici metastaze;
- c) obvezatno je uzeti svjež uzorak za klasičnu citogenetiku, no FISH-analiza se može obaviti i na arhiviranim preparatima iz parafinskih blokova.

Citogenetska se analiza može koristiti kao dodatni instrument u dijagnosticiranju metastaza te se preporučuje kod suspektne metastatske lezije čeljusti.

of the diagnostic workup, as well as in the evaluation of treatment protocols and prognosis (7).

The role of cytogenetics in solid tumors is however less pronounced as compared to hemato-oncology, but it is constantly evolving (8). For example, alterations of chromosome 4 is associated with oral squamous cell carcinoma (9,10), whereas chromosome 17 is usually involved with breast cancer as well as in many other solid tumors (11). Cytogenetic analysis of mandibular tumors were reported in cementifying fibroma and rhabdomyosarcoma (12,13).

Genetic instability is a common event in cancer. This instability might cause accumulation of mutations that confer growth advantages for the tumor cells. The shift from a premalignant lesion to a malignant tumor is also associated with progression of the genetic instability (14).

The identical cytogenetic findings in both the primary tumor and in the metastatic jaw lesion, lead us to the conclusion that both lesions are from one origin. This is an important contribution that can give strength to the histopathologic diagnosis of the mandibular lesion, being a metastasis.

The workup and findings of the present case may point toward the following:

- a) cytogenetics can be helpful in establishing diagnosis in oral solid tumor.
- b) cytogenetics can be an additional tool for diagnosis of a metastasis.
- c) fresh sample is mandatory for classical cytogenetics, however, FISH analysis can also be performed on archival paraffin embedded materials.

Cytogenetic analysis may be used as an additional tool for diagnosis of metastases and is recommended when a metastatic jaw lesion is suspected.

#### Abstract

The diagnosis of metastatic lesion to the jaws is difficult, challenging and is based mainly on histopathology. Distant metastasis of basal cell adenocarcinoma (BCAC) to the mandible from salivary gland tumor is considered rare. A case of mandibular metastasis from parotid BCAC is reported. The use of cytogenetics in the diagnostic work-up is described. Cytogenetic analysis may be used as an additional tool for diagnosis of metastases and is recommended when a metastatic jaw lesion is suspected.

Received: June 18, 2007

Accepted: October 11, 2007

#### Address for correspondence

Prof. Lipa Bodner,  
Department of OMF Surgery,  
Soroka University Medical Center,  
P.O. Box 151,  
Beer-Sheva 84101, Israel.  
Fax: 972-8-6403651  
E-mail: lbodner@bgu.ac.il

#### Key words

Adenocarcinoma; Neoplasm Metastasis;  
Mandible; Jaw

**References**

1. Hirshberg A, Buchner A. Metastatic tumors to the oral region. An overview. *Eur J Cancer B Oral Oncol.* 1995;31B(6):355-60.
2. Bodner L, Sion-Vardy N, Geffen DB, Nash M. Metastatic tumors to the jaws: A report of eight new cases. *Med Oral Patol Oral Cir Bucal.* 2006;11(2):E132-5.
3. Seifert G, Sobin LH. *Histological Typing of Salivary Gland Tumors (WHO)*. 2nd ed. New York: Springer-Verlag; 1991.
4. Ellis GL, Wiscovitch JG. Basal cell adenocarcinoma of the major salivary glands. *Oral Surg Oral Med Oral Pathol.* 1990;69(4):461-9.
5. Raslan WF, Leonetti JP, Sawyer DR. Basal cell adenocarcinoma of the parotid gland: a case report with immunohistochemical, ultrastructural findings and review of the literature. *J Oral Maxillofac Surg.* 1995;53(12):1457-62.
6. Manor E, Sion-Vardy N, Bodner L. Cytogenetic and fluorescence in situ hybridization analysis of basal cell adenocarcinoma of the mandible. *Cancer Genet Cytogenet.* 2006;166(2):186-8.
7. Breems DA, Van Putten WL, Huijgens PC, Ossenkoppele GJ, Verhoef GE, Verdonck LF et al. Prognostic index for adult patients with acute myeloid leukemia in first relapse. *J Clin Oncol.* 2005;23(9):1969-78.
8. Gebhart E. Comparative genomic hybridization (CGH): ten years of substantial progress in human solid tumor molecular cytogenetics. *Cytogenet Genome Res.* 2004;104(1-4):352-8.
9. Pershouse MA, El-Naggar AK, Hurr K, Lin H, Yung WK, Steck PA. Deletion mapping of chromosome 4 in head and neck squamous cell carcinoma. *Oncogene.* 1997;14(3):369-73.
10. Shah SI, Yip L, Greenberg B, Califano JA, Chow J, Eisenberger CF, Lee DJ et al. Two distinct regions of loss on chromosome arm 4q in primary head and neck squamous cell carcinoma. *Arch Otolaryngol Head Neck Surg.* 2000;126(9):1073-6.
11. Ma Y, Lespagnard L, Durbecq V, Paesmans M, Desmedt C, Gomez-Galdon M et al. Polysomy 17 in HER-2/neu status elaboration in breast cancer: effect on daily practice. *Clin Cancer Res.* 2005;11(12):4393-9.
12. Dal Cin P, Sciot R, Fossion E, Van Damme B, Van den Berghe H. Chromosome abnormalities in cementifying fibroma. *Cancer Genet Cytogenet.* 1993;71(2):170-2.
13. Cajaiba MM, Bale AE, Alvarez-Franco M, McNamara J, Reyes-Múgica M. Rhabdomyosarcoma, Wilms tumor, and deletion of the patched gene in Gorlin syndrome. *Nat Clin Pract Oncol.* 2006;3(10):575-80.
14. Ha PK, Pilkington TA, Westra WH, Sciubba J, Sidransky D, Califano JA. Progression of microsatellite instability from premalignant lesions to tumors of the head and neck. *Int J Cancer.* 2002;102(6):615-7.