

Dragana Gabrić Pandurić, Tihomir Kuna, Davor Katanec

Primarni ekstranodularni Non-Hodgkinov limfom usne šupljine prikriven boli nakon vađenja zuba

Pain After Tooth Extraction Masking Primary Extranodal Non-Hodgkin's Lymphoma of the Oral Cavity

Zavod za oralnu kirurgiju Stomatološkog fakulteta Sveučilišta u Zagrebu
Department of Oral Surgery School of Dental Medicine University of Zagreb

Sažetak

Maligni su limfomi u usnoj šupljini rijetki i čine približno 3,5 posto svih malignih promjena u oralnoj regiji. Opisan je slučaj primarnog non-Hodgkinova limfoma na lijevoj strani mandibule. Nakon što je pacijentu izvađen donji lijevi umnjak, perzistirala je spontana i intermitentna bol na lijevoj strani donje čeljusti. Intraoralnim pregledom ustanovljeno je da sporo cijeli postekstrakcijska alveola. Panoramska radiološka snimka pokazala je radiolucenciju s nepravilnim rubovima u stražnjoj mandibularnoj regiji na lijevoj strani. Nakon desetodnevne terapije antibiotikom, bol se smanjila, ali postekstrakcijska je alveola još neadekvatno cijelila. Inicijalno je bila pogrešno postavljena dijagnoza kroničnog osteomijelitisa. Na temelju histološkog i imunohistokemijskog nalaza postavljena je konačna dijagnoza - difuzni velikostanični limfom B-imunofenotipa. Nakon kombinacije radioterapije i kemoterapije, kod pacijenta se postigla potpuna remisija te su se povukli svi klinički znakovi bolesti. Dijagnosticiranje ekstranodularnog limfoma čeljusti je izazov, jer gotovo uvijek postoji sumnja na malignu tvorbu, a često je prikriven oralnim i dentalnim patološkim stanjima. Stomatolog je vrlo važan u ranom otkrivanju malignih limfoma usne šupljine.

Zaprimljen: 5. ožujka 2007.

Prihvaćen: 5. srpnja 2007.

Adresa za dopisivanje

Dragana Gabrić Pandurić
Sveučilište u Zagrebu
Stomatološki fakultet
Zavod za oralnu kirurgiju
Gundulićeva 5, 10 000 Zagreb
dgabric@sfzg.hr

Ključne riječi

neoplazme, oralne; non-Hodgkinov limfom

Uvod

Maligni limfomi su neoplazme limfopoetske grane retikuloendotelijalnog sustava (1). One nastaju iz B- i T- limfocitičnih staničnih linija koje, ovisno o njihovu stupnju razvoja i aktivacije, daju spektar tumora različite zloćudnosti (2). Tradicionalno se limfomi dijele na Hodgkinovu bolest (HD) i non-Hodkinove limfome (NHL), s obzirom na različitost u histološkom nalazu i njihovo ponašanje (3). Maligni limfomi oralnog područja rijetki su i čine

Introduction

Malignant lymphomas are neoplasms of the lymphopoietic portion of the reticuloendothelial system (1). These malignant lymphoid neoplasms arise from B- or T- lymphocytic cell lines that, according to their stage of development or activation, give rise to a spectrum of tumors that exhibit varying behaviors (2). Lymphomas have been traditionally divided into Hodgkin disease (HD) and non-Hodgkin lymphomas (NHL) because of their difference

približno 3,5 posto svih malignih promjena u toj regiji (4, 5). Limfomi su najčešći neepitelijalni maligni tumori u usnoj šupljini i maksilofacijalnom području, te prema tome koliko se često javljaju, treći su u skupini malignih promjena u tom području, nakon planocelularnog karcinoma i neoplazmi žlijezda slinovnica (6, 7).

NHL-i su heterogena skupina limfoproliferativnih malignih promjena koja je mnogo manje predvidiva od Hodgkinove bolesti te znatno češće metastazira u ekstranodularna tkiva i to nakon dužeg razdoblja bez simptoma bolesti (3, 7). Različiti su podaci vezani za čestoću ekstranodularne pojave non-Hodgkinova limfoma i kreću se između 24% i 40% (4, 5, 7-9). Većina slučajeva NHL-a, pa čak i gotovo svi, mogu se naći i u nodularnim i ekstranodularnim područjima. U području glave i vrata najčešća primarna ekstranodularna lokacija je Waldeyrov prsten (2).

Uzrok NHL-a još je nejasan (7). Iako je etiologija bolesti kontroverzna, nekoliko prikaza ističe povezanost NHL-a s virusnim infekcijama te različitim imunosupresivnim bolestima i stanjima, osobito s infekcijom humanim virusom imunodeficijencije (HIV-om) (1, 8, 9). U nekim slučajevima, NHL se povezuje s autoimunim bolestima, kao što su Hashimotov tireoiditis i Sjögranov sindrom (7). Također se smatra da postoji povezanost s gastritisom uzrokovanim mikroorganizmom *Helicobacter pylori* (10). U gotovo svim zemljama za koje su podaci dostupni, povećava se godišnja stopa incidencije za NHL. (11, 12). U posljednja dva desetljeća broj ekstranodularnih oblika bolesti raste više u odnosu prema nodularnim lokalizacijama (13).

Povremeno se maligni limfomi mogu pojaviti u tijelu mandibule (14, 15). Takva dosta rijetka lezija tada stvara velik dijagnostički problem i uglavnom se pogrešno dijagnosticira (16, 17). U diferencijalnoj dijagnostici posebnu pozornost treba posvetiti dentalnoj boli nepoznatog uzroka i oteklinama pronađenima kod prvog pregleda (18). Važno je istaknuti kako je većina oralnih karcinoma bezbolna, pa infekcija ili slična stanja često prikrivaju njihovu kliničku sliku. Također je iznimno važno da je stomatolog obaviješten o različitim kliničkim manifestacijama NHL-a u usnoj šupljini i maksilofacijalnom području, kako bi brzo i pravodobno mogao dijagnosticirati maligno stanje (3).

U ovom prikazu je opisan slučaj primarnog non-Hodgkinova limfoma lijeve strane mandibule prikriven kliničkom slikom komplikacije nakon ekstrakcije zuba.

in histology and patterns of behavior (3). Malignant lymphoma of the oral region are uncommon and account for approximately 3.5% of all oral malignancies (4, 5). Lymphomas are the most frequent non-epithelial malignant tumors in the oral cavity and maxillofacial region and represent the third most common group of malignant lesions in the site, following squamous cell carcinoma and salivary gland neoplasms (6, 7).

NHL are a heterogenous group of lymphoproliferative malignancies that are much less predictable than HD and have a far greater predilection to disseminate to extranodal tissues but often after a long disease free interval (3, 7). Various data exist regarding the incidence of extranodal occurrence of non-Hodgkin lymphoma, which ranges between 24% and 40% (16/1, 1/3,4, 9, 12). Majority of NHL cases, and most probably all of them, may be observed in both nodal and extranodal sites. In the head and neck region, the most common primary extranodal sites involve Waldeyer ring (2).

The cause of NHL is still unclear (7). Although the etiology of NHL remains controversial, several reports suggest an association between NHL and viral infection as well as a variety of immunosuppressive diseases and treatment states, notably human immunodeficiency virus (HIV) infection (1, 8, 9). In some cases, NHL has been related with autoimmune based diseases, such as Hashimoto thyroiditis and Sjögren syndrome (7). It has also been hypothesized that there may be a correlation with *Helicobacter pylori*-induced gastritis (10).

In almost all countries in the world for which good registry information is available, the average annual incidence rate of the NHL has been increasing (11, 12). Extranodal disease increased more rapidly than nodal disease over the past 2 decades (13).

Occasionally oral malignant lymphoma appears in the body of the mandible (14, 15). This uncommon lesion can pose significant diagnostic problems and is frequently misdiagnosed (16, 17). Particular care should be taken to consider it in the differential diagnosis when unexplained dental pain and swelling are present from the first visit (18). It is important to note that the majority of cases of oral cancer are pain free, and it is often infection or a coincidental finding that reveals them. It is important for the dentist to be aware of the various clinical manifestations of NHL of the oral cavity and of the maxillofacial region to diagnose this malignant condition quickly and appropriately (3).

Prikaz slučaja

Pacijenta u dobi od 52 godine njegov je stomatolog poslao u Zavod za oralnu kirurgiju Stomatološkog fakulteta Sveučilišta u Zagrebu radi pregleda i obrade neobične i prolongirane boli nakon ekstrakcije umnjaka i parestezije brade. Bolesnik nije imao priloženu medicinsku dokumentaciju. Izgledom je bio dobrog zdravlja i normalnog statusa. Oko šest tjedana prije dolaska u Zavod, počeo je osjećati spontanu i intermitentnu bol na lijevoj strani mandibule te je četiri dana nakon toga upućen stomatologu. No, bol se nije smirila ni nakon pulpektomije trećega donjeg lijevog molara, obavljene zbog sumnje na ireverzibilni pulpitis. Zato je donji lijevi umnjak ekstrahiran otprilike deset dana nakon endodontskog zahvata. S obzirom na to da je spontana bol u području lijeve mandibule i dalje perzistirala, pacijent je poslan u Zavod. Medicinska anamneza bila je bez osobitosti. Pacijent nije naveo je li imao vrućicu, gubi li na težini ili da li se noću znoji.

Pacijent je istaknuo da je oko četiri mjeseca prije ekstrakcije donjega lijevog umnjaka počeo osjećati utruće brade na lijevoj strani. Ekstraoralnim pregledom nisu pronađene nikakve veće promjene. Nije bilo ni palpabilnih limfnih čvorova u području glave i vrata. Intraoralnim pregledom je otkriveno da neadekvatno cijeli postekstrakcijska alveola u području donjeg lijevog umnjaka (Slika 1.).

Na ortopantomogramu je bilo vidljivo područje radiolucencije s nepravilnim rubovima u lateralnom području mandibule (Slika 2.), ali nije bilo znatnih promjena na radiogramu. Magnetska rezonancija nije obavljena.

Zbog sumnje na kronični osteomijelitis mandibule, prepisali smo desetodnevnu terapiju antibioticima. Nakon toga se spontana bol smanjila, ali je postekstrakcijska alveola i dalje neadekvatno cijelila. Pregledom usne šupljine pronađena je ekstenzivna egzofitična sivo-bijela lezija u postekstrakcijskoj alveoli donjega lijevog umnjaka. Nije bila mekana, bila je fiksirana za podležće tkivo i čvrste gumaste konzistencije. Pacijent je još imao paresteziju lijeve strane mandibule, ispitanu stimulacijom ubodom igle. Zahvaćala je usnu i vrh brade, pokazujući tako zahvaćenost donjeg alveolarnog živca. U lokalnoj anesteziji bila je obavljena inicijalna biopsija lezije u postekstrakcijskoj alveoli. Nakon histološke analize uzorka prve biopsije, nalaz je bio suspektan na maligni non-Hodgkinov limfom. Pronađena je promjena višeslojnoga pločastog epitela, rahla i edematozna stroma prožeta obilnim miješanim upalnim infiltratom. U jednom su žarištu bile lim-

In this report, a case of primary non-Hodgkin lymphoma of the left mandible that manifested clinically as a complication after tooth extraction is presented.

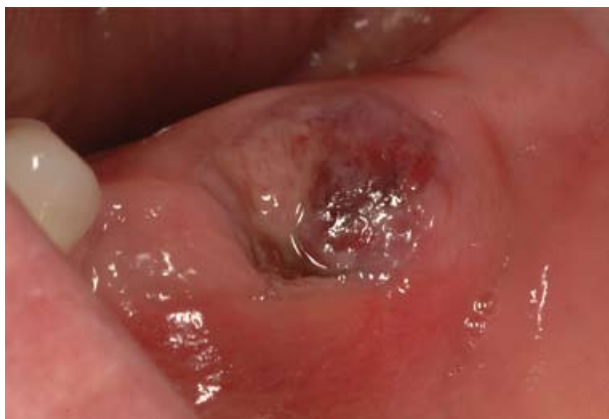Case Report

A 52-year-old man was referred to the Department of Oral Surgery University of Zagreb by his dentist for investigation and treatment of unusual and prolonged pain after third molar extraction and paresthesia of the chin. The patient's medical history was not contributory. He appeared to be in good health and was of normal stature. About 6 weeks before visiting our department, he had noticed spontaneous and intermittent pain of the left mandible and had been referred to a dentist 4 days later. Although pulpectomy of the third left lower molar had been done under the working diagnosis of irreversible pulpitis, the pain had continued. Therefore the third left lower molar was extracted about 10 days after the endodontic treatment. The spontaneous pain of the left mandible had continued and the patient was then referred to our department. Past medical history was unremarkable. He did not complain of fever, weight loss or night sweats.

The patient stated that approximately 4 months before extraction of the wisdom tooth he had begun to feel „numbness“ on the left side of the chin. Extraoral examination revealed no remarkable features. No palpable head and neck lymph nodes were present. Intraoral examination revealed healing retardation of the postextraction socket at the left lower third molar region (Figure 1).

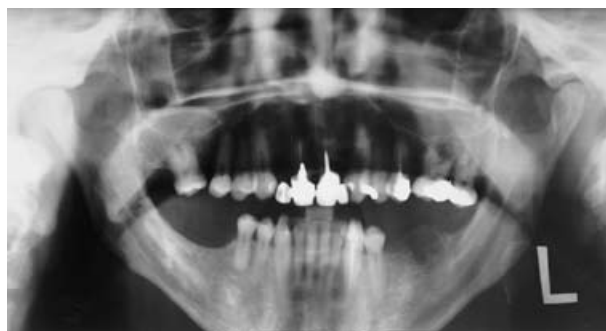A panoramic radiograph revealed a radiolucency in the posterior mandibular region with irregular margins (Figure 2), but there were no significant changes on the radiograph, and magnetic resonance imaging was not performed.

Because chronic osteomyelitis of the mandible was suspected, we prescribed a 10-day course of antibiotics. After that, although the spontaneous pain diminished, inadequacy of the healing at the extraction site was still present. Examination of the oral cavity disclosed extensive exophytic gray-white lesion emanating from left lower third molar extraction site. The lesion was nontender, was fixed to underlying tissue and had a firm rubbery consistency. The patient still had parasthesia to needle-prick stimulation on the left side of the chin. The parasthesia involved the lip and the tip of the chin indicating the involvement of the inferior alveolar nerve. An incisional biopsy of the lesion in postextraction socket was performed with the use



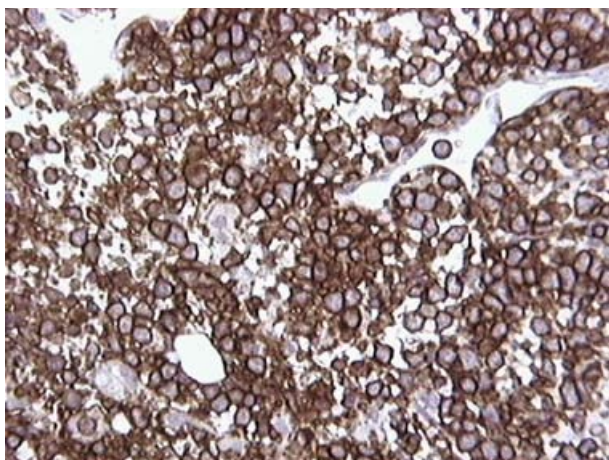
Slika 1. Intraoralna fotografija koja prikazuje neadekvatno cijeljenje postekstrakcijske alveole u području donjeg lijevog trećeg molara.

Figure 1 Intraoral photograph shows healing retardation of the postextraction socket at the left lower third molar region.



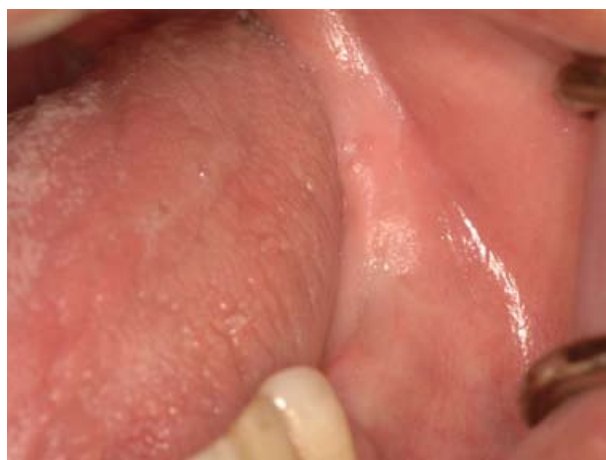Slika 2. Panoramska snimka pokazuje radiolucenciju s nepravilnim rubovima u molarnoj regiji donje čeljusti.

Figure 2 Panoramic radiograph shows radiolucency in the molar region of the mandible with irregular margins.



Slika 3. Imunohistokemijski naden signifikantno pozitivan CD20 antigen, marker B stanične diferencijacije.

Figure 3 Immunohistochemistry reveals significant positivity for CD20 antigen, a marker of B-cell differentiation.



Slika 4. Inspekcijom usne šupljine nađena je potpuna remisija bez ikakvih kliničkih znakova bolesti.

Figure 4 During a further inspection of the oral cavity, the patient showed complete remission with the disappearance of all clinical evidence of disease.

fatične stanice atipičnog izgleda s krupnim jezgama te izražena mitotička aktivnost stanica. Pacijent je tada poslan u Zavod za hematopatologiju, gdje je obavljena kompletna dijagnostička obrada (ponovna biopsija s patohistološkom obradom, ultrazvuk abdomena, CT toraksa i abdomena te citopunkcija palpabilnog limfnog čvora). CT toraksa i abdomena pokazao je laterotrahealni limfni čvor na lijevoj strani u području gornjeg medijastinuma uz arteriju subklaviju, promjera jedan centimetar i povećan limfni čvor promjera dva centimetra retrokruralno u visini hijatusa aorte, te povećane retroperitonealne limfne čvorove lumbalnih regija. Nativni presjeci jetre pokazali su niži koeficijent apsorpcije, što govori u prilog difuzne lezije jetre. Citološki nalaz

of local anesthesia. Histological findings: after analysis of the specimen of the incisional biopsy, malignant non-Hodgkin lymphoma was suspected. Changes were found of the stratified squamous epithelium, dense and edematous stroma, permeated with abundant mixed inflammatory infiltrate. In one focus atypical lymphatic cells were found with large nuclei and marked mitotic cellular activity. The patient was transferred to the Department of Hematopathology where complete diagnostic analysis was performed (a further biopsy with histopathological analysis, abdominal ultrasound, computed tomography (CT) of the thorax and abdomen, cytopuncture of the palpable axial lymph node). CT of the thorax and abdomen showed a laterotracheal lymph node on the left side in the area of the upper me-

punktata pokazao je mnogobrojne nezrele limfatične stanice tipa blasta s izrazito vaskulariziranom citoplazmom. Na osnovi druge biopsije, obavljena je patohistološka analiza. Histološki se radilo o tumorskom tkivu građenom od krupnijih, atipičnih limfatičnih stanica s umjereno obilnim citoplazmama i vezikularnim jezgrama, u kojima su se isticali jedan do dva nukleola. Pronađene su mnogobrojne mitoze i apoptoze te vidljiva slika „zvjezdanog neba“. Imunohistokemija je obavljena na parafinskim presjecima, uz pomoć spektra monoklonalnih antitijela kao markera. Imunohistokemijska analiza je pokazala da su tumorske stanice bile pozitivne na antigen CD20, marker B-stanične diferencijacije te na proteine BcL-2 i BcL-6 (Slika 3.).

Postavljena je dijagnoza primarnog non-Hodgkinova limfoma mandibule, difuznog velikostaničnog limfoma B-imunofenotipa. Ta vrsta ubraja se u limfome visokog stupnja malignosti, a javljaju se u srednjoj i starijoj životnoj dobi, a u tu se skupinu ubraja i naš pacijent. Povećani limfni čvorovi na svim lokalizacijama karakteristični su za limfome visokog stupnja malignosti, što je također utvrđeno u opisanom slučaju. Difuzni velikostanični B non-Hodgkinov limfom može biti lokaliziran, ali često se infiltrira u gastrointestinalni trakt i središnji živčani sustav. Nakon potpune kliničke obrade i verificirane dijagnoze malignog limfoma te primijenjene kombinacije kemoterapije i radioterapije, kod pacijenta je postignuta kompletna remisija i nestali su svi klinički znakovi bolesti, što je bilo uočljivo i tijekom ponovnog pregleda usne šupljine (Slika 4.). Nikakvih rekurentnih znakova nije bilo godinu dana nakon tretmana.

Rasprava

Iako većina non-Hodgkinovih limfoma nastaje u limfnim čvorovima, od 24 do 40 posto tih malignih promjena može imati ektranodularnu lokalizaciju (7, 19-22). Primarni ektranodularni limfomi glave i vrata razmjerno su rijetki (22). Zahvaćenost usne šupljine dosta je rijetka i otkrije se tek u 0,1% do 5% slučajeva (18, 19, 23, 24). Najčešće zahvaćeno područje usne šupljine i maksilofacijalne regije NHL-om jest Waldeyerov prsten (tonzila, nazofarinks, baza jezika, nepčana tonzila), a tonzile

diastinum by the subclavian artery, 1 cm in diameter, and an enlarged lymph node 2 cm in diameter retrocrurally at the height of the hiatus aorta, and also enlarged retroperitoneal lymph nodes of the lumbar region. Native cross sections of the liver showed lower coefficient of absorption, indicating diffuse hepatic lesion. The cytological finding of the needle aspiration of the lesion showed numerous immature lymphatic blast type cells with markedly vascularised cytoplasm. On the basis of the second biopsy histopathological analysis was performed. Histologically it showed tumorous tissue consisting of large, atypical lymphatic cells with moderately abundant cytoplasm and vesicular nuclei, in which 1-2 of the nuclei were prominent. Numerous mitotic figures and apoptosis were found and visible starry sky pattern. Immunohistochemical studies were performed on paraffin sections using a panel of monoclonal antibodies for the markers. Immunohistochemical analysis showed that the tumor cells were positive for CD20 antigen, a marker of B-cell differentiation, BcL-2 and BcL-6 proteins (Figure 3).

The diagnosis was primary non-Hodgkin lymphoma of mandible, diffuse large B-cell type. This type of lymphoma has a high degree of malignancy, which occurs in middle and older age, and the patient belongs to this group. The occurrence of enlarged lymph nodes on all locations is characteristic of highly malignant lymphomas, which was determined in this case. Diffuse B large-cell non-Hodgkin lymphoma may be localised, although it frequently infiltrates into the gastrointestinal tract and central nervous system. After complete clinical treatment and verification of the diagnosis of malignant lymphoma, and application of a combination of chemotherapy and radiotherapy, the patient showed complete remission with the disappearance of all clinical evidence of disease, which was visible during a further inspection of the oral cavity (Figure 4). One year status post treatment, he continues to do well, with no evidence of recurrence.

Discussion

Majority of non-Hodgkin lymphoma arise in lymph nodes, but 24%-40% of these malignancies arise in extranodal locations (7, 19-22). Primary extranodal lymphomas of the head and neck are relatively uncommon (22). Involvement of the oral cavity is particularly rare and accounts for only 0.1% to 5% of cases (18, 19, 23, 24). Most commonly affected site of NHL of the oral cavity and maxillofacial region is Waldeyer ring (tonsil, nasopharynx, base of the tongue, palatine tonsil) and the tonsils are the

su pritom najčešće zahvaćene (12, 25, 26). Primarni limfomi kosti čine oko 5% svih ekstranodularnih limfoma (20, 27, 28). Prema mišljenju Rinnaglia i njegovih suradnika, kad je riječ o čeljustima maksila je mnogo češće zahvaćena od mandibule te su posteriorna područja mnogo češće zahvaćena od anteriornih (20). Iako su primarne intrakoštane lezije NHL-a rijetke, 13% je otkriveno u čeljusti (29). NHL-i čeljusti obično nemaju specifičnih znakova i simptoma. Na limfom čeljusti treba posumnjati ako postoji dentalna bol nepoznatog uzroka, utrnuće, pokretljivost zuba, oteklina, ulceracije sluznice, tkivo u postekstrakcijskoj alveoli, litičke promjene kosti, parestezija ili anestezija alveolarnog živca te cervikalna adenopatija (28, 30-37). Rane lezije mogu se povezati s odontogenom upalom ili parodontnim stanjima, pa se u tom slučaju primjenjuju nepotrebni ili lokalni tretmani (endodontski tretman, ekstrakcija zuba, antibiotska terapija) što produžuje vrijeme do dijagnoze na osnovi biopsije (3, 20). Zbog spomenutih ranih simptoma najprije smo posumnjali na osteomijelitis čeljusti, što je i bila prva i pogrešna dijagnoza, pa je terapija samo prolongirala postavljanje konačne dijagnoze. Lezije primarnog limfoma kosti znatno su impresivnije klinički nego li radiološki. Radiološki nalaz nije specifičan, obično pokazuje difuznu koštanu destrukciju, izgleda poput solitarnog defekta ili nedostatka lamine dure ili sniženog ruba alveolarne kosti, aludirajući na stanja poput parodontitisa ili parodontnog apscesa (20, 37, 38). Iako tradicionalni filmovi mogu pokazati destruktivnu koštanu leziju, uporaba magnetske rezonancije omogućuje kliničaru znatno precizniju sliku destrukcije trabekularne kosti i promjenu koštane srži, što je svojstvo agresivnih tumora (39). Kod našeg pacijenta također nisu pronađene veće promjene na rendgenskoj snimci, a magnetska rezonancija nije bila obavljena.

Dijagnostika ekstranodularnog limfoma čeljusti izazov je zbog uobičajeno niskog stupnja sumnje na takvu promjenu i prikrivenosti malignog tumora uobičajenim oralnim i dentalnim patološkim stanjima. Dijagnoza NHL-a može se postaviti samo na temelju nalaza biopsije. Za to je nužna adekvatno uzeta biopsija te bliska suradnja kliničara i patologa. Uzorak uzet biopsijom mora sadržavati bazu lezije, jer periferni dijelovi mogu imati izgled normalnog tkiva, mora biti uzet oprezno i odmah dostavljen patologu - svjež ili u mediju koji određuje patolog (1). Uzorci obično nisu adekvatni za imunohistokemijsku analizu, jer se oni uzeti biopsijom iz usne šupljine rutinski stavljaju u formalin (35). Zbog istog

most frequent site (12, 25, 26). Primary lymphomas of bone compose about 5% of all extranodal lymphomas (20, 27, 28). According to Rinnagio et al, among jaw lesions the maxilla is more frequently involved than the mandible, with posterior locations favored over anterior sites (20). Although primary intraosseous lesions of NHL are rare, 13% reportedly occur within the jaws (29). NHLs arising in the jaws frequently present with non-specific signs and symptoms. Lymphoma of bone should be considered when there is unexplained dental pain, numbness, tooth mobility, swelling, overlying mucosal ulceration, a mass in the post-extraction socket, lytic osseous changes, inferior alveolar nerve paresthesia or anesthesia and cervical adenopathy (28, 30-37). Early lesions may be attributed to inflammatory odontogenic or periodontal conditions, resulting in unnecessary or infective local treatment (endodontic treatment, extraction, antibiotics) and protected delays before biopsy diagnosis (3, 20). Because of the aforementioned early symptoms we first suspected osteomyelitis, which was the initial misdiagnosis, the its therapy merely prolonged the period to the final diagnosis. Lesions of primary lymphoma of bone are more impressive clinically than radiographically. Radiologic findings are not specific, commonly exhibiting diffuse bone destruction, appearing as a solitary defect or as disappearance of lamina dura or lowering of the alveolar bone margin to a condition resembling periodontitis or periodontal abscesses (20, 37, 38). Although traditional plain films can disclose destructive osseous lesions, the use of magnetic resonance imaging has allowed clinicians to visualize more clearly the pattern of trabecular bone destruction and marrow replacement, characteristic of this aggressive tumor (39). In the case of the patient presented we also did not find significant changes on the radiograph, and magnetic resonance imaging was not performed.

The diagnosis of extranodal lymphoma of the jaw may be challenging, because frequently there is a low index of clinical suspicion and malignant tumor may mimic common oral and dental pathological conditions. The diagnosis of NHL can be made only by means of biopsy. The importance of an adequate biopsy and close cooperation between clinician and pathologist is stressed. The biopsy specimen should include the base of the lesion because peripheral portions of the lesion could represent normal tissue response to the malignant tumor. The specimen should be handled gently and delivered immediately to the pathologist, fresh or in a medium ordered by the pathologist (1). Specimens suit-

je razloga kod prezentiranog pacijenta i ponovljena biopsija na osnovi koje je postavljena konačna dijagnoza, temeljena na histološkom i imunohistološkom nalazu. Sigurno otkrivanje neoplazme temelji se na kombinaciji pažljivog histopatološkog nalaza i trenutačne imunohistokemijske analize (20). Kritični čimbenik u dijagnostici ektranodularnog limfoma čeljusti jest određivanje je li lezija kosti rezultat primarnog limfoma čeljusti ili koštana manifestacija već diseminirane bolesti (16). Kod našeg pacijenta dijagnosticirali smo primarni limfom mandibule zbog parestezije i prije ikakva stomatološkog zahvata. Pacijent nije imao cervikalnu adenopatiju kada je došao u Zavod, niti bilo kakve druge simptome diseminacije. Nakon gotovo tri mjeseca od trenutka pacijentova prvog dolaska do konačne dijagnoze, može se zaključiti da je rasap metastaza nastao u tom razdoblju, što je i otkriveno CT dijagnostikom.

Terapijske mogućnosti za liječenje NHL-a su kemoterapija, radioterapija ili oboje, što ovisi o stupnju malignosti tumora. Kod prezentiranog pacijenta primijenjena je kombinacija kemoterapije i radioterapije, s obzirom na visok stupanj malignosti, što je na kraju rezultiralo potpunom remisijom bolesti.

Prognoza i rezultati liječenja ovise o mnogo čimbenika, kao što su histološki tip, stadij bolesti, vrsta terapije, simptomatologija, primarno žarište, veličina tumora, starost pacijenta i, vjerojatno na prvom mjestu, diferencijalna dijagnostika svake sumnjive oralne promjene (26, 40, 41). Prema tim kriterijima, naš je pacijent trebao imati lošu prognozu s obzirom na visok stupanj malignosti limfoma, starosnu skupinu i kasno postavljenu konačnu dijagnozu. Iako je nakon terapije postignuta potpuna remisija bolesti, pacijenta je potrebno još dugo pratiti i kontrolirati (7). Ako nastupi recidiv bolesti, prijeko je potreban detaljan pregled radi rane detekcije tumorskog relapsa (19).

Zaključak

Sumnja u maligni limfom treba biti neizostavan dio diferencijalne dijagnostike svake oralne lezije. Stomatolog je vrlo važan u ranom otkrivanju

able for immunohistochemistry analysis are usually unavailable because oral biopsy specimens are routinely submitted in formalin (35). For this reason we repeated the biopsy, on the basis of which the final diagnosis for the patient was made, based on histological and immunohistochemical analyses. Careful histopathological review should be coupled with current immunohistochemical analysis to ensure detection of neoplastic features (20). A critical factor in the diagnosis of extranodal lymphoma involving the jawbone is determining whether the lesion actually represents a primary lymphoma of the jawbone or is instead an osseous manifestation of more disseminated disease (16). We diagnosed primary lymphoma of the mandible in the presented patient because of the presence of paresthesia prior to treatment by his dentist. The patient did not have cervical adenopathy on admittance to our Department nor did he have any other symptoms of dissemination. As almost three months passed from the moment the patient was first admitted up to the final diagnosis, we can conclude that during that period dissemination of the metastases occurred in the organ which were revealed during CT diagnostics.

Treatment options for NHL cases are chemotherapy, radiotherapy or both, depending on malignancy grade. In the presented patient chemotherapy and radiotherapy were applied because of the high degree of malignancy, which resulted in the complete remission of the disease.

Prognosis and the treatment outcome depend on many factors, such as the histologic type, the stage of the disease, the type of treatment, the presentation of symptomatology, the primary site, the size of the tumor, the age of the patient, and, maybe at the first place, differential diagnosis for any oral presentation (26, 40, 41). According to this criteria the patient in the case presented should have had poor prognosis because of the high degree of malignancy of the lymphoma, risk age group and late final diagnosis. Although remission of the disease took place after therapy, this patient still needs long-term follow-up. Local recurrence is frequent, including several years after the first diagnosis and long-term follow-up is necessary (7). When minimal residual disease is present, a close follow-up is needed for the early detection of a tumor relapse (4).

Conclusion

Malignant lymphoma should be part of the differential diagnosis for any oral lesions. By taking a rigorous medical history, making a differential di-

malignnih promjena jer uzima detaljnu medicinsku anamnezu, diferencijalnom dijagnostikom istražuje svaku oralnu promjenu, poduzima potrebne pretrage te prepoznaje znakove limfoma B staničnog tipa. Postoji li bilo kakva sumnja da konačna dijagnoza nije točna, potrebno je pacijenta hitno uputiti na specijalističku obradu.

agnosis for any oral presentation, undertaking appropriate investigations, and knowing the signs of B-cell lymphomas, dentists can play the important role in the early detection of these malignancies. If there is any suspicion that the definitive diagnosis is incorrect, then prompt referral for specialist advice is essential.

Abstract

Malignant lymphoma of the oral region are uncommon and account for approximately 3.5% of all oral malignancies. In this report, a case of primary non-Hodgkin lymphoma of the left mandible is presented. The spontaneous and intermittent pain of the left mandible had continued after third left molar extraction. Intraoral examination revealed healing retardation of the postextraction socket. A panoramic radiograph revealed a radiolucency in the posterior mandibular region with irregular margins. After the 10-day course of antibiotics the spontaneous pain diminished, but the inadequacy of the healing at the extraction site was still present. We initially misdiagnosed it as chronic osteomyelitis. Based on the histological and immunohistochemical examination, we made the diagnosis of diffused large cell lymphoma of the B-cell type. After the combination of chemotherapy and radiotherapy patient showed complete remission with the disappearance of all clinical evidence of disease. The diagnosis of extranodal lymphoma of the jaw may be challenging, because frequently there is a low index of clinical suspicion and malignant tumor may mimic common oral and dental pathological conditions. Dentists can play the important role in the early detection of the malignant lymphoma of the oral cavity.

Received: March 5, 2007

Accepted: July 5, 2007

Address for correspondence

Dragana Gabrić Pandurić
University of Zagreb
School of Dental Medicine
Department of Oral Surgery
Gundulićeva 5, HR-10 000 Zagreb,
Croatia
dgabric@sfzg.hr

Key words

Mouth Neoplasms; Lymphoma,
Non-Hodgkin

References

- Griffin TJ, Hurst PS, Swanson J. Non-Hodgkin's lymphoma: a case involving four third molar extraction sites. *Oral Surg Oral Med Oral Pathol.* 1988;65(6):671-4.
- Pazoki A, Jansisyanont P, Ord RA. Primary non-Hodgkin's lymphoma of the jaws: Report of 4 cases and review of the literature. *J Oral Maxillofac Surg.* 2003;61(1):112-7.
- Kolokotronis A, Konstantinou N, Christakis I, Papadimitriou P, Matiakis A, Zaraboukas T et al. Localized B-cell non-Hodgkin's lymphoma of oral cavity and maxillofacial region: a clinical study. *Oral Surg Oral Med Oral Pathol Oral Radiol Endod.* 2005;99(3):303-10.
- Sakuma H, Okabe M, Yokoi M, Eimoto T, Inagaki H. Spontaneous regression of intraoral mucosa-associated lymphoid tissue lymphoma: molecular study of a case. *Pathol Int.* 2006;56(6):331-5.
- Stenson KM, Wolf GT, Urba S. Extranodal non-Hodgkin's lymphoma of the head and neck: presentation in the facial bones. *Am J Otolaryngol.* 1996;17(4):276-80.
- Shindoh M, Takami T, Arisue M, Yamashita T, Saito T, Kohgo T et al. Comparison between submucosal (extra-nodal) and nodal non-Hodgkin's lymphoma (NHL) in the oral and maxillofacial region. *J Oral Pathol Med.* 1997;26(6):283-9.
- Lopez-Jornet P, Bermejo-Fenoll A. Oral mucosal non-Hodgkin's lymphoma. *Oral Oncol Extra.* 2005;41(6):101-3.
- Eisenbud L, Sciubba J, Mir R, Sachs SA. Oral presentations in non-Hodgkin's lymphoma: a review of thirty-one cases. Part I. Data analysis. *Oral Surg Oral Med Oral Pathol.* 1983;56(2):151-6.
- Albuquerque MA, Migliari DA, Sugaya NN, Kuroishi M, Capuano AC, Sousa SO et al. Adult T-cell leukemia/lymphoma with predominant bone involvement, initially diagnosed by its oral manifestation: a case report. *Oral Surg Oral Med Oral Pathol Oral Radiol Endod.* 2005;100(3):315-20.
- Nishimura M, Miyajima S, Okada N. Salivary gland MALT lymphoma associated with Helicobacter pylori infection in a patient with Sjögren's Syndrome. *J Dermatol.* 2000;27(7):450-2.
- Weisenburger DD. Epidemiology of non-Hodgkin's lymphoma: recent findings regarding an emerging epidemic. *Ann Oncol.* 1994;5 Suppl 1:19-24.
- Epstein JB, Epstein JD, Le ND, Gorsky M. Characteristics of oral and paraoral malignant lymphoma: a population-based review of 361 cases. *Oral Surg Oral Med Oral Pathol Oral Radiol Endod.* 2001;92(5):519-25.
- Lin AY, Tucker MA. Epidemiology of Hodgkin's disease and non-Hodgkin's lymphoma. In: Canellos GP, Lister TA, Sklar JL editors. *The lymphomas.* Philadelphia: Saunders; 1998. p. 43-60.
- Dosoretz DE, Raymond AK, Murphy GF, Doppke KP, Schiller AL, Wang CC et al. Primary lymphoma of bone: the relationship of morphologic diversity to clinical behavior. *Cancer.* 1982;50(5):1009-14.
- Pettit CK, Zukerberg LR, Gray MH, Ferry JA, Rosenberg AE, Harmon DC et al. Primary lymphoma of bone. A B-cell neoplasm with a high frequency of multilobated cells. *Am J Surg Pathol.* 1990;14(4):329-34.
- Remadi S, Korbi S, Kuffer R. Malignant lymphoma of the mandible. *Ann Pathol.* 1992;12(1):29-33.
- Nishioka T, Tsuchiya K, Nishioka S, Kitahara T, Ohmori K, Homma A et al. Pilot study of modified version of CHOP plus radiotherapy for early-stage aggressive non-Hodgkin's lymphoma of the head and neck. *Int J Radiat Oncol Biol Phys.* 2004;60(3):847-52.
- Kawasaki G, Nakai M, Mizuno A, Nakamura T, Okabe H. Malignant lymphoma of the mandible. *Oral Surg Oral Med Oral Pathol Oral Radiol Endod.* 1997;83(3):345-9.
- Freeman C, Berg JW, Cutler SJ. Occurrence and prognosis of extranodal lymphomas. *Cancer.* 1972;29(1):252-60.

20. Rinaggio J, Aguirre A, Zeid M, Hatton MN. Swelling of the nasolabial area. *Oral Surg Oral Med Oral Pathol Oral Radiol Endod.* 2000;89(6):669-73.
21. Dey P, Luthra UK, Sheikh ZA, Mathews SB. Fine needle aspiration cytology of primary non-Hodgkin's lymphoma of the tongue. A case report. *Acta Cytol.* 1999;43(3):422-4.
22. Clark RM, Fitzpatrick PJ, Gospodarowicz MK. Extranodal malignant lymphomas of the head and neck. *J Otolaryngol.* 1983;12(4):239-45.
23. van der Waal RI, Huijgens PC, van der Valk P, van der Waal I. Characteristics of 40 primary extranodal non-Hodgkin lymphomas of the oral cavity in perspective of the new WHO classification and the International Prognostic Index. *Int J Oral Maxillofac Surg.* 2005;34(4):391-5.
24. Skarin AT, Dorfman DM. Non-Hodgkin's lymphomas: current classification and management. *CA Cancer J Clin.* 1997;47(6):351-72.
25. Shima N, Kobashi Y, Tsutsui K, Ogawa K, Maetani S, Nakashima Y et al. Extranodal non-Hodgkin's lymphoma of the head and neck. A clinicopathologic study in the Kyoto-Nara area of Japan. *Cancer.* 1990;66(6):1190-7.
26. Ezzat AA, Ibrahim EM, El Weshi AN, Khafaga YM, AlJurf M, Martin JM et al. Localized non-Hodgkin's lymphoma of Waldeyer's ring: clinical features, management, and prognosis of 130 adult patients. *Head Neck.* 2001;23(7):547-58.
27. Kirita T, Ohgi K, Shimooka H, Okamoto M, Yamanaka Y, Sugimura M. Primary non-Hodgkin's lymphoma of the mandible treated with radiotherapy, chemotherapy and autologous peripheral blood stem cell transplantation. *Oral Surg Oral Med Oral Pathol Oral Radiol Endod.* 2000;90(4):450-5.
28. Gusenbauer AW, Katsikeris NF, Brown A. Primary lymphoma of the mandible: report of a case. *J Oral Maxillofac Surg.* 1990;48(4):409-15.
29. Ostrowski ML, Unni KK, Banks PM, Shives TC, Evans RG, O'Connell MJ et al. Malignant lymphoma of bone. *Cancer.* 1986;58(12):2646-55.
30. Barber HD, Stewart JC, Baxter WD. Non-Hodgkin's lymphoma involving the inferior alveolar canal and mental foramen: report of a case. *J Oral Maxillofac Surg.* 1992;50(12):1334-6.
31. Parrington SJ, Punnia-Moorthy A. Primary non-Hodgkin's lymphoma of the mandible presenting following tooth extraction. *Br Dent J.* 1999;187(9):468-70.
32. Liu RS, Liu HC, Bu JQ, Dong SN. Burkitt's lymphoma presenting with jaw lesions. *J Periodontol.* 2000;71(4):646-9.
33. Ardekian L, Peleg M, Samet N, Givol N, Taicher S. Burkitt's lymphoma mimicking an acute dentoalveolar abscess. *J Endod.* 1996;22(12):697-8.
34. Park YW. Non-Hodgkin's lymphoma of the anterior maxillary gingiva. *Otolaryngol Head Neck Surg.* 1998;119(1):146.
35. Nocini P, Lo Muzio L, Fior A, Staibano S, Mignogna MD. Primary non-Hodgkin's lymphoma of the jaws: immunohistochemical and genetic review of 10 cases. *J Oral Maxillofac Surg.* 2000;58(6):636-44.
36. Pecorari P, Melato M. Non-Hodgkin's lymphoma (NHL) of the oral cavity. *Anticancer Res.* 1998;18(2B):1299-302.
37. Söderholm AL, Lindqvist C, Heikinheimo K, Forssell K, Happonen RP. Non-Hodgkin's lymphomas presenting through oral symptoms. *Int J Oral Maxillofac Surg.* 1990;19(3):131-4.
38. Mealey BL, Tunder GS, Pemble CW 3rd. Primary extranodal malignant lymphoma affecting periodontium. *J Periodontol.* 2002;73(8):937-41.
39. Yasumoto M, Shibuya H, Fukuda H, Takeda M, Mukai T, Korenaga T. Malignant lymphoma of the gingiva: MR evaluation. *AJNR Am J Neuroradiol.* 1998;19(4):723-7.
40. Nathu RM, Mendenhall NP, Almasri NM, Lynch JW. Non-Hodgkin's lymphoma of the head and neck: a 30-year experience at the University of Florida. *Head Neck.* 1999;21(3):247-54.
41. Harabuchi Y, Tsubota H, Ohguro S, Himi T, Asakura K, Kaitaura A et al. Prognostic factors and treatment outcome in non-Hodgkin's lymphoma of Waldeyer's ring. *Acta Oncol.* 1997;36(4):413-20.