

Coll. Antropol. **24** (2000) 2: 529–539  
UDC 572:781(37)»01/02«  
Original scientific paper

# Morphological and Biomechanical Analysis of a Skeleton from Roman Imperial Necropolis of Casalecchio di Reno (Bologna, Italy, II-III c. A. D.). A Possible Case of Crutch Use

M. G. Belcastro and V. Mariotti

Department for Experimental Evolutional Biology, Anthropology,  
University of Bologna, Bologna, Italy

## ABSTRACT

*A Roman skeleton (T.130) from the roman necropolis of Casalecchio di Reno has been studied in order to understand if the hypothesis of crutch use, suggested by the severe articular degeneration at the hip joint that caused evident reduction of his locomotory possibilities, could be supported by the morphological alterations of other bones and joints.*

*The pathological changes and muscular development of the upper limbs and shoulder girdle bones suggest that these parts were submitted to a great mechanical stress. The observations are consistent with the hypothesis of crutch use that would have involved a new weight-bearing function of the upper limbs in order to help locomotion, even though it is difficult to assess the number and type of the crutches. The comparison with other possible cases of crutch use reported in literature gives an additional support to the interpretation of the findings.*

## Introduction

The study of human skeletal remains from a paleopathological and functional point of view can lead to the reconstruction of the possible habitual motional and postural behaviour as well as the life style of individuals.

These kinds of studies are hindered by many interpretative difficulties. The main problem concerns the difficulty of finding the aetiology of bone traces (activity, trauma, infections, other pathologies, ageing processes, heredity, etc.). Studies in sport and occupational medicine can be very helpful, but caution should be used in ap-

---

Received for publication December 19, 2000.

plying them to past people<sup>1</sup>. Moreover, the functional consequences of skeletal pathologies, as well as the dynamic meaning of skeletal markers of activity (muscular and ligament impressions, etc.), are not univocal. This leads to the impossibility, in most cases, of a specific functional interpretation of bone traces, especially without support from archaeological or historical evidence. Therefore we can only provide hypotheses on the level and type of activity.

The aim of our study is to infer, from postcranial morphological skeletal features, the possible functional implications of severe pathological alterations of the coxo-femoral joint in an aged male belonging to a Roman population settled in Casalecchio di Reno (Bologna, Italy) during the Imperial period. The necropolis of Casalecchio ('B' necropolis, II-III c. A.D.) consists of 43 burials (26 inhumations, 12 incinerations and 5 of unknown burial rite) and is part of a larger burial area (Mengoli, personal communication).

### Materials and Methods

This study focuses on an aged male skeleton (T.130), which shows a nearly complete ankylosis of the right hip joint together with other pathological traits. This fact accounts for severe difficulties of deambulation. The hypothesis of the crutch use, previously suggested by Giusberti (personal communication), lead us to conduct a deep overall observation of the morphological skeletal features in order to possibly confirm his proposal.

The postural and functional consequences of severe coxo-femoral alterations have been studied through the observation of articular and non-articular pathologies, traumas<sup>2-4</sup> and degree of development of entheses, scored following a method developed by Mariotti<sup>5</sup>.

Our results were compared with some cases reported in literature<sup>6,7</sup>.

The bones preserved of the skeleton are shown in Figure 1.

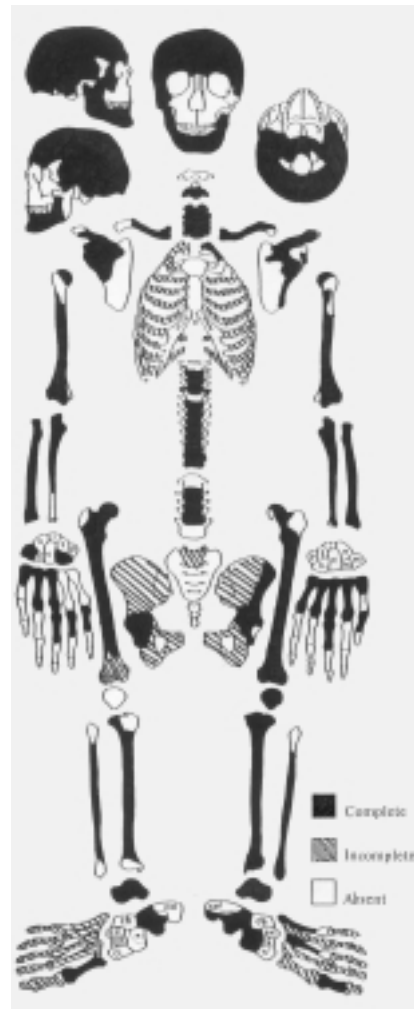

Fig. 1. State of preservation of the skeleton.

### Morphological and Biomechanical Analysis

This skeleton shows severe articular degeneration of the head of the **right femur**, greatly enlarged, with conspicuous marginal lipping, pitting and traces of eburnation (Figure 2). The morphology

was described by Hrdlicka as *caput penis*<sup>2</sup>. The corresponding **acetabulum** shows similar features (Figure 2). Articulating the two bones, the joint is almost completely ankylosed by the exostosis formation on the border of both acetabulum and femoral head: the femur results blocked at a semiflexed position (about 70°–80°), probably in some degree of adduction difficult to assess because of the incompleteness of the innominate bone. Moreover enthesopathies of the articular capsula (Figure 2) are observed. The primary cause of these severe alterations is not clear and some events could be considered to explain it (heavy physical workload<sup>8</sup>, osteoarthritis-OA, traumatic events, etc.). However, radiological examination of the specimens did not show evidence for trauma. Bennike & Bro-Rasmussen<sup>9</sup> refer that an ankylosis of a joint can be caused by only a few month's immobility. Dutour suggests that the hip joint of T.130 ankylosed because the man was forced in a sitting position (personal communication). In any case, it seems clear that the leg could not touch the ground; thus an external support to walk, probably given by one or two crutches, was utilised.

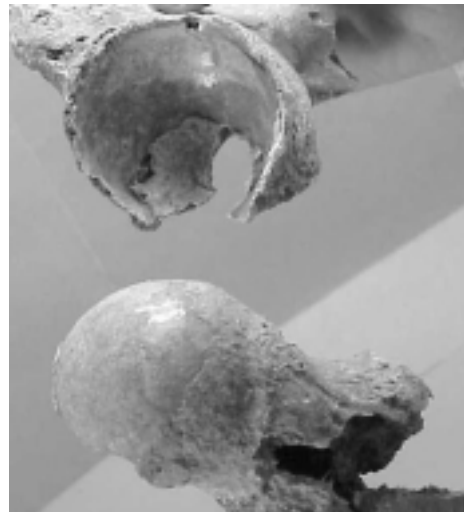
The other morphological features seem to confirm this hypothesis.

The left **femur** also shows articular degeneration of the head, though less severe than the right one, with a wide eburnated antero-superior area and a modified morphology of the neck (Figure 3). The preserved fragment of the corresponding **coxal bone** shows a wide eburnated area in the postero-superior part of the acetabulum and a conspicuous laminal marginal lipping; the acetabular fossa raises above the surface of the *facies lunata*. The position and extension of the eburnated areas of the two bones seem to indicate the walking movements.

Both **tibiae** show a high development of the insertion site of *m. soleus* and *pa-*



*Fig. 2. Top: right femur and acetabulum, showing conspicuous articular degeneration. Bottom: particular of the surface of the right coxal bone fragment preserved.*



*Fig. 3. Left femur and acetabulum, showing the corresponding wide eburnated areas.*

tellar ligament. The latter is ossified on the left **patella** (the right is missing) (Figure 4). Articular degeneration is present in both knees and feet and in the right ankle (not detectable in the left side).



Fig. 4. *Left patella (anterior view) with ossification of patellar ligament.*

Unfortunately the foot bones are not well preserved. However we observed a large laminal marginal lipping of the posterior facet of the left talus that, like the lipping observed on the left acetabulum, could be considered as an adaptation to additional effort suffered by the left lower limb, probably mostly concerned with weight-bearing.

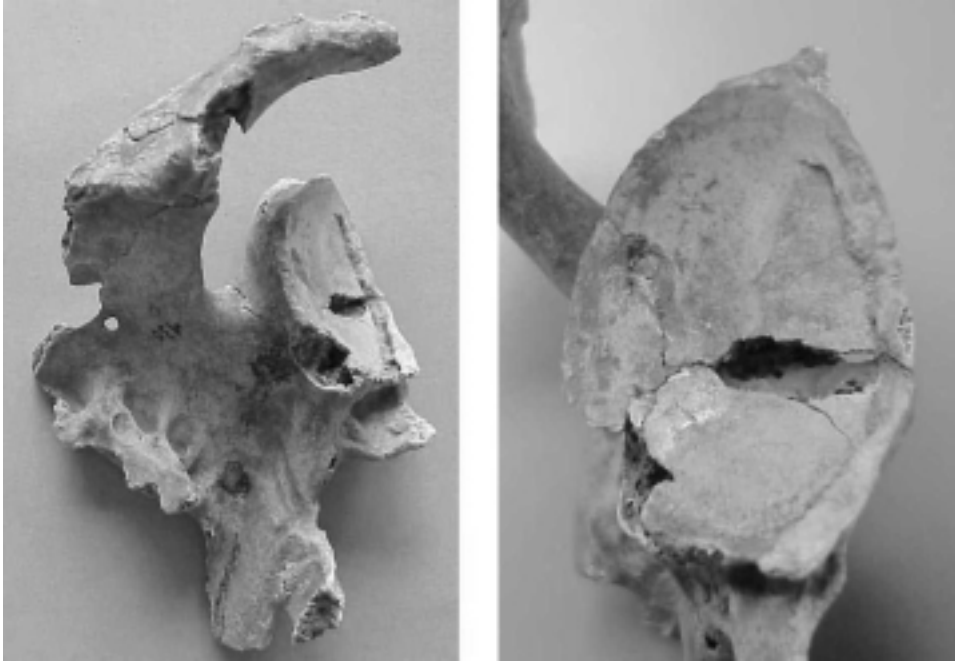
The joints of the upper limb show patterns of conspicuous articular degeneration attributed to mechanical stress<sup>10–14</sup>. Jurmain<sup>15</sup> pointed out that mechanical stress acts directly on the joint surfaces, while biological ageing is more closely related to changes in the marginal areas. Surface changes (pitting and eburnation) as well as marginal lipping are present in the joints of T.130.

Evidence for compressive forces, probably due to a weight-bearing function consistent with crutch use, are especially


present in the right elbow (the left was not preserved) and in both wrists and hands – more severe on the right side –. A conspicuous degeneration associated with eburnation of the scapulo-humeral, acromio-clavicular and sterno-clavicular joints also support the idea of severe mechanical stress.

In particular the glenoid cavity of the **right scapula** is eburnated in the posterior half, with an evident middle longitudinal line (Figure 5). This observation is consistent with the attrition during up and down movements of the humeral head, with the humerus in lateral rotation. In fact, a circular eburnated area (diameter ~ 1.5 cm) in the corresponding humeral head is observed (Figure 6). The glenoid margin is buttressed by new bone formation that can be attributed to the ossification of the labrum. Ossifications at the insertion sites for *m. teres minor* and *m. triceps brachii* and a great development of the *m. deltoideus* have been observed. In addition the infraspinous fossa is reduced to a »clot«, probably as a result of a traumatic event (not evident in the radiograph), that could have been worsened by the action of the *m. infraspinatus*. The **left scapula** also shows marginal lipping at the glenoid cavity; in addition, it has an enlarged and eburnated acromial facet (Figure 7) (the right one is altered as well, but to a lesser extent). Here, too, a great development of *m. deltoideus* is present.

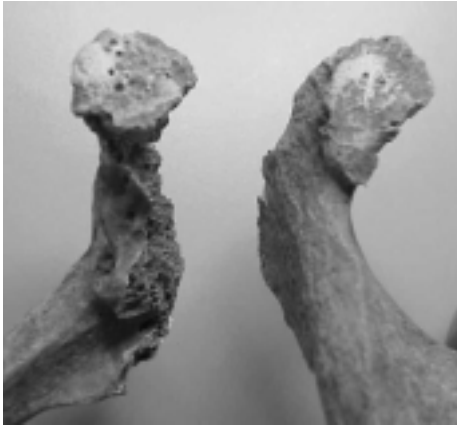
Both **clavicles** have enlarged and porotic sternal facets, the left also showing eburnation (Figure 8), and a great development of the insertion sites for *m. pectoralis major* and *m. deltoideus*. The **left clavicle** shows ossifications of the conoid and trapezoid ligaments and a degeneration of the acromial facet similar to that of the acromial facet on the scapula (Figure 7). The enthesopathy of the costal tuberosity is present only on the right side (Figure 8).



*Fig. 5. Left: right scapula (dorsal view), showing marginal lipping and eburnation of the glenoid cavity, great enthesophytes at the insertion sites for *m. triceps brachii* and *m. teres minor*; the infraspinous fossa reduced to a 'clot' and the great development of the insertion site for *m. deltoideus*. Right: detail of the right glenoid cavity, showing the particular eburnation.*



*Fig. 6. Right humeral head; note the eburnated area (left) and the conspicuous marginal lipping (right).*



*Fig. 7. Acromial extremity of the left clavicle and acromial process of the left scapula, showing the enlarged and eburnated corresponding acromial facets. Note also, on the clavicle, the ossification of the coraco-clavicular ligaments.*

The features of the humeral heads fit with those of the corresponding glenoid cavities (marginal lipping in both and eburnation in the right one, see Figure 6). In both **humeri** there is a great development of the insertion sites for *m. deltoideus*, *pectoralis major* and *latissimus dorsi/teres major*; enthesopathies on the lateral epicondyles of both humeri, insertion sites of the common extensor of the hand, have been observed (Figure 9). This leads one to think of the powerful extension of the wrist as when the hand grasps a crutch to support the body weight.

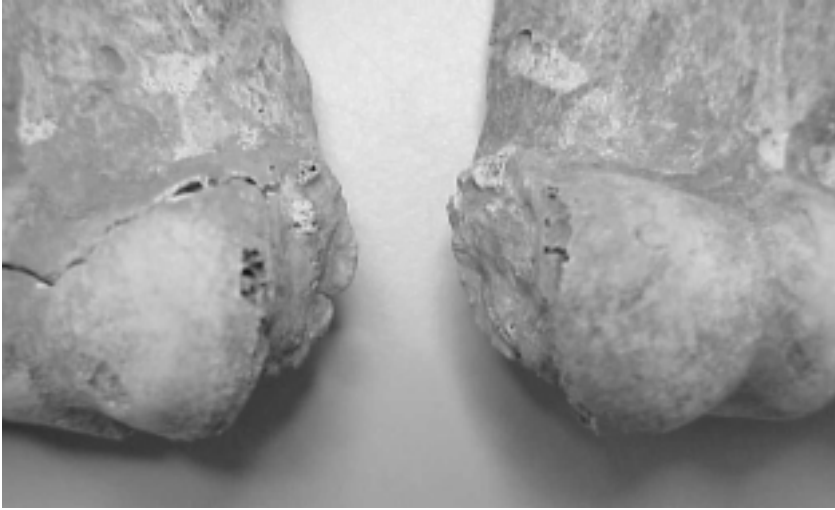
In both **radii** the insertion sites for *m. biceps brachii*, *m. pronator teres* and the *Weitbrecht* ligament are developed, more on the right side. Moreover, the distal articular surface shows conspicuous marginal lipping and eburnation (Figure 10). In both **ulnae** there are moderate enthesophytes at the *m. triceps brachii* insertion and a development of the interosseous crest, more evident on the right side. The insertion site of the *m. anconeus* is developed on the right side, but not detectable on the left side.




*Fig. 8. Top: sternal end of left and right clavicles. Bottom: detail of the enlarged and eburnated sternal facet of the left clavicle.*

Almost all the bones of both hands show severe articular degeneration with eburnation. The left trapezius is fused with the first metacarpal (Figure 11). Moreover, in the third left proximal phalanx there is an eburnated palmar extension of the distal articular surface indicating a great flexion of the intermediate phalanx, suggesting a strong grasp, probably on the crutch.

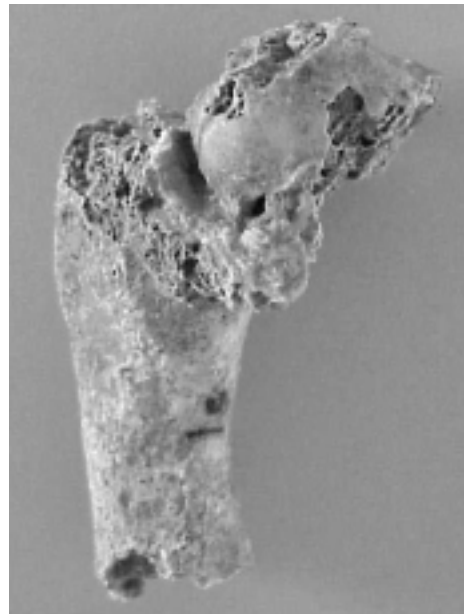
Since other cases are not reported in literature for Roman or earlier periods, except the skeleton T.115 from the same necropolis, for which the evidence of crutch use is not so clear, but however possible (Mariotti and Belcastro, in preparation), a comparison was carried out only with two medieval skeletons from Great Brit-



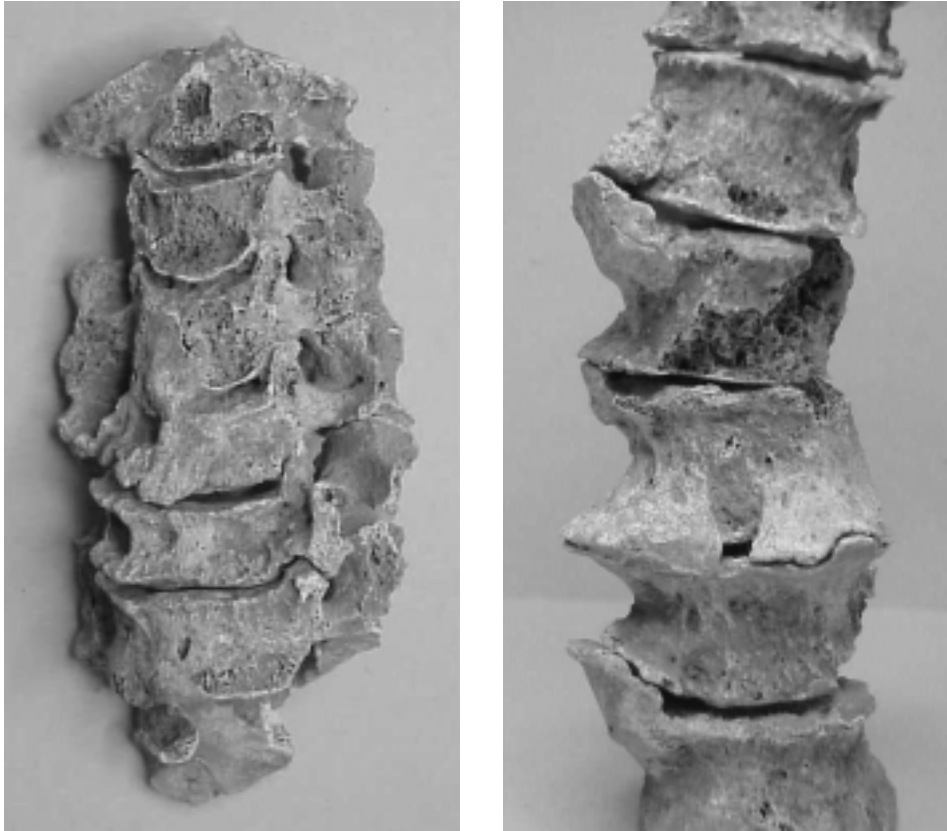
*Fig. 9. Lateral epicondyles of left and right humeri with entesopathy at the insertion site of the common extensor of the hand.*



*Fig. 10. Top: right and left distal epiphyses of radii with severe articular degeneration. Bottom: detail of the distal articular surface of the right radius showing the eburnated area.*



*Fig. 11. Left trapezium fused with the first metacarpal (medial view).*



*Fig. 12. Left: cervical vertebrae (anterior view). Right: thoracic vertebrae (T6-T12) (anterior view).*

ain. In fact nearly all the features we found in T.130 have also been observed on these skeletons, both showing a highly pathological right femur<sup>6,7</sup>. In one case the Authors hypothesise the use of a single crutch, while in the other case the use of axillary crutches is invoked, but without specifying if they were one or two. The articular and muscular patterns displayed by the individual of T.130 are consistent with the movements requested by crutch-aided locomotion. Most likely, two crutches were used according to the bilaterality of the changes. This implies an overuse of all upper limb joints in a weight-bearing function, a lateral rotation of the

humerus (m. teres minor, m. infraspinatus), an extension of the elbow against resistance (m. triceps brachii, m. anconeus) and adduction of the shoulder in order to prevent falling when the crutches touch the ground (m. pectoralis major). The use of the m. deltoideus, responsible for abduction and medial movement of the arm both on and backward, in crutch-aided locomotion has been proved by the EMG study<sup>16</sup>.

Although, as written above, many of the features observed could be explained as a result of crutch use, we cannot neglect to mention some other factors that could have played a role in their arising.



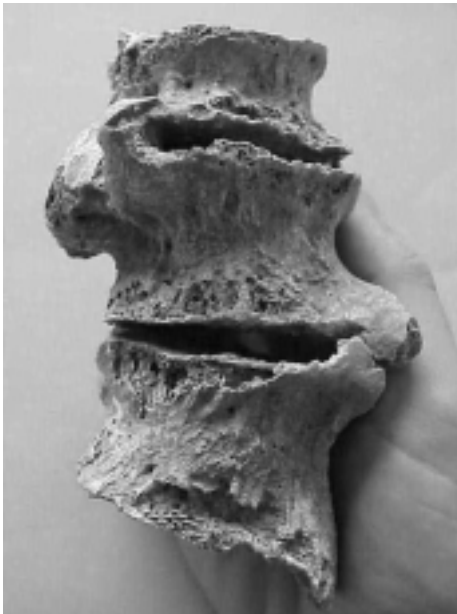First of all, we cannot exclude that the alterations of the right shoulder could be related to a probable traumatic event suffered by the corresponding scapula.

The **vertebral column** shows alterations such as marginal lipping, eburnation, porosity of C6 and C7 vertebral bodies and fusion of the C3-C5 (Figure 12). The same features are observed in the arches of the thoracic and lumbar traits. Syndesmophytes in the thoracic trait and fusion in the lumbar region (L2-L4, see Figures 12, 13) are also seen. The vertebral bodies show massive osteophytes, some with horizontal and some with vertical development, localised on both sides of the spine. These aspects are more compatible with severe osteoarthritis rather than Diffuse Idiopathic Skeletal Hyperostosis (DISH) even if some characteristics are also compatible with this disease<sup>3,11,17–19</sup>. In fact there is no evidence of

flowing ossification. Moreover, even if in many cases we cannot evaluate the laterality of the lesion, the most developed entesophytes we observed (scapular insertion of *m. triceps brachii* and *teres minor*) are unilateral. Thus it seems that this individual suffered from severe OA rather than hyperostosis. In this context, many articular and enthesopathic features could be reasonably attributed to a heavy mechanical stress related to the crutch use.

As already pointed out, the muscles involved in crutch-aided locomotion are particularly developed and enthesopathies of some of those muscles have been related to activity in other studies (quoted in Dutour<sup>20</sup>): *m. triceps brachii* on the olecranon (wood cutters, blacksmiths, baseball players), common flexor and extensor on the medial and lateral epicondyle of humerus (javeline throwers or golf players and tennis players), *m. biceps brachii* at the radial tuberosity (masons, bakers). The articular lesions observed on the two wrists are necessarily correlated with microtrauma, due to so called SLAC-wrist syndrome observed bilaterally on occupational and sporting conditions (pneumatic hammer workers, boxers, volleyball players and weights-lifters)<sup>21</sup>. The use of the crutches constitutes a good illustration of such microtrauma of the wrists.

Moreover, it should be noted that the large entesophyte observed on the scapula at the *m. triceps brachii* insertion, has been similarly observed on the right scapula of a shoemaker (male, 39 years old) belonging to a modern skeletal collection<sup>5</sup>. The skeleton of this individual (complete and well preserved) did not show other particular pathological traits. It seems thus possible that this feature is due to overuse of the triceps muscle, during the hands-on activities of this worker (hand sewing of leather, etc.).



*Fig. 13. Lumbar vertebrae (L2-L4) (anterior view).*

## Conclusions

We can hypothesise that this individual under study in this work used two crutches according to the bilaterality of skeletal modifications, although it is more difficult to assess the type of crutches (with or without axillary or hand-support). The different pattern of modification of the shoulders seems to suggest the use of two different types of crutches (such as a stick and an axillary crutch) or a different distribution pattern of the body weight on the crutches. Since there is a lack of evidence of crutch use in the osteoarcheological series, we think that this skeleton could represent a good reference

for both bioarcheological and forensic studies.

## Acknowledgements

The Authors wish to thank Prof. Fiorenzo Facchini and Prof. Ezio Fulcheri for their helpful suggestions. We thank Dr. Maurizio Busacca of the Istituto Ortopedico Rizzoli of Bologna, Italy, for the radiographic analysis.

A particular thank goes to Prof. Olivier Dutour for his thorough observation of the skeleton and helpful critical comments on the manuscript.

## REFERENCES

1. DUTOUR, O., *Bull. Mém. Soc. Anthrop. Paris*, 4 (1992) 233. — 2. ORTNER, D. J., W. G. J. PUTSCHAR, Identification of pathological conditions in human Skeletal Remains (Washington: Smithsonian Institution Press, 1981). — 3. MANN, R. W., S. P. MURPHY, Regional atlas of bone disease. A guide to pathologic and normal variation in the human skeleton (Springfield: C. C. Thomas, 1990). — 4. ROGERS, J., T. WALDRON, A field guide to joint disease in Archaeology (Chichester: John Wiley & Sons, 1995). — 5. MARIOTTI, V., Ricerche metodologiche sugli indicatori scheletrici morfologici di attività. (Tesi di Dottorato in Scienze Antropologiche, Università degli Studi Di Bologna, 1998). — 6. KNÜSEL, C. J., Z. C. CHUNDUN, P. CARDWELL, *Intern. J. Osteoarch.*, 2 (1992) 209. — 7. KNÜSEL, C. J., S. GÖGSEL, *Intern. J. Osteoarch.*, 3 (1993) 155. — 8. WALDRON, T., *Intern. J. Osteoarch.*, 7 (1997) 186. — 9. BENNIKE, P., F. BRO-RASMUSSEN, *Intern. J. Anthrop.*, 4 (1989) 137. — 10. ORTNER, D. J., *Amer. J. Phys. Anthrop.*, 28 (1968) 139. — 11. ROGERS, J., T. WALDRON, P. DIEPPE, I. WATT, *J. Archaeol. Sc.*, 14 (1987) 179. — 12. PALFI, G., *Bull. Mém. Soc. Anthrop. Paris*, 4 (1992) 209. — 13. PALFI, G., *Bull. Mém. Soc. Anthrop. Paris*, 9 (1997) 1. — 14. PALFI, G., O. DUTOUR, *Intern. J. Anthrop.*, 11 (1996) 41. — 15. JURMAIN, R. D., *Intern. J. Osteoarch.*, 1 (1991) 247. — 16. PEACOCK, B., *Physiotherapy*, 52 (1966) 264. — 17. CRUBEZY, E., *J. Paleopath.*, 3 (1989) 107. — 18. ARRIAZA, B. T., *Amer. J. Phys. Anthrop.*, 91 (1993) 263. — 19. MAAT, G. J. R., R. W. MASTWIJK, E. VAN DER VELDE, *Intern. J. Osteoarch.*, 5 (1995) 289. — 20. DUTOUR, O., *Amer. J. Phys. Anthrop.*, 71 (1986) 221. — 21. MASMEJEAN, E., O. DUTOUR, C. TOUAM, C. OBERLIN, *Ann. Chirur. Main (Ann. Hand Surg.)*, 16 (1997) 207.

*M. G. Belcastro*

*Dip. Biologia Evoluzionistica Sperimentale – Antropologia, Università degli Studi, Via Selmi 3, 40126 Bologna, Italia*

**MORFOLOŠKA I BIOMEHANIČKA ANALIZA KOSTURA IZ RIMSKE NEKROPOLE CASALECCHIO DI RENO (BOLOGNA, ITALIJA, II-III STOLJEĆE PO KRISTU): PRIMJER MOGUĆEG KORIŠTENJA ŠTAKA**

**S A Ž E T A K**

Rimski kostur (T. 130) iz rimske nekropole Casalecchio di Reno proučen je s ciljem da se provjeri da li pretpostavljenu uporabu štaka, koju nagovještaju izrazite degenerativne promjene zgloba kuka koje su prouzročile očito smanjenje lokomotornih sposobnosti, mogu poduprijeti morfološke promjene drugih kostiju i zglobova.

Patološke promjene, kao i razvoj mišićja ruku i kostiju ramenog obruča, ukazuju na izloženost velikim mehaničkim naprezanjima. Navedena opažanja podržavaju pretpostavku o uporabi štaka, što podrazumijeva da ruke preuzimaju velik dio opterećenja kako bi pomogle pri kretanju. Broj i vrstu štaka teško je procijentiti. Usporedba s drugim primjerima moguće uporabe štaka, poznatim iz literature, dodatno podržava ovakvo tumačenje nalaza.