

SKIN TUMORS OF THE PERIORBITAL REGION AND EYELIDS IN THE 1998-2002 PERIOD

Majda Vučić, Jasna Talan-Hranilović, Vesna Vucelić, Sanda Rožanković¹ and Renata Iveković

Ljudevit Jurak University Department of Pathology and ¹University Department of Ophthalmology, Sestre Milosrdnice University Hospital, Zagreb, Croatia

SUMMARY – The aim of this study was to determine the prevalence, sex and age distribution and localisation of the skin tumours and precancerous skin lesions in the periorbital region and eyelids during the 1998-2002 period among biopsy specimens in University Department of Pathology “Ljudevit Jurak. During observed period there were total number of 286 tumours and precancerous lesions. The most common was basal cell carcinoma with slightly female prevalence. Other analysed lesions; nevus, precancerous lesions and squamous cell carcinoma were found with significantly higher female prevalence. The most frequent localisation for all lesions was on the eyelids probably as the consequence of UV irradiation. Average age and standard deviation for all lesions in time of diagnoses was 65 ± 8 years for males and 64 ± 7 years for females. All patients with skin lesions should be advised of the risk of recurrent or new tumours. Prevention remains of prime importance in minimising the morbidity and mortality of lesions in this region. Exposure to ultra-violet (UV), especially UV-B, radiation is the most common cause for genetic abnormalities in cells and provoked factor in oncogenesis of skin tumours.

Key words: *skin tumours, precancerous lesions, periorbital region, eyelids, UV-provoked skin lesions*

Introduction

Skin tumours and precancerous lesions have a significant morbidity in geriatric population, although with relatively low mortality rates.^{1,2} Periorbital region and eyelids are the regions almost permanently and every day sun exposed parts of the skin.^{3,4} Among all lesions which mostly appear on sun exposed parts of the skin such as periorbital region and eyelids non melanoma skin tumours are the most common. In this region mostly arise basal cell carcinoma and the more aggressive squamous cell carcinoma.⁵ Sunlight is the most important factor in aetiology of precancerous lesions and epithelial skin tumours. Precancerous skin lesions often alternate into squamous cell carcinoma, with a latency of 10-20 years.^{6,7} The levels of UV

irradiation rise significantly through depletion of ozone layer so precancerous lesions and epithelial skin tumours will become an important health problem in future.⁸

The aim of this study was to determine the prevalence, sex and age distribution and localisation of precancerous lesions (actinic keratosis, Morbus Bowen) and skin tumours in the periorbital region and eyelids in bioptic material in University Department of Pathology “Ljudevit Jurak”.

Patients and methods

Data source were surgical biopsies excised in Department of Ophthalmology. Pathohistologic analysis was routinely performed on H&E slides. Pathological reports were computed in Thanatos Registry “Ljudevit Jurak” University Department of Pathology, Sestre Milosrdnice University Hospital and retrospectively analysed in period between 1998-2002 years. We analysed prevalence, sex and

Correspondence to: *Majda Vučić M.D.*, “Ljudevit Jurak” University Department of Pathology, Sestre Milosrdnice University Hospital, Zagreb, Croatia

E-mail: majda.vucic@hi.hinet.hr

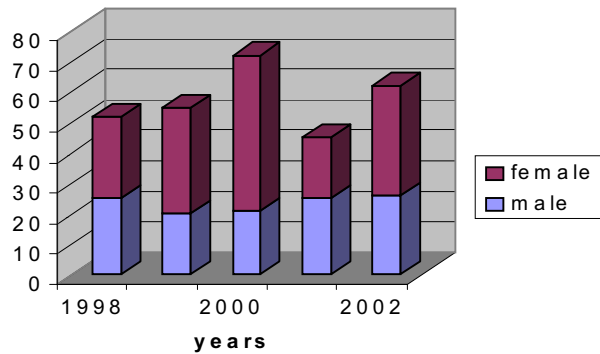


Figure 1. Distribution of analyzed skin lesions according to sex in the 1998-2002 period

age distribution and localisation of precancerous lesions and skin tumours in the periorbital region and eyelids.

Results

Total number of all skin lesions of the periorbital region retrospectively collected and analysed was 286. Distribution of histological types during the period 1998-2000 is shown in Table 1. The peak incidence of analysed skin lesions was in the year 2000 (Figure 1).

Among all analysed biopsies there were 72 nevoid lesions (25.7%), 16 precancerous lesions (5.7%), 14 squamous cell carcinomas (4.9%). The basal cell carcinoma was found with the most prevalence in 179 analyzed biopsies (63.7%). In one case combination of basal and squamous cell carcinoma was found. Additionally 3 malignant melanomas of the periorbital skin were found.

Table 1. Distribution according to histological types of the skin lesions in the 1998-2002 period

Histological type /years	1998	1999	2000	2001	2002	Total
Basal cell carcinoma	39	40	44	19	37	179
Squamous cell carcinoma	1	0	5	6	2	14
Precancerous lesions	1	1	3	5	8	18
Nevoid lesion	11	15	22	8	16	72
Malignant melanoma	0	0	2	0	1	3
Total	52	56	76	38	64	286

Table 2. Average age and sex distribution of the skin lesions in the 1998-2002 period

Histological type	Basal cell carcinoma	Squamous cell carcinoma	Precancerous lesions	Nevoid lesion	Malignant melanoma
Average age /years/	64:70	74:67	64:72	58:47	75:23
M:F					
Sex	1:1,1	1:1,8	1:3	1:3	1:0,5
M:F					

The basal cell carcinoma was presented with slight female prevalence, there were 97 females and 82 males. Sex distribution according to years is shown in Figure 2. Squamous cell carcinoma was rare tumour found in 9 female and 5 male patients. Precancerous lesions also predominate in female patients, actinic keratosis was found in 12 females compared with 4 males. Nevus lesions were present in 54 female and 18 male patients. It is also found 2 male patients with malignant melanoma and 1 female patient. Average age and male/female ratio is shown in Table 2. Average age for male patients with basal cell carcinoma, squamous cell carcinoma and precancerous lesions were 67 years while for same lesions in females were 70 years. Nevoid lesions were diagnosed in average age of 58 years for males and 47 for females. Majority of tumours was located on eyelids followed with canthal region while 24 cases (8.4% of all analysed tumours) was located on conjunctiva as it is seen in Table 3. Among conjunctival tumours 4 squamous cell carcinoma, 1 basal cell carcinoma, 18 nevi and 1 actinic lesion were found.

Discussion

Basal cell carcinoma in analysed material was the most common malignant skin tumour as it is reported in other published literature data. In previously analysed material

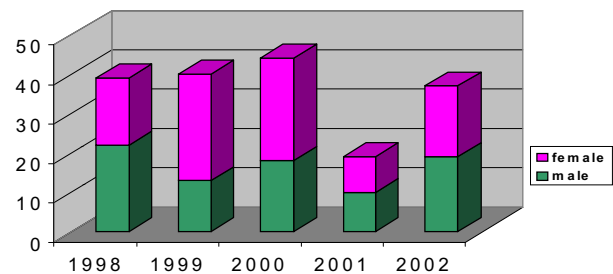


Figure 2. Frequency of basal cell carcinoma per sex in the 1998-2002 period

Table 3. Localisation of the skin lesions in the 1998-2002 period

Localisation	Number of skin lesions
Eyelids	111
Rooth of the nose	25
Canthal region	45
Supraorbital region	24
Infraorbital region	51
Conjunctiva of the globe	24
Periorbital region	6
Total	286

for the same region during 1981-1992 years total number of 498 lesions was found. The most frequent finding was basal cell carcinoma also with female prevalence.⁶ During the 1998-2002 period basal cell carcinoma was presented with slightly female prevalence while other analysed lesions were found significantly more common in female population. The mean age for all lesions was 65 years for males and 64 years for females. The eyelids are the most common localisation for all skin tumours of the head. The precancerous lesions and skin tumours in periorbital region and eyelids didn't show continuous increase trend in incidence rate. Despite the presence of various types of tissues in this region and the possibility to develop several other kinds of malignancies, the most frequent lesion were carcinomas.^{9,10} With an early diagnosis and correct treatment, prognosis is good especially for basal cell carcinoma. The purpose of the surgical treatment is not only the excision of the lesion, but also to maintain shape and function of the eyelid.¹¹ Because presentation varies and histological examination is required for accurate diagnosis, any suspicious lesion occurring on the eyelids should be excised and biopsied. Long-term exposure to UV radiation is considered a major risk factor. Ultraviolet light is known to cause DNA damage in the epidermis. The damaged DNA is repaired or deleted by apoptosis to prevent the generation of cancer. It has been suggested that a deficient apoptotic mechanism may predispose individuals to skin cancer.¹² These results imply that patients with basal cell carcinoma BCC have enhanced sensitivity to UV radiation or that there is some defect in the cell arrest or repair pathways, which results in damaged cells been pushed into apoptosis rather than repair. Squamous cell carcinomas of the skin were suggested to develop through a multistep process that involves activation of proto-oncogenes and/or inactivation of tumor suppressor genes in the human skin keratinocytes.¹³ Exposure to ultra-violet, especially UVB, radiation is the most common cause for these genetic abnormalities in cells. The photons of sunlight begin a series of

genetic events in skin leading to cancer¹⁴ All patients with periorbital and eyelid skin lesions should be advised of the risk of recurrent or new tumours and encouraged to attend lifelong follow up. Prevention remains of prime importance in minimising the morbidity and mortality of lesions in this region.^{10,11}

References

1. WOODHEAD AD, SETLOW RB, TANAKA M. Environmental factors in non melanoma and melanoma skin cancer. *J Epidemiol* 1999;9:102-14.
2. FRANCESCHI S, LEVI K, RANDIMBISON L, La VECCHIA C. Site distribution of different types of skin cancer: new aetiological clues. *Int J Cancer* 1996;67:24-8.
3. LEVI K, LA VECCHIA C, LUCCHINI F, NEGRI E. Trends in cancer mortality sex ratios in Europe, 1950-1989. *World Health Stat Q* 1992;45:117-64.
4. VASSALLO JA, ESPASANDIN JA, VIGNALE RA. Epidemiologic aspects of cancer in the skin in Uruguay. *Med Cutan Ibero Lat Am* 1984;12:285-91.
5. COEBERGER JW, NEUMANN HA, VRINTS LW, van der HEIJDEN L, MEIJER WJ, VERHAGEN-TEULINGS MT. Trends in the incidence of non melanoma skin cancer in the SE Netherlands 1975-1988: a registry based-study. *Br J Dermatol* 1991; 125:353-9.
6. TALAN-HRANILOVIĆ J, ČAJKOVEC V, GREGUREK-NOVAK T, PADOVAN S. Frequency of skin cancer and other ultraviolet radiation provoked skin lesions of eyelid and periocular region in the 1981-1992 period. *Acta med Croat* 1996;50:29-32.
7. ARLETTE JP, CARRUTHERS A, THRELFALL WJ, WARSHAWSKI LM. Basal cell carcinoma of the periocular region. *J Cutan Med Surg* 1998;2:205-8.
8. LINDGREN G, DIFFEY BL, LARKO O. Basal cell carcinoma of the eyelids and solar ultraviolet radiation exposure. *Br J Ophthalmol* 1998;82:1412-5.
9. DONALDSON MJ, SULLIVAN TJ, WHITEHEAD KJ, WILLIAMSON RM. Squamous cell carcinoma of the eyelids. *Br J Ophthalmol* 2002;86:1161-5.
10. MENCIA GUTIERREZ E, HERRERO LLUCH MJ, GUTIERREZ DIAZ E, GALVEZ RUIZ A. Basal cell and squamous cell carcinomas of the eyelid in adults under 50 years of age: 13 cases. *Arch Soc Esp Otolol* 2001;76:643-8.
11. COOK BE JR, BARTLEY GB. Epidemiologic characteristics and clinical course of patients with malignant eyelid tumors in an incidence cohort in Olmstead County, Minnesota. *Ophthalmology* 1999;106:746-50.
12. MARGO CE, MULLAZD. Malignant tumors of the eyelid: a population-based study of non-basal cell and non-squamous cell malignant neoplasms. *Arch Ophthalmol* 1998;116:195-8.
13. LEFFELL DJ. The scientific basis of skin cancer. *J AM Acad Dermatol* 2000;42:18-22.
14. COOK BE JR, BARTLEY GB. Treatment options and future prospects for the management of eyelid malignancies: an evidence-based update. *Ophthalmology* 2001;108:2088-98.

Sažetak

TUMORI KOŽE PERIORBITALNE REGIJE I VJEĐA U RAZDOBLJU 1998 DO 2002

M. Vučić, J. Talan-Hranilović, V. Vučelić, S. Rožanković^d and R. Iveković

U radu je prikazana učestalost, razdioba po godinama i spoli te lokalizaciji kožnih tumora i predtumorskih promjena u bioptičkom materijalu na Kliničkom Zavodu za Patologiju "Ljudevit Jurak" u vremenu od 1998-2002. godine u području oko očne duplje i na kopcima. U proučavanom razdoblju nađeno je 286 tumora i predtumorskih promjena. Najčešći tumor bio je karcinom bazalnih stanica s nešto češćim javljanjem u žena. Ostale analizirane promjene; madeži, predtumorske promjene i karcinom pločastih stanica nađeni su sa značajno većom učestalošću u žena. Najčešća lokalizacija analiziranih promjena je na kopcima kao moguća posljedica UV zračenja. Prosječna dob u svim promjenama u trenutku postavljanja dijagnoze i standardna devijacija bila je 65 ± 8 godina u muškaraca i 64 ± 7 godina u žena. Svi bolesnici s promjenama na koži imaju rizik pojave novih tumora. Najvažniji faktor u smanjenju pobola i smrtnosti promjena u ovoj regiji ostaje prevencija. Izlaganje UV zračenju, posebice UV-B zračenju je najvažniji poznati uzrok promjena genetskog materijala u staniци i provocirajući čimbenik u razvoju kožnih tumora.

Ključne riječi: tumori kože, predtumorske promjene, područje oko očne duplje, kopcima, UV – zračenje