

FEATURE

CHRISTMAS 2012: YESTERDAY'S WORLD

Revisiting the harem conspiracy and death of Ramesses III: anthropological, forensic, radiological, and genetic study

Zahi Hawass *egyptologist*¹, Somaia Ismail *professor of molecular biology*^{2,3}, Ashraf Selim *professor of radiology*⁴, Sahar N Saleem *professor of radiology*⁴, Dina Fathalla *molecular biologist*³, Sally Wasef *molecular biologist*⁵, Ahmed Z Gad *molecular biologist*³, Rama Saad *molecular biologist*³, Suzan Fares *molecular biologist*³, Hany Amer *assistant professor of pharmacology*⁶, Paul Gostner *radiologist*⁷, Yehia Z Gad *professor of molecular genetics*², Carsten M Pusch *molecular biologist*⁸, Albert R Zink *paleopathologist*⁹

¹Supreme Council of Antiquities, Zamalek, Cairo, Egypt; ²Department of Medical Molecular Genetics, National Research Center, Cairo, Egypt; ³Ancient DNA Laboratory, Egyptian Museum, Cairo, Egypt; ⁴Department of Radiology, Kasr Al Ainy Faculty of Medicine, Cairo University, Cairo, Egypt; ⁵Learning Resource Center, Kasr Al Ainy Faculty of Medicine, Cairo University, Egypt; ⁶Department of Animal Reproduction, National Research Center, Egypt; ⁷Department of Radiodiagnostics, Central Hospital Bolzano, Bolzano, Italy; ⁸Institute of Human Genetics, Division of Molecular Genetics, University of Tübingen, Tübingen, Germany; ⁹Institute for Mummies and the Iceman, European Academy, 39100 Bolzano, Italy

Abstract

Objective To investigate the true character of the harem conspiracy described in the Judicial Papyrus of Turin and determine whether Ramesses III was indeed killed.

Design Anthropological, forensic, radiological, and genetic study of the mummies of Ramesses III and unknown man E, found together and taken from the 20th dynasty of ancient Egypt (circa 1190-1070 BC).

Results Computed tomography scans revealed a deep cut in Ramesses III's throat, probably made by a sharp knife. During the mummification process, a Horus eye amulet was inserted in the wound for healing purposes, and the neck was covered by a collar of thick linen layers. Forensic examination of unknown man E showed compressed skin folds around his neck and a thoracic inflation. Unknown man E also had an unusual mummification procedure. According to genetic analyses, both mummies had identical haplotypes of the Y chromosome and a common male lineage.

Conclusions This study suggests that Ramesses III was murdered during the harem conspiracy by the cutting of his throat. Unknown man E is a possible candidate as Ramesses III's son Pentawere.

Introduction

The end of Ramesses III's life has long been debated among Egyptologists. A series of historical documents, of which the most important is the Judicial Papyrus of Turin,^{1,2} clearly state

that in the year 1155 BC, members of his harem made an attempt on his life as part of a palace coup. According to the documents, the coup failed, but it is unclear whether the assassination was successful. The Judicial Papyrus recounts four separate trials and lists the punishments meted out to those involved in the conspiracy. Chief conspirators included a secondary queen Tiy, and her son Prince Pentawere.¹

The ancient documents refer to Ramesses III as "the Great God," and imply that he had died before or during the trials. However, the texts also imply that the court received direct instructions from the king, who must therefore have survived the original attack.¹ The only line specifically interpreted by Egyptologists as a possible metaphor for an assassination is the "overturning of the royal bark."² Such circumlocution regarding the cause of a king's death has long been considered to be part of the protocol of ancient Egyptian literature.

Owing to the inconclusive nature of this textual evidence, and the lack of any obvious cause of death found in previous forensic studies of the king's mummy,³ scholars have argued a variety of possibilities: the king was injured as part of the plot and later died from his wounds, the plot was foiled entirely, or the attempt was successful.⁴ Moreover, the mummy of Prince Pentawere has not been definitively identified. However, scholars have considered the mummy of unknown man E as a possible candidate, who was found, like Ramesses III, in the royal cache

at Deir el Bahari. Unknown man E's contorted expression, unusual mummification process, and goat skin were noted during the unwrapping of the mummy in 1886.⁵ There has also been much speculation about the cause of his death, with poison or burial alive mentioned as possibilities, but no conclusive evidence for either.³

To gather more information about the harem conspiracy and the fates of Ramesses III and the suspected conspirator involved in his assassination, we analysed the mummies of Ramesses III and unknown man E using anthropological, forensic, radiological, and genetic methods.

Methods

The two mummies underwent a detailed morphological inspection to evaluate preservation and record any signs of injuries or postmortem damage. We combined this information with computed tomography (CT) scans, and did an anthropological and forensic analysis to determine the mummies' ages and possible causes of death. CT scans were performed using a multidetector CT unit (Somatom Emotion 6; Siemens Medical Solutions) installed on a truck.

Bone samples were taken from different body areas of the mummies (left and right humerus, tibia and femur, iliac bone) using sterilised biopsy needles (HS Trapsystem), and immediately transferred into sterile tubes. Bone sampling was done under sterile conditions in a dedicated room of the Egyptian Museum in Cairo. All staff involved in the sampling wore protective clothing, sterile gloves, and facemasks to prevent exogenous contamination. DNA extraction and purification were performed according to our previously published protocols in a dedicated laboratory in the Egyptian Museum, and replicated in a second laboratory at the Faculty of Medicine in Cairo University.⁶ Both laboratories performed DNA typing under strict precautions, following previously published criteria for ancient DNA authentication.⁶⁻⁸

We did a genetic kinship analysis to investigate a possible family relationship between Ramesses III and unknown man E. We amplified 16 Y chromosomal, short tandem repeats (AmpFSTR Yfiler PCR amplification kit; Applied Biosystems). Eight polymorphic microsatellites of the nuclear genome were also amplified (Identifiler and AmpFSTR Minifiler kits; Applied Biosystems). The Y chromosomal haplogroups of Ramesses III and unknown man E was screened using the Whit Athey's haplogroup predictor.⁹

Results

The CT investigation revealed a serious wound in the throat of Ramesses III's mummy, directly under the larynx (fig 1). The injury was roughly 70 mm wide and extended to the bones (fifth to seventh cervical vertebra), severing all soft tissue areas in the anterior side of the neck (fig 2). The trachea was clearly cut and its proximal and distal ends were retracted and separated by about 30 mm. A small, focal cortical interruption at the anterior surface of vertebral body was visible, at the seventh cervical vertebra (fig 2). Accordingly, all organs in this region (such as the trachea, oesophagus, and large blood vessels) were severed. The extent and depth of the wound indicated that it could have caused the immediate death of Ramesses III.

A flat, irregular foreign object was lodged in the right lower rim of the wound; it was roughly 15 mm in diameter with a high CT density (2200 HU), similar to a semiprecious stone (fig 2). Reconstruction of this foreign object showed a wedjet (or Horus eye) amulet (fig 3). The eye of Horus is a magical amulet that

served as a metaphor of royal power, protection, and good health in ancient Egypt.¹⁰

We estimated unknown man E to be about 18-20 years old, based on the incomplete fusion of epiphyseal lines in the long bones, as seen in CT scans. Unknown man E underwent an unusual process of mummification for the 20th dynasty of ancient Egypt (1186-1070 BC), because there was no evidence of removal of the inner organs or brain.¹¹ The skin has a reddish colour and the body was covered by a goat skin. Use of goat or sheep skins in dynastic burials was rare because these materials were regarded ritually impure.¹²⁻¹³ The red coloration of the mummy's skin could have been caused by a mixture of natron, crushed resin, and lime, which had been detected under a layer of bandages during the unwrapping in 1886.⁵

Unusual compressed skin folds and wrinkles were seen directly under the right mandible and at the right and left neck regions (fig 4). CT scans confirmed residue in the brain and inner organs, and the absence of embalming material inside body cavities (fig 5). The scans also revealed taphonomical changes in the mummy, as shown by gas formation in the abdominal cavity, urinary bladder, hip, and lower neck (figs 5 and 6). The thorax also seemed to be strongly inflated with air, together with widened intercostal spaces and a lateral shifting of the scapulae (fig 6). This effect could be due to postmortem processes of degradation in the mummy, but other reasons for the thorax widening should be considered. In modern cases, diseases such as emphysema or death by suffocation can lead to overinflation of the lungs.¹⁴

Genetic kinship analyses revealed identical haplotypes in both mummies (table 1); using the Whit Athey's haplogroup predictor, we determined the Y chromosomal haplogroup E1b1a. The testing of polymorphic autosomal microsatellite loci provided similar results in at least one allele of each marker (table 2). Although the mummy of Ramesses III's wife Tiy was not available for testing, the identical Y chromosomal DNA and autosomal half allele sharing of the two male mummies strongly suggest a father-son relationship.

Discussion

This study gives clues to the authenticity of the historically described harem conspiracy surrounding Ramesses III, and finally reveals its tragic outcome. Our CT analysis provides evidence that conspirators killed Ramesses III by cutting his throat. The large and deep cut wound in his neck must have been caused by a sharp knife or other blade. Damage to the throat after death appears to be unlikely, because the collar around the mummy's neck was intact and undamaged at the unwrapping in 1886, where a thick layer of bitumen was removed with a hammer from the mummy.¹⁵ It is a possibility that the throat was cut during the mummification process. Embalmers often restored damages during mummification, by inserting wooden sticks or replacing missing body parts;¹⁶ however, a treatment in which the throat was cut by the embalmers has not been described in any other Egyptian mummy.

Further evidence of an assassination comes from the presence of a Horus eye amulet in the wound. The presence of the amulet deep in the soft tissue of the wound together with the homogeneous material that penetrated the wound up to the bone substantiate the supposition that the wound was already present at the time of embalming. Most probably, the ancient Egyptian embalmers tried to restore the wound during mummification by inserting the amulet (generally used for healing purposes)

and by covering the neck with a collar of thick linen layers (fig 7↓).

Our analysis showed that Ramesses III and unknown man E shared the same paternal lineage and had identical alleles at autosomal markers, strongly suggesting that they were father and son. However, based on the genetic testing, any differentiation among the several sons of Ramesses III was not possible. Historically, Pentawere was the only son who revolted against his father in contrast to all his brothers. According to the Judicial Papyrus of Turin, Pentawere was involved in the harem conspiracy, was found guilty at trial, and then took his own life.

The unusual mummification process of unknown man E, including the ritually impure use of a goat skin to cover the body, could be interpreted as evidence for a punishment in the form of a non-royal burial procedure. Together with the genetically proven family relationship with Ramesses III, we therefore believe that unknown man E is a good candidate for Pentawere. Unknown man E's cause of death has to remain a matter of speculation. His inflated thorax and the skinfolds around his neck may point to violent actions that led to death, such as strangulation. However, the lack of further evidence for strangulation (such as fractures in the laryngeal skeleton)¹⁷ and the gas formation in the body caused by decomposition processes does not allow any clear conclusions regarding the cause of death of unknown man E.

We thank the Supreme Council of Antiquities of Egypt for their generous support of this study.

Contributors: ZH, SI, YZG, CPM, and ARZ designed the study, analysed the data, and drafted the manuscript. AS, HA, SNS, and PG did the radiological and forensic data analysis. DF, SW, AZG, SF, and RS provided and analysed the molecular data. All the authors reviewed the final version of the manuscript. ZH, AZG, CPM, and ARZ had full access to all of the data in the study, and take responsibility for the integrity of the data and the accuracy of the data analysis. ARZ is the study guarantor.

Funding: This study was supported by Discovery Channel and Brando Quilici productions and the Landesgraduierten-Förderung Tübingen. The writing of the article and the decision to submit the article for

publication was entirely independent of the funder. The funder had no input into the study design or analysis, nor the interpretation of data.

Competing interests: All authors have completed the ICMJE uniform disclosure form at www.icmje.org/coi_disclosure.pdf (available on request from the corresponding author) and declare: support from Discovery Channel and Brando Quilici productions and the Landesgraduierten-Förderung Tübingen for the submitted work; no financial relationships with any companies that might have an interest in the submitted work in the previous three years; no other relationships or activities that could appear to have influenced the submitted work.

Data sharing: No additional data available.

- Breasted JH. Ancient records of Egypt: historical documents from the earliest times to the Persian conquest, vol IV—the twentieth to the twenty-sixth dynasties. University of Chicago Press, 1906.
- Redford S. The harem conspiracy: the murder of Ramesses III. Northern Illinois University Press, 2002.
- Brier B. The mystery of unknown man E. *Archaeology* 2006;59:36-42.
- Smith GE. The royal mummies. Catalogue général des antiquités égyptiennes du Musée du Caire. Imprimerie de L'institut Français D'archéologie Orientale, 1912.
- Maspero G. Les momies royales de Deir el-Bahari. Mémoires de la Mission Archéologique Française au Caire. Institut Français d'Archéologie Orientale Cairo, 1889.
- Hawass Z, Gad YZ, Ismail S, Khairat R, Fathalla D, Hasan N, et al. Ancestry and pathology in King Tutankhamun's family. *JAMA* 2010;303:638-47.
- Hofreiter M, Serre D, Poinar HN, Kuch M, Pääbo S. Ancient DNA. *Nat Rev Genet* 2001;2:353-9.
- Roberts C, Ingham S. Using ancient DNA analysis in paleopathology: a critical analysis of published papers, with recommendations for future work. *Int J Osteoarcheol* 2008;18:600-13.
- Athey TW. Haplogroup prediction from Y-STR values using a bayesian-allele-frequency approach. *J Gen Geneal* 2006;2:34-9.
- Shaw I, Nicholson P. British Dictionary of Ancient Egypt. American University in Cairo Press, 1995: 133-4.
- Iskander Z. Mummification in ancient Egypt: development, history, and techniques. In: Harris JE, Wente EF, eds. An x-ray atlas of the royal mummies. University of Chicago Press, 1980.
- Herodotus. The histories [Translated by R Waterfield]. Oxford University Press, 2008.
- Forbes RJ. Studies in ancient technology: 1. Brill, 1964.
- Aghayev E, Thali MJ, Sonnenschein M, Hurlmann J, Jackowski C, Kilchoer T, et al. Fatal steamer accident; blunt force injuries and drowning in post-mortem MSCT and MRI. *Forensic Sci Int* 2005;152:65-71.
- Maspero G. Procès-verbal de l'ouverture des momies de Ramsès II et Ramsès III. In: Comptes-rendus des séances de l'Académie des Inscriptions et Belles-Lettres. 30e année, no 2, 1886:294-301.
- Nerlich AG, Zink A, Szeimies U, Hagedorn HG. Ancient Egyptian prosthesis of the big toe. *Lancet* 2000;356:2176-9.
- Suárez-Peñaranda JM, Alvarez T, Miguéns X, Rodríguez-Calvo MS, de Abajo BL, Cortesão M, et al. Characterization of lesions in hanging deaths. *J Forensic Sci* 2008;53:720-3.

Accepted: 12 November 2012

Cite this as: *BMJ* 2012;345:e8268

© BMJ Publishing Group Ltd 2012

Tables

Table 1 | Genetic kinship analysis

Sample	Y chromosomal data															
	DYS 448	DYS 438	DYS 437	YGATAH4	DYS 392	DYS 635	DYS 439	DYS 391	DYS 393	DYS 385a,b	DYS 19	DYS 458	DYS 389II	DYS 390	DYS 389I	DYS 456
Ramesses III	20	10	14	13	17	—	—	8	8	20	19	—	33	21	13	13
Unknown man E	20	10	14	13	17	—	—	8	8	20	19	—	33	21	13	13
Controls*																
Control DNA 007	19	12	15	13	13	24	12	11	13	11,14	15	17	29	24	13	15
Staff 1	19	12	15	12	13	23	12	11	12	11	14	15	29	24	13	16
Staff 2	19	11	14	11	11	25	12	10	12	13	13	19	27	24	11	14
Staff 3	19	12	15	12	13	23	12	11	12	11	14	15	29	24	13	16

DYS=DNA Y chromosome short tandem repeats (repeating DNA sequences of 4-5 base pairs). Data are number of repetitions of each short sequence; overall, they represent a Y chromosomal genetic fingerprint that can be used to test the paternal relation of Ramesses III and unknown man E and moreover predict the Y chromosomal haplogroup.

*Data from control DNA (provided with chemicals for DNA analysis; refers to an unknown European sample) and male staff members also supplied for comparison.

Table 2| Autosomal microsatellite data analysis

Sample	Autosomal marker							
	D13S317	D7S820	D2S1338	D21S11	D16S539	D18S51	CSF1PO	FGA
Ramesses III	9*; 12	6*; 15	15; 28*	28; 35*	8*; 11	8; 12*	7*; 10*	24*; 34.2
Unknown man E	9*; 13	6*; 13	19; 28*	29.2; 35*	8*; 12	12*; 26	7*; 10*	24*; 26

Data are number of repetitions of each short DNA sequence at autosomal marker, per chromosome; overall, they represent genetic fingerprints of Ramesses III and unknown man E. The markers can be used to test a possible family relationship between the two mummies.

*Matching number of repeats at each autosomal marker, between Ramesses III and unknown man E.

Figures

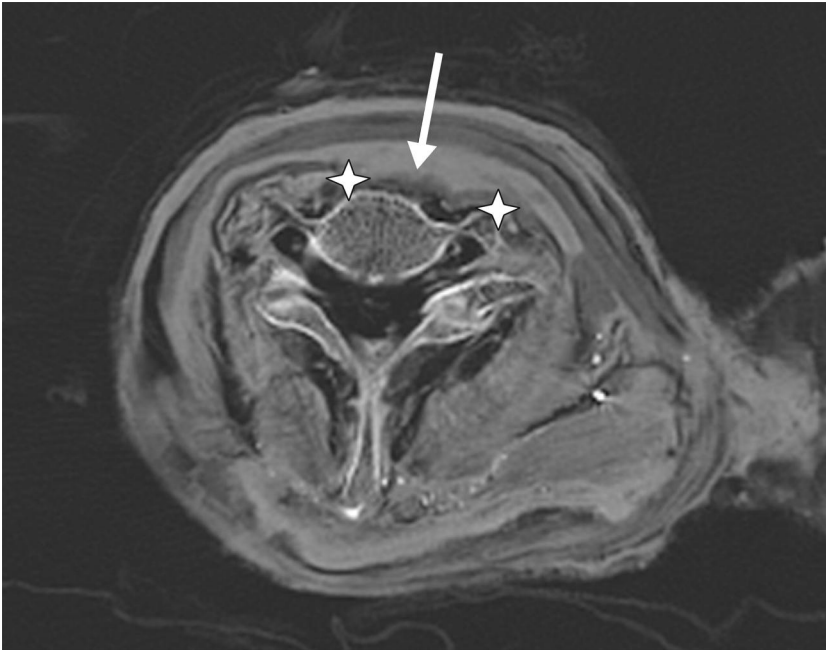


Fig 1 Axial CT section image of the neck of Ramesses III. Stars=wound margins. Arrow=homogenous embalming material seeping into wound and bone

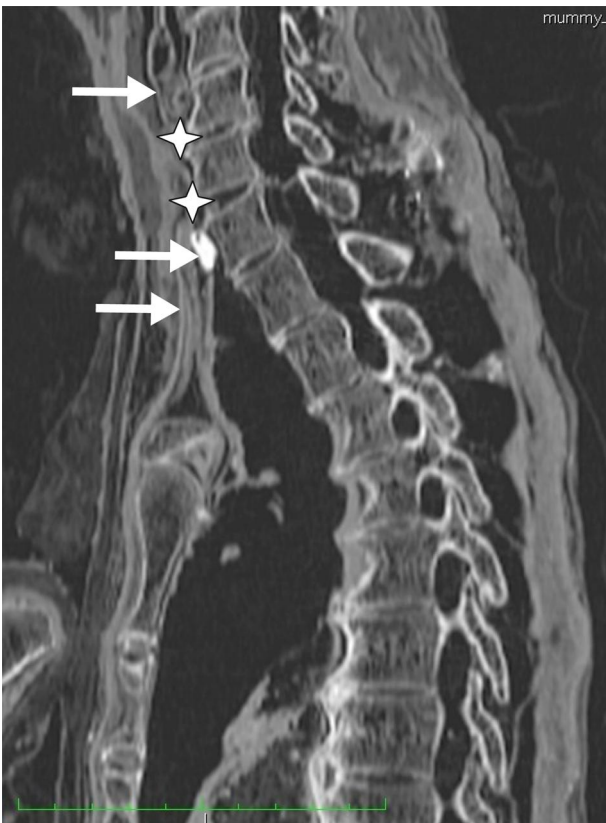

Fig 2 Sagittal CT section image of the neck of Ramesses III. Arrow=foreign object. Stars=wound margins; embalming material has seeped into wound and bone. Triangles=skin above and below the wound.

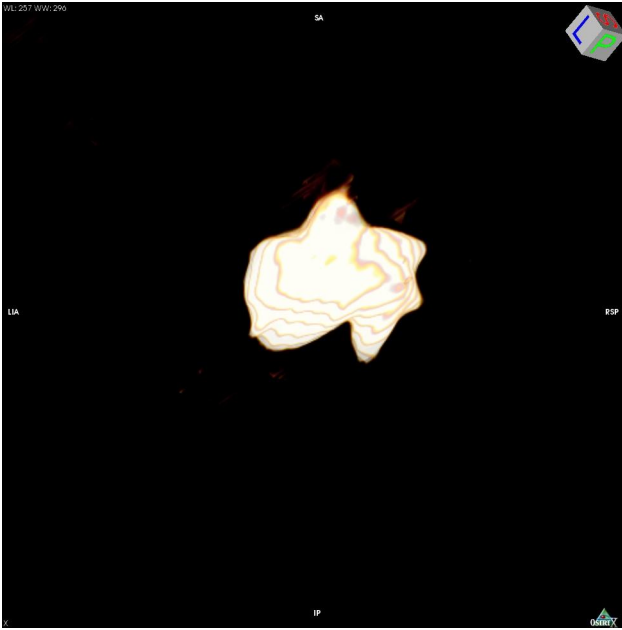


Fig 3 Three dimensional reconstruction of Horus eye amulet




Fig 4 Neck region of unknown man E. Arrows=skin folds and wrinkles under right mandible and neck region

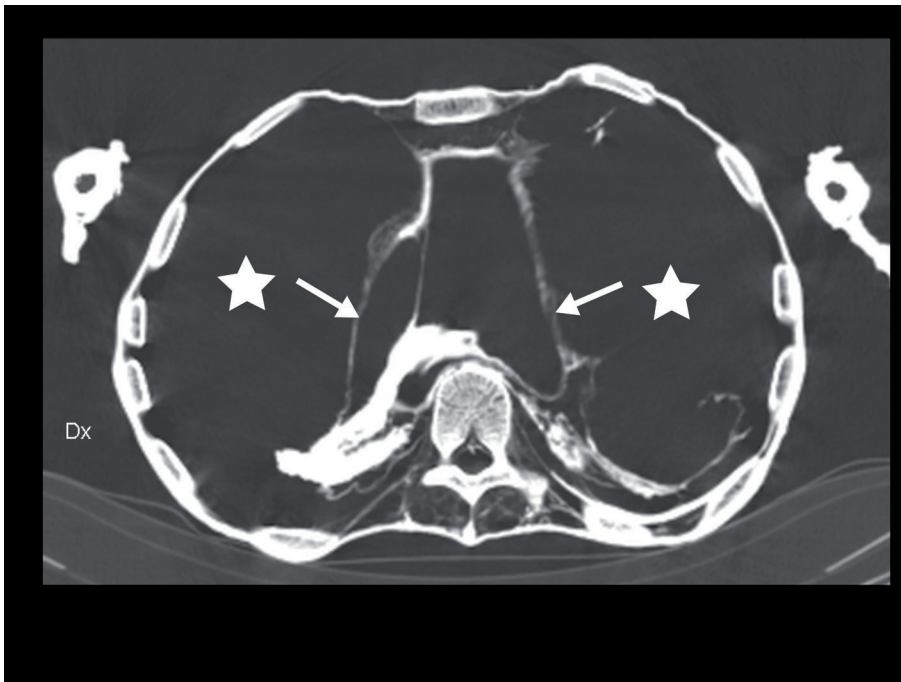

Fig 5 Axial CT image of the lower thoracic region of unknown man E. Thorax is filled with air (stars) and appears to be inflated. Residue in the diaphragm and organs (arrows) are present at the dorsal site

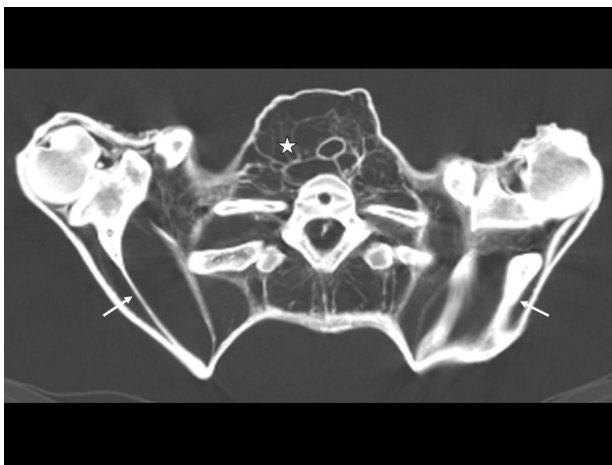


Fig 6 Axial CT image of the lower neck region and shoulder joints of unknown man E. Scapulae are shifted to the lateral side (arrows), and soft tissues are inflated because of gas formation (star)



Fig 7 Mummy of Ramesses III