

LATENT BACTERIAL INFECTION OF JOINTS AND THEIR CLINICAL IMPORTANCE

H.G. Fassbender

Zentrum für Rheuma-Pathologie, WHO Centre, Mainz, Germany

The pathologic diagnosis of bacterial infection (BA) is based on the presence of the following clear morphological features in the joint tissue: 1) laminated fibrin masses, which are permeated predominantly with a lot of neutrophils; and 2) infiltration of the synovial membrane by bacterial toxins and proteases of neutrophils, enzymatic degradation of the synovial structure, and subsequent formation of granulation and scar tissue. In addition, there are some further characteristics that develop as a consequence of the bacterial process.

On comparing these clear morphological findings with the clinical symptomatology and subsequent diagnosis provided by arthroscopic biopsy, it seems to us that there is a major discrepancy between the morphological processes and clinical symptomatology.

Thus, in 7210 joint biopsies obtained from patients with unspecific joint pains during the last 12 years we found 375 cases with morphological features of a clear active or regressing BA. However, only in 34 (9.07%) of these patients had the possibility of BA been considered by the referring clinic. In none of the remaining 341 cases was BA suggested; many were merely diagnosed as “unspecific rheumatic pain” as an indication for arthroscopic biopsy. None of the 375 patients had been treated with antibiotics. Bacterial infections that are clinically undetected are quite evenly spread across all age groups, with only a slight increment at old age. In detail, the age-related distribution is as follows: 0-10 years 7.3%, 11-20 years 10.3%, 21-30 years 13.7%, 31-40 years 12%, 41-50 years 17%, 51-60 years 18.8%, and over 60 years 20.8%.

We have termed this clinically undetected disease process “clinically latent bacterial arthritis” (CLBA). This CLBA largely corresponds to what clinicians have pragmatically termed “low-grade infection”.

The fact that a majority of these cases of CLBA observed were already regressed at the time of biopsy pro-

vides evidence for the self-limiting character of the process.

To summarize: without biopsy examination, this CLBA would not have been detected; and the fact that CLBA made up approximately 5% of the cases in our unselected biopsy material shows that this disease process is by no means rare!

It might be concluded from this clinically undramatic self-limiting course of CLBA that it is harmless. Our examinations show, however, the opposite, as we find severe damage of the joint cartilage and synovial membrane depending on the age and type of the process.

Because of the term “septic arthritis” there is a danger for patients that if the full picture of a sepsis is not present the physician may await for a clinically distinctive symptomatology to indicate the bacterial character of the joint disease process. In other words, if the doctor makes his antibiotic intervention dependent on clear symptoms of a bacterial joint process, he may overlook CLBA with the risk of considerable joint damage.

Thus, three different types of BA must be distinguished: 1) “true” septic arthritis with systemic indications of bacteremia, which is treated as a clinical emergency; 2) clinically manifested BA, but without systemic “septic” signs; nevertheless, the local process needs antibiotic intervention; and 3) relatively frequent CLBA, as we observed, with no typical symptoms, which is also self-limiting without antibiotics.

The clinical significance and prognosis of the 3 types are different: in type 1, there is the risk of systemic metastases of the infective agent principally into the lungs and brain, in some cases with fatal outcome; in type 2 (clinically “low-grade infection”), the purulent bacterial process is limited to the joint and leads to considerable damage, in type 3, it remains similarly limited to the joint. The difference from type 2 is purely quantitative, i.e. accord-

ing to our observations only a part of the synovial membrane is involved in the purulent bacterial process. This is the explanation for the relatively discrete, uncharacteristic symptomatology and its self-limiting nature. However, this process may also damage the joint.

The fact that in this CLBA bacterial infection is not suspected explains why the physician in charge in general does not order bacteriologic examination. In those cases, however, in which bacterial culture is routinely done on each biopsy, it is found that likewise "classic" BA, in the majority of cultures, *Staphylococcus aureus* or *Staphylococcus epidermidis* is identified.

The obvious idea that CLBA could be induced in the joint by a previous injection or other operative manipulation is refuted by the fact that no manipulation of the joint had been undertaken in any of the 375 cases we examined. We have therefore no doubt that this CLBA is of a hematogenous origin. Evidence for this is the observation that in 30.9% of these cases joint involvement was oligoarticular. According to our present state of knowledge, silent bacteremia is not infrequent. It can occur following minor treatment, endoscopy, and unnoticed trauma, or skin infections, and are in general without effects. In particular, there appears to be no preference of the infective agent to colonize the region of the joint^{1,2}. One may rather suspect that bacteremia may lead to infection in other body tissues, there also being silent, self-limiting, and showing no characteristic symptoms and sequels. By contrast, the synovial membrane, due to its irritability and anatomic location, reacts with exudative inflammation and pain. In some of our CLBA cases, skin infections were found but in most cases there was no evidence of the source of silent bacteremia.

Like in "classic" BA, in the above-mentioned 341 cases of CLBA we also found knee joint to be involved in the majority of cases (n=235; 68.9%), followed by the joints of the hand, ankle, finger, elbow, hip, shoulder, toe, and sternoclavicular joint in descending order of frequency.

In 341 patients with CLBA ("low-grade infection"), which had not been considered by the clinic to be BA, we additionally determined the following symptoms: low pain on loading and on movement of the joint involved in 67.4%, effusion in 45.7%, low swelling in 46.3%, and low pain at rest in 31.6% of cases. Redness was apparent in only 5.5% and heat in 2.9% of cases. In the majority of patients, only one of the classic phenomena of inflammation may be present.

It is interesting to compare these 341 cases with 34 patients in whom BA was provisionally diagnosed. In the latter, the symptomatology had no clear definition either; it depended more on whether or not the physician associated the case with a scanty symptomatology possibly being BA. In this type of BA, the parameters indicative of inflammation are frequently not helpful. The erythrocyte sedimentation rate can be between 6-140 mm *per* hour. Due to the relatively small numbers of causative agents, their detection is only possible during a short period of time. The provisional clinical diagnosis in 341 patients with CLBA was unspecific monoarthritis in 48.3%, rheumatoid arthritis (RA) in 17.6%, and unspecific oligoarthritis in 8.8% of cases. In the remaining 25.3% of cases, osteoarthritis (OA), psoriatic arthritis (PSA), juvenile chronic arthritis (JCA), villo-nodular synovitis (VNS), reactive arthritis (REA), urate gout, and Lyme arthritis were suggested. There were no suspicions of a bacterial infection: in other words, in these cases the diagnosis of BA depended on the objective morphological signs of bacterial processes.

References

1. GOLDENBERG DL, REED JI. Bacterial arthritis. *N Engl J Med* 1985;21:764-71.
2. ESTERHAI JL Jr, GELB I. Adult septic arthritis. *Orthop Clin North Am* 1991;22:503-14.

PATHOHISTOLOGIC STUDY ON MUCOSAL MORPHOLOGY OF CHRONIC MAXILLARY SINUSITIS

Petar Drviš¹, Hrvoje Čupić², Tomislav Baudoin¹, Livije Kalogjera¹, Mirko Ivkić¹, Dražen Shejbal¹

¹University Department of ENT, Head and Neck Surgery, and ²University Department of Pathology, Sestre milosrdnice University Hospital, Zagreb, Croatia

SUMMARY – The aim of the study was to evaluate morphological changes of maxillary sinus mucosa and to compare them with the levels of tryptase, myeloperoxidase (MPO) and eosinophil cationic protein (ECP) in sinus lavage, and also with subjective outcomes in patients with chronic rhinosinusitis after endosinusal treatment. Thirty patients with the symptoms of chronic rhinosinusitis were recruited for the study. Inclusion criteria were sinusitis symptoms persisting for more than 3 months and maxillary sinus mucosa thickening by >6 mm, considered as maxillary sinusitis. Patients with asthma, polyposis, recent infection, systemic steroid therapy or previous sinus surgery were excluded. Patients were treated endosinually with 2 mg dexamethasone and 40 mg gentamicin *per* maxillary sinus daily for 5 days. Patients rated their nasal/chronic rhinosinusitis disease-specific symptoms and completed a self-administered questionnaire concerning sinusitis symptoms at inclusion and after 30 days. Sinus lavage with 5 ccm of saline was obtained prior to the first endosinusal treatment. Tryptase, MPO and ECP were determined from lavage fluid. Biopsy specimens of maxillary sinus mucosa were obtained by biopsy forceps during sinusoscopy through the inferior meatus in local anesthesia. Fifteen (50%) patients showed improvement and symptom alleviation after the treatment (responders), and 15 (50%) were unchanged or worsened (IR <1) after the treatment (nonresponders). The pretreatment and post-treatment sinusitis symptom scores and improvement rate of sinusitis symptom scores showed no correlation with any of the histologic parameters. Significant improvement was noted for the overall sinusitis symptoms score ($p < 0.01$) in the study group as a whole. There was a significant difference in the baseline levels of MPO and ECP in sinus lavage ($p < 0.01$), and a difference in the number of mononuclears and eosinophils in biopsy specimens of maxillary sinus mucosa ($p > 0.05$) between the responders and nonresponders. Responders had a higher level of MPO and ECP in sinus lavage and higher number of mononuclears and eosinophils in biopsy specimens of maxillary sinus mucosa than nonresponders. There was no statistical difference in tryptase and other histologic parameters (number of mononuclears, edema, fibrosis, seromucous glands and goblet cell density) between responders or nonresponders. Eosinophilia in maxillary sinus mucosa specimens showed close correlation with ECP level in sinus lavage and inverse correlation with fibrosis ($p < 0.05$). Other inflammatory cells (mononuclears and neutrophils) in maxillary sinus mucosa specimens did not correlate with the level of any cytokine in sinus lavage or with other histologic parameters. Goblet cell density correlated with ECP level ($p < 0.05$) and inversely with MPO level in sinus lavage ($p < 0.01$). Fibrosis showed close correlation with tryptase ($p < 0.01$) and MPO ($p < 0.05$) levels in sinus lavage and inversely with edema ($p < 0.01$). Study results indicated higher levels of MPO and ECP in sinus lavage and higher number of mononuclears and eosinophils in biopsy specimens of maxillary sinus mucosa to predict better response to endosinusal steroid/antibiotic treatment.

Key words: *chronic rhinosinusitis, endosinusal treatment, cytokines, sinus mucosa, histology*

Correspondence to:
 Petar Drviš, M.D., University Department of ENT, Head and Neck Surgery, Sestre milosrdnice University Hospital, Vinogradska c. 29, HR-10000 Zagreb, Croatia
 E-mail: petar100@vip.hr

Introduction

Chronic rhinosinusitis (CRS) is one of the most common chronic disorders, with a significant impact on health-related quality of life (HRQL)¹. It is defined by its subjective signs, i.e. the intensity and duration of the characteristic symptoms that include postnasal drip, nasal obstruction and discharge, facial pressure or pain, headache, cough, and olfactory disorders lasting for more than 12 weeks. The severity of objective findings used for the diagnosis and staging of CRS (x-ray, sinus CT scans, bacteriology, inflammatory mediators) does not correlate with the subjective symptoms scores, but some of objective signs have been reported to be valuable predictors of poor longterm outcomes following conservative or surgical treatment². Evaluation of different conservative CRS treatment modalities in randomized controlled trials has indicated a limited value of non-surgical treatment for acceptable long-term outcomes. Medications usually recommended for CRS management are combinations of longterm antibiotics, topical nasal steroids, hypertonic or saline nasal douches, and short-term nasal decongestants. A wide range of surgical procedures have been used to treat this condition, from simple sinus puncture to functional endoscopic sinus surgery. In some studies, up to 50% of allergic patients with CRS did not improve after surgery^{2,3}. Maxillary antrostomy through the inferior meatus is a minor but common otolaryngologic procedure, usually followed by irrigation and topical application of the drug into the maxillary sinus⁴, performed in local anesthesia. Simple sinus irrigation combined with oral antibiotics prevented sinus surgery in more than a half of CRS patients⁵.

The maxillary sinus mucosa is thinner and less specialized than that found in the nasal cavity, and contains fewer goblet cells. The surface is covered by a single layer of pseudostratified ciliated columnar epithelium, and the basement membrane is delicate. The lamina propria is rather thin and composed of a superficial loose connective tissue layer and deep compact layer, which fuses with the underlying periosteum to form a dense periosteal layer, the mucoperiosteum. Mucosal glands are only found in the region of the ostia. The mucosa from patients with recurrent sinusitis shows an increase in goblet cell density, thickening of basement membrane, pathologic glands and polypoid formations, edema and variable presence of inflammatory cells in lamina propria. Tissue eosinophilia is a prominent feature of both allergic and nonallergic CRS⁶. The mucosa in chronic sinusitis shows hyperplasia and hyperactivity of the seromucous glands⁷. The nature of

effusion is not reflected in any specific histologic pattern of the mucosa⁸. The thickness of the antral mucosa correlates with the quantity of inflammatory cells⁹.

Some of the cells involved in the CRS inflammation release specific mediators. Eosinophils release eosinophil cationic protein (ECP), mast cells release histamine and tryptase, and neutrophils release myeloperoxidase (MPO), which is released during phagocytosis or cell activation. Characterization of the inflammation was investigated in this study by morphological examination of the maxillary sinus mucosa and measurement of cytokine levels in sinus lavage.

Material and Methods

Thirty patients with CRS symptoms were recruited for the study. All patients gave their informed consent and the study was approved by the Ethics Committee of the Sestre milosrdnice University Hospital, Zagreb, Croatia. Inclusion criteria were sinusitis symptoms lasting for more than three months and mucosal thickening of the maxillary sinus mucosa by more than 6 mm (x-ray Waters projection or ultrasound image), considered as maxillary sinusitis. Exclusion criteria were bronchial asthma, nasal polyposis, recent upper respiratory infection, systemic steroid therapy, any systemic disease or previous sinus surgery.

Biopsy specimens of maxillary sinus mucosa were obtained by biopsy forceps during antral sinusoscopy through the inferior meatus in local anesthesia. The specimens were immediately fixed for 24 hours in buffered 10% formalin, and embedded in paraffin wax; paraffin sections were stained with hematoxylin-eosin and examined histologically at the Department of Pathology, Sestre milosrdnice University Hospital, Zagreb, Croatia. Histologic changes were recorded by an independent pathologist without any clinical information. Semiquantitative grading (0, 1, 2 and 3) was based on the following variables: number of inflammatory cells (neutrophils, mononuclears and eosinophils), edema, fibrosis, seromucous glands and goblet cell density. Sinus lavage with 5 ccm of saline was obtained prior to the first endosinusal treatment. Samples were stored at room temperature for 2 hours, centrifuged at 1000 xg for 10 minutes, and placed in a refrigerator at -20 °C. Tryptase and ECP were determined by fluoroenzymeimmunoassay (UniCAP, Pharmacia&Upjohn, Uppsala, Sweden), and MPO by radioimmunoassay (Pharmacia, Sweden).

Patients were treated with 2 mg dexamethasone and 40 mg gentamicin *per* maxillary sinus/day (according to

Croatian guidelines for treatment of sinusitis), applied through a polyethylene anastomosis tube. During the 5-day treatment period, the patients did not receive any additional antibiotic or antiallergic treatment. Patients rated their nasal/CRS disease-specific symptoms and completed a self-administered questionnaire concerning major (obstruction, postnasal drip, headache, discharge, sneezing) and minor (facial swelling, cough, nasal itching, olfaction or taste disturbances) sinusitis symptoms before the intervention and at one month follow-up. Outcome was assessed in each patient by a questionnaire in which the patient rated different symptoms 0 – 3 according to intensity and frequency¹⁰. Sinusitis symptom scores are presented as mean value of 10 symptom scores¹¹. Improvement rate of the sinusitis symptoms score (symptomatic improvement rate) was calculated as a difference between the pretreatment and post-treatment sinusitis symptom scores. Patients were categorized as responders or nonresponders according to the severity of nasal symptom scores before and one month after the treatment. The improvement rate of sinusitis symptom scores was calculated as a difference between the pretreatment and post-treatment scores. Patients who showed symptom alleviation after the treatment and improvement rate more than 1 (IR > 1) were categorized as responders.

Statistical analysis was performed with the use of Smirnov-Kolmogorov test followed by Wilcoxon Signed Rank test for comparison of the sinusitis symptom scores. Comparison between responders and nonresponders was done by use of Student's unpaired t-test for cytokine levels, and by Mann-Whitney U test for sinusitis symptom scores. Correlations were calculated with Spearman rank correlation coefficient. All conclusions were based on a significance level of $p < 0.05$.

Results

Fifteen (50%) patients showed improvement and symptom alleviation after the treatment (responders), and 15 (50%) were unchanged or worsened (IR < 1) after the treatment (nonresponders). Pretreatment and post-treatment sinusitis symptom scores and improvement rate of sinusitis symptom scores did not correlate with any of the histologic parameters. Significant improvement was recorded for overall sinusitis symptom score ($p < 0.01$) in the study group as a whole.

There was a significant difference in the baseline levels of MPO and ECP in sinus lavage ($p < 0.01$) and a difference in the number of mononuclears and eosinophils in

biopsy specimens of maxillary sinus mucosa ($p > 0.05$) between responders and nonresponders. Responders had higher levels of MPO and ECP in sinus lavage and a greater number of mononuclears and eosinophils in biopsy specimens of maxillary sinus mucosa than nonresponders. There was no statistical difference in tryptase and other histologic parameters (number of mononuclears, edema, fibrosis, seromucous glands and goblet cell density) between responders and nonresponders.

Eosinophilia in maxillary sinus mucosa specimens showed close correlation with ECP level in sinus lavage and inverse correlation with fibrosis ($p < 0.05$). Other inflammatory cells (mononuclears and neutrophils) in maxillary sinus mucosa specimens did not correlate with the level of any cellular marker in sinus lavage or any other histologic parameter. Goblet cell density showed positive correlation with ECP level ($p < 0.05$) and inverse correlation with MPO level in sinus lavage ($p < 0.01$). Fibrosis correlated closely with tryptase ($p < 0.01$) and MPO ($p < 0.05$) levels in sinus lavage, and inversely with edema ($p < 0.01$).

Discussion

This study was undertaken to evaluate the morphological changes of maxillary sinus mucosa, and to compare them with the levels of particular cellular markers in sinus lavage and subjective outcomes in patients with chronic rhinosinusitis after endosinus treatment.

CRS can be studied by different methods. Biopsy of maxillary sinus mucosa directly identifies inflammatory cells and mucosal damage but usually gives little information on the state of cell activation, cannot provide quantitative results, and does not distinguish the possible heterogeneity of mucosal lesions. Hence, in this study we used sinus lavage because it indirectly identifies the degree of sinus inflammation by the measurement of mediators.

Eosinophilia in maxillary sinus mucosa specimens closely correlated with ECP level in sinus lavage ($p > 0.05$). Other inflammatory cells (mononuclears and neutrophils) in maxillary sinus mucosa specimens did not correlate with any cellular marker level in sinus lavage. It is indicative because mediators in sinus lavage fluid may be considered as markers of the specific cell activity. Increased fibrosis, which closely correlated with tryptase and MPO, may be attributed to the higher activity of inflammatory cells. Pretreatment and post-treatment sinusitis symptom scores and improvement rate of sinusitis symptom scores did not correlate with any of the histologic parameters. The absence of correlation is not surprising, since chronic rhinosinusitis has a multifactorial pathogenesis.

Corticosteroids effectively inhibit the production of a number of proallergic mediators¹². There is a significant reduction in the eosinophil and mast cell activation markers in sinus fluid and in subjective sinusitis symptom scores following endosinusal treatment^{13,14}, and this effect may also contribute to the beneficial effects of topical steroid treatment of sinus mucosa in chronic sinusitis patients. Interestingly, although surgical management of CRS has been reported to improve subjective scores better than conservative treatment, patients with poor outcomes after surgery have been found to demonstrate at least a 50% improvement rate due to perioperative or postoperative topical or systemic steroid or longterm macrolide treatment. In this study, the 5-day steroid/antibiotic endosinusal treatment in patients with CRS proved effective in reducing subjective sinusitis symptoms and improving HRQL.

Conclusion

The steroid-antibiotic endosinusal treatment in patients with CRS proved effective in reducing subjective sinusitis symptoms. Study results indicated the higher levels of MPO and ECP in sinus lavage, and greater number of mononuclears and eosinophils in biopsy specimens of maxillary sinus mucosa to predict better response to endosinusal steroid/antibiotic treatment.

References

1. GLIKLICH RE, METSON R. The health impact of chronic sinusitis in patients seeking otolaryngologic care. *Otolaryngol Head Neck Surg* 1995;113:104-9.
2. LAVIGNE F, NGUYEN CT, CAMERON L, HAMID Q, RENZI PM. Prognosis and prediction of response to surgery in allergic patients with chronic sinusitis. *J Allergy Clin Immunol* 2000;105:746-51.
3. LAVIGNE F, CAMERON L, RENZI PM, PLANET JF, CHRISTODOULOPOULOS P, LAMKIOUED B, HAMID Q. Intranasal administration of topical budesonide to allergic patients with chronic rhinosinusitis following surgery. *Laryngoscope* 2002;112:858-64.
4. QVARNBERG Y, KANTOLA O, SALO J, TOIVANEN M, VALTONEN H, VUORI E. Influence of topical steroid treatment on maxillary sinusitis. *Rhinology* 1992;30:103-12.
5. HARTOG B, van BENTHEM PP, PRINS LC, HORDIJK GJ. Efficacy of sinus irrigation *versus* sinus irrigation followed by functional endoscopic sinus surgery. *Ann Otol Rhinol Laryngol* 1997;106:759-66.
6. MOESNER J, ILLUM P, JEPPESEN F. Sinoscopic biopsy in maxillary sinusitis. *Acta Otolaryngol* 1974;78:113-7.
7. TOS M, MOGENSEN C. Mucus production in chronic maxillary sinusitis. A quantitative histopathological study. *Acta Otolaryngol* 1984;97:151-9.
8. STIERNAP, CARLSOÖ B. Histopathological observations in chronic maxillary sinusitis. *Acta Otolaryngol* 1990;110:450-8.
9. FORSGREN K, FUKAMI M, PENTTILA M, KUMLIEN J, STIERNAP. Endoscopic and Caldwell-Luc approaches in chronic maxillary sinusitis: a comparative histopathologic study on preoperative and postoperative mucosal morphology. *Ann Otol Rhinol Laryngol* 1995;104:350-7.
10. GLIKLICH RE, METSON R. Techniques for outcomes research in chronic sinusitis. *Laryngoscope* 1995;105(4 Pt 1):387-90.
11. BENNINGER MS, SENIOR BA. The development of the Rhinosinusitis Disability Index. *Arch Otolaryngol Head Neck Surg* 1997;123:1175-9.
12. WALLWORK B, COMAN W, FERON F, MACKAY-SIM A, CERVINA A. Clarithromycin and prednisolone inhibit cytokine production in chronic rhinosinusitis. *Laryngoscope* 2002;112:1827-30.
13. KALOGJERA L, VAGIC D, BAUDOIN T. Effect of endosinusal treatment on cellular markers in mild and moderate asthmatics. *Acta Otolaryngol* 2003;123:310-3.
14. KONDO H, NACHTIGAL D, FRENKIEL S, SCHOTMAN E, HAMID Q. Effect of steroids on nasal inflammatory cells and cytokine profile. *Laryngoscope* 1999;109:91-7.

OTOCEPHALY – A CASE REPORT

Marina Kos

Ljudevit Jurak University Department of Pathology, Sestre milosrdnice University Hospital, Zagreb, Croatia

SUMMARY – Otocephaly is a rare congenital malformation of the head and neck caused by maldevelopment of the 1st and 2nd pharyngeal arches. It is characterized by absence of the mandible and approximation of the ears in the midline region normally occupied by the mandible. Pathomorphological features of an infant with otocephaly born during 33rd week of gestation, which died immediately after birth because of the oral cavity atresia, are described. The infant was born from the first (poorly controlled) pregnancy in healthy parents. The putative causative factors of this malformation are briefly discussed.

Key words: *otocephaly, morphology*

Introduction

Developmental field is a portion of the embryo that reacts as a coordinated unit to the inductive effects of growth and differentiation. A monotopic field defect includes contiguous anomalies (e.g., cyclopia and holoprosencephaly or cleft lip and cleft palate). A polytopic field defect occurs if inductive processes produce more distantly located defects (e.g., in acrorenal field defect where the lack of interference with the inductive effect of the mesonephros causes defective limb-bud cartilage proliferation and differentiation).

Otocephaly is a causally heterogeneous, single developmental field defect that affects structures in the face and upper neck. Characteristic features are absence of the mandible and approximation of the ears in the midline region normally occupied by the mandible.

Case report

A 17-year-old woman was admitted to the University Department of Gynecology and Obstetrics, Sestre milosrdnice University Hospital, at 32+5 weeks of gestation for the onset of labor. It was her first pregnancy, controlled ir-

regularly elsewhere. She reported ultrasound examination on two occasions (presumably normal, she had no documentation). She had her first period at the age of 11, menstrual cycles were normal, her medical history was unremarkable except for smallpox and measles in infancy. Her blood group was 0 (Rh+). The father of the child was aged 22, healthy, blood group 0 (Rh unknown). On admission, she had labors at 2-3/10 min apart, fetal heart action was absent, her blood pressure was 130/80 mm Hg. The cervix had disappeared, it was 8-10 cm in diameter, and fetal head at the entrance of the pelvis. Amniotomy was performed to drain 6 L of yellowish-green amniotic fluid. Soon thereafter, she gave birth to a malformed male child, birth weight 1640 g, birth length 43 cm, and APGAR score 1/0. Intubation was attempted, at first through the nose, then through the mouth, but unsuccessfully. The child died after 5 min. The child and the placenta were referred for pathologic examination. The placenta weighed 460 g (measuring 21:15:2 cm), umbilical cord inserted laterally. Histologically, foci of neutrophils and hemorrhage were found in the membranous layer of the decidua, and the diagnosis of focal membranous chorioamnionitis with hemorrhage was made. Most chorionic villi were normal for gestational age, some of them showing features of immaturity. Gross examination revealed extreme microstomia and micrognathia, together with ventrally displaced external ears (Fig. 1). Radiograms showed no signs of the mandible. Autopsy showed blind ending oral cavity, bilateral cleft palate all the way to the uvula that was also cleft in

Correspondence to: *Assist. Prof. Marina Kos, M.D., Ph.D.*, Ljudevit Jurak University Department of Clinical Pathology, Sestre milosrdnice University Hospital, Vinogradska c. 29, HR-10000 Zagreb, Croatia
e-mail: dr_marina_kos@yahoo.com

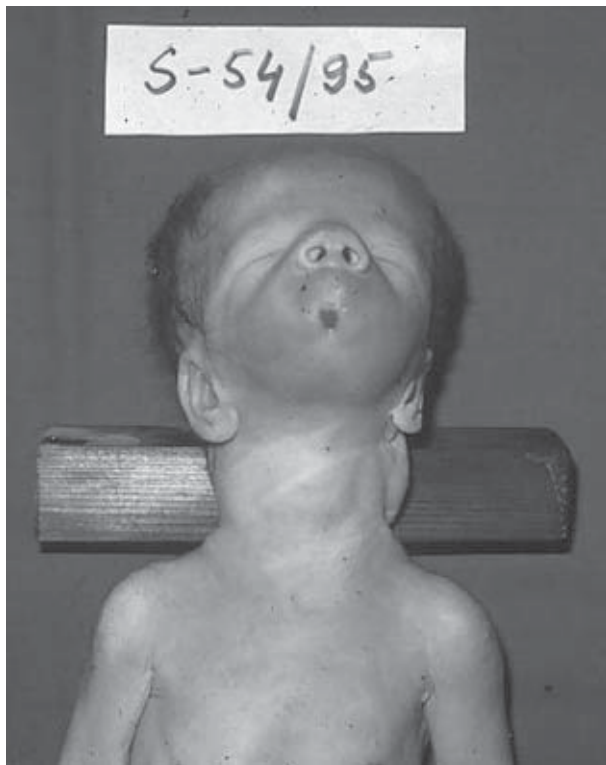


Figure 1. Gross appearance of the head and neck in otocephaly. Earlobes are localized low and towards the midline because of the mandibular agenesis. The mouth are only few milimeters in diameter

involved. There was no communication with the skull base. The pharynx was completely separated from the pouch of the oral cavity, also ending blindly on the cranial side, with a small tissue nodule dorsally, resembling abortive tongue. At serial cuts, immediately under the nodule, a calcified structure, probably hyoid bone, was found. The esophagus and trachea were patent, the lungs compact, purple. All other organs of the body as well as the brain were normal. Histology revealed three muscle bundles at the location of the tissue nodule (tongue tissue) covered with multilayered squamous epithelium and salivary gland tissue underneath. The thyroid gland and the thymus were normal for gestational age, and so were all other organs (the lungs were atelectatic and flooded with blood, and there was also hemorrhage in both adrenals, small hemorrhages in the epicardium, and generalized cyanosis). On interview after a couple of days, the mother definitely denied any infection she was aware of during the first months of pregnancy, or taking any medicine except for several glasses of the Cedevita vitamin drink. She also denied knowing of any cases of malformation in her or her husband's families.

Discussion

Otocephaly is the result of maldevelopment of the 1st and 2nd pharyngeal arches. Every pharyngeal arch contains a core of cartilage derived from neural crest cells, unsegmented mesoderm capable of forming striated muscle and bone, an artery that runs from the aortic sac to the dorsal aorta on the same side, and a nerve that enters it from the brain stem carrying motor fibers for the supply of striated muscles developing from the unsegmented mesoderm^{1,2}. The cause of otocephaly has been related to defects in neural crest cells of cranial origin, or to defects in the underlying mesodermal support elements of these cells³. It is thought that an altered embryologic development might take place at Carnegie stages 10 (embryonic days 22 or 23) and 11 (embryonic days 23-26)^{4,5}. Fetuses with otocephaly may have associated cardiac defects, renal anomalies, bilateral pulmonary agenesis, and esophageal atresia^{6,7}. Most cases occurred sporadically, even though its presence in siblings suggests autosomal recessive inheritance⁷⁻⁹. Most of the patients with this malformation die shortly after birth because of oropharyngeal malformations that prevent spontaneous inhalation as well as intubation and ventilation, however, a patient surviving beyond the perinatal period owing to the support of pediatric intensivists and advanced technology has been described¹⁰. In the case presented, the attempts of intubation were futile because of the complete atresia of the mouth floor. The described malformations correspond to the maldevelopment of the first two pharyngeal arches, because a small swelling was found where the tongue should have been (the primordium of the posterior one third of the tongue originates from the hypopharyngeal eminence belonging to the third and fourth arches). The importance of regular control and ultrasound examinations in this case cannot be stressed enough, because it seems incredible that a malformation was not suspected, if not on the basis of fetal morphology, then on the basis of the enormous polyhydramnion.

References

1. GILBERT-BARNES E, OPITZ JM. Congenital anomalies and malformation syndromes. In: STOCKER JT, DEHNER LP, eds. Pediatric pathology. Philadelphia: JB Lippincott Company, 1992:73-115.
2. FITZGERALD MJT, FITZGERALD M. Human embryology. London-Philadelphia: Bailliere Tindall, 1994.
3. PAULI RM, GRAHAM JM, BARR M Jr. Agnathia, situs inversus and associated malformations. Teratology 1981;23:85-??.

4. SCHIFFER C, TARIVERDIAN G, SCHIESSER M, THOMAS MC, SERGI C. Agnathia-otocephaly complex: report of three cases with involvement of two different Carnegie stages. *Am J Med Genet* 2002;112:203-8.
5. OPITZ JM, ZANNI G, REYNOLDS JF Jr, GILBERT-BARNES E. Defects of blastogenesis. *Am J Med Genet* 2002;115:269-86.
6. DeBUSE PJ, MORRIS G. Bilateral pulmonary agenesis, esophageal atresia and the first arch syndrome. *Thorax* 1973;28:526-??.
7. PAULI RM, PETTERSEN JC, ARYA S, GILBERT EF. Familial agnathia-holoprosencephaly. *Am J Med Genet* 1983;14:677-??.
8. GABA AR, ANDERSEN GJ, Van DYKE DL, CHASON JI. Alobar holoprosencephaly and otocephaly in a female infant with a normal karyotype and placental villitis. *J Med Genet* 1982;19:78-??.
9. MOLLICA F, PAVONE L, NUCIFORO G, SORGE G. A case of cyclopia. Role of environmental factors. *Clin Genet* 1979;16:69-??.
10. SHERMAK MA, DUFRESNE CR. Nonlethal case of otocephaly and its implications for treatment. *J Craniofac Surg* 1996;7:372-5.

Sažetak

OTOCEFALIJA – PRIKAZ SLUČAJA

M. Kos

Otocefalija je rijetka prirođena nakaznost glave i vrata koja nastaje zbog poremetnje razvoja prvog i drugog žrdrijelnog luka. U radu se opisuju patomorfološke osobine djeteta rođenog u 33. tjednu gestacije iz prve (loše kontrolirane) trudnoće mladih i zdravih roditelja, a koje je zbog atrezije usne šupljine i nemogućnosti intubacije umrlo neposredno nakon poroda. Također se ukratko raspravlja o mogućim uzročnim čimbenicima u nastanku ove nakaznosti.

Ključne riječi: *malformacije, glava, morfologija*

A COMMENT ON THE WHO CLASSIFICATION OF SALIVARY GLAND TUMORS

S. Manojlović

Department of Clinical and Experimental Pathology,
Dubrava University Hospital,
Zagreb, Croatia

Salivary gland tumors account for 2% to 6.5% of all head and neck neoplasms. Although infrequent, their histomorphological patterns exhibit extreme variability, making their diagnostic interpretation and classification very burdensome. Salivary gland tumor classification is a dynamic process that has undergone several modifications since the Foote and Frazell's classification formulated in the early 1950s. The revised World Health Organization (WHO) classification from 1991 showed significant modification and expansion from the first WHO classification from 1972. This classification has been used since 1991, and has proved to be the most comprehensive one, having undergone no significant changes in the last WHO working group revision. Despite the sophisticated histologic ramification, there is an agreement on a limited number of pathohistologic characteristics that determine the treatment and outcome of the patient with salivary gland tumor. The most important prognostic factors are: 1) histologic type; 2) TNM staging; 3) anatomic site of origin, and 4) completeness of surgical excision and margin status. There is no standard grading scheme applicable to all types of malignant salivary gland tumors, so histologic type indicates tumor grade. Certain entities are acknowledged as low grade (polymorphous low grade adenocarcinoma, basal cell adenocarcinoma, acinic cell adenocarcinoma) and some as high grade (salivary duct carcinoma, adenocarcinoma NOS, squamous cell carcinoma, undifferentiated carcinoma). Other salivary gland malignancies exhibit a histologic spectrum in which grading is significant and defined for each tumor type. Tumor stage and clinical or/and pathologic signs of local aggressiveness are major predictors of lymph node and distant metastasis, and therefore of outcome as well. Completeness of surgical excision and margin status are very important in both benign and malignant salivary gland tumors. Despite a higher proportion of malignant tumors arising in minor compared with major salivary glands, there is a trend for a more favorable survival for cancers originating in intraoral and oropharyngeal minor salivary glands, with the exception of nasopharyngeal and paranasal sinus malignancies. Recent knowledge in genetics does not influence significantly the current understanding of salivary gland tumorigenesis and its classification.

Immunohistochemistry and ancillary techniques such as flow cytometry and proliferative marker expression have shown limited usefulness in the differential diagnosis of salivary gland tumors. Therefore the current surgical pathology approach to salivary gland tumor diagnosis and characterization is a morphologic one, with appreciation of clinical staging and status of surgical margins.

US GUIDED FNAB IN THE PREOPERATIVE DIAGNOSIS OF PARATHYROID DISEASES

Mira Halbauer

University Department of Nuclear Medicine and Radiation Protection, Zagreb University Hospital Center,
Zagreb, Croatia

Parathyroid lesions are frequently treated as a disease of the thyroid, thus presenting a serious diagnostic problem. In the diagnosis and differential diagnosis of diseases developing as a result of disturbed parathyroid gland functions, it is important to determine the size and localization of abnormal, nonpalpable parathyroid glands, their morphology and microscopic structure. The accuracy of the diagnosis of suspected enlarged parathyroid glands can be improved by a combination of ultrasound examination, ultrasonically guided fine needle aspiration (FNA) biopsy cytology, and analysis of the aspirates for parathyroid hormone. This is very important, since the results thus obtained are decisive in the choice of therapy. Data found in the literature and our own experience have shown high resolution sonography to be the procedure of choice, with its main advantage being the possibility of ultrasound controlled FNA biopsy of the enlarged parathyroid gland for cytologic analysis. The nature of lesions examined by ultrasound can then be confirmed by cytologic examination of the material obtained. The material obtained can also be used for parathyroid hormone determination and sometimes for histologic analysis. Parathyroid cells are identifiable in FNA samples, especially if using specific staining procedures or immunochemistry. Since it is not always possible to differentiate between parathyroid cells and those of follicular thyroid epithelium in Papanheim-stained smears, on the basis of the morphologic appearance alone, an accurate and definitive diagnosis could be made on the basis of cytologic features supported by positive immunostaining for chromogranin or by use of additional cytochemical method such as silver nitrate stain demonstrating argyrophilia in the parathyroid cell cytoplasm. In conclusion, several points should be emphasized: (1) FNA

biopsy cytology has a definite preoperative diagnostic value when ultrasound examination reveals a possible parathyroid enlargement, especially when both routine and specific staining procedures are utilized; (2) this procedure is simple and safe, and has a high diagnostic accuracy in patients with suspected parathyroid gland enlargements; (3) the recognition of cytologic variations is important for identifying a lesion as parathyroid in origin. Therefore, such specimens should be examined by a cytopathologist experienced in recognizing the morphology of endocrine cells.

CHILD ABUSE SYNDROME

M. Marcikić, B. Dumenčić, E. Matuzalem

Department of Pathology and Forensic Medicine,
School of Medicine, Josip Juraj Strossmayer University,
Osijek, Croatia

A major problem in pediatric, social medicine and forensic pathology is the physical, psychological and sexual abuse of children by parents or guardians. Child abuse is pervasive throughout the society. The nationality and social class, appearance and education confer no exception from violence suffered by children. The syndrome is usually discussed in relation to more industrialized countries, however, there is little doubt that it is a universal problem although probably less common in cultures with predominant large communal family units than in urbanized societies with predominant isolated nuclear families. Protecting children from abuse and exploitation is the responsibility of all capable adults. In addition to this general responsibility, doctors have professional duties and responsibilities. The doctor may become professionally involved in three ways: 1) a member of the public may tell the doctor that she/he suspects, or has evidence of, child abuse; 2) a doctor may become suspicious of abuse during the course of his work; and 3) a doctor may be asked by a local authority to help in the investigation of child abuse, e.g., by examining a child suspected of being a victim of abuse.

PROJECT: ALCOHOL-RELATED CANCER AND GENETIC SUSCEPTIBILITY IN EUROPE (ARCAGE)

A. Znaor¹, R. Kušec², M. Virag³, T. Znaor², S. Manojlović³

¹National Institute of Public Health, ²Merkur University Hospital, ³Dubrava University Hospital,

Zagreb, Croatia

Great differences in the incidence of upper aerodigestive tract cancers across Europe cannot be explained by differences in the absolute levels of smoking and alcohol consumption. The International Agency for Research on Cancer has launched a multicenter case-control study of upper aerodigestive tract cancer in 13 centers from 9 European countries, Croatia included. By the end of the recruitment period (December 31, 2004), 5000 cases and 5000 controls should be recruited. The Croatian center (National Institute of Public Health) is expected to recruit 75 cases and 75 controls. The aim of the project is to assess the role of different environmental and genetic risk factors and their interactions in the etiology of upper aerodigestive tract cancer. A 10-ml blood sample and a lifestyle questionnaire are a minimum requirement for all subjects. Genetic polymorphisms will centrally be tested using, for this purpose custom designed, DNA-microarray technology. A common database of lifestyle data will be developed for statistical analysis. In Croatia, 35% of subjects have been recruited so far: 26 oral cancer cases, 5 pharyngeal cancer cases and 21 controls. The cases and controls were recruited from Dubrava University Hospital and Merkur University Hospital, Zagreb. Multicenter international case-control studies with custom designed DNA microarrays provide an opportunity to assess the role of genetic susceptibility as well as of environmental factors in the etiology of cancer. Considering the well established pathologic, oncologic and epidemiologic practices, Croatia can provide a valuable contribution to such studies.

CYTOLOGIC FINDINGS OF EPITHELIOID ANGIOSARCOMA OF THE SCALP – CASE REPORT

E. Garcia-Ureta, B. Sanroman Budiño

Juan Canalejo Hospital, La Coruña, Spain

Angiosarcomas are rare, aggressive tumors of vascular origin, most commonly affecting older males. In this report, cytologic features of a patient with an epithelioid angiosarcoma are presented.

rcoma of the scalp are presented. A wide, hemorrhagic lesion with progressive enlargement occurred three months before on the scalp of a 74-year-old woman who had no history of previous trauma to the region. FNAC was performed with a 23 gauge needle in a standard manner. Smears from the FNAC were stained according to Papanicolaou and MGG techniques. Immunocytochemistry was performed according to standard methods. The antibodies used included keratin, EMA, CD-31, Factor VIII, and CD-34. On cytology, the smears were moderately cellular and very bloody. The cells were present simply or arranged in loose groups and tight aggregates. The cells were pleomorphic, round, oval, polygonal and occasionally spindle. The cytoplasm was abundant, dense, with elongated processes and intracytoplasmic lumina. The nuclei were indented and hyperchromatic, with clumped chromatin and prominent nucleoli. Mitotic figures were observed. Immunocytochemical markers including factor VIII, CD-31 and CD-34 were positive confirming the vascular nature of the neoplasm. Based on these cytologic features a diagnosis of angiosarcoma was made. Histologic and immunohistochemistry showed classic features of epithelioid angiosarcoma. Specific recognition of angiosarcoma in cytologic specimens is difficult and definitive diagnosis in the absence of ancillary methods is only occasionally achieved. The prominent epithelioid features may cytologically mimic poorly differentiated carcinoma, malignant melanoma and even epithelioid sarcoma. Recognition of subtle cytologic features of vasoproliferation, immunocytochemical demonstration of endothelial markers, and/or ultrastructural examination are necessary before a final conclusion may be drawn.

FINE NEEDLE ASPIRATION CYTOLOGY OF MALT LYMPHOMA OF THE EYELID – CASE REPORT

E. Garcia-Ureta

Juan Canalejo Hospital,
La Coruña, Spain

Malignant lymphomas arising in ocular adnexa are rare, and they account for 8% of all extranodal lymphomas. There are only sporadic case reports of such lesions in the eyelid with FNAC studies. In this report, cytologic features of a patient with eyelid MALT lymphoma are presented. An 83-year-old woman with no history of a systemic lymphoproliferative disease presented with a 2-month history of a right eyelid mass not associated with pain or any

other symptoms. FNAC of the eyelid mass was performed. A total of four Papanicolaou and MGG specimens were prepared. Additional material was used for immunocytochemistry studies with CD-20 and CD-3 primary antibodies. On cytology, the smears showed a relatively uniform population of lymphoid cells. The lymphocytes were composed of predominantly small-sized cells with round to irregular nuclear outlines; the cytoplasm was scanty and basophilic. Immunocytochemistry revealed the lymphoid cells to be B-cells (CD-20+). Lymphoepithelial lesions were absent. Histologically, immunochemical and gene rearrangement studies showed a typical picture of MALT lymphoma. Differential diagnosis of FNAC material includes reactive lymphoid hyperplasia and inflammatory pseudotumor. The traditional morphologic criteria employed to distinguish extranodal lymphoid hyperplasia and malignant lymphoma generally have not been helpful in evaluating these extranodal lymphocytic proliferations composed predominantly of small lymphoid cells. The use of special techniques in diagnostic cytology specimens is well established; in histopathology it has a particularly important role in the assessment of lymphoid proliferative disorders.

FINE NEEDLE ASPIRATION CYTOLOGY OF MYOEPIITHELIOMA OF THE HARD PALATE – CASE REPORT

E. Garcia-Ureta, E. Carro Rey

Juan Canalejo Hospital,
La Coruña, Spain

Myoepithelioma appears to resemble pleomorphic adenoma clinically and may be a development variant of pleomorphic adenoma. Myoepithelioma is a rare salivary gland tumor composed nearly exclusively of myoepithelial cells; the plasmacytoid variant is an uncommon subtype. Just a few benign and malignant myoepitheliomas have been studied by FNAC. FNAC findings of a plasmacytoid myoepithelioma are reported. A 55-year-old woman presented with a painless nonulcerated submucosal nodule located in the hard palate. FNAC of the palate mass was performed according to standard procedure using a 23 gauge needle. Two slides were stained with Papanicolaou and another two slides with MGG. Additional slides were used for immunocytochemical studies with keratin, vimentin, S-100 protein and alpha-smooth muscle actin primary antibodies. On cytology, the aspirates were very cellular and composed of solely one cellular type lying in a clean back-

ground. Cells were arranged mainly in old-shaped aggregates with an overt tendency towards dispersion. Also, abundant single cells were seen. They presented round nuclei without nucleoli and prominent and finely granular cytoplasm reminiscent of plasma cells. Atypia and mitosis were not seen. Immunocytochemical studies demonstrated positive staining with keratin, vimentin and S-100 protein. Considering these findings, a diagnosis of pleomorphic adenoma with prominent myoepithelial overgrowth was made. Light microscopy immunohistochemistry studies performed on a surgical specimen showed a typical picture of myoepithelioma. This case illustrates the cytologic findings in myoepithelioma. The main differential diagnosis is pleomorphic adenoma. Although the benign nature of myoepithelioma can generally be recognized on FNAC material, the cytologic features are not specific and its distinction from pleomorphic adenoma is not possible.

FINE NEEDLE ASPIRATION CYTOLOGY OF HEAD AND NECK LYMPH NODES DURING A 5-YEAR PERIOD

S. Kojić-Katović, A. Vasilj, S. Ćurić-Jurić, F. Jurić

Department of Cytology,
Sestre milosrdnice University Hospital,
Zagreb, Croatia

Lymphadenopathy of the head and neck is a common clinical problem. It can be caused by infections, malignancy, immune disorders, etc. Fine needle aspiration cytology has an important role in the diagnosis of lymph node enlargement. During a 5-year period (1999-2003), 1759 fine needle aspiration procedures were performed at Department of Cytology, Sestre milosrdnice University Hospital, 318 (18%) of them under ultrasound guidance. There were 98/1759 (6%) nondiagnostic smears; 1084/1661 (65%) benign and 577/1661 (35%) malignant lymph nodes. Hematologic disease (non-Hodgkin's lymphoma and Hodgkin's disease) was diagnosed in 204/577 (35%) and metastatic process in 373/577 (65%) malignant lymph nodes. Immunocytochemistry was performed in 17 cases (11 lymphomas and 6 metastatic tumors). Fine needle aspiration cytology was found useful in the management of patients who underwent the procedure. Patients with benign diagnosis were followed up and some of them were serologically tested for infectious diseases. Patients with a newly detected hematologic disease were mostly operated on (node excision) for the histopathologic diagnosis

and those with a metastatic disease were referred for oncologic treatment.

CORRELATION OF CYTOLOGIC AND HISTOPATHOLOGIC DIAGNOSIS OF PAROTID GLAND TUMORS

E. Žokvić, I. Maričević, M. Šokčević

Department of Cytology,
Sestre milosrdnice University Hospital,
Zagreb, Croatia

Fine needle aspiration cytology (FNAC) is often used in the diagnosis of parotid gland lesions. At our Department of Cytology, FNA was performed in 176 patients, some of them under ultrasound guidance, during a 5-year period. Cytologic analyses found tumor lesions in 85 cases. Correlation with histopathology was available in 50 cases. Of these, 40 were histologically benign (15 Warthin's tumors, 23 pleomorphic adenomas, and one basal cell adenoma and possible oncocytoma each) and 10 histologically malignant (4 adenoid cystic carcinomas, 3 mucoepidermoid carcinomas, and one basal cell carcinoma and carcinosarcoma each). In the group of histologically benign tumors (n=40) cytologic diagnosis was also benign tumor in 39 cases and cyst with inflammation in one case. In the group of histologically malignant tumors (n=10) cytologic diagnosis was malignant in 8 case and benign tumor in 2 cases. FNAC is highly efficient in the diagnosis of parotid gland lesions, patient selection for surgical treatment, and differentiating benign from malignant tumors.

LICHEN SCLEROSUS ET ATROPHICUS – CASE REPORT

A. Soldo-Belić, M. Šitum, J. Meštrović-Štefekov,
N. Rajačić

Department of Dermatology and Venereology,
Sestre milosrdnice University Hospital,
Zagreb, Croatia

Lichen sclerosus et atrophicus (LSA) is a chronic atrophic disease of unknown etiology. It is more common in females than in males (F:M=10:1). It occurs at the age of 40-60. Anogenital site is most common, however, extragenital site is observed in 20% of cases. We describe a 54-year-old male with skin lesions disseminated on the scalp, unilaterally on the face and both shoulders. The lesions first

appeared 4 months before on the right ear in the form of tiny red-violet macules that spread quickly to the right side of the face, scalp and both shoulders. The initial red-violet color turned rust-brown and small pit scars began to appear, particularly on the face. On hospital admission, he had numerous small, pigmented brown macules on the right side of the face, both shoulders, and frontal, temporal and parietal regions, associated with small pit atrophic lesions on the right side of the face only, and larger, atrophic lesions on specified regions of the scalp, clinical findings which were not at all characteristic of LSA. Biopsy was obtained from the parietal region. Histologic findings were certainly consistent with LSA: epidermal atrophy with subepidermal blistering and edematous, swollen collagen. There was also significant incontinentia pigmenti (melanin) in the papillary dermis, and perivascular infiltration of monocytes. Therapy with chloroquine (Resochin) was started, and the patient has been under observation.

ACINIC CELL CARCINOMA – CASE REPORT

Lj. Fuštar-Preradović, D. Đanić¹, T. Jakovina, K. Jakovina
Departments of Pathology and Forensic Medicine, and of
¹ENT and Cervicofacial Surgery,
Dr. Josip Benčević General Hospital,
Slavonski Brod, Croatia

Acinic cell carcinomas account for only 2%-3% of salivary gland tumors, and 90% of them are located in the parotids. They are sometimes bilateral or multicentric, and 10%-15% of these tumors metastasize to lymph nodes. A 47-year-old woman had a tumor in the upper lobe of the parotid gland. The aspirate smear contained cells larger than acinar cells in a normal salivary gland, and the cytoplasm appeared either finely vacuolated or densely gray. The nuclei were uniform, round or oval with a small, central nucleolus. The stroma showed lymphoid infiltrates. There were no regional metastases to lymph nodes. The parotid gland was surgically removed. Microscopically, the tumor formed a well-circumscribed mass. The stroma was scanty, showing few lymphocyte infiltrates. The tumor consisted of large basophilic, granular cells, sometimes in an acinar configuration. These cells were stained with PAS (periodic acid-Schiff). There generally were round clear spaces, which may have resulted from the accumulation of entrapped secretion or from cell rupture and coalescence of intracytoplasmic vacuoles. The diagnosis was acinic cell carcinoma. One lymph node without tumor invasion was found near the parotid gland.

ONCOCYTIC MUCOEPIDERMOID CARCINOMA OF THE PAROTID GLAND

V. Blažičević, K. Marjanović, B. Dmitrović, S. Manojlović

Department of Pathology and Forensic Medicine,
Osijek University Hospital,
Osijek, Croatia

Oncocytic mucoepidermoid carcinoma of the salivary gland is rare. A 66-year-old woman who presented with a slowly growing left parotid mass is presented. The parotid gland was placed in 10% buffered formaldehyde solution (formalin). Sections were embedded in paraffin for standard hematoxylin-eosin, periodic-Schiff with and without diastase, mucicarmine, and phosphotungstic acid-hematoxylin staining employing the overnight incubation method. On histopathologic examination, the parotid gland grossly revealed a partially cystic, well-circumscribed mass measuring 3.5 cm in diameter and filled with clear mucoid material. There was a thin rim of normal salivary gland tissue surrounding the mass. Microscopically, low-power examination revealed a solitary mass with irregular but smooth contours. The entire tumor was surrounded by a fibrocollagenous capsule of variable thickness. The neoplasm consisted of nests and trabeculae of typical oncocytes characterized by abundant, granular eosinophilic cytoplasm and central dark, round nuclei with occasional nucleoli. In addition, fibrocollagenous trabeculae separated the nests and lobules of tumor cells. Cysts varying in size with epithelial lining composed predominantly of oncocytes and mucinous goblet cells were observed throughout the tumor. Focal areas of the cysts were composed of polygonal squamoid cells. Mitotic figures and necrosis were absent but evidence of vascular invasion and perineural infiltration was observed. With the phosphotungstic acid-hematoxylin stain, the cytoplasm of oncocytic cells had an intense blue granularity. Periodic acid-Schiff with and without diastase demonstrated intense staining of both the intraluminal and intracytoplasmic material, and mucicarmine stained the cytoplasm of goblet cells. The diagnosis of mucoepidermoid carcinoma involves identification of mucous, epidermoid, intermediate and, in some cases, clear cells that are present in a varying proportion and arranged in cystic or glandular patterns, solid nests or cords, or their combinations. In addition, basaloid and columnar cells can often be seen. In contrast, sebaceous, spindle or oncocytic cells rarely occur, but when they predominate, they can present a challenging differential diagnosis. Because of the rarity of the oncocytic variant of mucoepidermoid carcinoma, determining prognosis may

be problematic. However, based on grading criteria used for routine mucoepidermoid carcinomas, the tumor in this case was considered a low-grade carcinoma. Accordingly, we believe that complete surgical excision of this tumor and long-term clinical follow-up are appropriate treatment option.

References

1. GHIATH H *et al.* Oncocytic mucoepidermoid carcinoma of the parotid gland. *Arch Pathol Lab Med* 1994;118:313-4.
2. BABAK J-P *et al.* Oncocytic mucoepidermoid carcinoma of the salivary glands. *Am J Surg Pathol* 1999;23:523-9.
3. BRANNON RB *et al.* Oncocytic mucoepidermoid carcinoma of parotid gland origin. *Oral Radiol Endod* 2003;96:727-33.

MALIGNANT RHABDOID TUMOR OF THE TONGUE – CASE REPORT

Č. Tomasović-Lončarić, S. Lambaša, S. Manojlović, A. Bauer-Šegvić, D. Ljubanović

Department of Pathology, Dubrava University Hospital, Zagreb, Croatia

Malignant extrarenal rhabdoid tumor (MERT) is an unusual neoplasm of uncertain histogenesis, distinctive histologic pattern and aggressive clinical behavior. Approximately 100 examples of MERT have been reported over a broad range of anatomic locations as of this date. To the best of our knowledge, there has been only one case report of MERT which occurred in the tongue so far. An 18-year-old female presented with induration of the anterior third of the tongue of a 16-month duration. The surface was bulging, berry-shaped and bleeding, suggestive of an angiomatous lesion. Radial excision of the tongue was performed. Histopathologic analysis revealed a solid tumor measuring 1 cm in the largest diameter. The tumor was composed of epithelioid, eosinophilic cells with 'rhabdoid' features; some of these cell contained rounded eosinophilic cytoplasmic inclusions that displaced the nuclei to the periphery. Most of the cells showed diffusely distributed vimentin immunoreactivity, and focal epithelial membrane antigen and keratin immunoreactivity. The cells were unreactive to desmin, S-100 protein, F VIII, LCA, and skeletal and smooth muscle actin. Angioinvasion was present at the tumor periphery. Ultrastructurally, cells contained intracytoplasmic paranuclear whorled intermediate filaments (6-7 nm) with glycogen, dilated rough endoplasmic reticulum, ribosomes and mitochondria em-

bedded in the filaments. The basal membrane and intercellular junctions were present. Following pathologic report, re-excision of the tongue was done and the patient received chemotherapy. Twenty months after the diagnosis the patient showed no signs of tumor recurrence or metastases. Although there has been a contradiction whether malignant rhabdoid tumor represents a distinctive pathologic entity or a phenotype shared by heterogeneous neoplasm, most authors support the diagnosis of 'rhabdoid tumor' because the biologic implications of the phenotype are constant and important on clinical grounds.

References

1. PATRON J *et al.* Malignant rhabdoid tumor of the tongue. *Oral Surg Oral Med Oral Pathol* 1988;65:67-70.
2. WICK MR *et al.* Malignant rhabdoid tumors: a clinicopathologic review and conceptual discussion. *Semin Diagn Pathol* 1995;12:233-48.
3. PARHAM DM *et al.* The clinicopathologic spectrum of putative extrarenal rhabdoid tumors. *Am J Surg Pathol* 1994;18:1010-29.

INSULAR CANCER OF THYROID GLAND – CASE REPORT

I. Novosel¹, S. Bulimbašić², V. Ramljak³, R. Šeparović⁴, D. Došen⁵, V. Šeparović⁶

¹Department of Pathology, Dr. Ivo Pedišić County Hospital, Sisak;

²Department of Pathology, Sveti Duh General Hospital, Zagreb;

³Departments of Cytology, ⁴Internal Medicine, ⁵ENT, and

⁶Pathology, University Hospital for Tumors, Zagreb, Croatia

The first case of insular thyroid cancer recorded in the Croatian medical literature is reported.

Insular cancer, a rare malignant tumor, is classified according to its cytologic and architectural features as a poorly differentiated cancer of the thyroid. It accounts for 4%-7% of all malignant tumors of that site. As a distinct tumor entity it was first described in 1984 by Carcangiu *et al.* Insular cancer occurs more often in female population (M:F=1:2) aged 34-76. At diagnosis extrathyroid expansion of the tumor is established in 59% of cases. The age at tumor occurrence, tumor size and nodal involvement are emphasized as important prognostic factors. A 71-year-old female patient presented to our hospital with the symptoms of inspiratory stridor. Clinical examination (x-rays and

ultrasound) detected an expansive tumor mass of the left thyroid lobule measuring 6 cm. Because of this the trachea was narrowed to 5 mm in diameter. Total thyroidectomy was performed after US guided fine needle aspiration. Prompt surgical treatment was indicated because of cytologic suspicion of a poorly differentiated malignant disease. Pathohistologic analysis of standard H/E biopsies revealed a tumor mass with a characteristic insular growth pattern for monomorphic tumor cells with hyperchromatic nuclei and scant cytoplasm within which abortive follicles could be seen.

Immunohistochemical analysis confirmed the diagnosis of insular cancer; there was a diffuse positive reaction of tumor cells to thyroglobulin, focally to TTF-1, and scant to cytokeratin, while calcitonin, FVIII and CD34 as well as LCA were clearly negative. Thus, although rare, insular cancer of the thyroid ought to be considered on differential diagnosis of malignant thyroid tumors. Patients with insular cancer show better survival rate (average 3.9 years) than patients with anaplastic carcinoma. One-year follow-up of our patient did not reveal any relapse or metastatic disease.

References

1. PIETRIBIASI F *et al.* Am J Clin Pathol 1990; 94:687.
2. PILOTTI S *et al.* Am J Surg Pathol 1994;18:1054.

LYMPHOPROLIFERATIVE LESIONS IN SALIVARY GLANDS

M. Milković, P. Korać, S. Šitić, A. Borovečki

Department of Clinical Pathology and Cytology, Merkur University Hospital, Zagreb, Croatia

The etiopathogenesis of extranodal lymphomas is supposed to be associated with longlasting pre-existing inflammatory or autoimmune lesion, which can stimulate proliferation and transformation of lymphatic tissue. The most common primary salivary gland lymphoma is MALT type lymphoma. It differs from gastric MALT lymphoma in bcl-10 expression. During the 1992-2004 period, salivary glands in 151 patients were morphologically analyzed, 111 of them parotid and 40 submandibular glands. The analysis yielded the following results: 89 patients had benign and malignant epithelial changes, 35 showed lymphatic tissue proliferation, 12 had chronic inflammatory changes, 12 were free from any morphological changes, and 3 had

metastatic tumors, whereas inadequate material for analysis was obtained in one patient. The aim of the study was to define the type of lymphocytic expression and presence/absence of bcl-10 in 35 patients with lymphocytic proliferation and transformation. The slides were routinely processed (H&E, Giemsa). The phenotype was defined by CD20, CD3, CD79a, IgM, CD21, CD5 and CD10 monoclonal antibodies. Clonality was determined by PCR method and immunohistochemistry was used to detect expression and localization of bcl-10 oncogen positivity (MoAb Zymed Laboratories Corp.).

References

1. QUINTANA JL *et al.* Salivary gland lymphoid infiltrate associated with lymphoepithelial lesions. Hum Pathol 1997;28:757-9.
2. ELLIS GL *et al.* Atlas of tumor pathology. Tumors of the salivary glands. AFIP; 1996.

CD43 AS AN IMMUNOHISTOCHEMICAL MARKER FOR POOR PROGNOSIS IN OCULAR ADNEXAL LYMPHOMAS

M. Nola¹, A. Lukenda², M. Kalauz², P. Rašteggorac², M. Petrovečki³, M. Sičja³, I. Radman⁴, I. Aurer⁴

¹Department of Pathology, Zagreb University School of Medicine;

²University Department of Ophthalmology, Zagreb University Hospital Center;

³Zagreb University School of Medicine;

⁴Department of Hematology, University Department of Medicine, Zagreb University Hospital Center, Zagreb, Croatia

The aim of the study was to analyze ocular lymphomas treated at University Department of Ophthalmology, to classify them according to the new classification of the World Health Organization (WHO), and to determine which factors have a prognostic significance. From 1986 till 2003, histologic diagnosis of ocular lymphoma was made in 28 patients treated at Zagreb University Hospital Center. Histopathologic slides were reviewed and tumors were classified according to the new WHO classification. Additional immunohistochemical studies were performed on 35 specimens that were available. The antibodies used were CD3, CD5, CD10, CD20, CD43 and bcl-6, and in few cases cyclin D1, bcl-2, CD23, CD79a and CD138. Four patients were excluded from further study. The median age of patients was 62 years, with a 2:1 female predominance. Ocular adnexal lymphomas were found at the fol-

lowing anatomic sites: orbit in 20 (83.4%), and eyelid and conjunctiva in 2 (8.3%) patients each. Three patients had prior or concurrent systemic disease and 21 patients had primary lymphoma (83.3% stage IE, 4.2% stage IIE, and 12.5% stage IV). The main subtypes of non-Hodgkin lymphoma according to the WHO classification were

extranodal marginal zone B-cell lymphoma (83.3%), diffuse large cell B-cell lymphoma (8.3%), mantle cell lymphoma (4.2%) and plasmacytoma (4.2%). Six lymphomas were CD43 positive and five of them were extranodal marginal B-cell lymphomas. Local relapse was found in three patients and distant recurrence in four patients. Distant recurrence was found in four patients with stage IE disease (two of them also had a local relapse). In the group of patients with B-EMZL the estimated five-year overall survival rate was $92.9 \pm 6.6\%$, and five-year failure-free survival rate was $80.1 \pm 10.3\%$. Age, gender, side of involvement, anatomic localization of the lesion, clinical stage of disease, and mode of therapy had no prognostic significance during the median follow-up period of 52 (range 9-131) months. The immunohistochemical marker CD43 was the only parameter of prognostic significance ($p=0.035$). Patients with B-EMZL had almost 14 times higher chance for an unfavorable outcome if the tumor cells expressed CD43 on their surface as compared with the CD43 negative cases. These findings indicate that most ocular adnexal lymphomas usually have a B cell immunophenotype, the morphologic and immunohistochemical features of extranodal marginal zone B-cell lymphoma, and a favorable prognosis. Our data suggest that CD43 could be useful to distinguish the group of patients with B-EMZL with unfavorable prognosis from those that have a good prognosis. CD43 positive ocular lymphomas are associated with a higher rate of subsequent distant recurrence and a risk of lymphoma-related death ($p=0.035$).

EXPRESSION OF C-ERBB-2 TISSUE ANTIGEN IN PATIENTS WITH ORAL LICHEN RUBER IN CORRELATION WITH CLINICAL STATUS

D. Biočina-Lukenda¹, A. Pirkić², A. Cekić-Arambašin¹

¹Department of Oral medicine, School of Dentistry, University of Zagreb;

²Ljudevit Jurak University Department of Pathology, Sestre milosrdnice University Hospital, Zagreb, Croatia

According to WHO criteria, oral lichen ruber (OLR) is a precancerous lesion of oral mucosa.

The aim of the study was to define the possible malignant potential of OLR lesions by determining the intensity of c-erbB-2 antigen expression. The study included 30 patients with clinically and histopathologically confirmed diagnosis of OLR. Results were compared with a control group of 15 patients diagnosed with oral leukoplakia, verified as leukoplakia simplex. The aim of the study was to assess the intensity of c-erbB-2 expression in the clinical forms of lichen ruber planus (LRP) and lichen ruber erosivus (LRE), and to compare the antigen expression according to inflammation and degree of hyperkeratosis. The c-erbB-2 antigen was detected by the APAAP and LSAB immunohistochemistry methods after treatment in a microwave oven. The reaction of the study antigen was expressed as mosaic, delicately positive in the spinous layer cells and negative in basal layer cells. The reaction was of a strong intensity in tonofibrils of the spinous layer cells. In the control group, the reaction was uniform and strong in all epithelial layers. There was no difference in the expression intensity between the two clinical forms of oral lichen. The intensity of this antigen expression was independent of the extent of inflammation, but positively correlated with the extent of intralesional hyperkeratosis. It is concluded that such a modified expression of c-erbB-2 antigen in OLR lesions points to an altered nature of these lesions with a potential to undergo malignant transformation.

PROLIFERATIVE ACTIVITY OF EPITHELIAL CELLS IN ORAL LICHEN RUBER DETECTED BY PCNA AND KI-67 ANTIGENS

D. Biočina-Lukenda¹, A. Pirkić², A. Cekić-Arambašin¹

¹Department of Oral medicine, School of Dentistry, University of Zagreb;

²Ljudevit Jurak University Department of Pathology, Sestre milosrdnice University Hospital, Zagreb, Croatia

Proliferative activity of epithelial cells in oral lichen ruber (OLR) lesions may be caused by underlying inflammation following an immune reaction. The aim of the study was to detect PCNA and Ki-67 tissue antigens in correlation with the severity of clinicopathologic alteration of oral mucosa in OLR, to assess the expression intensity of these antigens in the clinical forms of lichen ruber planus (LRP) and lichen ruber erosivus (LRE), and to compare antigen expression according to inflammation and hyperkeratosis degree. Patients (N=30) with the clinical

and histopathologic diagnosis of OLR were selected. The control group included patients with a verified diagnosis of oral leukoplakia. The PCNA and Ki-67 tissue antigens were detected by the APAAP and LSAB immunohistochemistry methods after treatment in a microwave oven. The reaction of study antigens was mosaic-like, intracellular and focal prominent in particular cell groups. PCNA antigen was detected in the basal and parabasal cell layers, and in inflammatory infiltrate of lamina propria. The Ki-67 antigen was detected in basal cells and in some inflammatory cells of lamina propria. The reaction was negative in other epithelial layers. High intensity of PCNA antigen expression was observed in OLR lesions, without any notable difference in the expression intensity between the two clinical forms of the disease. The intensity of PCNA antigen expression positively correlated with the extent of inflammation and intralesional hyperkeratosis. The expression of Ki-67 tissue antigen manifested with mild to moderate reaction. Reaction of greater intensity was observed in erosive lesions of oral lichen. The reaction positively correlated with the extent of inflammation and intralesional hyperkeratosis. Accordingly, the immunohistochemical reaction of PCNA and Ki-67 antigens was found to alter according to the clinical status of OLR patients, and could be related to the modified nature of OLR lesions.

FHIT PROTEIN EXPRESSION IN HUMAN DENTAL CYSTS

A. Malčić, S. Jukić, S. Domitrović-Krušlin, I. Anić, B. Pavelić, K. Pavelić¹, B. Krušlin²

Department of Dental Pathology, School of Dentistry;
¹Department of Molecular Medicine, Ruđer Bošković Institute;
²Ljudevit Jurak University Department of Pathology, Sestre milosrdnice University Hospital, Zagreb, Croatia

Fragile Histidine Triad (FHIT) has been shown to span the fragile chromosomal site FRA 3b at band 3p14.2¹. Alterations and deletions within the FHIT gene and concomitant perturbations of FHIT protein expression are strongly linked to the genesis and establishment of human tumors of the lung, cervix, breast, stomach, pancreas, oral cavity, and other tissues². FHIT gene acts as a tumor suppressor, and therapeutic significance of the restoration of its expression has been proposed³. The aim of this study was to estimate the expression of the FHIT protein in the

epithelial lining of oral cysts by use of immunohistochemistry. An immunohistochemical study was conducted on 21 oral cysts collected for pathohistologic diagnosis after cystectomy and apicectomy. Nineteen of these were inflammatory radicular cysts obtained from 10 male and 9 female patients, age range 14-69 (mean age 40.9) years. Two were developmental odontogenic cysts: 1 keratocyst obtained from a male aged 49, and 1 follicular cyst from a female aged 29. The primary antibody used was rabbit anti-FHIT (Zymed Laboratoires Inc., San Francisco, CA, USA). Seven radicular inflammatory cysts (5 from male and 2 from female patients) showed positive reaction implying normal expression of FHIT. Three radicular inflammatory cysts showed weak positive reaction (all 3 from female patients). The reaction was negative in 9 radicular inflammatory cysts (5 from male and 4 from female patients). Neither of the 2 developmental cysts showed positive reaction. It is concluded that expression of FHIT protein is to a certain extent altered in inflammatory dental cysts. Due to the different origin and nature of developmental cysts, it is possible that the aberration of FHIT protein is even more frequent, however, additional studies in more specimens should be performed to make any firm conclusion.

References

1. INOUE H *et al.* PNAS 1997;96:14584.
2. HUEBNER K *et al.* Br J Cancer 2003;88:1501.
3. LUCA R *et al.* PNAS 2002;99:3615.

EPSTEIN-BARR VIRUS EXPRESSION IN BREAST CANCER

N. Bilalović¹, S. Vranić², S. Hasanagić², I. Selak¹

¹Department of Pathology,
²School of Medicine, University of Sarajevo, Sarajevo, Bosnia and Herzegovina

Epstein-Barr virus (EBV), a ubiquitous herpes virus, was the first virus shown to cause malignant alterations in humans. Recently, several studies have pointed to the important but controversial role of EBV in the development of breast cancer, reporting on different percentage of EBV positive tumor cells (21%, 32% and 51%). In the present study, we analyzed the frequency of EBV in 44 specimens of invasive breast cancer diagnosed at the Department of Pathology, Sarajevo University School of Medicine. EBV expression was correlated with histopatholog-

ic and clinical data as well with disease-free survival (DFS) and overall survival (OS). For immunohistochemical staining, the EBNA-1 monoclonal antibody (DAKO, Glostrup, Denmark) was used. EBNA-1 scoring system was as follows: 0 – no positive cells; 1 – rare cells positive or staining could be identified with certainty only by using magnification of at least $\times 200$; 2 – staining can be identified by low-power examination, but it is weak; and 3 – staining can be identified by low-power examination, and it is intense. Nine (20.5%) tumors were negative and 35 (79.5%) positive for EBNA-1. Of the positive tumor cells, 8 (18.2%), 14 (31.8%) and 13 (29.5%) tumors showed intensity 1, 2 and 3, respectively. There was no correlation between EBNA-1 expression of EBV and estrogen, progesterone, Bcl-2 and cyclin D1 expression in breast cancer (Mann-Whitney test). There was no statistically significant correlation between age and EBV presence, however, 21 of 22 women (95%) aged < 50 and 14 of 22 (63%) women aged > 50 were positive for EBV. We recorded a considerably higher expression of EBNA-1 EBV in our biopsy samples compared with data from the available literature. The reason for this is not clear, and more sophisticated and molecular methods should be used to elucidate it.

CYCLIN D1 IS A USEFUL PROGNOSTIC FACTOR IN BREAST CANCER

N. Bilalović¹, S. Vranić², S. Hasanagić², H. Basić³, A. Tatarević³, I. Selak¹

¹Department of Pathology, School of Medicine, University of Sarajevo;

²School of Medicine, University of Sarajevo;

³Department of Oncology, Sarajevo University Clinical Center, Sarajevo, Bosnia and Herzegovina

The aim of the study was to evaluate and compare basic histopathologic data (type, grade, tumor size, lymph node status, mitotic activity) and immunohistochemical markers (estrogen receptor (ER), progesterone receptors (PR), Bcl-2 and Cyclin D1) with relapse-free survival (RFS) and overall survival (OS). Medical records of 52 patients from Central Database of Department of Oncology, Sarajevo University Clinical Center, diagnosed in 1998, were analyzed. The mean follow-up was 58 (range 4-99) months. Routine histopathologic evaluation was performed on 52 formalin fixed and paraffin embedded tumor tissues. For immunohistochemistry ER, PR and Bcl-2 staining with DAKO monoclonal antibodies were used. For cyclin D1

NovoCastra monoclonal antibody was used. Kaplan-Meier test and Cox regression were used on statistical analysis. Patients with smaller tumor size had longer OS and RFS ($p=0.003$ and $p=0.04$, Kaplan-Meier test). Tumor grade showed inverse correlation with OS ($p=0.006$). Patients with four or more positive auxiliary lymph nodes had significantly shorter OS and RFS ($p=0.001$ and $p=0.003$). Higher mitotic activity correlated with shorter OS ($p=0.003$). Higher ER and PR density correlated with longer OS ($p=0.04$ and $p=0.01$, respectively). Stronger Bcl-2 expression was associated with longer OS and RFS ($p=0.006$ and $p=0.005$). Weaker cyclin D1 expression correlated with longer OS ($p=0.02$). Cox regression yielded cyclin D1 as the only independent prognostic factor ($p=0.05$). Although a number of factors are of prognostic significance for OS and RFS, only cyclin D1 was demonstrated to be an independent prognostic factor in this study.

EVOLUTION OF THE NECK DISSECTION PHYLOSOPHY

D. Shejbal, Z. Alerić, I. Barač, Ž. Odobašić, K. Zurak, V. Bedeković, M. Ivkić, B. Šimunjak, D. Globlek

University Department of ENT, Sestre milosrdnice University Hospital, Zagreb, Croatia

We followed the evolution of planning and performing neck dissection since the first Crile 'en block resections'. Many new, more selective methods, the choice of which depends on the tumor site and its metastases, have been developed since the first procedures. There has been strict acceptance of the neck dissection accomplishment according to contemporary protocols for removal of micrometastasis in the 90's to differentiate it from the 80's. Due to this, a new methodology of preoperative staging as well as postoperative follow-up and systematized nomenclature have been introduced; the number of elective and bilateral dissections has increased; and the number of elective radiotherapies and postoperative irradiation has decreased. The main purpose of the report is to show the impact of these changes on the number of larynx and neck dissection procedures, and on changes in their interaction during the last two decades. The number of dissections and the choice of the method of dissection depending on tumor site and type of laryngectomy are discussed. The results showed a significant improvement in the indications, better selectivity, and an increase of the overall number of dissections

in the second decade compared with the first decade, thus confirming the previously mentioned significant change in the surgical approach to head and neck carcinoma as well as strict acceptance and introduction of the new procedures. Neck dissections performed at University Department of ENT, Sestre milosrdnice University Hospital, from 1982 till 2001, are elaborated, with retrospective analysis of larynx carcinoma.

STRATEGIES FOR TREATMENT OF KELOID AND HYPERTROPHIC SCARS

D. Shejbal, Z. Alerić, V. Bedeković, M. Ivkić, L. Kalogjera, P. Drviš

University Department of ENT,
Sestre milosrdnice University Hospital,
Zagreb, Croatia

Keloids and hypertrophic scars are consequences of excessive collagen deposition during the wound healing process. The increased number of operations and injuries, widely accepted culture of piercing, and higher esthetic criteria have resulted in a higher interest in the methods of their treatment. Due to the lack of animal models, research of any kind can only be based on clinical experience. A great number of therapeutic options show that no ideal therapy has yet been found. The use of multiple modalities is often necessary to treat the lesions successfully. Molecular, biochemical and clinical features of keloids and hypertrophic scars as well as treatment modalities are discussed.

SECONDARY HYPERPARATHYROIDISM; PARATHYROIDOMATOSIS – CASE REPORT

D. Parazajder¹, M. Kovačić¹, D. Pavlović², Z. Petrović³, P. Drviš⁴, D. Bošić⁴

¹Division of ENT/Head and Neck Surgery, Department of Surgery, and

³Department of Pathology, Sveti Duh General Hospital;

²University Department of Medicine, and

⁴University Department of ENT/Head and Neck Surgery, Sestre milosrdnice University Hospital, Zagreb, Croatia

Secondary hyperparathyroidism (SHPT) is a disorder most frequently caused by chronic renal failure in its terminal stage. Sometimes it is caused by various disorders of the metabolism of vitamin D, phosphates and calcium.

Chronic renal failure leads to phosphate retention, low levels of D₃, and parathyroid hormone bone resistance. This leads to hypocalcemia and decrease in the number of calcium and D₃ receptors on parathyroid cell surface. In the beginning of the disease parathyroid glands respond with an increased synthesis and excretion of parathyroid hormone. As the disease develops, there is hyperplasia of parathyroid glands, first diffuse, and then nodular in the final stage. Blood levels of calcium, phosphate, intact PTH and alkaline phosphatase are measured for the diagnosis of SHPT. Ultrasound examination of the neck is required to evaluate the stage of the disease and to determine an indication for surgery. In the early stages the treatment is focused on phosphate reduction, phosphate binders and oral vitamin D intake. In the advanced stage of the disease calcitriol pulse therapy, calcium mimetics and vitamin D analogs can be added. In the terminal stage percutaneous inactivation with ethanol or application of calcitriol directly into the parathyroid glands can be tried. As a final solution, parathyroidectomy, subtotal, total or total with autotransplantation can be performed. Parathyroidomatosis is described as multiple nodules of parathyroid tissue scattered through soft tissues of the neck and/or mediastinum. It is believed that parathyroidomatosis is caused by autoimplantation of parathyroid cells during surgery of parathyroid glands. A female patient with chronic renal failure is presented. In 1997, she underwent subtotal parathyroidectomy for advanced SHPT. After 4.5 years free of symptoms, the disease recurred with all findings characteristic of SHPT. On ultrasound examination 8 nodules were found, with extension from the postoperative scar on the neck through soft tissues deeply next to the left thyroid lobe (parathyroid cells proved on cytologic biopsy). Reoperation was performed, when 7 and half nodules were resected.

PERIPHERAL NERVE SHEATH TUMOR OF NASAL SEPTUM – CASE REPORT

M. Grgić¹, H. Čupić², S. Stevanović¹, M. Ivkić¹

¹University Department of ENT, Head and Neck Surgery, and ²Ljudevit Jurak University Department of Pathology, Sestre milosrdnice University Hospital, Zagreb, Croatia

A 62-year-old female patient with an unusual tumor of the posterior nasal septum is presented. The patient complained of difficult and worsening nasal breathing during the last several years. She was a diabetic with appropriate

insulin control of glycemia. Routine nasal examination at the onset of symptoms showed no evidence of nasal pathology. She denied epistaxis, headaches or nasal discharge. As nasal obstruction progressed, another ENT examination showed bulging of the posterior septum that obstructed both nasal cavities but was covered with normal mucosa. CT scan revealed a round tumor occupying posterior septum, measuring 4 cm in diameter, located just in front of the sphenoid rostrum. Biopsy showed the tumor to be composed of myxomatous stroma and numerous vascular spaces. The stroma contained small fusiform to stellate cells without mitotic activity. Initial finding pointed to a 'hemangiopericytoma-like' tumor. The tumor was removed endoscopically. Negative margins were confirmed by intraoperative biopsy. Definitive histologic and immunohistochemical analysis (IHA) revealed the same histologic pattern as described earlier. IHA was positive for vimentin, CD31, CD34, GFAP, NSE, S100, CK-pan, and SMA. Differential diagnosis was a 'hemangiopericytoma-like' tumor again, however, strong reactivity to S100 suggested a definitive diagnosis of peripheral nerve sheath tumor. Clinical finding of very moderate bleeding during biopsy also supported this diagnosis instead of vascular tumor. Benign peripheral nerve sheath tumors are rare in the head and neck area, with only one case arising in the nasal septum, according to the literature cited in Medline.

LYMPH VESSELS OF HUMAN PARATHYROID

R. Pezerović-Panijan, Đ. Grbeša, D. Ježek, A. Čavčić, I. Goršić

Department of Histology and Embryology, School of Medicine, University of Zagreb, Zagreb, Croatia

There is a lack of studies on lymph vessels of the human fetal, postnatal and adult parathyroid gland. Few studies dealing with the above-mentioned topic have produced controversial results. Therefore, the aim of the current study was to investigate the presence of lymph vessels in the human parathyroid gland at various ages. Forty-four human parathyroid glands (patients aged 4-90 years) were divided into three age groups: 4-30 (1), 31-60 (2) and 61-90 (3) years. After standard histologic procedure (fixation, dehydration, embedding) tissue samples were serially cut and stained with hematoxylin-eosin and PAS. The slides were analyzed by light microscopy and immersion. The study showed the structure of parathyroid glands of groups 1 and 2 to be quite similar. In both groups the parenchyma

of the gland mainly consisted of chief cells with pale stained cytoplasm, whereas the morphology, location and content of lymph vessels were identical. Surprisingly, no lymph vessels were recorded in group 3. The parenchyma of the gland mainly consisted of chief cells with a dark stained cytoplasm. Study results indicated the morphology of human parathyroid changes that could be attributed to different functional status/activity of the gland at a particular age.

EXPRESSION OF INTRATUMORAL MICROVESSEL DENSITY IN DIFFERENTIATED CARCINOMAS OF THYROID GLAND WITH AND WITHOUT METASTASES

H. Čupić¹, B. Krušlin¹, D. Tomas¹, V. Petric², M. Ivkić², M. Belicza¹

¹Ljudevit Jurak University Department of Pathology, and ²University Department of ENT, Sestre milosrdnice University Hospital, Zagreb, Croatia

Differentiated carcinoma of the thyroid is considered to be a biologically relatively indolent neoplasm characterized by a favorable outcome following appropriate surgical treatment. However, about 30% of the tumors take an unexpected course and behave in a highly malignant fashion, showing poor prognosis. Therefore, in order to investigate whether intratumoral microvessel density could be used to identify a subgroup of patients with more aggressive behavior of the tumor as potential candidates for radical surgical treatment, adjuvant radiotherapy, antiangiogenic therapy and more intensive clinical follow-up, intratumoral microvessel count (MVC) and intratumoral microvessel density (MVD) were analyzed in 50 localized papillary carcinomas (LPC), 50 papillary carcinomas of the thyroid gland with metastatic involvement of regional lymph nodes (PCMLN), 50 associated metastatic tumors (M), and normal thyroid gland tissue. Also, intratumoral MVD and tumor histologic grade were compared between LPC and PCMLN groups, and the relationship between intratumoral MVD and clinical parameters of age, sex and tumor size was analyzed. The study was carried out by immunohistochemistry on the paraffin embedded material. Formalin fixed, paraffin embedded tissue was cut at 5 mm, deparaffinized and stained with monoclonal antibody to human Von Willebrand Factor H0079 (Factor VIII related antigen, Dako, Denmark) following Microwave Streptavidin ImmunoPeroxidase (MSIP) protocol on DAKO Tech-

Mate™ Horizon automated immunostainer. Invasive tumors were often heterogeneous with respect to the amount and distribution of microvessels, therefore sections were examined at low magnifications (x40, x100) to identify the most vascular area of the tumor ('hot spot'). Within these 'hot spots' counting was done in 10 non-overlapping consecutive high power magnification fields (x400/0.144 mm²). The average MVC was calculated from 10 vascular 'hot spots', and was also expressed as MVD/mm² of the tumor area. Statistical analysis was performed by the SAS 6.12 and STATISTICA 6.0 statistical package. The level of significance was set at $p < 0.05$ in all cases. A statistically significant difference in MVD was observed between LPC and PCMLN ($p < 0.001$). Mean MVD in LPC was 118.00/mm² as compared with 201.29/mm² in PCMLN. A statistically significant difference was observed in MVD between G1 (low grade) and G2 (high grade) papillary carcinomas ($p < 0.001$). Mean MVD in G1 carcinomas was 132.14/mm² as compared with 208.53/mm² in G2 carcinomas. Finally, our results suggest that intratumoral MVD expression in papillary carcinomas of the thyroid gland may help identify the group of high risk patients with a more aggressive biologic behavior of these tumors, who can benefit from new therapies such as angiogenesis-inhibiting drugs and adjuvant radiotherapy following more extensive surgical treatment, accompanied by careful follow-up. This selective approach may lead to the prevention of unnecessarily aggressive treatments for tumors that are likely to take a benign course and of inappropriate therapy for others with anticipated aggressive behavior display.

PERITUMORAL RETRACTION CLEFTING IN BASAL CELL CARCINOMA OF THE SKIN

J. Zarubica¹, T. Gabelić², S. Domitrović-Krušlin³, L. Labinac-Peteh¹, M. Vučić³, H. Čupić³, B. Krušlin³

¹Pula General Hospital, Pula;

²School of Medicine, University of Zagreb, Zagreb;

³Ljudevit Jurak University Department of Pathology, Sestre milosrdnice University Hospital, Zagreb, Croatia

Peritumoral lacunas or peritumoral retraction clefting are frequently observed around buds of basal cell carcinomas (BCC) and appear as a clear halo on hematoxylin-eosin section. They were considered as technical artifacts related to fixation methods. However, they can be observed on frozen sections where there are no similar fixation artifacts. Peritumoral clefting of BCC may be considered as a good

example of carcinoma-stroma interaction. The aim of the study was to analyze the presence of peritumoral clefting in different BCC types. The surgical pathology registry at Ljudevit Jurak University Department of Pathology was canvassed for the year 2003 to identify patients with skin BCC. Twenty-nine tumors were selected and further classified according to established histopathologic criteria as solid undifferentiated and adenoid differentiated. All relevant patient data including age, sex and histologic appearance were analyzed. There were 16 patients with adenoid and 13 patients with solid form of BCC. In the group with adenoid form there were eight males and females each, age range 48-89 (mean 67.9) years. In the group with solid form there were eight males and five females, age range 46-81 (mean 65.8) years. Tumor nests with more than 10 adenoid structures were analyzed. We also observed peritumoral clefting present in more or less than 50% of the adenoid structure circumference. All tumors were localized in the head and neck region. In the group of 13 solid BCCs there were three tumors with retraction clefting around complete circumference of the nests. Five tumors had less than 50% and five had more than 50% circumference included in retraction clefting. In the group of 16 adenoid BCC type there were two tumors in which there was clefting retraction around whole adenoid formation circumference. One tumor had less than 50% and thirteen had more than 50% circumference included in clefting retraction. We confirmed the existence of peritumoral retraction clefting in both solid and adenoid types of BCC. Clefting was found to be more pronounced in adenoid BCC type. Obviously, this phenomenon is due to the interaction between tumor cells and stroma, and should be additionally analyzed.

References

1. PINCUS H. Arch Dermatol 1965;91:24.
2. MEROT J *et al.* Acta Derm Venerol 1984;64:209.
3. MOORE RD *et al.* Am J Clin Pathol 1960;34:125-30.

OCULOPHARYNGEAL MUSCULAR DYSTROPHY – CASE REPORT

A. Bauer-Šegvić¹, A. Milić², D. Ljubanović¹, N. Canki-Klain³

¹Department of Pathology, Dubrava University Hospital;

²Croatian Institute of Brain Research;

³University Department of Neurology, Zagreb University Hospital Center, Zagreb University School of Medicine, Zagreb, Croatia

Oculopharyngeal muscular dystrophy (OPMD) is an adult-onset autosomal dominant disease with a worldwide distribution. It usually presents in the sixth decade with progressive dysphagia, ptosis, and proximal limb weakness. Unique nuclear filament inclusions in skeletal muscle fibers are its pathologic hallmark. It is caused by stable (GCG)₈₋₁₃ expansions in exon 1 of poly(A)-binding protein 2 gene (PABP2). (GCG)₆ represents normal repeat length, while (GCG)₇ is a polymorphism that acts as a modifier of the disease severity or as a recessive mutation. More severe phenotypes were observed in compound heterozygotes for the (GCG)₉ mutation and (GCG)₇ allele that is found in 2% of the population. We report on the histologic study in a 56-year-old woman who had progressive eyelid dropping from the age of 48. She had mild dysphagia, hardly noticed ophthalmoplegia, and severe proximal limb girdle weakness that had started around the age of 56 when she had been hospitalized and found to have a myogenic pattern of EMG, high serum level of creatine kinase and stenocardia. Muscle biopsy was performed. The biopsy specimen was examined by light and electron microscopy. Tissue samples for light microscopy were fixed in formalin, embedded in paraffin, and stained with hematoxylin and eosin. Electron microscopy samples were prepared according to standard procedure. Light microscopy showed normal arrangement and different thickness of muscle fibers. Examination of semi-thin sections showed the presence of a clear zone in some muscle fiber nuclei (intranuclear inclusions). On electron microscopy, these inclusions were made of tubular filaments arranged in tangles or palisades. The filaments were seen in muscle fibers but not in the cytoplasm or other cells found in the samples. The muscle fibers had otherwise normal ultrastructure. The intranuclear inclusions are specific for oculopharyngeal muscular dystrophy. Several years later DNA analysis confirmed the diagnosis of OPMD, finding her to be a compound heterozygote for (GCG)₈ mutation and (GCG)₇ allele of PABP2 gene. Until the identification of PABP2 gene mutations, definitive diagnosis relied on electron microscopy observation of intranuclear inclusion. Non-

vasive DNA testing from peripheral blood has now replaced this approach. The test is reliable, can be done in Zagreb, and permits accurate genetic counseling.

References

1. TOME FM *et al.* Morphological changes in muscle fibers in oculopharyngeal muscular dystrophy. *Neuromusc Disord* 1997;7:S63-69.
2. MULLER H *et al.* Genetic heterogeneity of oculopharyngeal muscular dystrophy. *Neuromusc Disord* 1996;6:S30.

HYALINIZING SPINDLE CELL TUMOR WITH GIANT ROSETTES OF THE UTERUS – CASE REPORT

S. Bulimbašić¹, I. Novosel², M. Dasović-Knežević³, V. Šeparović⁴, L. Beketić-Orešković⁵

¹Sveti Duh General Hospital, Zagreb;

²Dr. Ivo Pedišić County Hospital, Sisak; ³Zadar General Hospital, Zadar;

⁴Departments of Pathology and

⁵Radiotherapy, University Hospital for Tumors, Zagreb, Croatia

A case of a hyalinizing spindle cell tumor of the uterus with giant rosettes (HSTGR) is presented. To our knowledge, this is the first case of HSTGR described in the Croatian medical literature. A 38-year-old woman presented with painless uterus enlargement on routine gynecologic examination. Preoperative CT, ultrasound and radiographic examinations did not reveal any distant metastases. The patient underwent total hysterectomy and bilateral adnexectomy with selective pelvic and para-aortal lymphadenectomy. No complications occurred postoperatively. No adjuvant treatment was performed. The resected enlarged uterus measured 20x18x12 cm. Serial slicing of the uterus revealed a tumor mass of 15 cm in maximum length. The margins of the tumor merged with the uterine wall and the tumor infiltrated more than one half of the myometrium. Pathohistologic analysis confirmed the diagnosis of HSTGR. The tumor consisted of spindle stroma with predominating picture of large collagen nodules surrounded in rosette-like fashion by tumor cells in axial array, which in some areas coalesced into long serpinginous cords of dense hyalinization. Spindled stroma of varied cellularity consisted of fibroblastic cells that formed a storiform pattern in the hypocellular hyalinized or myxoid areas. Immunohistochemical staining confirmed the biphasic pattern of HSTGR; stromal reaction was positive for vimentin, NSE, SMA, desmin, but negative for S-100,

CD34, SA and cytokeratin, while the rosettes showed negative reaction with all performed staining. HSTGR was originally described in 1997 by Lane *et al.* At least morphologically it is closely related to low-grade fibromyxoid sarcoma. Although considered to be a tumor of low malignant potential, since the initial report a few cases with the development of pulmonary metastases have been described. At least one of them was associated with longterm survival. Fifteen months after operation, our patient is feeling well with no signs of recurrence. Extended follow-up will be necessary to rule out the development of local recurrence as well as metastatic disease.

References

1. LANE KL *et al.* Hyalinising spindle cell tumor with giant rosettes. A distinctive tumor closely resembling low grade fibromyxoid sarcoma. *Am J Surg Pathol* 1997;21:1481-8.
2. WOODRUFF JM *et al.* Low grade fibrosarcoma with palisaded granuloma-like bodies (giant rosettes): report of a case that metastasized. *Am J Surg Pathol* 1999;23:1423-8.
3. FARINHA P *et al.* Metastasizing hyalinizing spindle cell tumor with giant rosettes: report of a case with long survival. *Histopathology* 2000;36:92-3.

PURE LIPOMA OF THE UTERUS – A VERY RARE ENTITY

L. Labinac-Peteh¹, A. Pirkić¹, M. Matković-Bilin¹, A. Predanić²

¹Ljudevit Jurak University Department of Pathology, and

²University Department of Gynecology and Obstetrics, Sestre milosrdnice University Hospital, Zagreb, Croatia

Introduction

Pure lipoma is a very rare benign tumor of the uterus which commonly occurs in postmenopausal women. In the literature, lipoleiomyomas are most often described, however, these were the ones that do not represent a particular entity but a combination of two different tumors having different histogenesis. Several cases of pure uterine lipoma in the presence of endometrial carcinoma have been reported. The histogenesis of pure uterine lipoma has not yet been fully clarified. Previously, these tumors also used to be considered as hamartomas or choristomas, however, this opinion has been abandoned. Recently, the origin of these tumors has been explained by chromosomal aberration at the molecular level. Cytogenetics of the uterine lipoma has pointed to chromosomal abnormality in the

zones responsible for the control of cellular proliferation. Translocations of different genes, which become susceptible to aberration at several locations, were found in benign tumors of the mesenchymal origin, e.g., leiomyoma, pleomorphic adenoma, lipoma and chondrogenic pulmonary hamartoma. However, aberrant expression of HMGA2 protein should occur due to dysfunction of Tsc2 tumor suppressor gene in those cases in which structural abnormality is not present. Although rare, these tumors may pose a problem on the differential diagnosis *versus* other uterine mesenchymal tumors. Clinical symptoms and physical signs are similar to those in leiomyoma.

On gross examination, these tumors are yellowish in color, well confined, often presenting as a small node which is situated within the muscular layer. Histologically, the tumor is composed of lobules of mature lipid cells, which are divided by delicate soft tissue in which blood vessels of capillary type are often seen.

Case Report

An 85-year-old woman was admitted to the University Department of Gynecology and Obstetrics, Sestre milosrdnice University Hospital, for surgical removal of a left ovary tumor. A 2-cm large, round tumor with regular ultrasound flow on the left side of the uterus was clinically verified. Total hysterectomy and bilateral adnexectomy were performed, and a large cystic tumor mass of bluish color and smooth surface, which occupied the entire Douglas' pouch, was found in the left ovary.

Histologically, a well-circumscribed, yellowish, soft, intramural node measuring 5 mm was incidentally found in the uterine corpus. The tumor was lobulated and composed of mature lipid cells, among them narrow stripes of loose connective tissue were seen. A diffuse adenomyosis was also found. Endometrium was fibrocystic and atrophic. An empty cystic formation filled with blood measuring 7x8 cm was found in the right ovary, which was microscopically verified as an endometrial hemorrhagic cyst. The right fallopian tube was 7 cm long and was attached to the uterus, with histologic signs of chronic inflammation. The left adnexa were normal. Tumor cells showed an intensive positive Sudan B reaction. Immunohistochemical expression of S-100 antigen was prominent in tumor cells.

Conclusion

Pure lipoma is an extremely rare benign tumor of the uterus, which is of a mesenchymal origin. Usually, it is an incidental finding in postmenopausal women. Pure lipo-

ma may present a problem on differential diagnosis of uterine tumors.

References

1. KURMAN A *et al.* Blaunstein's pathology of the female genital tract. Springer, 2002.
2. SETNA Z *et al.* Ind J Pathol Microbiol 1999;42:383-4.
3. FALK S *et al.* Geburtshilfe Frauenheilkd 1989;49:762-4.
4. SHINTAKU M. Pathol Int 1996;46:498-502.
5. Di GESU G *et al.* Eur J Obstet Gynecol Reprod Biol 1998;80:199-200.
6. ALONSO EE. Gynecol Obstet Mex 1995;63:30-2.

INFLAMMATORY PSEUDOTUMOR OF THE CERVIX – CASE REPORT

I. Novosel¹, J. Ilić², D. Babić², B. Božić³, D. Janković¹, S. Jukić²

¹Department of Pathology and

³Department of Gynecology, Dr. Ivo Pedišić County Hospital, Sisak;

²Clinical Department of Pathology, Zagreb University Hospital Center, Zagreb, Croatia

Inflammatory myofibroblastic tumor, synonymously referred to as inflammatory pseudotumor (IPT), has become an almost ubiquitous non-neoplastic tumorous condition, most frequently reported in the lungs, however, no other anatomic site can be excluded. Recent literature emphasizes a frequent involvement of pediatric cases. Only seven cases of IPT have been reported in the uterus. To the best of our knowledge, we herein report on the histopathologic and immunohistochemical findings in the second case of cervical IPT in the literature. In December 2003, an 18-year-old woman presented to our hospital because of dysfunctional bleeding. Gynecologic examination revealed an incidental finding of a solitary leiomyoma-like mass measuring 4.2 and 3.8 cm in maximum diameter, originating from the cervix. Four months after surgical excision of the tumor the patient was feeling well with no signs of recurrence. A distinctive mesenchymal lesion composed of spindle cells, displaying morphological features of myofibroblasts admixed with considerable numbers of inflammatory cells, was found on histopathologic analysis of the tumor. Immunohistochemical staining was negative for SMA and positive for CD68, confirming the diagnosis of IPT. Although extremely rare at this location,

IPT should be taken in consideration if differential diagnosis of mesenchymal malignant lesion or other non-neoplastic condition is questioned. No history of trauma or recent surgical procedure, absence of Michaelis Guttman bodies, and negative special stains for microorganisms, together with distinctive histologic appearance of the tumor, should ease the confirmation of IPT.

References

1. ABENOZA P *et al.* Int J Gynecol Pathol 1994;1:80.
2. AZUNO Y *et al.* Am J Obstet Gynecol 2003;3:890.
3. GILKS CB *et al.* Int J Gynecol Pathol 1987;6:275.

SECOND PRIMARY MALIGNANT TUMORS IN PATIENTS WITH PRIMARY COLORECTAL ADENOCARCINOMA

G. Krajačić¹, I. Romac², M. Srbanic², K. Kunjko², M. Turčić², M. Kos², D. Baličević², B. Krušlin²

¹Zabok General Hospital, Zabok;

²Ljudevit Jurak University Department of Pathology, Sestre milosrdnice University Hospital, Zagreb, Croatia

The aim of the study was to determine the frequency and types of second primary malignancy in patients with primary colorectal adenocarcinoma. A total of 2035 (1200 male and 835 female) patients with colorectal carcinoma were analyzed. Data were obtained from the computer based colorectal cancer registry at Ljudevit Jurak University Department of Pathology for the 1995-2003 period. The database contains data on each patient including pathohistologic diagnosis. The following parameters were analyzed: sex and age distribution, and localization of second primary malignant tumors in patients with primary colorectal carcinoma. There were 107/2035 (5.3%) patients with second primary malignancy, 59 (3%) men and 48 (2.3%) women. Second primary malignancies in descending order of frequency were: stomach (16.5%), prostate (13.9%), skin (13%), urinary bladder (11.3%), and kidney cancer (6.9%). Ninety-eight (91.5%) patients had only one second malignancy, whereas nine (8.5%) patients had more than one second malignancy. It is concluded that the histopathologic type and location of second primary malignancy can be of great importance for patients, their physicians and pathologist. In this series the frequency of secondary malignancies was much higher than expected, reaching up to 5% of patients. Had we excluded skin cancers from the analysis, the frequency of second primary malignancies

would probably be lower, but data should be checked at the National Cancer Registry.

References

1. BRINSTER DR, RAPER SE. Synchronous colon and pancreatic cancers in a patient with Peutz-Jeghers syndrome: report of a case and review of the literature. *Surgery* 2004;135:352-4.
2. CAPRA F, SCINTU F, ZORCOLO L, MARONGIU L, CASULA G. Synchronous colorectal and renal carcinomas. Is it a definite clinical entity? *Chir Ital* 2003;55:903-6.
3. BOOR A, JURKOVIĆ I, DUDRIKOVA K. An unusual coincidence of multiple synchronous kidney tumors with a metachronous rectal adenocarcinoma. *Pathol Res Pract* 2003;199:695-9.

CHANGES IN UROPATHOLOGIC FINDINGS AT A 20-YEAR DISTANCE

K. Tomić¹, G. Krajačić², O. Kraus³, B. Krušlin⁴, M. Belicza⁴

¹Dr. Josip Benčević General Hospital, Slavonski Brod;

²Zabok General Hospital, Zabok;

³University Department of Urology and

⁴Ljudevit Jurak University Department of Pathology, Sestre milosrdnice University Hospital, Zagreb, Croatia

During the last 20 years, the occurrence of some diseases has changed due to a different way of living and new diagnostic and treatment possibilities. Diagnostic imaging (CT, MR and especially ultrasound) has increased the rate of identification of renal tumors, while there has not been any systematic screening for urologic diseases. Department of Urology is a referral center for prostate diseases since 1994. The procedure of needle core biopsy was introduced two years later and its utilization has increased significantly over the last few years. In the present study, the occurrence of some urologic diseases was compared at 20 years apart using the histopathologic database for 2 two-year periods. Data on all patients who underwent biopsies at Department of Urology during the 1980-1981 and 2000-2001 periods were included in the study. In the 1980/81 period, tissue samples of 25,117 patients were analyzed at Department of Pathology, 1070 (4.3%) samples being obtained from urologic patients. In the 2000/01 period, there were 27,720 patients, 2,233 (8%) of them from Department of Urology. Urogenital tract tuberculosis was found in 13 (1.2%) patients during the 1980/81 period, and in only two (0.1%) patients in the 2000/01 period. In the 1980/81 and 2000/01 periods, there were 13 (1.2%) and 102 (4.6%) renal cell carcinomas, respectively. Of all urologic

biopsies in the first period there was only one (0.1%) case, and in the 2000/01 period there were 17 (0.8%) cases of urothelial carcinoma of the pyelon. In the 1980/81 period there was not a single case of oncocytoma, whereas in the 2000/01 period 3 cases of oncocytoma were recorded. There were 106 (10%) and 64 (0.2%) testicular biopsies in the total number of urologic patients in the 1980/81 and 2000/01 periods, respectively. Of all testicular biopsies there were 13 (12%) and 29 (45%) tumors of the testis in the 1980/01 and 2000/01 periods, respectively. Seminoma accounted for 30% (n=4) and 55% (n=16) of all germ cell tumors in the 1980/81 and 2000/01 periods, respectively. Of the total number of urology biopsies performed in 1980/81 and 2000/01, there were 416 (38.8%) and 963 (43%) prostate biopsies, respectively, 59 (14%) of them carcinomas in 1980/81 and 222 (23%) carcinomas in 2000/01. An increasing number of prostate biopsies was recorded in the 2000/01 period, mainly due to the large proportion of needle core biopsies (304 of 966 prostatic biopsies). Prostatic biopsies accounted for 40% of all urologic biopsies in 2000 and for 46% in 2001. On the basis of this study it is concluded that the total number of urologic biopsies increased 1.9-fold comparing the first (1980-1981) and second (2000-2001) period. There was a significant increase in the number of renal cell carcinoma (3.8-fold) and urothelial carcinoma of the pyelon (8.4-fold). The total number of testicular biopsies decreased, whereas the number of testicular tumors and seminomas increased. Tuberculosis of the urogenital system decreased 13-fold.

References

1. ZHENG T *et al.* *Int J Cancer* 1996;65:723-9.
2. CARBONE A *et al.* *Arch Esp Urol* 2001;54:87-94

PERIACINAR RETRACTION CLEFTING AND P63 IMMUNOSTAINING IN PROSTATIC CARCINOMA

B. Krušlin, D. Tomas, Lj. Odak, A. Cviko, S. Kozlović, D. Bobonj, M. Belicza

Ljudevit Jurak University Department of Pathology, Sestre milosrdnice University Hospital, Zagreb, Croatia

The diagnosis of prostate carcinoma is based on three major histologic criteria: the infiltrative growth pattern, the absence of basal cell layer, and the presence of macronucleoli. Basal cells are invariably absent from the malignant

glands of prostate cancer. The ability of immunohistochemical staining to detect basal cells has proven to be diagnostically invaluable, especially in needle biopsy specimens. P63, a homolog of the tumor suppressor gene p53, has been shown in the basal cell component of epithelium from a variety of tissues, including prostate epithelium. One of the criteria favoring cancer is the presence of retraction clefting around neoplastic glands that is probably connected to the lack of basal cells. Therefore, the aim of this study was to correlate the presence and extent of retraction clefting and the expression of p63 in neoplastic glands in needle core biopsies. Fourteen cases with prostate carcinoma diagnosed on the basis of major and favoring criteria at Department of Pathology, Sestre milosrdnice University Hospital, were chosen for the study. The patients were aged 64-80 (mean 68.8) years. They underwent sextant biopsy after having an increased PSA serum value. In all cases retraction clefting was also described in biopsy findings. Immunohistochemical staining was performed following the Microwave Streptavidin ImmunoPeroxidase (MSIP) protocol on a DAKO TechMate Horizon automated immunostainer using antibodies to p63. Retraction clefting was observed in all 14 cases; in 8 (57.2%) it affected more, and in 6 (42.8%) less than 50% of the gland circumference. p63 immunostaining was negative in all carcinoma cases but positive in adjacent normal glands. Our results strongly suggested a connection between the lack of basal cells in neoplastic glands and the development of retraction artifacts. The results also showed invariably negative staining for p63 in all cases with periacinar retraction artifacts. We conclude that the clefts represent a reliable diagnostic criterion and that staining for p63 might be useful when the clefts affect less than 50% of the gland circumference or are not present at all.

References

1. EPSTEIN JI. *Mod Pathol* 2004;17:307-15.
2. KRUŠLIN B *et al.* *Virchows Arch* 2003;443:524-7.
3. WEINSTEIN MA *et al.* *Mod Pathol* 2002;15:1302-8.

NEGLECTED INFANT OR INFECTIVE DISEASE

K. Marjanović¹, B. Dumenčić¹, M. Marcikić¹, B. Dmitrović¹, D. Vuković², E. Matuzalem¹

¹Department of Pathology and Forensic Medicine, and
²Department of Mycobiology, Osijek University Hospital, Osijek, Croatia

A rare case of infant death caused by an infective disease (probably congenital toxoplasmosis), which was discovered on forensic autopsy at Department of Pathology and Forensic Medicine, Osijek University Hospital (CHO) is presented. Autopsy was performed upon notification from the CHO Department of Pediatrics, characterizing it a case of criminal offence of child neglect and abuse. The offender was the child's mother, currently in her fifth marriage with altogether 10 children. By court ruling she lost her parental right over 9 children for neglect and abuse, and was sentenced to one-year term of imprisonment. The tenth child was born from uncontrolled pregnancy on February 17, 2002. Thus, with social and medical supervision and with no reported signs of neglect, the child was admitted at the age of 70 days for hospital treatment for elevated temperature, dehydration, hypotrophy, convulsions, and progressing coma vigil. During hospital stay, doubts were raised of the possible child neglect and abuse, and judicial proceeding was started. Forensic autopsy, histopathologic findings and serology tests indicated that the cause of death was a congenital infectious disease, on the basis of which the mother was acquitted.

THE IMPORTANCE OF IMPLEMENTATION OF THE FIVE-TIER WHO CLASSIFICATION OF PITUITARY ADENOMAS

T. Sajko¹, Ž. Gnjidić¹, J. Talan-Hranilović²

¹University Department of Neurosurgery,
²Ljudevit Jurak University Department of Pathology, Sestre milosrdnice University Hospital, Zagreb, Croatia

Great changes have taken place in the basic knowledge of pituitary adenomas during the last decade, with a number of different classifications of pituitary adenomas proposed. In 2000, World Health Organization accepted the five-tier classification of pituitary adenomas proposed by Kovacs and Horvath. It is based on clinical and biochemical results, neuroradiologic imaging, operative findings, histology, immunocytochemistry and electron microscopy

studies on more than 10000 surgically treated pituitary adenomas. Its importance is that it supplies the endocrinologist, neurosurgeon and oncologist with valuable information concerning the biologic behavior, growth potential, treatment response and prognosis of pituitary adenomas. Due to financial restraints, lack of facilities and unavailability of well trained personnel, this five-tier classification cannot be implemented in all institutions. Nevertheless, clinical, biochemical, neuroradiologic, operative, histologic and immunohistochemical data are generally available. Together with the novel biologic techniques that provide data on tumor growth rate, aggressiveness and invasiveness, they are necessary in establishing correct diagnosis which will direct the patient's future treatment.

We strongly advocate this five-tier classification of pituitary neoplasms and hope it will find full implementation.

References

1. KOVACS K, HORVATH E, VIDAL S. Classification of pituitary adenomas. *J Neurooncol* 2001;54:121-7.
2. SANNO N, TERAMOTO A, OSAMURA RY, HORVATH E, KOVACS K, LLOYD RV, SCHEITHAUER BW. Pathology of pituitary tumors. *Neurosurg Clin North Am* 2003;14:25-39.
3. KOVACS K, SCHEITHAUER BW, HORVATH E, LLOYD RV. The World Health Organization classification of adenohypophyseal neoplasms: a proposed five-tier scheme. *Cancer* 1996;78:502-10.

TISSUE TYPING OF HLA GENES, ANTIGENS, AND ANTI-HLA ANTIBODY SCREENING IN TISSUE AND ORGAN TRANSPLANTATION

M. Batarello¹, N. Martinez¹, I. Humar¹, K. Rubia², V. Kerhin-Brkljačić¹

¹Tissue Typing Center, Department of Urology, Zagreb University Hospital Center, Zagreb;

²Department of Cytology, Karlovac General Hospital, Karlovac, Croatia

It is well established that transplantation is the method of choice in organ failure and to treat hematologic disorders and malignancies. In organ transplantation, organ donors can be relatives or cadavers. Bone marrow transplantation prefers HLA identical siblings, and now the use of unrelated bone marrow donors is in progress. However, the first condition for selecting a donor is ABO compatibility, which is followed by matching in major histocompatibility antigens. HLA antigens are detected by standard complement-dependent-cytotoxic assay. The same assay is

used to determine anti-HLA antibodies in sera of patients waiting for transplantation. In combination with good matching, the pretransplant cross-match reaction between donor cells and recipient sera must be negative. Special condition is detection of autoanti-HLA antibodies. With all criteria fulfilled it is reasonable to expect a higher surviving rate and good graft function.

COMPARATIVE EVALUATION OF THE MYCOBACTERIUM GROWTH INDICATOR TUBE (MGIT) WITH SOLID MEDIUM FOR ISOLATION OF MYCOBACTERIUM

N. Sučić, S. Zvonar, B. Tićac

Institute of Public Health, Rijeka, Croatia

Because mycobacteria are slow growing and require long incubation times, appropriate decontamination procedures, culture media, and conditions of incubation must be selected to facilitate optimal recovery from clinical specimens. The objective of the study was to evaluate isolation rates and time to detection of mycobacteria in clinical specimens using both BBL Mycobacterium Growth Indicator Tubes (MGIT) and Lowenstein-Jensen (LJ) medium as a reference method. Over a period of 2 years a total of 743 clinical samples were treated by N-acetylcysteine-NaOH method for decontamination and fluidification. Direct examinations were performed using Ziehl-Nielsen staining. For each sample, aliquots of 0.5 ml were inoculated onto Lowenstein-Jensen and to MGIT. Cultures were inoculated at 37 °C and daily observed for 2 months. It appears clearly that MGIT are a sensitive liquid medium containing a fluorescent sensor that allows for early detection of mycobacterial growth.

GIEMSA STAINING: METHOD OF CHOICE TO DETECT *HELICOBACTER PYLORI* IN CHRONIC GASTRITIS

Z. Bogović, D. Baličević, J. Matić

Ljudevit Jurak University Department of Pathology, Sestre milosrdnice University Hospital, Zagreb, Croatia

The bacterium *Helicobacter (H.) pylori* provokes gastritis and has also been associated with the possibility of cancer development. It is usually located on the mucous membrane of the stomach and in the area of gastric fave-

oli. The dye is used on formalin-fixed, paraffin-embedded tissue sections. Before tissue section staining, it is extremely important that the tissue of the stomach mucous membrane is correctly oriented in paraffin and the slice thickness is 4-6 μ m. In this way, one layer of the gastric mucosa cells is obtained, with *H. pylori* clearly visible if present. There are several methods to detect *H. pylori* in gastric mucosa of patients with chronic active gastritis and chronic gastritis: KWIK DIFF stain kit – Shandon kit; Warthin-Starry staining – silver method; Giemsa staining – Merck dye; and LSAB+System HRP/DAB-IHC method for *H. pylori* (Vissulation – LSAB+/HRP-DAB). Giemsa staining has a number of advantages: it is a quick, simple to perform, and differentiating method allowing for *H. pylori* to be easily observed within glandular epithelium of the gastric mucosa biopsy specimen. And the last but not the least, because of its simple performance and favorable price it is widely applicable in laboratories with less sophisticated equipment. However, Giemsa staining also suffers from some drawbacks, as follows: the Giemsa solution has to be filtered each time before use. Otherwise, a sediment is formed, so stain artifacts may cover *H. pylori*. The Giemsa working solution should be fresh. The acetate buffer should also be fresh, because the prepared tissue section has to be rinsed properly to ensure accurate diagnosis. Furthermore, the immersion time is also important for optimal staining of *H. pylori*. If the immersion time is too long, it is not possible to differentiate *H. pylori* due to vivid purple color of the whole tissue section. If the immersion time is too short, it is not possible to differentiate *H. pylori* because it is pale whereas the whole tissue section is light blue. The following results are obtained: nuclei – blue; cytoplasm, connective tissue – pink; erythrocytes – salmon colored; bacteria – blue to violet. Accordingly, Giemsa staining can be recommended as a fast, reliable and inexpensive method in the routine diagnosis of *H. pylori* in chronic active gastritis and chronic gastritis. According to our longlasting experience, a small series should be made (multiple cuts on the same glass). Furthermore, it is important to prepare an unstained cut for further studies, primarily IHC analysis of the mucus in the focal areas of a possible intestinal metaplasia. On gastric biopsy from different areas (antrum, pylorus, corpus), each specimen should be labeled in separate to make a precise diagnosis and to determine the location of *H. pylori*.

QUANTITY AND QUALITY OF IMMUNOHISTOCHEMICAL ANALYSIS BEFORE AND AFTER APPLICATION OF DAKO TECHMATE AUTOMATED IMMUNOSTAINER

J. Matić, H. Čupić, B. Krušlin

Ljudevit Jurak University Department of Pathology, Sestre milosrdnice University Hospital, Zagreb, Croatia

Technical advances that have supervened in the recent years are responsible for immunohistochemistry becoming a staple of the histopathology laboratory. The aim of the study was to analyze the period before (1997-2000) and after (2001-2002) the introduction of automated immunostainer in daily routine to reveal the potential advantages/disadvantages in comparison with standard manual immunohistochemical procedures. The study was carried out on a DAKO TechMate™ Horizon automated immunostainer, which has a capacity of up to 40 slides that can be used with up to 20 different primary antibodies, providing 12 staining protocols and additional 20 custom made protocols. The number and quality of slides, duration of staining procedure, and possible reduction in reagent utilization were compared. There was a significant increase in the number of observed slides between the two periods of observation, from 1507 to 2687 *per year*. The number of applied antibodies increased from 30 to 81. The time required for the procedure was reduced and standardization more easily achieved. Owing to the mentioned advancements, there was more time and personnel left for other activities including educational and scientific projects using immunohistochemical analysis.

DIAGNOSIS OF UROGENITAL TRICHOMONIASIS BY *TRICHOMONAS VAGINALIS* CULTIVATION – OUR TEN-YEAR EXPERIENCE

J. Lozić

Dr. Fran Mihaljević University Hospital of Infectious Diseases, Zagreb, Croatia

The value of our own modification of axenic cultivation of *Trichomonas (T.) vaginalis* on Diamond medium with the addition of nistatin was tested in a total of 15917 samples from patients with chronic disorders, including 12365 vaginal swabs, 2158 ejaculates collected over a 10-year period, and 1394 expressed prostate secretions collected

over a 3-year period. Analysis of the results obtained by cultivation according to days of incubation for 24, 48 and 72 hours revealed 1036 (8.38%) vaginal swabs, 264 (12.23%) ejaculates and 90 (6.45%) expressed prostate secretions to showed the growth of *T. vaginalis*. Besides native slide microscopy, the fastest method used in laboratory diagnosis of trichomoniasis, a negative finding yet requires completion of the diagnostic procedure by cultivation for the result to be considered definitive. Comparison with clinical observations showed cultivation to be a more appropriate and efficient method. Analysis of the results recorded during the period of 10 years showed the identification by cultivation to be three times superior to the native slide microscopy identification. The increased incidence of positive cultures during spring and fall in patients of both sexes could be explained by biologic and socioethologic patterns, and calls for additional studies.

CEREBROSPINAL FLUID IN PATIENTS WITH AIDS

A-M. Vitko

Dr. Fran Mihaljević University Hospital of Infectious Diseases,
Zagreb, Croatia

The aim of the paper is to present cytomorphological changes in the cerebrospinal fluid (CSF) of patients with the acquired immunodeficiency syndrome (AIDS). CSF cell count was done in a Fuchs-Rosenthal chamber and sedimentation in a Cytospin 3 (Shandan) at 700 rpm for 5 min, then the sediment was stained by the May-Grünwald-Giemsa (MGG) method. Cytomorphological analysis was done on an Olympus (1000X) optical microscope. In general, pleocytosis in the CSF of patients with neuro-AIDS was low or even normal (5-150 ccm). According to our observation, the cytomorphological changes in CSF were not characteristic. Mononuclear cells, which predominated, were lymphocytes and monocytes with a small number of their reactive forms and different types of particular phagocytes. Very often, some erythrocytes could be found. Cryptococcal meningitis is a frequent secondary infection of the central nervous system in AIDS patients, and this yeast can be seen in the CFS sediment stained by MGG as well as in the Indian ink preparation. The number of yeast has to be counted in a FR chamber. Low mononuclear pleocytosis with frequent findings of cryptococci very reliably leads to the diagnosis of neuro-AIDS.