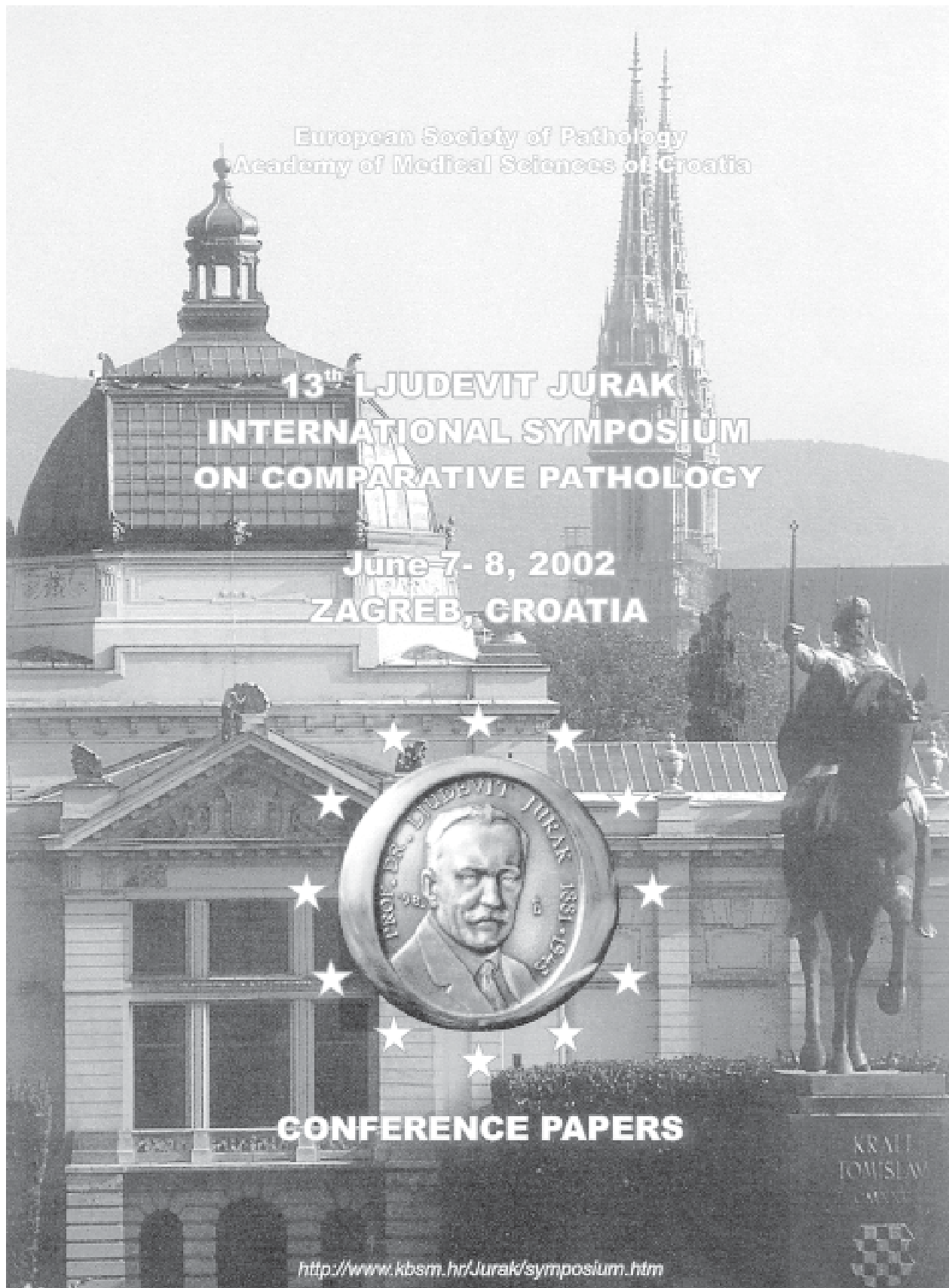

ROLE OF PATHOLOGISTS IN BREAST CANCER UNITS

G. Bussolati

Dept. Biomedical Sciences and Oncology, University of Turin, Turin, Italy

Pathologists are part of the core team of breast units, together with surgeons and radiologists. This means that they do not only play a diagnostic role for breast cancer, as used in the past, since they are requested for pre- and postoperative role in planning the therapeutic approach. Meetings for planning treatment of single cases are of basic importance, and also as an occasion for other specialists to understand our problems of morphological interpretation. Such meetings are a stimulus so that pathologists can better afford the new requests imposed by a rapidly changing scenario. One of the most compelling requests is reproducibility, and to achieve it pathologists must confront with diagnostic guidelines, definitions and landmarks. Guidelines produced by a group established by the EU of pathologists from different European countries involved in breast cancer screening proved effective in favoring reproducibility, as expressed by K statistics. However, in specific areas such as classification and definition of *in situ* lesions, such as atypical hyperplasia, reproducibility is far from ideal. Participation in a breast unit means highlighting of specific steps, which proved essential in a collaborative work and, ultimately, for the fight against breast cancer. Important steps are: identification of microcalcifications, definition of margins, diagnosis of *in situ* and microinvasive lesions, detection of metastatic spread. Problems are in fact not only related to morphological interpretations, but to communication as well. Examples are the diagnostic definition of fine needle aspirates and core biopsies, where the use of five standard categories (inadequate, benign; atypic, probably benign; suspect for malignancy, malignant) has proved effective in producing a preoperative diagnosis in conjunction with radiological and clinical criteria. The management, either cytologic or histologic of axillary lymph nodes and especially of sentinel nodes is a new challenge of both scientific and diagnostic impact. Similarly, the evaluation of the prognostic and therapeutic parameters such as HER2 overexpression/

amplification poses new budgetary problems which have to be solved by pathologists not only through diagnostic skill, but on the basis of organization and collaboration as well.

SOFT TISSUE TUMORS OF THE BREAST

V. Eusebi

Anatomic and Surgical Pathology of the University of Bologna, Ospedale Bellaria, Bologna, Italy

Benign and malignant soft tissue tumors of the breast will be presented. Lipomas are the most common benign soft tissue tumors of the breast. When glandular tissue is entrapped within a lipoma, the lesion qualifies as adenolipoma or adenohebernoma according to the type of adipose tissue. The first case of angiomyolipoma HMB 45 positive will be illustrated. A unifying concept concerning solitary fibrous tumors, myofibroblastomas and spindle cell lipomas will be presented. The term of benign spindle stromal cell tumor (BSST) will be proposed for these lesions that are amenable to a common precursor cell of the breast stroma that is vimentin and CD 34 positive. Accordingly, the concept of malignant spindle stromal cell tumors (MSST) will be presented along the line of the benign counterpart. Angiosarcomas will be discussed with emphasis on the Stewart Treves syndrome.

MALIGNANT LYMPHOMA OF THE BREAST

J. Lamovec

Institute of Oncology, Ljubljana, Slovenia

Malignant lymphomas of the breast are a rare disease. They may occur as primary or secondary tumors. Morphologically, it is not possible to determine their primary or secondary nature¹.

The criteria for defining a lymphomatous lesion in the breast as primary were first proposed by Wiseman and Liao in 1972²: 1) availability of adequate histologic material; 2) documentation of breast involvement as a primary site; 3) presence of breast tissue in or adjacent to

lymphoma infiltrate; 4) no concurrent nodal disease except for the involvement of ipsilateral axillary lymph nodes; and 5) no previous history of lymphoma involving other organs or tissues.

Strictly adhering to such criteria, some primary breast lymphomas may be lost since no allowances are made for those primary breast lymphoma cases that may present in higher clinical stages. Obviating this, some authors consider as primary breast lymphomas all those cases in which breast is the first or major site of presentation even though subsequent staging procedures reveal involvement of other sites, such as bone marrow³.

Clinical Presentation

The lesion most commonly presents as a unilateral breast mass in postmenopausal women (median age 55 to 60 years), although it may occur at any age. In about 10% of cases, it is bilateral. In men, breast lymphoma is exceedingly rare.

A subset of patients, characteristically from tropical Africa, are young women, during or immediately after pregnancy, who present with massive bilateral breast swelling. The latter disease is endemic in this part of the world. Histologic examination in these patients reveals Burkitt's or Burkitt-like lymphoma⁴. Non-African cases of this type of lymphoma are also on record.

The incidence of primary breast lymphoma ranges from 0.04% to 0.5% of breast malignancies in most published series^{1,3,5}. The incidence of secondary lymphoma in the breast is difficult to ascertain, since many of those lesions are but one manifestation of disseminated disease and are never biopsied.

Gross Features

Primary and secondary breast lymphomas usually present grossly as a well defined uni- or multinodular mass of soft or firmer white-gray tissue, sometimes with necrotic and hemorrhagic foci. The tumor varies in size and may attain up to 20 cm in diameter.

Histopathology

The vast majority of breast lymphomas are diffuse large cell B lymphomas as defined by recent WHO clas-

sification. The latter lymphomas were given different names in older classification schemes, such as reticulum cell sarcoma, histiocytic lymphoma, large cell cleaved or noncleaved lymphomas, centroblastic or immunoblastic lymphoma, etc. In addition to large cell B lymphomas, a variety of other types of lymphoma may also manifest as primary or secondary tumors in the breast.

The relation of pre-existing mammary tissue and infiltrating lymphoma varies. In some cases, the bulk of the tumor is located in subcutaneous fatty tissue and breast parenchyma is at its periphery; in other cases, the ducts and lobules of breast tissue are embedded in the infiltrate, while in rare cases pre-existent tissue is overgrown by lymphoma and barely visible. In such cases, remnants of ducts and lobules may only be revealed by using keratin immunostaining. Stroma may be scant or more abundant, sometimes sclerotic and hyalinized. Although most of the tumors are grossly circumscribed, a microscopically different degree of infiltration of the surrounding tissue is always evident.

Diffuse large cell B lymphoma^{1,3,5-8}: This type of lymphoma is characterized by large lymphoma cells with oval or indented nuclei, with one to three nucleoli and with a narrow rim of basophilic cytoplasm; such cells generally resemble centroblasts. Different number of immunoblasts are frequently admixed, sometimes such cells are predominant. Mitoses are usually numerous. In some cases, cells appear more pleomorphic with wider variation in cell forms and sizes; smaller reactive lymphocytes of B or T types are also present in the infiltrate. Occasionally, reactive histiocytes are numerous, imparting a "starry sky" appearance to the tumor. Adjacent mammary tissue may exhibit lobular atrophy or lymphocytic lobulitis which may be very prominent (lymphocytic mastopathy).

Lymphoma cells are immunoreactive for CD20, CD79a, CD45RB, and negative for CD3 and CD45RO. Cases with immunoblastic features may show light chain restriction. Exceptionally, lymphoma cells may express CD30 antigen.

Follicular lymphoma^{1,3,5,7,8}: It features neoplastic follicles composed of centrocytes and centroblasts in different proportions and may be graded into 2 or 3 grades, depending on the number of centroblasts inside the neoplastic follicles. Immunohistochemically, the lymphoma cells show positivity for B cell antigens, and for CD10 and bcl-2, and are negative for CD5 and CD23. Follicular dendritic cells in tight clusters, positive for CD21, delineate neoplastic follicles. Selective infiltration of ductal-lobu-

lar units by lymphomas of other types, such as diffuse large cell B lymphoma may mimic neoplastic follicles and could be confounded for true follicular lymphoma.

Burkitt's lymphoma^{4,8}: The infiltrate in this lymphoma is composed of medium-sized cells with round nuclei, multiple central nucleoli, coarse chromatin and rather thick nuclear membrane. The cytoplasm is moderate in amount, basophilic with fine vacuoles containing lipids. Mitoses are very numerous. Cells grow in a cohesive pattern, they square off with each other. Numerous tingibody macrophages are evenly scattered among lymphoma cells producing characteristic but in no way pathognomonic "starry sky" appearance of the lymphoma. The breast parenchyma is usually hyperplastic and secretory. Ki-67 fraction of viable cells is 100%.

Immunohistochemically, pan-B markers are positive, surface immunoglobulins, usually of IgM type, are also positive, while CD5, bcl-2, and TdT are negative. EBV is frequently demonstrated in endemic but not in sporadic cases. IgH and IgL genes are rearranged.

Burkitt-like lymphoma is similar in morphological appearance but immunoblast and centroblast-like cells are also admixed.

Extranodal marginal-zone B-cell lymphoma of MALT type^{1,3,5}: An undetermined number of breast lymphoma cases belong to the category of MALT lymphoma. The breast is considered to be part of a common mucosal immune system⁹ and may, during an autoimmune process, acquire lymphoid tissue in lymphoma. Most recent series of breast lymphoma have some cases of MALT lymphoma included. Typically, lymphoma of this type is composed of small lymphocytes, monocytoid (marginal zone type) cells and plasma cells. The latter may dominate the whole microscopic aspect of the lesion. Larger blast type cells may also be present. The infiltrate may be vaguely nodular, reactive follicles may be seen, some of them colonized by monocytoid cells. The lymphoepithelial lesion, i.e. infiltration of the ductal/lobular epithelium by monocytoid (centrocyte-like) cells was originally overestimated as a diagnostic criterion for MALT lymphoma of the breast; its presence is not a prerequisite for diagnosis. Furthermore, it has become increasingly evident that breast epithelium is infiltrated by lymphoma cells of a variety of lymphomas and even more commonly by T reactive cells admixed to lymphomatous infiltrate. Immunohistochemically, MALT lymphoma cells express pan-B markers such as CD20 and CD79a, it is usually bcl-2 positive but negative for CD10, CD5, and CD23. The translocation t(11;18)(q21;q21) has been identified in many MALT

lymphomas; analysis did not include breast cases¹⁰. The same holds true for recently described trisomy 3 identified in a number of MALT lymphomas¹¹. Breast may also be involved by secondary MALT lymphoma originating at another MALT site.

Some other types of lymphoma may also rarely present in the breast, as primary or secondary lesions, including lymphoblastic lymphoma of either B or T type, extremely rarely peripheral T cell lymphoma, and secondary small lymphocytic lymphoma/CLL or mantle cell lymphoma.

Differential Diagnosis

Large cell malignant lymphomas may, in certain instances, be misdiagnosed as poorly differentiated duct or lobular carcinoma. Immunohistochemical reactions for keratin resolve any possible dilemma in such cases. Myeloid cell tumors may also be confounded for malignant lymphomas; if basic immunoreactions are inconclusive, myeloperoxidase staining to exclude the former possibility should be used. Inflammatory conditions may mimic MALT lymphomas; in some cases immunohistochemical reactions, flow cytometry and molecular genetic analysis should be employed to determine clonality of the lesion. Reactive follicular hyperplasia can be differentiated from follicular lymphoma by using bcl-2 immunoreactions; reactive follicles are bcl-2 negative. The issue of so-called pseudolymphoma remains unresolved; many authors believe that they really represent MALT type lymphoma.

Prognosis and Treatment

Primary breast lymphoma behave in a similar way as lymphomas of corresponding types and stages in other localizations. Localized low-grade lesions, such as MALT type lymphomas, are treated locally by surgery and/or radiation; high grade tumors require systemic chemotherapy with or without irradiation.

References

1. MATTIA AR, FERRY JA, HARRIS NL. Breast lymphoma. A B-cell spectrum including low grade B-cell lymphoma of mucosa associated lymphoid tissue. *Am J Surg Pathol* 1993;17:574-87.
2. WISEMAN C, LIAO KT. Primary lymphoma of the breast. *Cancer* 1972;29:1705-12.

3. HUGH JC, JACKSON FI, HANSON J, POPPEMA S. Primary breast lymphoma. An immunohistologic study of 20 new cases. *Cancer* 1990;66:2602-11.
4. SHEPHERD JJ, WRIGHT DH. Burkitt's lymphoma presenting as bilateral swelling of the breast in women of child-bearing age. *Br J Surg* 1967;54:776-80.
5. LAMOVEC J, JANCAR J. Primary malignant lymphoma of the breast. Lymphoma of the mucosa-associated lymphoid tissue. *Cancer* 1987;60:3033-41.
6. ABBONDANZO SL, SEIDMAN JD, LEFKOWITZ M, TAVASSOLI FA, KRISHNAN J. Primary diffuse large B-cell lymphoma of the breast. A clinicopathologic study of 31 cases. *Pathol Res Pract* 1996;192:37-43.
7. BOBROW LG, RICHARDS MA, HAPPERFIELD LC, ISAACSON PG, LAMMIE GA, MILLIS RR. Breast lymphomas: a clinicopathologic review. *Hum Pathol* 1993;24:274-8.
8. LIN Y, GOVINDAN R, HESS JL. Malignant hematopoietic breast tumors. *Am J Clin Pathol* 1997;107:177-86.
9. BIENENSTOCK J, BOFUS AD. Review: mucosal immunology. *Immunology* 1980;41:249-70.
10. OTT G, KATZENBERGER T, GREINER A, KALLA J, ROSENWALD A, HEINRICH U, OTT MM, MULLER-HERMELINK HK. The t(11;18)(q21;q21) chromosome translocation is a frequent and specific aberration in low-grade but not high-grade malignant non-Hodgkin's lymphomas of the mucosa-associated lymphoid tissue (MALT) type. *Cancer Res* 1997;57:3944-8.
11. WOTHERSPOON AC, FINN TM, ISAACSON PG. Trisomy 3 in low-grade B-cell lymphomas of mucosa-associated lymphoid tissue. *Blood* 1995;85:2000-4.

RECENT ADVANCES IN MOLECULAR GENETICS OF BREAST CANCER

K. Pavelić, K. Gall-Trošelj
Ruđer Bošković Institute, Division of Molecular Medicine, Zagreb, Croatia

Breast cancer is among the most common tumors affecting women. It is characterized by a number of genetic aberrations. Five to 10% of all cases are estimated to be inherited. The hereditary breast and ovarian cancer syndrome includes genetic alterations of various susceptibility genes, particularly BRCA 1 and BRCA 2. Breast tumors in patients with a germ-line mutations in the BRCA 1 and BRCA 2 gene have an increase in additional genetic defects compared with sporadic breast tumors. Accumulation of somatic genetic changes during tumor progression may follow a specific and more aggressive pathway of chromosome damage in these individuals. Recent advances in genomics and bioinformatics, particularly in DNA-sequencing approaches and DNA-chip technology are revolutionizing target identification of small molecules. Here we review some new findings in the function of BRCA 1 gene function. A major BRCA 1 downstream

target gene is the DNA damage-responsive gene GADD 45. Induction of BRCA 1 triggers apoptosis through activation of c-Jun N-terminal kinase/stress-activated protein kinase (JNK/SAPK). BRCA 1 interacts with the SWI/SNF complex which controls DNA structure. SWI/SNF is a chromatin remodeling complex important in gene expression. New knowledge about the genetic portrait of breast tumor is coming from differential gene expression profiling using microarrays. Human genome studies as well as development of "DNA chips" provide a window for observing patterns of gene activity in cells, which will revolutionize cancer classification. Knowledge of the molecular characteristics of breast tumor has already made it possible to identify those breast cancer patients who could benefit from therapies that target these features. Progress in basic research in signaling provides the opportunity to attack signal-transduction targets involved in proliferation, survival, invasion, angiogenesis, metastasis and resistance. Exciting knowledge in breast cancer biology is rapidly accumulating in parallel with recent developments in rational selection and validation of relevant targets that provide unique opportunities for development of "intelligent" therapeutics.

IDENTIFICATION OF NEW MOLECULAR TARGETS FOR THE TREATMENT OF BREAST CANCER

E. A. G. Blomme¹, F. Del Piero², K. L. Kolaja¹
¹Pharmacia Corporation, Molecular and Experimental Toxicology and Pathology, Skokie, IL, USA, and
²University of Pennsylvania, School of Veterinary Medicine, Department of Pathobiology and Department of Clinical Studies, New Bolton Center, PA, USA

SUMMARY - The completion of the human genome sequence provides unique opportunities to identify new molecular targets for a variety of diseased conditions, especially for neoplastic diseases. Breast cancer is an ideal disease for the implementation of the recently developed, sophisticated genomic technologies, which permit the study of expression of many genes or proteins simultaneously, an approach known as molecular profiling. This approach is considered a major step forward in the development of new drugs that are more effective and less toxic than the current generation of antitumor agents. In this paper, we briefly review the current and future genomics

technologies, such as DNA microarrays and proteomics techniques, and their use in the identification of new molecular targets for the treatment of breast cancer. We also discuss the challenge associated with the development of bioinformatics tools to analyze the massive number of data points generated by these technologies. Proof of principle is now emerging, demonstrating that selective agents against abnormal or mutated gene products can indeed be useful in the treatment of cancer. However, despite heavy investment in genomics research by the pharmaceutical industry, the full impact of genomics on drug discovery has yet to be fully demonstrated.

Key words: *Genomics; Microarrays; Proteomics; Molecular target*

Introduction

The completion of the human genome sequence provides a quantum lead towards identifying new molecular targets for a variety of diseased conditions, especially for neoplastic diseases^{1,2}. The repositories of genes and their regulatory sequences represent the starting point of a new challenge, understanding how the 30,000-40,000 genes present in the human genome and their protein products interact and function. In addition of providing the unique opportunity to better understand basic biology and to identify the molecular basis of diseases, the annotation of the human genome offers the promise of an increased rate of drug discovery and development.

Breast cancer is a major health problem worldwide and consequently, a large amount of research effort has been focused on the molecular understanding of this disease³. The medical treatment of cancer still has many unmet needs⁴. The main curative therapies (surgery and radiation) are usually successful only at an early stage, and existing chemotherapeutic treatments are largely palliative. The majority of the current antitumor agents have been unveiled during screening in cytotoxicity assays, although some have also been designed to act on defined molecular targets. However, none of the established cancer drugs were developed in the light of a clear understanding of the molecular differences between neoplastic and normal cells. Breast cancer is an ideal disease for the implementation of the recently developed, sophisticated genomic technologies, which permit to study the expression of many genes or proteins simultaneously, an approach known as molecular profiling. This approach is considered a major

step forward in the development of new drugs that are more effective and less toxic than the current generation of antitumor agents. In this paper, we will review the application of genomic technologies for the rational identification of new therapeutic targets for breast cancer.

DNA Microarray and Molecular Transcription Profiling

Molecular transcription profiling is the large-scale analysis of gene expression using DNA array technologies^{5,6}. DNA microarrays have only been recently introduced to the scientific community⁷. Microarrays consist of rows and rows of microscopic spots, each of which contains an identical single-stranded polymeric molecule of deoxyribonucleotide (typically oligonucleotides or cDNAs, the probe) attached to a solid support, such as a glass slide or a miniature silicon chip. These arrays can accommodate up to tens of thousands of spots and can be used for high-throughput studies of genomic structure and studies of active gene expression. Figure 1 provides an illustration of these DNA arrays. These arrays use the principle of specific DNA base pairing, i.e. A-T and G-C, to allow the large-scale analysis of mRNA abundance as an indicator of gene expression, to detect polymorphisms within a population, or to detect new genes, as unknown DNA sequences can be analyzed⁸. Over the past few years, a number of different commercially available array products have been introduced. Although most of these products remain relatively expensive, their cost is regularly decreasing, and these products should soon become affordable for most laboratories. Therefore, it is critical that most cancer scientists become familiar with this technology. Recently, customized or in-house microarrays have grown in popularity to help investigators focus on their particular area of interest without being distracted by the huge volume of data generated by some commercial microarrays⁹. It should be mentioned that, although the microarray technology is the most widely used technique for gene expression analysis, others are available, including serial analysis of gene expression (SAGE), differential hybridization, differential display or GeneCalling¹⁰.

The application of arrays to genomic studies includes the search for single nucleotide polymorphisms (SNPs) and a powerful application of these studies is in the field of pharmacogenomics⁶. Because each individual has a slightly different genetic makeup, each will have a unique set of SNPs. SNPs are the most frequent form of genetic

DNA Microarray for Gene

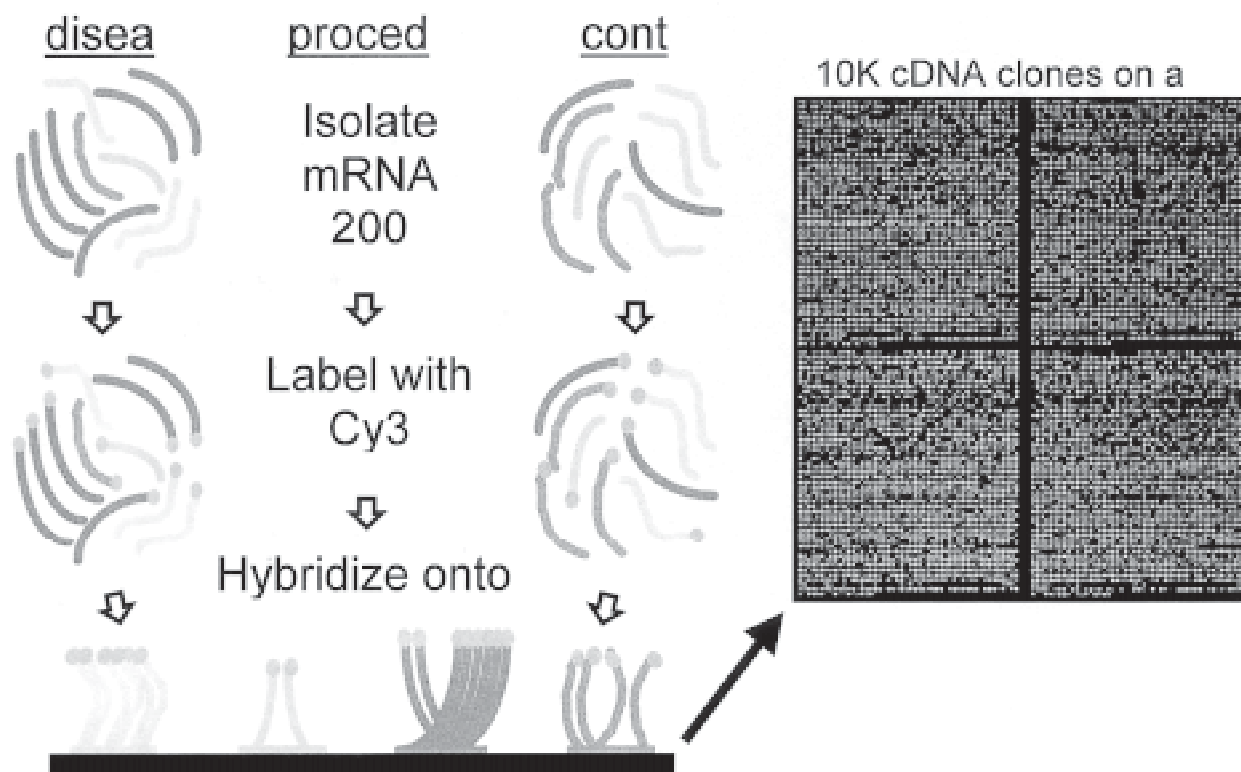


Fig. 1. Gene expression analysis using DNA microarrays. In this example, a two-color microarray is used to analyze transcriptional profiling differences between a diseased tissue and its corresponding normal tissue. RNA is extracted from both the diseased and the normal tissues, each RNA is labeled with a fluorescent probe (in this case a red fluorescence probe, Cy5, for the diseased tissue and a green fluorescent probe, Cy3, for the normal tissue), and both labeled RNAs are hybridized together on the same microarray. Competitive binding to the thousands of probes printed as microscopic spots on a glass slide leads to a differential fluorescence for each spot based on expression levels of particular genes. For instance, if a particular gene is expressed at higher levels in the normal tissue compared to the diseased tissue, the spot where the corresponding probe is printed will appear green. In contrast, if a particular gene is expressed at lower levels in the normal tissue, the spot will be red. Finally, if a particular gene is expressed at similar levels in both tissues, the two fluorescent colors will blend to form a new color (yellow). DNA microarrays typically accommodate up to tens of thousands of spots and are now routinely used for high-throughput studies of active gene expression in diseased tissues. This genomics tool enables scientists to identify previously unrecognized therapeutic targets in a rapid and efficient manner.

variation (~3 million/person or approximately 1 SNP/kb), are highly stable, and are relatively easy to identify. Programs to detect and map SNPs in the human genome are well underway with the ultimate aim of establishing a SNP map of the genome¹¹. When SNP analysis is used in conjunction with analytical techniques, such as genetic-linkage mapping or association analysis, a genetic propensity for predisposition to disease, unique metabolism, or adverse events can be identified. Although these SNPs may not be the actual cause of disease, their utility lies in their potential to help predict how an individual may respond to a particular drug. Pharmacogenomics may, therefore,

help identify at-risk patients prior to treatment and prevent adverse drug reactions. Furthermore, SNPs may be useful to predict whether a certain drug would be effective in a patient with a specific disease. Although most marketed drugs are efficacious in a vast majority of the patient population, pharmacogenomics offers an opportunity to resurrect drugs that have been discarded because of low efficacy or adverse effects in the entire patient population. In this regard, pharmacogenomics can undoubtedly contribute to a better design of clinical trials in the future.

Molecular transcription profiling analyses have already profoundly enhanced our understanding of many diseases,

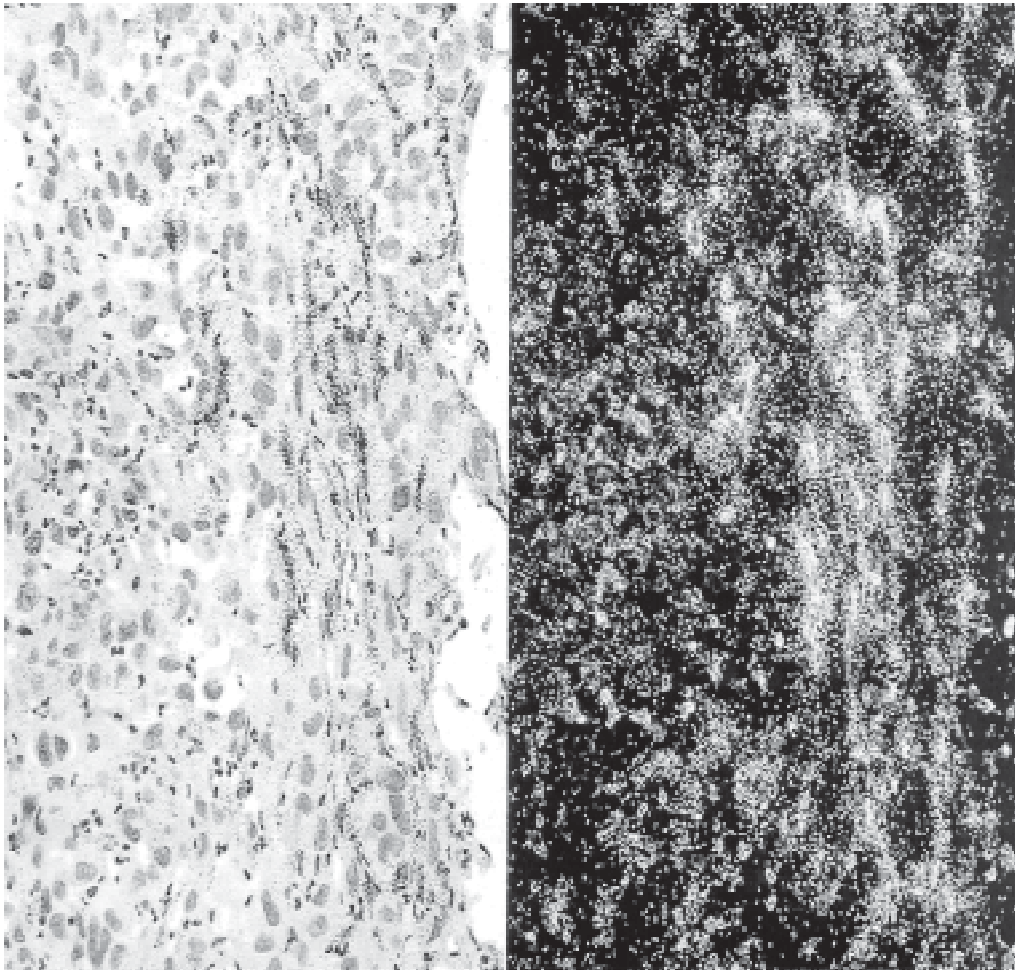


Fig. 2. Validation of a molecular target by radioactive in situ hybridization. A critical step after the identification of a putative therapeutic target is to validate the target's relevance to the disease process. In this example, a specific mRNA (product of gene X) was shown to be upregulated 5-fold in a neoplasm compared to normal tissue using DNA microarrays. This gene was, therefore, considered a putative therapeutic target. Since no commercial or proprietary antibodies were available against the protein products, radiolabeled riboprobes specific for this mRNA were generated by in vitro transcription after cloning of the cDNA. These riboprobes were used to evaluate expression of this gene product in tissue sections. In this particular example (a breast tumor), the gene appears to be up-regulated and specifically expressed in endothelial cells, suggesting that this gene product may be involved in angiogenesis. Further validation work, using in vitro transfection experiments, confirmed the role of this gene product in angiogenesis.

including breast cancer^{5,12,13}. Cell function can be best understood by determining the transcription level of all genes in the genome (the transcriptome). The next step for transcriptional analysis will be the rapid identification and evaluation of potential therapeutic targets. In cancer, the accumulation and combinatorial effects of abnormalities, driving the initiation and progression of cancer, result from mutations and/or changes in expression level of cancer-causing genes¹⁴. Therefore, therapeutic agents that would target the key molecular abnormalities that lead to malignant progression, have the potential of being more selective than the current non-specific cytotoxic agents, and

therefore, more efficacious and less toxic. Proof of principle is now emerging that these selective agents can indeed be useful for the treatment of cancer¹⁴. For instance, the HER-2/neu oncogene is overexpressed in approximately 30 percent of breast cancers, and these tumors are more aggressive and somewhat more resistant to chemotherapy than those not overexpressing the oncogenes¹⁵. These observations have led to the development of a monoclonal antibody (Herceptin® or trastuzumab) against the extracellular domain of this receptor tyrosine kinase⁴. Several clinical trials have demonstrated an improved response rate, a prolongation of the time to disease progression, and an increased

overall survival compared to the standard of care, demonstrating the power of this genes-to-drugs paradigm for drug discovery. Herceptin® was approved by the U.S. Federal Drug Administration (FDA) in 1998 for the treatment of HER-2-positive breast cancer. Other receptor tyrosine kinases are frequently overexpressed in cancer. Therefore, several epidermal growth factor (EGF) receptor tyrosine kinase inhibitors, such as ZD-1839 (Iressa®), are currently being developed for the treatment of various cancer types, and results of preclinical studies and preliminary clinical trials indicate that the EGF receptor is indeed a valid target for anticancer therapy^{16,17}. Because microarray technologies examine the expression profile of thousands of genes simultaneously at the mRNA level, it is now possible to study the sum total differences in gene expression between normal and diseased cells. This clearly will lead to the identification of new subtypes of tumors and will not only help the pathologist provide a more refined biological-based diagnosis, but will also enable scientists to identify previously unrecognized therapeutic targets in a rapid and efficient manner^{9,13,18}.

Proteomics

A major limitation of transcript profiling is that transcriptional activity does not necessarily reflect the activity of the protein product of a particular gene. This is mostly due to variation in cellular location and to complex and versatile protein regulation mechanisms, such as context-dependent post-translational phosphorylation, sulphation and glycosylation⁵. In addition, assigning a role for a protein based on a gene sequence information is not always feasible, because gene sequence reveals little information about protein function and disease relevance¹⁹. Therefore, a recent focus has been shifted towards proteomics, a protein-based approach to provide functional and expression information for proteins on a genome-wide scale (the proteome).

Currently, the proteomics tools consist mostly of electrophoresis or chromatography coupled with mass spectrometry¹⁹. Several new technologies have recently been introduced for high-throughput protein characterization and discovery, such as protein arrays and proteome-scale screens for generic enzyme activities (e.g., protease and phosphatase)¹⁹. Applying these technologies to various diseases, and to breast cancer in particular, can work in concert with genomic technologies to identify new potential therapeutic targets. The challenge facing proteomics

is, however, enormous, since it is estimated that approximately 75 percent of proteins in multicellular organisms have, as of yet, no known cellular function. Furthermore, human genes are fairly complex, incorporating variable numbers of protein domains into sophisticated functional products, with further protein diversity provided by alternative splicing¹⁷. Finally, protein-based technologies are extremely low throughput and more challenging to develop compared to transcription profiling techniques.

Laser Capture Microdissection

Genomic and proteomic analysis of cells in their native environment can provide the most accurate picture of the alterations that occur *in vivo* during the disease state. *In vitro*, cells are not subject to the endocrine and paracrine signals that regulate their overall behavior. However, studying tissues is not an easy task, mostly because tissues are complex three-dimensional structures, composed of large numbers of perpetually interacting cell populations. In the case of breast cancer, neoplastic cells may only account for a small proportion of the tissue analyzed, and the overall genomic and proteomic analyses may be confounded by the presence of large numbers of non-neoplastic cells, such as fibroblasts, endothelial cells or macrophages.

To overcome these confounding factors, powerful analytical algorithms have been developed to gauge the relative abundance of an unknown cell subpopulation within tissue samples. Such algorithms use known genes associated with particular subpopulations of cells as reference values to estimate the proportion of cancer cells, stromal cells and inflammatory cells⁵. An alternative to the use of these algorithms is the implementation of microdissection techniques. Laser capture microdissection (LCM) is a technology for rapid and easy procurement of a microscopic and pure cell subpopulation from its complex tissue milieu¹². The advantage is that LCM permits the investigator to focus directly on the disease subpopulation or compare several subpopulations of tissue cells from the same patient's sample. In addition, recent data suggest that LCM would allow quantitative gene expression analysis in formalin-fixed, paraffin-embedded tissues, allowing to take advantage of large numbers of archived pathological tissue specimens²⁰. The disadvantages of LCM are that it is resource intensive and provides only limited amounts of cellular material to study, although the recent development of reliable amplification protocols has partially solved this problem¹². LCM has been successfully applied in the study

of breast cancer pathogenesis and the identification of potential therapeutic targets, and it is likely that this technology will become a necessary component of the drug discovery process, as well as the cancer biology laboratory.

Target Validation

A critical step after the identification of a putative therapeutic target is to validate the target's relevance to the disease process²¹. An important part of this validation step can be achieved through the development of appropriate preclinical animal disease models. In particular, scientists now have the ability to genetically manipulate the mouse through transgenesis and gene targeting to test hypotheses regarding gene function and their role in disease. These knockout or transgenic mouse models (an important part of functional genomics) provide a powerful tool to the gene-to-drug paradigm for drug discovery²². The literature contains an enormous number of examples where a genetically engineered mouse model has helped better define the relevance of a specific gene product in a disease model. For instance, p53 knockout mice rapidly develop neoplasms in various tissues, as seen in patients with the Li-Fraumeni syndrome who have germline mutations of p53²³⁻²⁵. Other molecular tools are also available for target validation in animal models, such as antisense oligonucleotides, ribozymes and neutralizing antibodies^{4,26}.

Another method used to validate a target for breast cancer is analysis of its expression in a large population of breast tumors by immunohistochemistry and/or *in situ* hybridization¹⁰. While such a validation step can still be achieved analyzing one slide at a time, this can be very tedious and laborious. Hence, the recent development of tissue microarrays to increase the throughput of the process²⁷. Tissue microarrays consist of hundreds to thousands cylindrical tissue biopsies, ranging from 0.6 up to 4 mm in diameter, each from a different patient, all distributed on a single glass slide. The tissue microarray technology has been tested and validated in several cancer types, including breast cancer²⁸. The data confirmed many of the clinicopathological correlation of gene amplifications or immunostaining reactions reported with conventional techniques on the basis of whole tumor analysis⁵. Full automation of tissue array creation and screening is being developed to expeditiously validate the large numbers of newly identified potential therapeutic targets for cancer treatment.

Bioinformatics

While the cancer biologist will definitely benefit from these new technologies, it is clear that one of the major current challenges is to develop informatics techniques to facilitate the processing and analysis of this large amount of data. Interpretation of data and the development of models that facilitate the understanding of specific biological phenomena have become priorities. A common characteristic of contemporary drug discovery projects is their increasing complexity compared to the past, where discovery efforts were largely dominated by chemistry and pharmacology. Genomics techniques have led to the creation of a new research discipline, called bioinformatics.

Initially, the focus of bioinformatics was on the analysis, processing, and archiving of genomic sequence data. Because of the rapid progress of the large-scale genome sequencing projects culminating in a "first draft" of the human genome, bioinformatics is now moving from the genome to the transcriptome and proteome level, with the focus shifting from the evaluation and annotation of genomic sequence data to the analysis of actual gene products²⁹. The use of DNA microarrays generates a massive number of individual data points, which must then be analyzed by using data mining tools sufficiently sophisticated to categorize all these data group them in a meaningful manner⁸. These analytical tools are aimed toward the hunting of potential drug targets, the deciphering of possible cellular pathways, and the generation of hypotheses regarding the potential roles of certain genes. Protein-focused bioinformatics efforts aim to better understand the cellular expression, post-translational modifications, family relationships, structures and functions of proteins, as well as to evaluate their potential as suitable drug targets²⁹.

Several private and public databases exist for genome mapping, nucleic acid and protein sequences, and protein structures. In particular, Internet resources provide invaluable information and make available databases with relevance to drug discovery and genomic technologies²¹. For instance, the DNA sequence information available in these public databases can be used to identify transcripts differentially expressed in normal breast epithelial cells and breast tumor cells³⁰. Similar approaches can easily be adapted and applied to other tumor types with sufficient transcript sequences available in the public databases.

Conclusion

In drug discovery, initial expectations of new technologies are often too high. Despite large-magnitude efforts and resource commitments to new technologies (such as high-throughput screening and combinatorial chemistry) in the last decade, our ability to produce high-quality drug candidates has not become significantly enhanced. Obviously, the long period of time it takes for novel drugs to reach the market makes it very difficult to assess the immediate impact of a technology. In the 1990s, the primary goal of genomics research in the pharmaceutical industry was to increase the number of identified molecular targets and to gain proprietary rights to use those targets³¹. This goal has partly been successful: many more targets have been identified, intellectual property abounds, and proof of principle that these targets are valid has been demonstrated. However, an increased productivity of the pharmaceutical industry has yet to be demonstrated. Will genomics have its expected impact on drug discovery? First, it is important to remember that these technologies add a substantial new level of complexity to the drug discovery process, which will require the formation of large multidisciplinary teams to properly integrate these tools in the existing drug discovery and development process. In addition, in the drug discovery and development process, a long road with many hurdles separate the identification of a relevant gene target and the regulatory approval of an innovative drug: is the new gene a drugable target? Can adequate pharmacokinetic properties be achieved? Does the drug modulate the target in patients? Are there side effects and if so, are they manageable? Is there significant therapeutic benefit? What biomarker can be used to quickly predict efficacy? Are combinatorial genome-based therapies necessary for efficacy? What is the appropriate patient population? While drug development has not become much easier or faster, the promise of a major impact of genomics on drug discovery is still largely intact: it is likely that the genomics technologies will provide scientists with a large new collection of molecular targets for the treatment of various diseases, including breast cancer. However, success will require the proper and effective use of complementary technologies, expertise and innovative design of clinical trials, and proper integration of these various aspects is likely to become the definitive competitive advantage to pharmaceutical companies.

References

1. International Human Genome Sequencing Consortium. Initial sequencing and analysis of the human genome. *Nature* 2001;409:860-921.
2. VENTER JC, ADAMS MD, MYERS EW, LI PW, MURAL RJ, SUTTON GG, *et al.* The sequence of the human genome. *Science* 2001;291:1304-51.
3. HORTOBAGYI GN. Treatment of breast cancer. *N Engl J Med* 1998;339:974-84.
4. GIBBS J. Mechanism-based target identification and drug discovery in cancer research. *Science* 2002;287:1969-73.
5. LIOTTA L, PETRICOIN E. Molecular profiling of human cancer. *Nat Rev Genet* 2000;1:48-56.
6. GRAVES DL. Powerful tools for genetic analysis come of age. *Trends Biotechnol* 1999;17:127-34.
7. SCHENA M, SHALON D, DAVIS RW, BROWN PO. Quantitative monitoring of gene expression patterns with a complementary DNA microarray. *Science* 1995;270:368-9.
8. MAUGHAN NJ, LEWIS FA, SMITH V. An introduction to arrays. *J Pathol* 2001;195:3-6.
9. ALIZADEH AA, ROSS DT, PEROU CM, Van de RIJN M. Towards a novel classification of human malignancies based on gene expression patterns. *J Pathol* 2001;195:41-52.
10. PEALE FVJR, GERRITSEN ME. Gene profiling techniques and their application in angiogenesis and vascular development. *J Pathol* 2001;195:7-19.
11. BENTLEY DR. The human genome project: an overview. *Med Res Rev* 2000;20:189-96.
12. SGROI DC, TENG S, ROBINSON G, LeVANGIE R, HUDSON JR, ELKAHLOUN AG. *In vivo* gene expression profile analysis of human breast cancer progression. *Cancer Res* 1999;59:5656-61.
13. LAKHANI SR, ASHWORTH A. Microarray and histopathological analysis of tumours: the future and the past? *Nat Rev* 2001;1:151-7.
14. CLARKE PA, te POELE R, WOOSTER R, WORKMAN P. Gene expression microarray analysis in cancer biology, pharmacology, and drug development: progress and potential. *Biochem Pharmacol* 2001;62:1311-36.
15. SLAMON DJ, CLARK GM, WONG SG, LEVIN WJ, ULLRICH A, McGUIRE WL. Human breast cancer: correlation of relapse and survival with amplification of the HER-2/neu oncogene. *Science* 1987;235:177-82.
16. ADJEI AA. Epidermal growth factor receptor tyrosine kinase inhibitors in cancer therapy. *Drugs Fut* 2001;26:1087-92.
17. WORKMAN P, CLARKE PA. Innovative cancer drug targets: genomics, transcriptomics and clinomics. *Expert Opin Pharmacother* 2001;2:911-5.
18. ALIZADEH AA, EISEN MB, DAVIS RE, MA C, LOSSOS IS, ROSENWALD A, *et al.* Distinct types of diffuse large B-cell lymphoma identified by gene expression profiling. *Nature* 2000;403(6769):503-11.
19. EDWARDS AM, ARROWSMITH CH, des PALLIERES B. Proteomics: new tools for a new era. *Modern Drug Discov* 2000;3:36-44.

20. SPECHT K, RICHTER T, MUELLER U, WALCH A, WERNER M, HOEFLER H. Quantitative gene expression analysis in microdissected archival formalin-fixed and paraffin-embedded tumor tissue. *Am J Pathol* 2001;158:419-29.
21. SAWYER TK. Deciphering therapeutic targets. *Biotechniques* 2001;30:1086-90.
22. WEST DB, IAKOUGOVA O, OLSSON C, ROSS D, OHMEN J, CHATTERJEE A. Mouse genetics/genomics: an effective approach for drug discovery and validation. *Med Res Rev* 2000;20:216-30.
23. DONEHOWER LA, HARVEY M, SLAGLE BL, McARTHUR MJ, MONTGOMERY CAJR, BUTEL JS *et al*. Mice deficient for p53 are developmentally normal but susceptible to spontaneous tumors. *Nature* 1992;356:215-21.
24. HARVEY M, McARTHUR MJ, MONTGOMERY CAJR, BUTEL JS, BRADLEY A, DONEHOWER LA. Spontaneous and carcinogen-induced tumorigenesis in p53-deficient mice. *Nat Genet* 1993;5:225-9.
25. VARLEY JM, EVANS DG, BIRCH JM. Li-Fraumeni syndrome: a molecular and clinical review. *Br J Cancer* 1997;76:1-14.
26. TAYLOR MF. Target validation and functional analyses using antisense oligonucleotides. *Expert Opin Ther Targets* 2001;5:297-301.
27. KONONEN J, BUBENDORF L, KALLIONIEMI A, BARLUND M, SCHRAML P, LEIGHTON S, *et al*. Tissue microarrays for high-throughput molecular profiling of tumor specimens. *Nat Med* 1998;4:844-7.
28. HEISKANEN M, KONONEN J, BARLUND M, TORHORST J, SAUTER G, KALLIONIEMI A, *et al*. CGH, cDNA and tissue microarray analyses implicate FGFR2 amplification in a small subset of breast tumors. *Anal Cell Pathol* 2001;22:229-34.
29. BAJORATH J. Rational drug discovery revisited: interfacing experimental programs with bio- and chemo-informatics. *Drug Discovery Today* 2001;6:989-95.
30. LEERKES MR, CABALLERO OL, MACKAY A, TORLONI H, O'HARE MJ, SIMPSON AJG, *et al*. *In silico* comparison of the transcriptome derived from purified normal breast cells and breast tumor cell lines reveals candidate upregulated genes in breast tumor cells. *Genomics* 2002;79:257-65.
31. WARD SJ. Impact of genomics in drug discovery. *Biotechniques* 2001;31:626-34.

PROGNOSTIC VALUE OF HER-2/NEU IN BREAST CARCINOMA PATIENTS

J. Jakić-Razumović

University Department of Pathology, Zagreb University Hospital Center, Zagreb, Croatia

The development and spread of malignant tumors is a multi-step process, involving a variety of alterations in the mechanisms controlling cell proliferation, differentiation and genetic alterations. Understanding of the biological process involved in tumorigenesis has practical application in the clinical areas of diagnosis, prognosis and treatment^{1,2}. The goal of clinicians managing patients with malignancy is to create therapy to give maximum benefit

to each individual patient. The decisions are usually based in part on predictors of the likely biological behavior of a given tumor. The major tumor characteristics in breast cancer known to be of value in prognosis include tumor size, tumor histologic type and grade, axillary lymph node status, steroid hormone receptor status, ploidy, and cell kinetics^{3,4}. Establishing prognosis based on these parameters is successful to a large extent, but they still fail to accurately predict the clinical course of all patients. Therefore, the search for better means of integrating prognostic data and for new prognostic markers in breast cancer patients still remains a major goal.

The human epidermal growth factor receptor-2 (HER-2) protooncogene encodes 185 transmembrane glycoprotein, often simply called HER-2/neu or c-erbB-2 protein receptor. *In vitro* and animal studies have indicated that HER-2/neu gene amplification and protein overexpression play a role in oncogenic transformation, tumorigenesis and metastasis. Furthermore, the growth of tumors and human breast carcinoma cell lines overexpressing HER-2/neu receptor is inhibited by anti-HER-2/neu monoclonal antibody, opening a new avenue for targeted cancer therapy. In 1987, Slamon *et al*.⁶ first reported a significant relationship between amplification of the HER-2/neo oncogene and adverse clinical outcome in patients with breast cancer. Although subsequent studies have largely confirmed this association in patients with node positive disease, whether or not HER-2/neo gene amplification or overexpression is an independent prognostic factor in patients with node-negative breast cancer remains a matter of controversy⁵⁻¹⁰. Although still somewhat controversial, the majority of clinical studies suggest that HER-2/neu is amplified and overexpressed in approximately 20%-30% of breast carcinomas, and that among the new biological indicators of tumor aggressiveness it is potentially useful in predicting the outcome of patients with breast carcinoma and can be used effectively to improve the identification of high-risk patients^{6,7,11,12}. It is generally accepted that HER-2 overexpression is associated with shorter overall survival, low level of ER, and higher tumor grade. However, considerable variation in the incidence of amplification/overexpression and prognostic significance of HER-2/neu has been reported. Some investigators found amplification in only 10% of patients and no correlation to clinical outcome¹³, whereas others found overexpression in up to 50% of patients and a strong association with outcome^{4,14}. Indeed, in our study the incidence of HER-2/neu overexpression was 42.7% with some marginal association with outcome in univariate

analysis ($p=0.059$) and no significant influence on survival in multivariate analysis¹⁵. Conflicting results of numerous studies, including our study, highlight some of the persisting controversies surrounding the use of HER-2/neu as a prognostic marker. Also, these results emphasize the importance of considering HER2/neu status in the light of information provided by other prognostic variables. For this reason, we tried to assess the prognostic significance of HER-2/neu overexpression in association with other known prognostic factors, and showed association with tumor size ($p=0.041$) and grade ($p=0.037$), DNA ploidy ($p=0.046$) and cathepsin D expression in stromal macrophages ($p=0.024$). These findings pointed to HER2/neu overexpression as an indicator of prognosis in grade II breast carcinoma, suggesting that determination of both tumor size and DNA ploidy in combination with HER-2/neu overexpression appear to enhance the ability to recognize the patients at different risk¹⁵.

More recently, there has been considerable interest in the potential role of HER-2/neu gene amplification and overexpression as a predictor of response to various therapeutic modalities in patients with breast cancer. In particular the results of recent clinical trials have indicated that treatment with monoclonal antibody to HER-2/neu protein (Herceptin®) may be useful in prolonging the survival of patients with metastatic disease. In our small group of 17 advanced breast carcinoma patients who were enrolled in the study from the beginning of 1999 until July 2000 at the Zagreb University Hospital Center, all were treated with Herceptin® and Taxol® in combination. All patients had tumors positive for HER2/neu by HercepTest. Partial response to therapy was observed in 47%, stable disease in 29% and progression of disease in 24% of patients. However, complete response was not observed in the investigated group of patients. In this way, the overall therapy benefit (stable disease and partial response) was found in 76% of patients. Complications of therapy include neutropenia, thrombocytopenia, diarrhea and onycholysis, but there were no signs of congestive heart failure¹⁶.

Furthermore, some studies have indicated that tumors with HER-2/neu overexpression may show resistance to certain forms of cytotoxic therapy and sensitivity to others. Finally, some recent experimental and clinical studies have suggested that HER-2/neu overexpression is associated with resistance to tamoxifen even when tumors were ER positive, and therefore the success of Herceptin® therapy depends upon the selection of the most appropriate patients for treatment. Candidates for Herceptin®

therapy can be identified by the evaluation of tumor cells for the presence of altered HER-2/neu.

As a result of this information, there is a growing clinical demand for HER-2/neu analysis of current and archived breast cancer specimens. There are a variety of methods available to determine the HER-2/neu status of breast cancers. These include assays to evaluate: 1) gene amplification as Southern blot, slot blot, dot blot, polymerase chain reaction (PCR), *in situ* hybridization and fluorescence *in situ* hybridization (FISH), 2) assays to determine mRNA overexpression such as Northern blot analysis, slot blot, and *in situ* hybridization, and 3) methods to assess protein overexpression (Western blot analysis, immunoassay, and immunohistochemistry (IHC)). Many of these methods are beyond the scope of most pathology laboratories for technical reasons. Furthermore, most of these assays require prospective collection of fresh tissue and are not applicable to archival material. The IHC method performs well and gives a clear picture of the heterogeneity of protein expression in tumor cells; it distinguishes tumor cells from normal cells and is easy to perform on routine paraffin-embedded material. HercepTest is a semi-quantitative IHC assay to determine HER-2/neu protein overexpression in breast cancer tissues routinely processed for histologic evaluation. For the determination of HER-2/neu protein overexpression, only the membrane staining intensity and pattern should be evaluated using scale 0-3+. Even if the standardized HER-2/neu protocol is followed, the subjective nature of histologic scoring can lead to spurious results. The need to distinguish between "faint" and "weak" staining is subject to bias even when positive control tissues are included in each stain run. Based on the problems associated with IHC (i.e. lack of standardization and subjective bias), some experts argue that FISH is a better alternative. FISH measures HER-2/neu gene amplification but tends to be more expensive, complicated, and time-consuming than IHC, and HER-2/neu must be scored on the invasive component of breast cancer (because a high % of breast *in situ* lesions have altered the HER-2/neu status).

Although each of these methods has its advantages and disadvantages, direct comparisons of these two assays have been few and are limited by small numbers of cases. Utility of IHC *versus* FISH for the selection of breast cancer therapy requires thorough analysis of the results of clinical trials now underway that address this issue. Any correlative study comparing IHC with FISH without statistically significant outcome data of patients treated with Herceptin® is of limited value for resolving the IHC-

FISH controversy. Wang *et al.*¹⁷ correlated IHC results with FISH over the past 18 months. These results showed excellent correlation in over 98 percent of HercepTest-negative cases (0, 1+) lacking HER-2/neu gene amplification, and in tumors with high expression (3+) demonstrating amplification. A poor correlation was found between cases considered to be weakly positive (2+) with the HercepTest and amplification with FISH. However, only 11 percent of all breast cancer cases demonstrated 2+ IHC staining. Based on these results, the authors suggest that clinically and economically, significant value is testing for HER-2/neu by HercepTest (IHC) with reflex to FISH only in cases of weakly positive results (2+). The cost of reflex testing of all 0 or 1+ cases is significant, since this group comprises up to 88 percent of all breast cancer cases. Controversy still exists as to whether the cases that show 0 or 1+ staining but demonstrate amplification (two percent of all cases examined) will respond to Herceptin.

In our hands also HercepTest provides excellent reproducibility and standardization, and close to 90% of all breast cancers can be adequately and reliably determined by IHC, with molecular evaluation reserved for borderline cases. Our own findings in 45 patients tested by IHC and FISH for HER-2/neu detection showed excellent correlation between IHC HER-2/neu analysis and the molecular technique for HER-2/neu amplification (FISH), except for the weakly positive (2+) IHC results as determined by the FDA-approved HercepTest. By IHC 12/45 (26.6%) were HER-2/neu positive. Six out of seven IHC high positive specimens (3+) showed gene amplification by FISH (85.7%), and 3/5 IHC medium positive specimens (2+) showed no gene amplification (60%). None of the cases negative by IHC showed expression of HER-2/neu by FISH. Concordances between FISH and IHC results were seen in 42 out of 45 cases (93.5%). We conclude that all 2+ IHC cases can in turn be subject to FISH analysis to confirm the presence of an altered HER-2/neu gene. This combination of assays would help ensure that patients who are most likely to benefit from Herceptin are identified. FISH testing is used to determine HER-2/neu status in equivocal circumstances, but the use of HercepTest as a screening assay allows for improved cost control and turnaround time without detriment to the patient.

It is known that the FISH procedure required more technician time and more interpretation time *per* case for the pathologist than IHC. Reagent costs were subsequently higher for FISH than for IHC. There is a high level of correlation between FISH and IHC in the evaluation of HER-2/neu status of breast cancers using forma-

lin-fixed, paraffin-embedded specimens, although the choice of which assay to use should be left for individual laboratories to make based on technical and economic considerations. The results published to date may make it difficult to justify the routine use of FISH for detection of HER2 status in breast cancers¹⁸⁻²⁰. It is generally accepted, at this level of knowledge that the best approach is to combine both IHC and FISH assays, and to use the IHC assay as a triage step, followed by FISH to analyze the IHC medium and high positive cases¹⁸⁻²⁰.

References

1. FEARON ER, VOGELSTEIN B. A genetic model for colorectal tumorigenesis. *Cell* 1990;61:759-67.
2. THOMPSON AM, STEEL CM, CHETTY U, CARTER DC. Evidence for the multistep theory of carcinogenesis in human breast cancer. *Breast* 1992;1:29-35.
3. ELLEDGE RM, MCGUIRE WK, OSBORNE CK. Prognostic factors in breast cancer. *Semin Oncol* 1992;19:244-53.
4. MILLER WR, ELLIS IO, SAINSBURG JRC, DIXON JM. Prognostic factors - ABC of breast diseases. *BMJ* 1994;309:1573-6.
5. CLARK GM, WONG SG. Human breast cancer: correlation of relapse and survival with amplification of the HER2/neu oncogene. *Science* 1987;235:177-82.
6. SLAMON D, CLARK GM, WONH SH, LEVIN WJ, ULLRICH A, MCGUIRE WL. Human breast cancer: Correlation of relapse and survival with amplification of the HER-2/neu oncogene. *Science* 1987;235:177-82.
7. BORG A, TANDON AK, SIGURDSSON H, *et al.* HER2/neu amplification predicts poor survival in node-positive breast cancer. *Cancer Res* 1990;50:4332-7.
8. LOVEKIN C, ELLIS IO, LOCKER A, *et al.* c-erbB-2 Oncoprotein expression in primary and advanced breast cancer. *Br J Cancer* 1991;63:439-43.
9. QUENEL N, WAFFLART J, DONICHON F, *et al.* The prognostic value of c-erbB-2 in primary breast carcinomas: a study on 942 cases. *Breast Cancer Res Treat* 1995;35:283-91.
10. ROSEN PP, LESSER ML, ARROYO CD, *et al.* Immunohistochemical detection of HER2/neu in patients with axillary lymph node negative breast carcinoma: a study of epidemiologic risk factors, histologic features, and prognosis. *Cancer* 1995;75:1320-6.
11. REVILLION F, BONNETERRE J, PEYRAT JP. ERBB2 oncoprotein in human breast cancer and its clinical significance. *Eur J Cancer* 1998;34:791-808.
12. PRESS MF, BERNSTEIN L, THOMAS PA, *et al.* HER2/neu gene amplification characterized by fluorescence *in situ* hybridization: poor prognosis in node-negative breast carcinoma. *J Clin Oncol* 1997;15:2894-904.
13. ZHOU DJ, AHUJA H, CLINA MJ. Proto-oncogene abnormalities in human breast cancer: c-erbB-2 amplification does not correlate with recurrence of disease. *Oncogene* 1989;4:105-8.
14. NOGUCHI M, KAWASAKI N, NAGAYOSHI O, *et al.* C-erbB-2 oncoprotein expression versus internal mammary lymph node metastases as additional prognostic factors in patients with axillary lymph node-positive breast cancer. *Cancer* 1992;69:2953-60.

15. JAKIĆ-RAZUMOVIĆ J, PETROVEČKI M, UŽAREVIĆ B, GAMULIN S. Mutual predictive value of c-erbB-2 overexpression and various prognostic factors in ductal invasive breast carcinoma. *Tumori* 2000;86:30-6.
16. MRSIĆ M, GRAGIĆ M, BUDIŠIĆ Z, PODOLSKI P, BOGDANIĆ V, LABAR B, JAKIĆ-RAZUMOVIĆ J, RESTEK-SAMARŽIJA N, GOŠEV M. Trastuzumab in the treatment of advanced breast cancer: single-center experience. *Ann Oncol* 2001;12 (Suppl):95-6.
17. WANG S, SABOORIAN MT, FRENKEL E, HYNAN L, GOKASLAN ST, ASHFAQ R. Laboratory assessment of the status of HER2/neu protein and oncogene in breast cancer specimens: comparison of immunohistochemistry assay with fluorescence *in situ* hybridization assays. *J Clin Pathol* 2000;53:374-81.
18. JACOBS TW, GOWN AM, YAZIJI H, BARNES MJ, ASHNITT SJ. Comparison of fluorescence *in situ* hybridization and immunohistochemistry for the evaluation of HER2/neu in breast cancer. *J Clin Oncol* 1999;17:1974-82.
19. DOWSETT M, COOKE T, ELLIS IO, GULLICK WJ, GUSTERSON B, MALLON E, WALKER R. Assessment of HER2 status in breast cancer: why, when and how? *Eur J Cancer* 2000;36:170-6.
20. HENDRICKS JB. Histopathology at the trailing edge (editorial). *J Histotechnol* 2000;23:297.

FACTORS INFLUENCING PROGNOSIS AND SURVIVAL IN EARLY (TN0M0) BREAST CARCINOMA

S. Frković-Grazio
Institute of Oncology, Ljubljana, Slovenia

Carcinoma of the breast is the most common malignant tumor in women in the western world. Its incidence has been rising steadily over the past decades. Despite considerable progress in early diagnosis and treatment, mortality remains relatively high and approximately every third or second woman with breast cancer will ultimately die of the disease.

TNM stage is generally accepted as the most important determinant of outcome in breast cancer. In addition to hormonal status of the patient (pre- or postmenopausal) and the presence of steroid receptors in the tumor, TNM stage has long been the only factor used by clinicians to make therapeutic decisions.

During the past two decades, there has been a gradual change in the treatment of breast cancer with a tendency toward less radical surgery and more adjuvant systemic therapy. In the early era of chemotherapy, this type of treatment was mainly used in patients with advanced disease; however, meta-analyses of large clinical trials have clearly shown that systemic chemotherapy and hormonal therapy also reduce the risk of cancer recurrence and mortality in patients with early breast cancer. Accordingly, the

question of who should be treated by systemic therapy has eventually changed to the question of who should not be so treated.

Due both to more widespread public education and to early diagnosis by mammography screening programs, the percentage of patients with node negative breast cancer (N0) is increasing. The majority of these patients (about 70%) do not experience disease recurrence after surgery and/or radiotherapy alone (local therapy); therefore, it seems inappropriate to suggest systemic adjuvant therapy for all node negative breast cancer patients. Since the relative risk reduction is constant across different tumor stages and risk groups, it is obvious that the absolute benefit from adjuvant therapy may be quite small in some specific low-risk group of patients. It is reasonable to attempt to avoid excessive treatment morbidity and cost by using selective prognostic markers to identify prognostically relevant subsets of patients. However, an "ideal" prognostic indicator or a widely accepted combination of markers able to identify patients at low *versus* high risk has yet to be clearly defined.

Numerous studies have reported that several clinicopathologic features have prognostic importance in node-negative breast carcinoma patients. These features include tumor size, histologic grade, and histologic type of tumor, vascular invasion and some new biological markers. Only a few studies have simultaneously evaluated the relative prognostic weight of various newer biological markers compared with all conventional clinicopathological markers by performing a multivariate analysis. Also, the majority of these studies included heterogeneous group of patients regarding tumor size.

Recently, an International Consensus Panel proposed a 3-tiered risk classification for patients with negative axillary lymph nodes (Table 1) and defined the low-risk group as those with tumor size of 1 cm or less, positive ER or PR status and histologic grade 1; they suggested that this is the only group in which adjuvant systemic therapy could be omitted. Since this proposal is not based on multivariate analyses of large data sets, its true prognostic value remains uncertain.

Table 1. Risk categories for women with node-negative breast cancer

	Low-risk (has all listed factors)	Intermediate-risk (between the other 2 categories)	High-risk (has at least 1 listed factor)
Tumor size	≤ 1cm	1-2 cm	> 2cm
ER or PR status	positive	positive	negative
Tumor grade	grade 1	grade 1-2	grade 2-3

Although the patients with stage I (T1N0M0) breast carcinoma (i.e. tumor measuring 2 cm or less without regional lymph node and distant metastasis) have an excellent short term prognosis, approximately 20% will eventually develop distant metastases and die of the disease. However, the remaining majority would be cured by surgery alone and gain no benefit from adjuvant systemic therapy. Unfortunately, there is no general agreement how to best identify the latter group.

Less than 15 published studies evaluated the prognostic value of different factors in T1N0M0 breast carcinoma and only few of them included the newer biologic indicators, such as c-erbB-2, p53, bcl2, Ki67 (MIB-1), flow-cytometric DNA ploidy or S-phase fraction determination. Although the results of these studies are somewhat controversial, histologic or nuclear grade, proliferative activity (as assessed by either mitosis counting, SPF determination or Ki67 expression), vascular invasion and tumor size most often emerged as significant prognostic factors.

We recently investigated a group of 270 patients with T1N0M0 breast carcinoma who were treated at the Institute of Oncology Ljubljana and were followed for a median of 12.5 years. All original slides were reviewed and examined for histologic type, mitotic index (MI), Nottingham histologic grade (NHG) and its components (extent of tubule formation, pleomorphism, mitotic counts) and presence of vascular invasion. Representative tumor slides were stained immunohistochemically for p53, bcl-2, c-erbB-2, MIB-1(Ki67), CEA, ER and PR using LSAB method and Dako TechMate 500 automatic immunostainer. The prognostic value of investigated features was evaluated using univariate and multivariate survival analysis.

Survival of our patients (84.4% cancer-specific survival, CSS, and 77.4% metastasis-free survival, MFS, at 10 years) was similar to that reported in other series of patients with T1N0M0 tumors. In keeping with other reports, late recurrences were not uncommon. The prognostic value of tumor size was not confirmed in our study: although survival was somewhat worse in patients with tumors larger than 1 cm (T1c) than in those with tumors measuring 1 cm or less (T1ab), the difference was not significant. We confirmed the prognostic significance of NHG: both MFS and CSS were significantly better in patients with grade 1 than in those with grade 2 or 3 tumors. Apart from NHG, in univariate analysis, MI, vascular invasion and c-erbB-2 expression were significant predictors of MFS and CSS. In addition, CEA expression and MIB-1 reactivity were significantly related to MFS, and histologic type to CSS. Age, menopausal status, type of treatment, PR or ER status and

expression of bcl-2 or p53 were not significantly associated with survival. The relative importance of prognostic variables was tested in Cox's proportional hazard model. When all variables were entered in the model, MI, histologic type, vascular invasion and CEA expression emerged as significant independent prognostic factors for both MFS and CSS.

MI was the single most important prognostic factor for MFS and CSS; however, our findings suggest that optimal cutoff values for different prognostic groups may be lower than those proposed in NHG. When testing various multivariate models to predict CSS, NHG retained its independent prognostic value only in the model that did not include MI and histologic type, whereas it was replaced by MIB-1 reactivity in multivariate analysis of MFS.

By combining four independent factors (MI, histologic type, vascular invasion and CEA expression) into a prognostic index, the patients could be allocated into three prognostic groups. Patients in the first group (15%) developed metastatic disease in almost one half of cases and those in the second (60%) in one third of cases. In the third group (25%), prognosis was excellent, with more than 90% MFS at 15 years after surgery. In the latter group, the use of adjuvant chemotherapy may be unnecessary. By applying the aforementioned Consensus Panel criteria, the group of patients in whom adjuvant systemic therapy could be omitted would be considerably smaller.

References

- EIFEL P, AXELSON JA, COSTA J, *et al.* National Institutes of Health Consensus Development Conference Statement: adjuvant therapy for breast cancer, November 1-3, 2000. *J Natl Cancer Inst* 2001; 93:979-89.
- Polychemotherapy for early breast cancer: an overview of the randomised trials. Early Breast Cancer Trialists' Collaborative Group. *Lancet* 1998; 352:930-42.
- Systemic treatment of early breast cancer by hormonal, cytotoxic, or immune therapy. 133 randomised trials involving 31,000 recurrences and 24,000 deaths among 75,000 women. Early Breast Cancer Trialists' Collaborative Group. *Lancet* 1992; 339:1-15.
- Early stage breast cancer: consensus statement. NIH Consensus Development Conference, June 18-21, 1990. *Cancer Treat Res* 1992; 60:383-93.
- GOLDHIRSCH A, WOOD WC, SENN HJ, *et al.* Meeting highlights: international consensus panel on the treatment of primary breast cancer. *J Natl Cancer Inst* 1995; 87:1441-5.
- YARBRO JW, PAGE DL, FIELDING LP, *et al.* American Joint Committee on Cancer Prognostic Factors Consensus Conference. *Cancer* 1999; 86:2436-46.
- FITZGIBBONS PL, PAGE DL, WEAVER D, *et al.* Prognostic factors in breast cancer. College of American Pathologists Consensus Statement 1999. *Arch Pathol Lab Med* 2000; 124:966-78.

8. SAUERBREI W, HÜBNER K, SCHMOOR C, *et al.* Validation of existing and development of new prognostic classification schemes in node negative breast cancer. German Breast Cancer Study Group. *Breast Cancer Res Treat* 1997; 42:149-63.
9. MOONTE, JONES SE, BONADONNA G, *et al.* Development and use of a natural history data base of breast cancer studies. *Am J Clin Oncol* 1987; 10:396-403.
10. QUIET CA, FERGUSON DJ, WEICHELBAUM RR, *et al.* Natural history of node-negative breast cancer: a study of 826 patients with long-term follow-up. *J Clin Oncol* 1995; 13:1144-51.
11. ROSEN PP, GROSHEN S, KINNE DW. Survival and prognostic factors in node-negative breast cancer: results of long-term follow-up studies. *J Natl Cancer Inst Monogr* 1992; 11:159-62.
12. ROSEN PP, GROSHEN S. Factors influencing survival and prognosis in early breast carcinoma (T1N0M0-T1N1M0). Assessment of 644 patients with median follow-up of 18 years. *Surg Clin North Am* 1990; 70:937-62.
13. RAUSCHECKER HF, SAUERBREI W, GATZEMEIER W, *et al.* Eight-year results of a prospective non-randomised study on therapy of small breast cancer. The German Breast Cancer Study Group (GBSG). *Eur J Cancer* 1998; 34:315-23.
14. JOENSUU H, PYLKKÄNEN L, TOIKKANEN S. Late mortality from pT1N0M0 breast carcinoma. *Cancer* 1999; 85:2183-9.
15. LEE AK, LODA M, MACKAREM G, *et al.* Lymph node negative invasive breast carcinoma 1 centimeter or less in size (T1a,b N0M0): clinicopathologic features and outcome. *Cancer* 1997; 79:761-71.
16. LEITNER SP, SWERN AS, WEINBERGER D, *et al.* Predictors of recurrence for patients with small (one centimeter or less) localized breast cancer (T1a,b N0 M0). *Cancer* 1995; 76:2266-74.
17. STIERER M, ROSEN H, WEBER R. Nuclear pleomorphism, a strong prognostic factor in axillary node-negative small invasive breast cancer. *Breast Cancer Res Treat* 1992; 20:109-16.
18. STAEL O, DUFMATS M, HATSCHEK T, *et al.* S-phase fraction is a prognostic factor in stage I breast carcinoma. *J Clin Oncol* 1993; 11:1717-22.
19. STENMARK-ASKMALM M, STAEL O, OLSEN K, *et al.* p53 as a prognostic factor in stage I breast cancer. South-East Sweden Breast Cancer Group. *Br J Cancer* 1995; 72:715-9.
20. RAILO M, LUNDIN J, HAGLUND C, *et al.* Ki-67, p53, Er-receptors, ploidy and S-phase as prognostic factors in T1 node negative breast cancer. *Acta Oncol* 1997; 36:369-74.
21. FRKOVIĆ GRAZIO S, BRAČKO M. Long term prognostic value of Nottingham histological grade and its components in early (pT1N0M0) breast carcinoma. *J Clin Pathol* 2002; 55:88-92.

ADVANCES IN BREAST FNA

F. Schmitt

Instituto de Patologia e Imunologia Molecular da Universidade do Porto – IPATIMUP e Faculdade de Medicina da Universidade do Porto, Porto, Portugal

Fine-needle aspiration cytology (FNA) is a simple, rapid, accurate and cost-effective method that has become a standard of care in the evaluation of breast lesions. Over recent years, FNA has become the method to assess pal-

pable and non-palpable breast lesions, and contributes to management decisions at surgical and medical levels, being the source of primary diagnosis in several cases. In addition, cytology is also largely used to diagnose lymph node metastasis and to evaluate pleural effusions in patients with breast cancer. As the treatment planning is frequently made preoperatively based on cytological material, the diagnosis should be as precise as possible, and as much prognostic information should be gained from the cytologic specimens as possible.

FNA has largely replaced frozen sections and, in cases candidates for primary chemotherapy it can provide hormonal assessment as well as other useful parameters relevant for the prognosis and prediction of therapeutic response. Furthermore, FNA material can also be used for some special studies such as immunohistochemistry, cytometry, *in situ* hybridization and molecular biology techniques.

The aim of this review is to report the major application of the new technologies in cytologic material obtained from breast FNA biopsies.

Identification of Myoepithelial Cells

The presence of myoepithelial cells is one of the most important criteria to support a diagnosis of benign lesion in FNA of the breast. However, on cytologic examination, the correct identification of myoepithelial cells is sometimes difficult, as they might be confused with apoptotic cells, stromal cells, and even epithelioid histiocytes. Since some years ago, several markers have been used in cytologic material in an attempt to identify myoepithelial cells. However, most of these markers (such as smooth-muscle actin, calponin, H-caldesmon, cytokeratins 5/6/14) have shown cross-reaction with other cells (myofibroblasts, luminal cells, stromal cells, pericytes) and are expressed at the cytoplasm of myoepithelial cells that can be lost in smears.

Recently, two novel markers have been used to identify myoepithelial cells at the histologic and cytologic levels. P63, a p53-homologue nuclear transcription factor, is a protein that is necessary for the maintenance of the basal compartment of several multilayered epithelia and is selectively expressed in basal cells of stratified epithelia, in the basal cells of prostate and myoepithelial cells of the breast, salivary and lacrimal cells. Recently, Barbareschi *et al.* and our group have shown that p63 is a reliable myoepithelial cell marker in histologic sections. Moreover,

some preliminary studies have pointed out that p63 could be better than other conventional myoepithelial cell markers because, as it is localized in the nuclei of myoepithelial cells, it overcomes the cytoplasmic fragility of myoepithelial cells in FNA. Studying more than 90 cases of breast FNA smears with immunocytochemistry for p63 antibody, we demonstrated that this marker highlighted the nuclei of two distinct cell populations: 1) all of the oval-to-spindle-shaped cells with dark nuclei on epithelial cell clusters, and 2) all of the naked nuclei observed in the background of the smears. No immunoreactivity for p63 was observed in the cells admixed with fibrillary matrix of fibromyxoid stroma or in those isolated cells with oval nuclei and sparse-to-moderate cytoplasm. Based on these results, we strongly suggest that p63 is a reliable marker for myoepithelial cells in breast FNAs and that the majority of naked nuclei, defined as oval-to-spindle-shaped cells without any discernible cytoplasm, show a myoepithelial origin and thus, they might be included in the major criteria to diagnose benign breast lesions. Moreover, we observed that p63 helps identify myoepithelial cells overlying malignant cell clusters that we found consistently in cases of ductal carcinoma *in situ*. However, further studies with large series of patients using similar methodology are required in order to define how specific and sensitive this finding is in ruling out invasion in FNA of the breast.

The other myoepithelial cell marker used by our group is maspin. Maspin is a member of the serpin family of serine protease inhibitors, and it has been claimed to be a tumor and metastasis suppressor and to have anti-angiogenic properties. Maspin is consistently expressed by myoepithelial cells and our group has shown that myoepithelial tumors of the breast are positive for maspin. Although initial studies demonstrated cytoplasmic expression only, we showed for the first time that maspin is also expressed in the nuclei, a finding recently confirmed by other groups.

Estrogen and Progesterone(ER/PR) Assessment

Besides giving prognostic information, hormonal receptor analysis is a useful tool to predict hormonal response in human breast cancer. According to the College of American Pathologists (CAP) Consensus Statement 1999, concerning the prognostic factors in breast cancer, hormone receptor analysis should be performed routinely in all primary breast carcinomas. Although hormone re-

ceptor analysis has been traditionally performed on surgically removed specimens, FNA offers a suitable alternative for this determination in a number of situations: a) inoperable cases and metastatic or recurrent tumors in which the size and accessibility to surgical biopsy presents a problem; b) cases in which preoperative irradiation or presurgical therapy is the initial treatment option; and c) advanced tumors in which serial hormone receptor studies may provide information regarding response to therapy.

The assessment of hormone receptors on cytologic material has been performed by immunocytochemistry with good correlation with histologic and biochemistry determinations. Some years ago, we described a method of immunocytochemical assessment of estrogen receptor status on alcohol-fixed smears obtained by FNA from breast cancer patients, using a commercially available monoclonal antibody with antigen retrieval, and the results were compared with the assessment by ER immunocytochemical assay using the same procedure on formalin-fixed tissue and with assessment by ER-ICA assay on frozen sections. The results were scored semiquantitatively using a five grade scoring system. Although we have been critical in the use of score system in cytologic specimens, especially in relation to the extension of immunoreactivity, we found a good correlation between the results obtained on the cytologic specimens and on the histologic material. The heterogeneity of ER expression within the tumor should be taken in consideration whenever using FNA material for semi-quantification of ER because it might cause discrepant results. The putative usefulness of quantification in cytochemical hormone receptor assays remains controversial, and no consensus about the use of semiquantitative scoring system or mere division of tumors into positive and negative ones has been attained so far. Although it has not been shown that quantitative values beyond a defined level are helpful in selecting treatment options, some authors using FNA material showed better response to treatment with tamoxifen in patients with more than 50% ER-positive tumor cells.

HER2/neu Assessment

The proto-oncogene *c-erbB2* is localized on chromosome 17 and encodes a 185-kD transmembrane glycoprotein with tyrosine kinase activity, which possesses a close sequence homology with the epidermal growth factor receptor. This oncogene is overexpressed in about one third of breast cancers and its overexpression is associated with

high histologic grade, reduced survival, lower responsiveness to methotrexate-based treatment regimens and hormone receptor modulators such as tamoxifen, as well as higher responsiveness to doxorubicin-based regimens. Recently, a humanized antibody against HER2/neu was developed (Herceptin - Genentech, Inc, South San Francisco, CA), and might be used as a novel neoadjuvant primary therapy for HER2/neu positive breast cancer patients. Some authors showed that it is possible to determine the immunocytochemical expression of HER2/neu in previously Papanicolaou-stained aspirates of breast carcinomas. They found a strong correlation between HER2/neu immunocytochemistry of aspirates and their corresponding tissue biopsies. In fact, the determination of HER2/neu in smears and cytoblock preparations may be as sensitive as, or even more sensitive than that of formalin-fixed, paraffin-embedded tissue. In cytology, the pattern of expression of HER2/neu is relatively uniform and is evidenced by membrane staining. NCL-CB11, a monoclonal antibody against the internal domain of the HER2/neu protein, gave better results in cell smears with strongest reaction and least background staining.

The clinical use of Herceptin requires the evaluation of HER2/neu amplification from every potentially eligible patient. Fluorescence *in situ* hybridization (FISH) is currently regarded by the FDA as the gold standard method for detecting HER-2/neu amplification. A big deal of discussion has emerged recently concerning the accordance between the immunohistochemical assessment of HER2/neu overexpression and the real amplification of the gene assessed by FISH. For tissue sections, the semiquantitative immunohistochemical approach accepted by FDA is defined as positive membranous staining in more than 10% of the neoplastic cells. Partial or incomplete, weak to moderate, and moderate to strong membranous staining in more than 10% of the tumor cells must be scored as 1+ (negative), 2+ (weak positive), and 3+ (strong positive), respectively. Several reports showed a good correlation between a 3+ immunorexpression of HER2/neu and the amplification of the gene using formalin-fixed paraffin embedded tissue; however, in 1+ and 2+ cases, there is no correlation between these parameters and these patients may have benefits assessing c-erb-B2 amplification by FISH analysis. In the last years, some authors have successfully assessed the amplification of HER2/neu by FISH analysis in archival cytologic fine needle aspirates and showed a good concordance with paraffin-embedded tissue.

The findings reported so far support that FNA cytologic samples might constitute the most cost-effective and easi-

est way to assess the HER2/neu amplification and overexpression, however, further studies are required to characterize the method for semiquantitative analysis of its immunocytochemical expression. Besides, FISH analysis requires microscopes with special filters and complex image analysis system to interpret the fluorescent signal. With the aim to supervise this drawback, the chromogenic *in situ* hybridization (CISH), a new modification of FISH, that enables detection of HER-2/neu gene copies with conventional peroxidase reaction in breast cancer specimens using regular microscopes, has been tested with outstanding results. Further studies in this front are needed to verify the applicability of this new method in FNA cytologic samples.

P53 Expression

P53 encodes a 53 kD nuclear phosphoprotein with tumor suppressor activity. The wild type P53 protein, which is a transcription regulator, is present in the nuclei of all mammalian cells where it appears to be involved in the regulation of cell proliferation and apoptosis. Recent clinical evidence supports a critical role of P53 status in providing prognostic information, mainly in node-negative breast cancer patients. In fact, there is increasing evidence that tumors lacking normal P53 function are clinically more aggressive as they acquire a selective growth advantage becoming more resistant to ionizing radiation and some anticancer drugs. P53 immunostaining is nuclear and could be determined in previously Papanicolaou-stained aspirates of breast carcinomas. When we compare P53 gene mutations *versus* overexpression, the data obtained by molecular biology methods for assessment of mutations give better prognostic information than immunohistochemistry performed with PAb 1801 monoclonal antibody. In histologic material using a semi-quantitative approach we found an association between the presence of mutation in SSCP analysis and strong P53 staining and absence of mutation in cases with scarce and weakly positive neoplastic cells, however, we do not test this system in FNA smears. Since it is possible to detect P53 mutations and deletion in FNA material using polymerase chain reaction single strand conformation polymorphism (PCR-SSCP) and DNA sequencing analyses in DNA extracted from cell suspensions or archived stained smears and that specific mutations in the P53 gene are associated to primary resistance to chemotherapy, the assessment of P53 mutations on FNA material could be very useful to predict clinical behavior and responsiveness to therapy in breast cancer. This is of particular value in a

primary chemotherapy setting, as complete tumor regression may occur and FNA-based pre-chemotherapy information may represent the only available information unaffected by therapy. The application of molecular biology techniques to the existing archival smears may become a valuable tool to detect genetic changes in samples from breast cancer aspirates, making FNA a reliable and helpful tool for the diagnosis, prognostic assessment and therapeutic management of breast cancer patients.

Sialyl-Tn Expression

Sialyl-Tn (STn) is a core region carbohydrate antigen formed by the premature 2-6 sialylation of N-acetylgalactosamine whose expression is associated with some human malignancies. In fact, neoplastic transformation is almost invariably associated with marked changes in cell membrane glycoconjugates due to abnormal expression or depression of DNA encoding glycosyl transferases and the expression of simple mucin-type antigens, including STn is highly restricted in normal adult tissues. In our experience, the expression of this marker in breast cancer is associated with the presence of axillary metastases, lack of hormonal receptor, and high histologic grade. Moreover, some authors have demonstrated that STn positivity appears to be a marker of resistance to adjuvant chemotherapy. Using immunocytochemistry, we documented STn expression in mammographically detected breast lesions diagnosed by FNA cytology. Therefore, the determination of expression of STn in breast aspirates could be a useful marker to assess resistance to chemotherapy as well as to identify cases with high risk of axillary metastases.

Assessment of Telomerase Activity

Telomeres are repetitive sequences at the ends of chromosomes that protect chromosomes from incomplete replication, nuclease degradation, and end-to-end fusion during replication, playing a major role during DNA replication. In most somatic cells, after each cell division, the telomeres are eroded, leading to a progressive shortening of their length. When one telomere reaches the critical point, the cell stops dividing, and senesces. The maintenance of telomeres depends on the telomerase activity. Telomerase is a ribonucleoprotein complex responsible for *de novo* telomere synthesis and addition of telomeric repeats to existing telomeres. Telomerase activity (TA) is almost restricted

to embryonic cells, germ cells, and malignant neoplastic cells; very low levels of this enzyme have been detected in somatic tissues, mainly restricted to the basal cell layer of several epithelia and cells in the terminal ducts of the breast. Telomerase activity can be measured *in vitro* by using the telomeric repeat amplification protocol (TRAP), including cells obtained by FNA specimens. The presence of TA was demonstrated in 80% to 90% of breast carcinoma FNA samples; however, some benign lesions presented some level of telomerase activity, including fibroadenomas. Further evaluation of the sensitivity and specificity of TA for malignant cells is required before this technique could be accepted as a new marker in routine cytology.

References

1. BARBARESCHI M, PECCIARINI L, CANGI MG, MACRI E, RIZZO A, VIALE G, DOGLIONI C. P63, a p53 homologue, is a selective nuclear marker of myoepithelial cells of the human breast. *Am J Surg Pathol* 2001; 25:1054-60.
2. FITZGIBBONS PL, PAGE DL, WEAVER D, THOR AD, ALLRED DC, CLARK GM, RUBY SG, O'MALLEY F, SIMPSON JF, CONNOLLY JL, HAYES DF, EDGE SB, LICHTER A, SCHNITT SJ. Prognostic factors in breast cancer. College of American Pathologists Consensus Statement 1999. *Arch Pathol Lab Med* 2000;124:966-78.
3. HIYAMA E, SAEKI T, HIYAMA K, TAKASHIMA S, SHAY JW, MATSUURA Y, YOKOYAMA T. Telomerase activity as a marker of breast carcinoma in fine-needle aspirated samples. *Cancer* 2000;90:235-8.
4. KLIJANIENKO J, COUTURIER J, GALUT M, EL-NAGGAR AK, MACIOROWSKI Z, PADOY E, MOSSERI V, VIELH P. Detection and quantitation by fluorescence *in situ* hybridization (FISH) and image analysis of HER-2/neu gene amplification in breast cancer fine-needle samples. *Cancer* 1999;87:312-8.
5. LAVARINO C, CORLETTI V, MEZZELANI A, DELLA TORRE G, BARTOLI C, RIVA C, PIEROTTI MA, RILKE F, PILOTTI S. Detection of TP53 mutation, loss of heterozygosity and DNA content in fine-needle aspirates of breast carcinoma. *Br J Cancer* 1998; 77:125-30.
6. MOORE JG, TO V, PATEL SJ, SNEIGE N. HER-2/NEU gene amplification in breast imprint cytology analyzed by fluorescence *in situ* hybridization: direct comparison with companion tissue sections. *Diagn Cytopathol* 2000;23:299-302.
7. NIZZOLI R, BOZZETTI C, NALDI N, GUAZZI A, GABRIELLI M, MICHIARA M, CAMISA R, BARILLI A, COCCONI G. Comparison of the results of immunocytochemical assays for biologic variables on preoperative fine-needle aspirates and on surgical specimens of primary breast carcinomas. *Cancer* 2000;90:61-6.
8. POREMBA C, SHROYER KR, FROST M, DIALLO R, FOGT F, SCHAFFER KL, BURGER H, SHROYER AL, DOCKHORN-DWORNICZAK B, BOECKER W. Telomerase is a highly sensitive and specific molecular marker in fine-needle aspirates of breast lesions. *J Clin Oncol* 1999;17:2020-6.
9. REIS-FILHO JS, SCHMITT FC. Taking advantage of basic research: p63 is a reliable myoepithelial and stem cell marker. *Adv Anat Pathol* 2002; in press.

10. REIS-FILHO JS, MILANEZI F, SILVA P, SCHMITT FC. Maspin expression in myoepithelial tumors of the breast. *Pathol Res Pract* 2001;197:817-22.
11. SCHMITT FC, BENTO MJ, AMENDOEIRA I. Estimation of estrogen receptor content in fine-needle aspirates from breast cancer using the monoclonal antibody 1D5 and microwave oven processing: correlation with paraffin embedded and frozen sections determinations. *Diagn Cytopathol* 1995;13:347-51.
12. SCHMITT FC. Comments on p53 protein expression, cell proliferation and steroid hormone receptors in ductal and lobular *in situ* carcinomas of the breast. *Eur J Cancer* 1997; 33:1903.
13. SCHMITT FC, SOARES R, CIRNES L, SERUCA R. P53 in breast carcinomas: association between presence of mutation and immunohistochemical expression using a semiquantitative approach. *Pathol Res Pract* 1998;194:815-19.
14. SCHMITT FC, MARINHO A, AMENDOEIRA I. Expression of sialyl-Tn in fine-needle aspirates from mammographically detected breast lesions: a marker of malignancy? *Diagn Cytopathol* 1998; 18:325-9.
15. SOLOMIDES CC, ZIMMERMAN R, BIBBO M. Semiquantitative assessment of c-erbB-2 (HER-2) status in cytology specimens and tissue sections from breast carcinoma. *Anal Quant Cytol Histol* 1999;21:121-5.
16. TANNER M, GANCBERG D, DI LEO A, LARSIMONT D, ROUAS G, PICCART MJ, ISOLA J. Chromogenic *in situ* hybridization: a practical alternative for fluorescence *in situ* hybridization to detect HER-2/neu oncogene amplification in archival breast cancer samples. *Am J Pathol* 2000;157:1467-72.

MAMMARY NEOPLASIA IN CATS AND DOGS

F. Del Piero

University of Pennsylvania, School of Veterinary Medicine, Departments of Pathobiology and Clinical Studies, New Bolton Center, Philadelphia, USA

Mammary neoplasms are very prevalent in dogs and cats, but are rare in other domesticated species. Because of their prevalence in these companion animals, and because they are a model for human breast cancer, they are deeply investigated clinically, histologically, immunohistochemically and with other molecular pathology techniques. Mammary neoplasms are the third most frequently occurring tumor in female cats, following hematopoietic neoplasms and skin tumors. The incidence of mammary tumors in this species is less than half that of humans and dogs, nevertheless, these tumors account for 17% of neoplasms in female cats. The great majority (about 80%) of feline mammary tumors are malignant (adenocarcinomas). Breed predisposition (Siamese) has been speculated but not proven. Mammary tumors occur primarily in intact cats from 9 months to 23 years of age, with a mean age of 10 to 12 years. Several reports have documented an association between the prior use of progesterone-like molecules and the develop-

ment of benign or malignant feline mammary neoplasms. While low concentrations of progesterone receptors have been found in the cytoplasm of some feline mammary tumors, dihydrotestosterone receptors have not been identified. Only 10% of the feline tumors examined were positive for estrogen receptors: a much higher percentage of estrogen receptor positive tumors are seen in dogs and humans. Tubular, papillary, and solid adenocarcinomas are the most common malignant tumors and the majority present a combination of tissue types in each tumor. Sarcomas, mucinous carcinomas, duct papillomas, adenosquamous carcinomas, and adenomas are rarely seen. Mammary gland dysplasia, while infrequent, needs to be differentiated from malignant neoplasms. Lobular hyperplasia and fibroepithelial hyperplasia are types of non-inflammatory hyperplasia identified in the mammary gland of the cat. These hyperplastic conditions are relatively common, and thought to be associated with hormonal stimulation of the glandular tissue, which decreases following ovariohysterectomy. Benign tumors include simple and complex adenomas, low- and high-cellularity fibroadenomas, benign mixed tumors and duct papillomas. Feline mammary gland neoplasm can involve any or all of the glands and is distributed equally between the left and right sides. Multiple gland involvement occurs in more than half of affected cats. Metastatic lung and thorax involvement may be extensive. Tumor size is the single most important prognostic factor for malignant feline mammary tumors. Other significant prognostic factors affecting recurrence in and survival of feline malignant mammary tumors are the extent of surgery and histologic grading of the tumor. Cats with a tumor size of greater than 3 cm in diameter will have a median survival time of 4 to 6 months. Cats with a tumor size of 2 to 3 cm in diameter will have a significantly increased survival time with a median of about 2 years. Cats with tumor less than 2 cm in diameter have a median survival time of more than 3 years. Thus, early diagnosis and treatment is a very important prognostic factor for malignant feline mammary tumors. Mammary tumors are extremely common in intact female dogs, and account for at least 50% of all reported neoplasms. At least 70% of intact bitches will develop a clinically detectable mammary tumor if they live to 15 years of age, and almost all of them will have microscopic tumor foci. Ovariohysterectomy prior to the first heat cycle greatly reduces the risk (more than 80%) of developing mammary neoplasia later in life, with the benefits reduced with time and no benefits of spaying after the second heat. Some report that 50% of canine mammary tumors are malignant and 50% of the malignant neoplasms metastasize, others reports that

metastasis is much less frequent. The most reliable predictor of true behavioral malignancy in canine mammary tumors is local invasion. While local invasion is readily detected by histologic examination of the excised tumors, it can also be predicted with accuracy by clinical examination. Tumors that seem to be fixed to the underlying tissue, cross the midline, or are otherwise obviously infiltrative are likely to be true malignancies. A bitch with one detected mammary tumor very often will have numerous microscopic foci in the same or other glands. Malignant tumors of the dog include several types of carcinomas: noninfiltrating (*in situ*), complex, simple, tubulopapillary, solid, anaplastic and some special types of carcinomas including spindle, squamous, mucinous, and lipid rich carcinomas. Sarcomas, which are much less frequent, include fibrosarcomas, osteosarcomas, and other sarcomas. In addition, carcinosarcoma and carcinoma or sarcoma within a benign neoplasm have been described. Benign tumors include simple, complex, basaloid adenomas, fibroadenomas, benign mixed tumors, duct papillomas. Other described changes in the canine mammary gland include ductal, lobular, and epithelial hyperplasia, adenosis, cysts, duct ectasia, fibrosclerosis and gynecomatia.

DIAGNOSTIC IMAGING FOR THE IDENTIFICATION OF CARDIAC TUMORS IN HUMANS AND DOGS

C. M. Bussadori* S. Biasi** C. Quintavalla*** D. Pradelli*** L. Marconato****

*Clinica Veterinaria G.Sasso, Milan, Italy **Unit#224; Operativa di Cardiologia Clinica S.Carlo, Paderno Dugnano, Milan, Italy ***Istituto di Clinica Medica Facolta' di Medicina Veterinaria, Università di Parma ****School of Veterinary Medicine, Department of Pathobiology, University of Pennsylvania, USA

Diagnostic imaging (particularly echocardiography and MRI) has increased the frequency of identification of cardiac tumors. Although still uncommon, cardiac neoplasia is more than an academic curiosity. In human patients, benign tumors are more frequent than malignant, with myxomas being most prevalent. A sex predisposition has been observed, with a higher prevalence in females. Cardiac tumors are diagnosed in patients of all ages. The most frequent cardiac tumors in dogs are hemangiosarcomas, chemodectomas, ectopic thyroid carcinomas, and pericardial mesothelioma. For most of these tumor types there

is a demonstrated breed predisposition; for example chemodectomas are most commonly found in brachiocephalic breeds. Diagnostic imaging is needed to guide surgical treatment: surgical removal of these tumors has grown following the introduction of echocardiographic examination. Diagnostic imaging is useful even in prenatal diagnosis of cardiac neoplasias such as rhabdomyoma and rhabdomyosarcoma. Almost all cardiac related tumors could be identified by echocardiography, particularly intracardiac ones. When transthoracic echocardiography is unable to fully evaluate the edges of cardiac masses, transesophageal echocardiography can be used to provide more complete diagnostic information. MRI synchronized with cardiac cycle can achieve additional information. Echocardiography and MRI are complementary diagnostic tools. In the dog, cardiac tumors are commonly typified by echocardiography based on their peculiar morphological features. Even in human patients, echocardiography and MRI give enough information to identify the type of cardiac tumor.

DRUG-INDUCED LIVER DISEASES

H. Denk

Department of Pathology, University of Graz, Graz, Austria

The liver is the central organ of drug metabolism and also a major target of drug toxicity. Many drugs and chemicals are potentially hepatotoxic, including drugs used for treatment of liver diseases. It is known from several studies that about 2% to 10%, in older age groups even more, of hospitalized icteric patients are drug victims and about 25% of acute necrotizing liver diseases are related to drug intake. Moreover, drugs are also causes of chronic liver diseases. Practically all types of acute and chronic liver disorders can be drug-induced. Therefore, diagnosis depends on close cooperation between the pathologist and clinician, and particularly on the information about the patient. The diagnosis of adverse drug effects is important since further administration of a drug potentiates liver injury and may even lead to a chronic course.

Hepatotoxic drugs can be divided into intrinsic and idiosyncratic types. Intrinsic hepatotoxins mostly have cytotoxic and less often cholestatic effects, which are dose-dependent, fairly well predictable with a short latent period. The lesions are reproducible in animal experiments. Liver disease due to this type of drugs is rather rare and

mostly associated with overdose. A typical example is acetaminophen (paracetamol) intoxication.

Liver injury caused by idiosyncratic liver toxins is more often seen. Only a small percentage of susceptible patients are affected. These drug effects are unpredictable and usually not experimentally reproducible. The latent period between the drug administration and onset of liver disease is often long and variable, but shorter latent periods are seen upon readministration. The idiosyncratic type of drug-induced liver injury is either caused by an immune response against the drug or a metabolite in association with cellular proteins, or by genetically determined variations in drug metabolism and resulting toxic metabolites.

The morphologically detectable consequences of adverse drug reactions are variable and in principle nonspecific, although eosinophilia, pigment-containing macrophages, steatosis, and ductular reaction are suggestive of drug etiology. Morphologic alterations comprise adaptive responses of hepatocytes, hepatic and non-hepatic lesions, granuloma formation, cholestasis, finally fibrosis or even cirrhosis, and vascular and neoplastic changes.

Cellular adaptation with increased amounts of smooth endoplasmic reticulum is morphologically characterized by ground glass-like appearance of hepatocytes, predominantly in centrilobular areas.

The most frequent manifestations of intrinsic hepatotoxins are steatosis (macro- or microvesicular) and necrosis, usually in acinar zone 3. Macrovesicular steatosis for example may result from the administration of corticosteroids, the microvesicular form may be caused e.g. by tetracyclins, anticonvulsants or anti-inflammatory drugs. Microvesicular steatosis often results from the inhibition of mitochondrial β -oxidation. Parenchymal necrosis may be zonal (perivenous, periportal, intermediate), non-zonal or massive. Intrinsic hepatotoxins tend to the induction of zonal, idiosyncratic or non-zonal necroses. Typically, perivenous zonal necrosis is caused by an overdose of paracetamol.

Acute hepatitis may follow the administration of diverse drugs, including anesthetics but also herbal preparations. It resembles an idiosyncratic reaction with latent periods between exposure and manifestation of liver disease varying between days and months. The morphology is similar or even identical to acute viral hepatitis with variable degrees of necrosis, steatosis, cholestasis, lobular activity and portal inflammation. The presence of epithelioid cell granulomas suggests drug etiology. A classical example of this type of drug reaction is halothane hepatitis. In its early stage, centrilobular necrosis caused by toxic

metabolites prevails, whereas in the later stage the hepatic picture predominates. This adverse reaction to halothane occurs in about 1 to 10 of 30000 exposed individuals but the frequency increases to about 1 in 100 following multiple exposures.

Multiple or prolonged exposures to certain drugs may lead to chronic liver disease. Drug-induced chronic hepatitis is indistinguishable from chronic viral or autoimmune hepatitis both with respect to morphology and serology (e.g., occurrence of autoantibodies). Drug-induced chronic hepatitis is often accompanied by pronounced lobular necrosis, lymphocytic, plasmacytic and eosinophil-granulocytic inflammation in variable combinations. Chronic hepatitis may be induced by acetaminophen (paracetamol), tetracyclins, sulfonamides, anti-inflammatory, anticonvulsive, antihypertensive and antiarrhythmic drugs.

Steatohepatitis, characterized by steatosis, hepatocellular ballooning, Mallory body formation, inflammation and pericellular fibrosis, morphologically resembling alcoholic hepatitis, can be caused by a variety of drugs, including synthetic estrogens, amiodarone, methotrexate and tamoxifen. The risk of development of steatohepatitis is enhanced by obesity.

Cholestasis is a common manifestation of drug-induced liver disease. It may be classified as canalicular, hepatocanalicular or ductular. Pure canalicular cholestasis without morphologic signs of liver cell damage and inflammation occurs in a small percentage of genetically susceptible individuals after administration of 17- α -alkylated anabolic or contraceptive steroids. Jaundice usually develops 1-6 months after commencement of treatment. In contraceptive pills, the estrogen component is the major mediator of cholestasis. Hepatocanalicular cholestasis develops, e.g., in 1%-2% of patients treated with chlorpromazine and is associated with portal and lobular inflammation of varying degrees, enlargement of hepatocytes, multinucleation and mitoses. The lesion may vary from almost pure cholestasis to pronounced hepatitis.

Chronic drug-induced cholestatic conditions are occasionally observed and may be accompanied by bile duct lesions finally leading to a vanishing bile duct syndrome.

About 30% of granulomas in the liver are drug-induced. Hepatic granulomas should, therefore, always raise suspicion of an adverse drug reaction. Many drugs can be incriminated, with non-steroidal anti-inflammatory drugs playing a major role in this respect.

The vascular system of the liver may also be the target of adverse drug reactions (anabolic and contraceptive steroids, cytostatic drugs, herbal preparations), which in-

clude sinusoidal dilatation (anabolics, contraceptives) and endothelial lesions with resulting veno-occlusion disease (cytostatic drugs).

The association of hepatocellular adenomas with long-term administration of contraceptives and anabolics is a well known although a rather rare event. The risk associated with contraceptives increases with prolonged intake, higher estrogen content and in individuals of older (above 30 years) age groups.

In conclusion, drug-induced lesions of the liver show a variable morphology on liver biopsy. The diagnosis is important since discontinuation usually results in recovery. Drug-induced liver injury should always be considered in patients with hepatobiliary symptoms, particularly in older age groups and in females who are more susceptible. Close cooperation between the pathologist and clinician is an imperative to establish a correct diagnosis.

General Reading

1. SCHEUER PJ, LEFKOWITZ JH. Liver biopsy interpretation. London, Edinburgh, New York, Philadelphia, St. Louis, Sydney, Toronto: W.B. Saunders, 2000.
2. SHERLOCK S. Diseases of the liver and biliary system. 8th Ed. Oxford, London, Edinburgh, Boston, Melbourne: Blackwell Scientific Publications, 1989.
3. ZIMMERMAN HJ. Hepatotoxicity. The adverse effects of drugs and other chemicals on the liver. 2nd Ed. Philadelphia: Lipincott Williams & Wilkins, 1999.
4. ZIMMERMAN HJ, ISHAK K. Hepatic injury due to drugs and toxins. In: Mac SWEEN RNM, BURT AD, PORTMANN BC, ISHAK KG, SCHEUER PJ, ANTHONY PP, eds. Pathology of the liver, London, Edinburgh, New York, Philadelphia, St. Louis, Sydney, Toronto: Churchill Livingstone, 2002: 621-709.

THE ONE MEDICINE CONCEPT: APPLICATIONS IN VETERINARY AND HUMAN CLINICAL TOXICOLOGY

R. H. Poppenga

American Board of Veterinary Toxicology
Diagnostic Toxicology Laboratory, School of Veterinary
Medicine, University of Pennsylvania, Philadelphia, USA

The School of Veterinary Medicine at the University of Pennsylvania was founded in 1884. The aims of the School, as stated in the Announcement of its formation, were "to give instruction, both theoretical and practical, in all branches pertaining to the scientific study of the elements of medicine, and the practical application of

these elements to the domestic animals, in the preservation of their health, in their employment as useful aids to man, and in the diseases to which they are subject." Thus, from the outset, the School was identified as a branch of medicine. Of note, ten of the School's original faculty had M.D. degrees. The philosophy of there being only "one medicine", involving both humans and animals, has guided the school over the last 117 years. Veterinary medicine has certainly benefited from advances in human medicine in a number of specialty areas, including veterinary clinical toxicology. Conversely, veterinary medicine has improved the health and well-being of people in many significant ways. More specifically, veterinarians and veterinary toxicologists have contributed to the advancement of the specialty of human clinical toxicology by 1) improving the diagnosis and treatment of human and animal toxicant-induced disease, 2) improving our understanding of toxicologic mechanisms and comparative toxicology and pathology, 3) enhancing the recognition of new and emerging toxicologic threats, and 4) preventing human and animal toxicant-induced disease. Veterinary toxicologists and analytical chemists have been at the forefront in the utilization of a variety of analytical techniques for the detection of toxicants in a number of biological and environmental matrices. The day-to-day use of inductively coupled plasma argon emission spectroscopy (ICPAES) for the diagnosis of metal intoxications was first instituted in veterinary diagnostic toxicology laboratories. Adaptation of sophisticated analytical techniques for broad-based toxicant screening continues with the use of liquid chromatography – mass spectroscopy and ICP-mass spectroscopy systems. Veterinarians were early investigators of the safety and efficacy of fomepizole (4-methylpyrazole) for the treatment of ethylene glycol intoxication of dogs. From a comparative toxicology standpoint, recent investigations in cats have demonstrated species differences with regard to the effectiveness of fomepizole to inhibit alcohol dehydrogenase. The impact on human health of persistent organic pollutants such as PCBs has been difficult to assess. Investigation of seal mortalities in the Baltic has demonstrated that ingestion of PCB-contaminated fish can impair immune function and potentially exacerbate infectious disease outbreaks. Such studies have direct application to the potential risks to humans of eating PCB-contaminated foodstuffs. Aflatoxins were first isolated from peanut meal during investigations of an epizootic of "turkey X" disease in England; histopathologic examination of affected turkeys demonstrated the hepatotoxicity of these mycotoxins. Subsequent studies revealed their ani-

mal and human carcinogenic potential. Veterinary toxicologists were the first to isolate and chemically characterize the fumonisin mycotoxins, common contaminants of corn and the cause of several animal diseases including equine leucoencephalomalacia (ELEM). Isolation and chemical characterization of these mycotoxins has led to considerable investigation into their mechanism(s) of toxic action and their potential impact on human health. Veterinary toxicologists play an essential role in preventing toxicant-induced human disease. They are involved in assuring that feedstuffs intended for livestock consumption are free of chemical contaminants that might result in violative residues in meat, milk and eggs destined for human consumption. Investigation into unexplained food-animal deaths by veterinary toxicologists often prevents chemically-contaminated animal products from being used as human food. Veterinary toxicologists play an essential role in the use of animals as biomonitors of environmental quality. The diagnosis of lead exposure and/or intoxication in a household is often initially made in a pet such as a dog or cat. Such a diagnosis can prevent significant exposure of young children to lead or early recognition of an adverse effect. In the U.S., the establishment of the National Animal Poison Control Center (NAPCC) nearly 15 years ago has provided a valuable database of animal exposures to toxicants. The NAPCC database assists in the recognition of potential toxicant hazards to humans. For example, information on the intoxication of animals by some human dietary supplements has been useful in characterizing their potential hazard to people. Additional animal poison information services are now available in England and France. In summary, veterinary clinical toxicologists interface directly with their human colleagues in a variety of ways. It is important that human and veterinary clinical toxicologists recognize that there is only "one clinical toxicology" and seek ways to promote and exploit such a concept for the mutual benefit of our human and animal patients.

DIAGNOSIS OF SOLITARY CYSTS OF MAMMAE

N. V. Bogomolova, M. A. Mikhel, N. A. Bigeldina
Saratov State Medical University, Saratov, Russia

The diagnosis of mammary cysts in women does not pose major difficulties for most physicians experienced in the treatment of the given pathology. Nevertheless, the se-

quence of diagnostic measures and interpretation of their outcomes are not always optimum either from the point of reliable verification of the diagnosis, or of diagnostic completeness of this condition. Interesting experience in the diagnosis of mammary cysts has been collected at the Saratov regional center of family planning and reproduction. A series of 107 cases of mammary cysts appearing as solitary cysts were found to be multiple, monolateral or bilateral cysts. It is necessary to note that the efficiency of clinical diagnosis of cysts largely depends on their performance – depth, degree of filling, and possible imitation of fatty involution of mammae. Taking it into account, in case of solitary cyst revealed by clinical examination, diagnostic ultrasonography before traditionally used pneumocystography is helpful. Considering high (98%) specificity of the examination for the diagnosis of cysts, similar tactics does not only allow for detection of nonpalpable cysts, but also evaluation of their size and localization. For precise topologic picture of the cyst localization, single biopsy with consequent pneumocystography can be used. In this way, the radiation is considerably reduced as compared with radiography. Moreover, this approach need not be limited exclusively by ultrasonography finding, as pneumocystography allows for more concrete investigation of the internal wall for availability of cysts and choice of subsequent treatment.

FINE NEEDLE ASPIRATION CYTOLOGY OF ADENOID CYSTIC CARCINOMA OF THE BREAST. REPORT OF THREE CASES WITH THIN-PREP AND IMMUNOCYTOCHEMICAL STUDIES

E. Garcia Ureta, A. Veiga Barreiro
Hospital Juan Canalejo As Xubias, Spain

Adenoid cystic carcinoma (ACC) of the breast is a rare neoplasm, yet its diagnosis is important because it has an excellent prognosis compared to most other malignancies of the breast. In this communication, our experience with three cases of AAC of the breast is presented in which the diagnosis was based on fine-needle aspiration cytology (FNAC). In three female patients aged 78, 60 and 49, FNAC was performed according to standard procedure using a 23-gauge needle. Two slides were stained with Papanicolaou and another two slides with May-Grünwald-Giemsa. Additional slides were stained with alcian blue and PAS (before and after diastase digestion). In two

cases, the needle was rinsed in Preserv CyT solution after each pass and the material obtained from the rinse was used for Thin-Prep technique, along with the material obtained from a new FNAC. Immunocytochemistry was performed using standard methods. The antibodies used included keratin, epithelial membrane antigen, vimentin, S-100 protein, smooth muscle actin, laminin and type IV collagen. Cytologic findings were typical for cribriform ACC in each case. The May-Grünwald-Giemsa and Papanicolaou stained slides showed three-dimensional clusters of uniform cells with cystic spaces. The nuclei were round and uniform, small and ovoid, with fine chromatin and scanty cytoplasm arranged around cores or spheres of homogeneous acellular material. The cystic spaces contained cyanophilic amorphous material that stained positive for PAS and alcian blue stains. Thin-Prep slides contained less cells. It showed good correlation with conventional preparation. Cytomorphology in Thin-Prep slides allowed a definitive diagnosis. Immunocytochemical studies demonstrated positive staining of epithelial cells with low-molecular-weight cytokeratin. Antibodies to S-100 protein and smooth muscle actin demonstrated positive staining of other cells within papillary groupings consistent with myoepithelial cells. Studies for type IV collagen and laminin showed intense staining of the spherules. The aspirate yielded a typical smear composed of round, multilayered clusters of uniform cells arranged around cores of homogeneous, acellular material, strongly suggestive of the diagnosis of ACC. The cytologic differential diagnosis includes adenosis tumor, collagenous spherulosis, pleomorphic adenomas, adenomyoepithelioma and pseudo-adenoid cystic carcinoma. To our knowledge, the ACC cases reported here are the first examples of this type of breast cancer assayed by Thin-Prep technique.

PRIMARY MALT LYMPHOMA OF THE BREAST. A CASE WITH CYTOLOGIC AND IMMUNOCYTOCHEMICAL DIAGNOSIS

E. Garcia Ureta, A. Veiga Barreiro, J. M. Mosquera Reboredo, G. Matheu Capó
Hospital Juan Canalejo As Xubias, Spain

Primary lymphoma of the breast is rarely considered in differential diagnosis of a breast mass. The incidence in different studies varies from 0.076% to 0.53% of malignant lesions of the breast. It accounts for 10% of all breast sarcomas, 2.2% of all extranodal non-Hodgkin's

lymphomas, and 0.38% of all non-Hodgkin's lymphomas. Low-grade lymphomas of the breast, particularly mucosa-associated lymphoid tissue (MALT) lymphomas, have been exceedingly rare. In this report, we present cytologic features of a patient with breast MALT lymphoma. An 81-year-old woman presented with a 2-month history of a right breast mass detected by mammography, not associated with pain or any other symptoms. There was no other remarkable medical history. Fine-needle aspiration (FNA) biopsy of the breast was performed. A total of six Papanicolaou and May-Grünwald-Giemsa stained slides were prepared. Additional material was used for immunocytochemical studies with CD20 and CD3 primary antibodies. Cytologic features: the smears showed a relatively uniform population of lymphoid cells. Scattered large, thick clusters of epimyoeplithelial cells with intimately associated lymphocyte tangles were also present. Normal mammary gland acini were absent. The lymphocytes were composed of predominantly small-sized cells with round to irregular nuclear outlines, the chromatin was coarse and with small nucleoli, the cytoplasm was scant and basophilic. Immunocytochemical studies revealed that lymphoid cells were B-cells (CD20 +). Histology, immunohistochemical and gene rearrangement studies confirmed the cytologic diagnosis. The material obtained from our patient had a distinctive cytologic morphology. Monoclonality was demonstrated by immunocytochemistry. Differential diagnosis of FNA biopsy material from mammary gland lesions includes reactive lymphoid tissue. To our knowledge, this is the first description of a low-grade MALT lymphoma in a mammary gland to be diagnosed by FNA.

FINE NEEDLE ASPIRATION CYTOLOGY OF MAMMARY PSEUDOANGIOMATOUS STROMAL HYPERPLASIA: REPORT OF THREE CASES

E. Garcia Ureta, A. Veiga Barreiro, J. M. Mosquera Reboredo, G. Matheu Capó
Hospital Juan Canalejo As Xubias, Spain

Pseudoangiomas stromal hyperplasia (PASH) was first described by Vuitch *et al.* in 1986 as a benign lesion composed of stromal tissue proliferation with a complex pattern of interconnected spaces. Clinical features of PASH consist of a palpable, mobile, firm painless mass. This report describes fine needle aspiration cytology

(FNAC) features of three cases of mammary PASH that presented as palpable masses. In three female patients aged 40, 37 and 39, the lesion presented as a discrete, painless, unilateral breast mass. The three cases were clinically and mammographically diagnosed as fibroadenoma. In these patients FNAC was performed using 23 to 25 gauge needles. All subsequently obtained surgical specimens were routinely processed and stained with Papanicolaou and May-Grünwald-Giemsa. The three patients' samples showed a similar aspect. The aspirates were cellular showing large fragments of monolayered two-dimensional ductal epithelium. There were clusters of cohesive ductal cells dispersed throughout the smears. Scattered groups of poorly cellular stromal fragments and a background with bipolar, naked nuclei were also identified. Grossly, the tumors were well circumscribed, with a smooth external surface and a variable consistency from firm to rubbery. Microscopically, the tumors were composed of intermixed stromal and epithelial elements. The histologic features were identical to those of classical cases of PASH. In all cases, the most striking histologic finding was a complex pattern of anastomosing empty spaces in the collagenized hypocellular stroma. Although the benign nature of PASH can generally be recognized on FNAC material, the cytologic features are not specific, and its distinction from fibroadenoma and fibrocystic changes is not possible. In addition, it is crucial to correlate the clinical characteristics, mammographic studies and cytologic findings in order to avoid a diagnosis of malignancy.

FINE NEEDLE ASPIRATION CYTOLOGY OF MAMMARY ADENOMYOEPITHELIOMA. A CASE REPORT

E. Garcia Ureta, A. Veiga Barreiro, G. Matheu Capó, J. M. Mosquera Reboredo
Hospital Juan Canalejo As Xubias, Spain

Adenomyoepithelioma is a rare breast lesion, which was first described by Hamperl in 1970. Although the histologic features of adenomyoepithelioma have been well described, there are few literature reports documenting the cytology of these lesions. The purpose of this communication is to describe the FNA cytology features in a case of adenomyoepithelioma. A 57-year old female presented with a hump in the upper outer quadrant of the right breast. No other symptoms or signs were present. Smears were prepared from fine needle aspirate of the

hump. Air-dried smears were stained with May-Grünwald-Giemsa and alcohol-fixed smears were stained with Papanicolaou stain. The aspirates were cellular and consisted of large tightly cohesive aggregates of cells along with small amounts of stromal material. Stromal material was randomly distributed throughout cellular aggregates. On high power, two cell types were identified. One type was predominantly basaloid, spindle-shaped with cytoplasm varying from clear to eosinophilic. The nuclei were rounded with minute nucleoli. The second cell type was columnar to cuboidal, having finely granular eosinophilic to foamy cytoplasm, globoid nuclei and prominent nucleoli. Numerous bare nuclei were present. Mitotic figures were absent. Histologic examination showed the classic features of adenomyoepithelioma. Adenomyoepithelioma has a dual component of epithelial and myoepithelial cells. The presence of myoepithelial cells is a helpful finding in identifying some proliferative lesions of the breast as benign. Benign and malignant lesions are adenosis tumor, collagenous spherulosis, pleomorphic adenoma and adenoid cystic carcinoma in which myoepithelial cells are a prominent and diagnostically important component. These lesions should be considered on differential diagnosis. More cases of myoepithelial cells in the lesion of the breast have to be studied in order to understand better their cytologic features.

FINE NEEDLE ASPIRATION CYTOLOGY OF PLEOMORPHIC ADENOMA OF THE BREAST. CASE REPORT

E. Garcia Ureta, A. Veiga Barreiro, J. M. Mosquera Reboredo, G. Matheu Capó
Hospital Juan Canalejo As Xubias, Spain

Pleomorphic adenoma of the breast (PAB) is an uncommon but known benign neoplasm that might be misinterpreted both clinically and pathologically as a malignant tumor. There are only sporadic case reports of these lesions in the breast. We herein report the cytologic characteristics of an additional PAB diagnosis by fine-needle aspiration (FNA). An 80-year-old woman presented with a mass in her left breast that had persisted for two months. No other lesions were observed. The patient underwent ultrasound guided FNA of the mass using a 22-gauge needle. Air-dried smears were stained with May-Grünwald-Giemsa (MGG) and alcohol-fixed smears were stained with Papanicolaou stain. Cytologic examination of the aspirate revealed mod-

erate cellularity with isolated cells or clusters of epithelial cells. The smears showed both small dense clusters and large loose, irregular clusters with fuzzy margins or a spindle cell core. The lesion was composed of uniform, small cells with round to oval nuclei with finely granular chromatin. Epithelial cells contained abundant cytoplasm with distinct cytoplasmic borders with a plasma cell-like appearance in isolated cells. Fibrillary chondromyxoid ground substance was observed. Mytotic figures were absent. The surgical specimen showed a typical picture of pleomorphic adenoma. Thus in the aspirate, a dual population of epithelial and myoepithelial cells were identified in cell aggregates and numerous bare nuclei were present. Cytologic differential diagnosis of pleomorphic adenoma is wide. The main cytologic differential diagnoses include fibroadenoma and low grade phyllodes tumor. Aspirates from these lesions may contain large cellular aggregates with a dual population of epithelial and myoepithelial cells, abundant bare nuclei and stromal elements. Adenosis tumor, collagenous spherulosis, adenomyoepithelioma and adenoid cystic carcinoma should be considered on the differential diagnosis of breast aspirates containing a dual population of cells.

ASSOCIATION BETWEEN HER2/NEU EXPRESSION AND HORMONE RECEPTOR STATUS IN BREAST CANCER PATIENTS

Yashar G¹, Basheska N¹, Kraveva S², Vasev N², Ivkovski Lj¹, Prodanova I¹, Kubelka K¹, Smichova S², Zografski G¹
Department of Histopathology and Clinical Cytology¹,
Institute of Radiotherapy and Oncology², Skopje
Medical Faculty, Skopje, Republic of Macedonia

Determination of HER2/neu expression by immunohistochemistry is mandatory for application of Herceptin® therapy in breast cancer patients. The purpose of this study was to investigate the association between HER2/neu expression and hormone receptor status, as well as with other clinicopathological parameters in breast cancer patients. HER2/neu, p53 and Ki-67 expression was determined in 169 postoperative stage I-III (UICC, 1997) breast cancer patients using the standardized DAKO HercepTest® and immunoperoxidase technique, respectively. The results of HER2/neu immunoreactivity were evaluated by performing the standardized scoring system (0 = negative, 1+ = weakly positive, 2+ = positive, 3+ = strongly positive staining), while ER and PgR were scored in a semiquantitative fashion (ER-ICA and PR-ICA). The results from HER2/

neu expression were correlated to hormonal receptor status and clinicopathological parameters (tumor size, histopathologic grade, nuclear grade, histologic type of the tumor, lymph node status and patient age). Statistical significance was determined with χ^2 and Fisher's exact test. HER2/neu expression was positive in 66 patients (37%). There was no significant association between the values of HER2/neu and ER/PgR status, or with any other clinicopathological parameter. ER status significantly correlated with PgR status ($p < 0.01$), tumor size ($p < 0.01$), lymph-node involvement ($p < 0.01$) and tumor type ($p < 0.01$). PgR status was related to the histopathologic grade ($p < 0.01$), lymph-node status ($p < 0.01$), tumor type ($p < 0.01$) and patient age ($p < 0.01$). HER2/neu is a relatively new promising marker in predicting the response to target specific therapy. However, its predictive value remains a complex and inconclusive subject. According to our results, the prognostic potential of HER2/neu seems to be independent from hormone receptor status and any other clinicopathological parameter in breast cancer patients.

IMMUNOHISTOCHEMISTRY OF MALE BREAST CANCER

D. Tomas, H. Jurlina, M. Glasnović, T. Leniček, M. Elez, V. Gladić, B. Krušlin
Ljudevit Jurak University Department of Pathology,
Sestre milosrdnice University Hospital, Zagreb, Croatia

Although common in females, breast cancer is very rare in males. It accounts for less than 1% of all cancer cases in males and less than 1% of all breast cancer cases. Due to its rarity there is very little information available regarding male breast cancer. The objective of this study was to shed some light on male breast cancer statistics by using breast cancer cases found in the cancer cases registry of the Sestre milosrdnice University Hospital and comparing them to other similar studies. Data were collected in 21 (0.88%) male patients, out of a total of 2380 male and female patients in whom breast cancer was diagnosed as the result of biopsies performed at the Ljudevit Jurak University Department of Pathology during the 1980-2001 period (22 years). Special attention was paid to the last six cases of male breast cancer found in the 1995-2001 period. Formalin fixed and paraffin embedded tumor tissues were cut into 5-mm sections, deparaffinized and stained with hematoxylin and eosin. Immunohistochemistry for estrogen, progesterone, prostate specific antigen

(PSA) and HER-2/neu was also performed. The mean age in 21 male patients with breast cancer at the time of diagnosis was 62.4 years, which is consistent with other clinical studies of male breast cancer. The mean percentage of male breast cancer cases was 0.88%, which is in agreement with <1% of male breast cancer cases reported in other studies. Nineteen of 21 (90.4%) male breast cancer cases were infiltrating ductal (NOS: no other specified), one (4.8%) was intraductal, and one (4.8%) medullary cancer. Special attention was paid to all biopsies performed in males with breast cancer during the 1995-2001 period. These six were tested for estrogen and progesterone receptors as well as for the presence of PSA and HER-2/neu (c-erbB-2) markers. Five (83.3%) of these six patients were positive for estrogen receptors, and six (100%) were positive for progesterone receptors. None (0%) of the six tumors tested positive for PSA markers, and the HER-2/neu (c-erbB-2) marker was positive in only one (16.6%) of the six biopsies performed in the 1995-2001 period. The mean age (62.4) in 21 male patients with breast cancer at the time of diagnosis is in accordance with the respective literature data. The percentage of male breast cancer *vs.* female breast cancer was 0.88%, which is comparable with <1% found in other studies. The absence of PSA positivity in male breast is in agreement with other studies, suggesting that PSA is not useful as a tumor marker. The low percentage of HER-2/neu markers (16.6%) as compared with other similar studies, reporting on 29% positivity, was most likely the result of the low number of biopsies taken in consideration.

CORRELATION OF CYTOLOGIC AND HISTOLOGIC DIAGNOSES OF THE BREAST

I. Maričević, M. Šokčević, S. Čurić-Jurić and F. Jurić*
Department of Cytology, Sestre milosrdnice University Hospital, *Zagreb University School of Medicine, Zagreb, Croatia

Fine-needle aspiration cytology (FNAC) is widely used in the diagnosis of breast lesions and selection of patients for surgical treatment. In our Department of Cytology during in three-year period FNAC was performed in 1485 patients, in most cases under ultrasound guidance. In a group of 124 women who underwent surgical treatment at our hospital, preoperative cytologic findings were malignant in 73 cases, benign in 47 cases, and 4 specimens were inadequate. Postoperative histology found 80 carcinomas and

44 benign lesions. The rate of concordance between the cytologic and histologic diagnoses was high except for the cases with a cytologic diagnosis of atypical epithelial hyperplasia. Statistical analysis revealed the sensitivity of FNAC for the presence of carcinoma to be 93.50%, specificity 97.77%, positive predictive value 98.63% and negative predictive value 89.36%. These results confirm that FNAC is a highly reliable method in the diagnosis of breast lesions.

METASTASIS OF BREAST CANCER TO UTERINE CERVIX: A CASE REPORT AND REVIEW OF THE LITERATURE

M. Eržen, M. Lenart, I. Košorok, J. Šinkovec, N. Puhan, M. Čavić, D. Kopač
Dept. of Obstetrics and Gynecology, University Medical Centre, Ljubljana, Slovenia

A patient with abnormal cervical cytology resulting in the detection of breast cancer metastasis is presented, and the literature on breast cancer metastasis to the uterine cervix (BCMC) was updated until March 2002, with special emphasis on the clinical and cytopathological diagnosis. A 60-year-old woman was repeatedly referred to gynecologist during 6 years after menopause, because of postmenopausal symptoms, bleeding and discharge, atrophic vaginitis and abdominal pain. Endometrial curettage revealed no malignancy. PAP test was negative during these 6 years. However, the last cervical smear revealed borderline glandular cells. After 5 months, the repeated smear revealed severely dyskaryotic glandular cells with clear background, and the patient was referred to cervical curettage and biopsy. In the biopsy, subepithelial stroma was diffusely infiltrated by small cancer cells arranged in a distinctive single file pattern. Cancer cells stained positive for cytokeratin. The arrangement of neoplastic cells was essentially different from the usual infiltration pattern of squamous cell- or adenocarcinoma, and metastases of breast cancer (lobular histologic type) was suspected. At clinical examination, bilateral multiple tumors of the breast were detected metastases in bone and lungs were confirmed on x-rays. The patient was treated by chemotherapy and hormonal treatment, but she died 22 months after the diagnosis. BCMC is a rare phenomenon. Similar to other uncommon secondary tumors of uterine cervix, they may be overlooked on the differential diagnosis of usual disorders of the genital tract. On the Medline search, 50 reported cases of BCMC were collected.

Twenty-seven cases were found in the reports reviewed from 1950 to 1999. In 21% of these, metastases were found before or at the same time as the primary tumor. The most common clinical symptom was abnormal vaginal bleeding (57%), also present in our patient. However, 32% of the patients were without clinical signs of cervical malignancy, and 41% of cases were only found at autopsy. The statement that more than 80% of primaries with uterine metastases are of the invasive lobular type was not supported by the observations of other authors. Pap test failed to reveal cervical metastasis in one third of the cases. Analysis of 33 Pap smears with the cells originating in extrauterine carcinomas, confirmed histologically, showed that the ovary, gastrointestinal tract and breast were the most frequent primary sites (85% of cases). Several studies have indicated that the lack of tumor diathesis is characteristic of metastatic carcinoma, a notion not supported by the others.

It is generally agreed that BCMC is rare, occurs in the advanced stage of the disease and poses diagnostic problems. Pap test can serve as a diagnostic tool as well as an adjunct test to staging and patient's treatment.

BASIC PATHOLOGIC FINDINGS IN BREAST CARCINOMA DURING A FIVE-YEAR PERIOD

J. Bezić, S. Tomić, A. Alujević, B. Vrbičić
Department of Pathology, Split Clinical Hospital, Split, Croatia

Aim of the study: As a result of the use of screening mammography, many breast biopsies are now performed for small, non palpable, mammographically detected abnormalities. In contrast to breast biopsies in the premammographic era, breast biopsies for mammographic abnormalities contain a greater number of small invasive cancers (minimal breast cancer), *in situ* carcinomas, tubular carcinomas and atypical hyperplasias. Twenty-five years ago, only 3%-5% of all breast cancers were ductal *in situ* carcinomas (DCIS), almost exclusively of comedo high-grade type. Presently the proportion of breast carcinomas diagnosed as DCIS has increased to 15%-40% of all breast cancers in screening centers, and these DCIS are predominantly of non-comedo type. The aim of this study was to estimate the proportion of *in situ* carcinomas and small invasive cancers as well as other basic histopathologic features of breast carcinomas surgically removed at the Split Clinical Hospital during a 5-year period. We analyzed the basic pathologic features of 942 breast carcinomas, oper-

ated at the Split Clinical Hospital, in the 1997-2001 period. We divided the tumors into four groups according to their greatest diameter: tumors with diameter ≤ 1 cm, 1-2 cm, 2-3 cm, and with greatest diameter >3 cm. Carcinomas were classified into the usual histologic types, and tumor grade was assigned according to the Bloom-Richardson grading system. Tumors with positive one or more lymph nodes at all axillary levels were considered node positive. The number of operated carcinomas at the Split Clinical Hospital was 181 in 1997 and 1998, 190 in 1999, 183 in 2000 and 207 in 2001. The rate of small invasive cancers (≤ 1 cm) was 16.07%. The highest percentage was found in the group of the tumors with greatest diameter of 1-2 cm (35.71%), followed by the group with a diameter of 2-3 cm (25.56%) and >3 cm (22.21%). There were 69.83% of ductal invasive carcinomas, 10.70% of lobular carcinomas, and 4.1% of mixed ductal and lobular carcinomas. The rate of *in situ* carcinomas was only 3.24%, with a predominance of high and intermediate grade of ductal *in situ* carcinomas. The highest number of carcinomas were moderately differentiated (42.51%), 33.57% of tumors were well differentiated and 23.91% of tumors were poorly differentiated. There were 49.82% of node positive patients. Our results showing a small proportion of breast carcinomas diagnosed as *in situ* carcinomas, and small proportion of minimal invasive breast cancer are similar to the results in the premammographic era in the western world. Better results on this issue can be achieved by organization of screening centers and by achieving highest percentage of mammographic screening in the female population.

MACROPHAGE LEVELS AND PARENCHYMAL EXPRESSION OF MONOCYTE CHEMOTACTIC PROTEIN-1 IN HUMAN INVASIVE DUCTAL BREAST CARCINOMA

T. Valković¹, S. Štifter², M. Hasan³, F. Dobrila⁴, N. Jonjić²
¹Departments of Internal Medicine, ²Pathology, ³Histology and Embryology, and, ⁴Surgery, Medical School, University of Rijeka, Rijeka, Croatia

Tumor associated macrophages (TAM) are a population of mononuclear-phagocytic cells, which can express complex functions related to tumor biology. Monocyte chemoattractant protein-1 (MCP-1) is a chemokine involved in the macrophage infiltration of tumor tissue. The aim of this study was to define the TAM level and the parenchymal

MCP-1 expression by immunohistochemical analysis in 97 invasive ductal breast carcinomas NOS; to investigate their possible relationship and to correlate their values with tumor size, grade, mitotic activity index (MAI), lymph node status and microvessel density (MVD). Furthermore, the expression and quantification of MCP-1 mRNA were determined by reverse transcriptase-polymerase chain reaction (RT-PCR) in 8 samples of invasive ductal breast carcinomas, 3 fibroadenomas and 8 samples of normal breast tissues. MCP-1 immunoreactivity was present in tumoral cells, but also in TAM, fibroblasts and endothelial cells. Statistical analysis did not show significant correlation between MCP-1 expression in tumoral epithelium and tumor size, grade, MAI, lymph node status, MVD, and TAM, while TAM showed a connection with tumor proliferation (MAI) ($p < 0.001$) and MVD ($p = 0.008$). In all cases of breast carcinomas (8/8) and in the majority of fibroadenomas (2/3) and normal breast tissues (7/8), the MCP-1 mRNA was detected by RT-PCR. It can be concluded that TAM play a protumoral role in invasive breast carcinoma NOS by promoting tumor proliferation and angiogenesis. According to immunohistochemical analysis, these results indicate that MCP-1 is not crucial for macrophage attraction to tumor locus in breast carcinoma but it must be pointed out that immunohistology is not the method of choice for estimating the chemoattractant potential of MCP-1. The results of RT-PCR indicate that all cases of breast carcinomas expressed MCP-1 mRNA in generally higher levels than non-malignant breast tissues. RT-PCR is a very good and objective method for determining the production of MCP-1 in tumors, or more precisely their mRNA.

RELATIONSHIP BETWEEN ABO BLOOD GROUPS AND PRIMARY BREAST CANCER PROGNOSIS

Mohammad Reza Jalali Nadooshan*, Hamid Reza Taheri*, Naser Valaei**
*Shahed University, **Shahid Beheshti University of Medical Science, Tehran, Iran

Breast cancer is the most common cancer in females, and multiple factors contribute to the prognosis of this cancer, one of the suggested being blood groups. Therefore, this study was designed to determine the relationship between ABO blood groups and prognosis.

This case-control study was performed in 200 patients (100 controls and 100 cases) and 1000 healthy persons

without breast cancer as a second control group. Control group patients with good prognosis had tumor size less than 2.5 cm without axillary node involvement, and case group with poor prognosis had tumor size greater than 2.5 cm with at least one axillary node involved. Patient blood groups were derived from their medical files.

Blood groups B and AB were more prevalent in the poor prognosis patients than in other groups. Antigen B was found in the control group (30.5%) and case group (45%). OR equaled 1.8 in this study. The probability of poor prognosis in those patients with breast cancer who expressed AgB ranged from at least 1.2 to up to 2.8-fold that in the general population.

It is concluded that blood group antigen B correlates with poor prognosis of breast cancer, and evaluation of its role requires further prospective studies with patient follow-up.

RELATIONSHIP BETWEEN PATIENT AGE, GRADE OF BREAST CANCER AND DISEASE PROGNOSIS

Mohammad Reza Jalali Nadooshan*, Hamid Reza Taheri*, Naser Valaei**
**Shahid Beheshti University of Medical Science, *Shahed University, Tehran, Iran

Concerning the prevalence of breast cancer and its well-known prognosis as well as the role of patient's age and disease grade in the prognosis, and in order to determine the relationship of grade and age with prognosis, we performed a study in patients referred to 3 university hospitals during 7 years. This case-control study included 200 patients with breast cancer: 100 cases were selected on the basis of involvement of at least 1 lymph node, and tumor size greater than 2.5 cm (case=poor prognosis) and another 100 patients selected on the basis of absence of the above criteria (control=good prognosis). Grading based on Bloom-Richardson criteria was identified. The mean age of control group patients was 42.5 ± 8.8 , and of case group 53.4 ± 12.2 yrs, yielding a 25.6% difference. Also, development of breast cancer at age > 50 may increase the probability of poor prognosis by 17 times. The probability of poor prognosis in grade III was 5.6-fold that found in grade I. Age and grade both influence the prognosis of breast cancer and other studies with patient follow-up are recommended.

PROGNOSTIC SIGNIFICANCE OF LYMPHATIC AND BLOOD VESSEL INVASION BY TUMOR CELLS IN COLORECTAL CARCINOMA

S. Tomić, S. Anđelinović, L. Puljak*, V. Pešutić-Pisac, J. Bezić, K. Milostić, G. Trgo*

Department of Gastroenterology, *Department of Pathology, *Department of Urology, Split Clinical Hospital, Split, Croatia

This study was undertaken to examine the prognostic value of lymphatic and blood vessel invasion by tumor cells in colorectal carcinoma. In this study, 100 patients with colorectal carcinoma were examined. Vessel invasion by tumor cells was examined in formalin fixed, paraffin embedded tissue using standard hemalaun-eosin method, Verhoeff method and immunohistochemistry (anti-human von Willebrand's factor, DAKO, EPOS). Vessel invasion by tumor cells positively correlated with higher tumor grade ($p=0.0001$), Dukes stage ($p=0.0001$), occurrence of metastatic disease in 5-year period ($p=0.0001$), and lower 5-year survival ($p=0.0001$). Lower 5-year survival rate was observed in patients with vascular invasion considering correction of the stage too (Dukes B: $p=0.018$; Dukes C: $p=0.0002$). However, when we compared 5-year survival period in patients with Dukes stage B and Dukes stage C when blood vessel invasion was confirmed, we did not find any statistically significant difference ($p=0.62$). Lymphatic and blood vessel invasion may be independent prognostic criteria in patients with colorectal carcinoma. Moreover, it seems that using this parameter it is possible to separate a subgroup of patients with colorectal carcinoma in Dukes B stage with worse prognosis who need postoperative adjuvant therapy.

MESENCHYMAL PANCREATIC TUMORS

G. Cecchetto, R. Cecchetto, C. Clemente, G. Marchesini, A. Pennelli, Galligioni
Istituto di Anatomia Patologica, Padua, Italy

Mesenchymal pancreatic neoplasias are extremely rare, compared with the epithelial, neuroendocrine or cystic ones, and occasionally their histogenesis may not be for sure assessed even by immunohistochemistry. The most conspicuous casuistics is that of Ferrozzi *et al.* from 2000, including 2 lymphangiomas, 2 lipomas, 4 schwannomas, 1 neurofibroma, 2 leiomyosarcomas, 1 undifferentiated

sarcoma and 9 non-Hodgkin lymphomas. Apart from this study, in the literature we found only isolated case reports. In the last four years, we observed 446 pancreatic lesions in adults: 1 liposarcoma (diagnosed by aspiration cytology and successively confirmed by histology), 1 spindle cell sarcoma, 262 adenocarcinomas, 56 neuroendocrine tumors, 18 cystic lesions, 83 pancreatitis, 23 pseudocysts, 13 tumors of the Vater ampulla, 5 pancreatic infiltrations of lymphoma, and 3 of leiomyosarcoma. The pathologist must be very careful in the diagnosis of primary pancreatic sarcoma, as most of them are spindle cell carcinoma or pancreatic infiltration of retroperitoneal sarcomas.

ESOPHAGEAL HEMANGIOPERICYTOMA AS AN ACCIDENTAL ENDOSCOPIC FINDING. A CASE REPORT

D. Baličević¹, I. Novosel², D. Hrabar³

¹Ljudevit Jurak Department of Pathology, Sestre milosrdnice University Hospital, Zagreb

²Department of Pathology, Dr Ivo Pedišić County Hospital, Sisak

³University Department of Medicine, Sestre milosrdnice University Hospital, Zagreb, Croatia

Hemangiopericytoma is a rare malignant vascular tumor that derives from pericytes. It is common in extremities and retroperitoneum, but extremely rare in gastrointestinal tract.

According to recent literature, only two cases refer to esophageal localization. We report the first case of hemangiopericytoma in the gastroesophageal region. A 56-year-old patient presented to the gastroenterologist for dyspeptic problems. As recommended therapy with H2-receptor antagonist showed no improvement, gastroendoscopy was done. By visual inspection, ventricular mucosa appeared slightly reddish, but with normal rugal folds.

A prominent and accidental finding was a polypoid mass located at the very gastroesophageal border. It looked like a sessile polyp of coin size, grayish, with rough surface. During the same act, biopsy of gastric mucosa in the region suspect of chronic gastritis as well as polypectomy were performed.

Pathohistologic examination confirmed chronic gastritis. The tumor-like mass had a characteristic staghorn appearance of capillary branches, surrounded by nests of ovoid cells, with no mitoses. Silver impregnation showed

extremely positive reaction, while immunohistochemical staining revealed negative reaction to cytokeratin and CD34.

As hemangiopericytoma is an uncommon vascular neoplasm with a vascular pattern similar to many other tumors, it is usually diagnosed by exclusion. The following parameters should be included: vasculature, histologic pattern, degree of cellular pleomorphism, necrosis, mitoses and giant cell content. Immunohistochemistry is crucial for the accurate diagnosis of hemangiopericytoma.

References

1. BURKE J S, *et al.* Hemangiopericytoma of the esophagus. *Hum Pathol* 1981;12:96-100.
2. MIDDLETON L P, *et al.* The histological spectrum of hemangiopericytoma: application of immunohistochemical analysis including proliferative markers to facilitate diagnosis and predict prognosis. *Hum Pathol* 1998;29:636-40.
3. KOWALSKI P J, *et al.* Proliferation index as a prognostic marker in hemangiopericytoma of the head and neck. *Head Neck* 2001; 492-6.

HCV-LIKE HCV-NEGATIVE HEPATITIS IN OLT

A. Cecchetto, G. Cecchetto, R. Clemente,
C. Marchesini, G. Pennelli, A. Galligioni
Istituto di Anatomia Patologica, Padua, Italy

HCV infection is the most frequent event in a transplanted liver, both in HCV-positive and HCV-negative recipients. In long-term follow-up, the recurrence rate of HCV is from 87% to 100% of transplanted livers, and within 1 year, 32% to 100% of the patients are affected by acute or chronic hepatitis or cirrhosis. Histologic lesions in OLT may be observed even without any clinical or serologic marker, because of immunosuppressive therapy, and HCV DNA can be detected by PCR analysis before or without an antibody response. Moreover, 10% of HCV negative recipients may be infected by blood transfusion during transplantation or by the presence of HCV in the donor tissues. The morphological features of HCV hepatitis in a transplanted liver are quite modified by immunosuppressive therapy; differential diagnosis includes a large spectrum of OLT-related pathology such as HBV infection, cellular rejection, recurrence of PBC, and opportunistic infections. In more than 560 OLT performed in Padua, almost one half of the patients were not HCV positive, and among them we observed 11 cases – 3 pediatric – affected by HCV-like HCVC-negative hepatitis. TTV

was found in 2 out of 6 cases. In our opinion, the detection of TTV does not necessarily mean that it is the virus responsible for HCV-like HCVC-negative hepatitis, as it is widespread and inconstantly hepatotoxic.

MUCINOUS COLORECTAL CARCINOMAS IN BIOPSIES, 1996-2001

D. Brezovečki-Bidin¹, D. Baličević¹, D. Tomas¹,
L. Tuzović¹, M. Škarica¹, N. Bulj¹, S. Hrkač-Knežević¹,
D. Ciglar¹, V. Radotić¹, T. Leniček¹, M. Glasnović¹,
D. Kovačević² and M. Belicza¹
Ljudevit Jurak University Department of Pathology¹
University Department of Surgery²
Sestre milosrdnice University Hospital, Zagreb, Croatia

SUMMARY – Mucinous colorectal carcinomas show some clinicopathological characteristics that are not found in nonmucinous carcinomas. A total of 1451 colorectal carcinomas were analyzed. Carcinomas were divided into two groups according to the presence or absence of mucinous content. Then, three independent pathologists reviewed all slides with carcinomas with mucinous content by microscopic morphometry and divided them into two subgroups: mucinous carcinomas (>50% mucin) and colorectal carcinomas with mucin (<50% mucin). The following parameters were analyzed: share of mucinous colorectal cancer and cancer with mucin, sex and age distribution of all three groups of carcinomas, and localization and Dukes stage of mucinous carcinomas and carcinomas with mucin. Mucinous carcinomas were confirmed to have poorer prognosis, predilection for younger age group, higher incidence in the proximal colon, and no male predomination. Colorectal carcinomas with mucin had some characteristics of both mucinous cancer and nonmucinous cancer, and could be positioned somewhere in between these two different groups.

Key words: *colorectal carcinoma, mucinous colorectal carcinoma, colorectal carcinoma with mucin*

Introduction

The rates of colorectal cancer incidence vary considerably when observed worldwide, according to sex, age and anatomic subsite, and have changed over time¹. In Europe, especially in eastern countries, and in the United States,

colorectal cancer is on the second place of all cancer-related deaths. About 98% of all colorectal tumors are adenocarcinomas. Many of them produce different amounts of mucin, which is secreted into the gland lumen or into the gut wall². Mucinous colorectal carcinomas are defined on the basis of the amount of the mucus component in the tumor mass, and the term mucinous carcinoma may only be applied to the carcinomas that contain $\geq 50\%$ of the mucinous component³. The role of a large extracellular mucinous component in colorectal carcinomas continues to be controversial. In some authors' opinion, these tumors have a predilection for younger age groups, involve the more proximal colon, there is no male predomination, are more advanced at diagnosis, and have a poorer prognosis than nonmucinous colorectal carcinomas⁴. The poorer prognosis and aggressive clinical course are directly influenced by the percentage of mucinous component⁵. Apart from this quantitative criterion, some genetic alterations (e.g., frequency of mutation ki-ras and p-53 genes, level of Muc2 expression) also differentiate these tumors from the nonmucinous ones⁶⁻⁸. The purpose of this report is to analyze some clinicopathologic features of mucinous colorectal carcinomas in our environment. We compared colorectal cancer with and without mucinous content, and also the same parameters within the group of colorectal cancer with mucinous content according to the amount of mucin ($>50\%$ of mucinous content and $<50\%$ of mucinous content). The following parameters were analyzed: share of mucinous colorectal cancer and cancer with mucin, sex and age distribution of all three groups of carcinomas, and localization and Dukes' classification of mucinous carcinomas and carcinomas with mucin⁹.

Patients nad Methods

Patient data were obtained from the computer based colorectal cancer registry at the Ljudevit Jurak University Department of Pathology, for the period between January 1, 1996 and December 31, 2001. A total of 1451 colorectal carcinomas were analyzed. Formalin fixed, paraffin embedded tumor tissue was cut at 5-mm sections, deparaffinized, stained with hematoxylin and eosin, and examined for the presence of mucin. Carcinomas were divided into two groups according to the presence or absence of mucinous content. Then, three independent pathologists reviewed all slides with carcinomas that had mucinous content by microscopic morphometry and divided them into two subgroups: mucinous carcinomas and

colorectal carcinomas with mucin. When 50% or more of high-power fields examined consisted of mucinous tumor tissue, the term mucinous carcinoma was applied. For carcinomas with less than 50% of mucinous content the term "carcinoma with mucin" was applied³.

Results

We detected 160 (11%) colorectal carcinomas with mucinous content, 95 (6.5%) mucinous carcinomas, and 65 (4.5%) carcinomas with mucin. The share of mucinous colorectal carcinomas and carcinomas with mucin increased over the 6-year period from 4.4% to 14.9% (Fig. 1). The male/female ratio was lower in mucinous carcinomas and carcinomas with mucin than in carcinomas without mucin, except for the year 1996 when the male/female ratio was 3.5. In 1999, the number of female patients with mucinous colorectal carcinoma and carcinoma with mucin was higher than the number of male patients (male/female ratio 0.9) (Fig 2). The mean age of patients with mucinous colorectal carcinoma and carcinoma with mucin was slightly lower than the mean age of patients with carcinoma without mucin. The mean age of patients with mucinous cancer and cancer with mucin was lowest in 1996 (only 61.3 years) and highest in 1998 (69.7 years). Comparison of the mean age of all three groups of patients (mucinous carcinomas, and carcinomas with and without mucin) revealed it to be lower in patients with mucinous carcinomas than in other patient groups, but similar in patients with carcinomas with mucin and those with carcinomas without mucin (Fig. 3). Mucinous carcinomas and carcinomas with mucin were predominantly located in the rectum ($>40\%$), followed by ascending and sigmoid colon with an almost identical percentage of cases ($\sim 20\%$), and then transverse colon ($\sim 10\%$). Localization remained unknown for 5.2% of mucinous carcinomas and 6.2% of

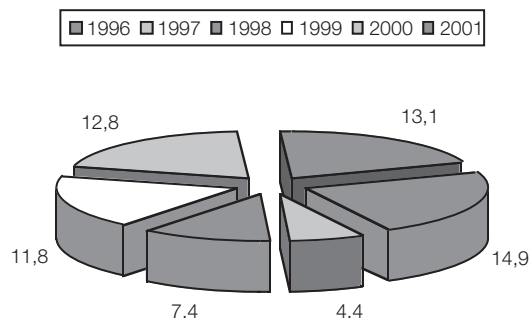


Fig. 1. Percentage of mucinous colorectal carcinomas and carcinomas with mucin from 1996 till 2001.

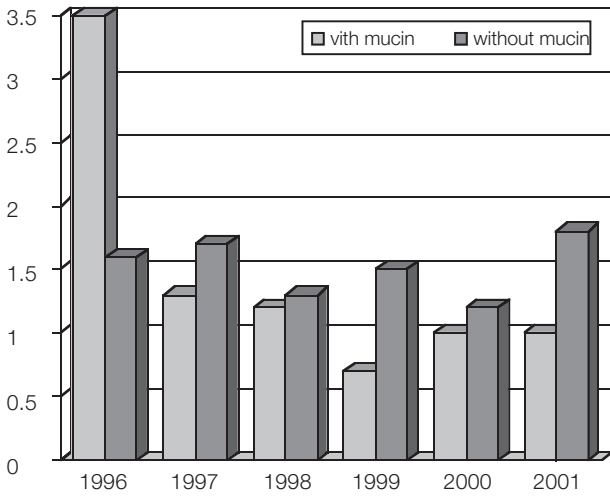


Fig. 2. Male/female ratio in carcinomas with mucinous content (all carcinomas that contained mucin) compared with colorectal carcinomas without mucin.

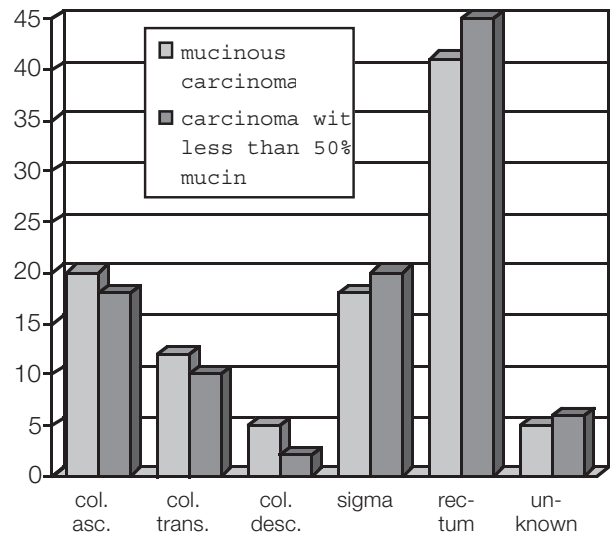


Fig. 4. Distribution of mucinous carcinomas and carcinomas with mucin according to localization.

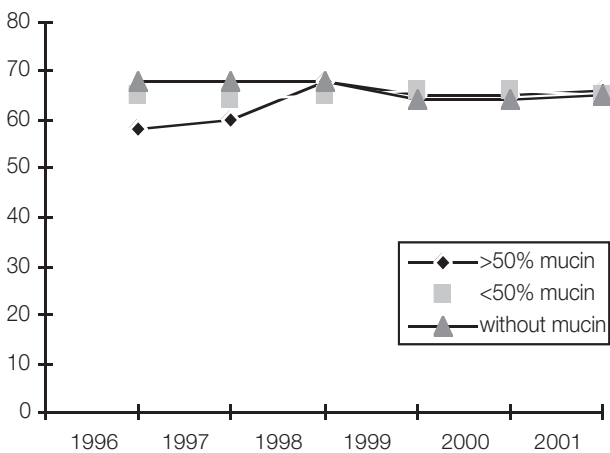


Fig. 3. Mean age of patients with mucinous carcinomas, carcinomas with mucin and carcinomas without mucin.

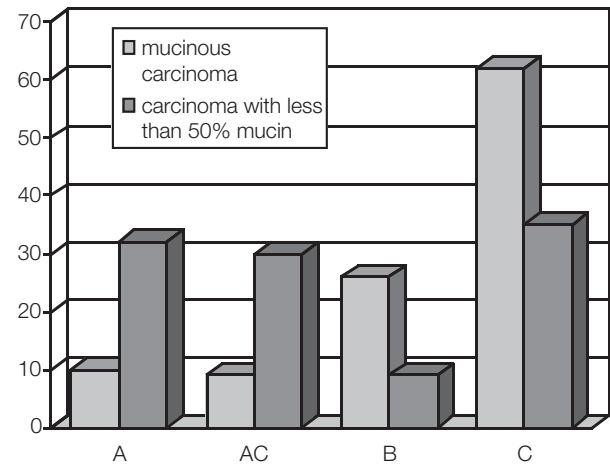


Fig. 5. Comparison of Dukes stage of mucinous carcinomas and carcinomas with mucin.

carcinomas with mucin (Fig. 4). Comparison of Dukes classification between mucinous carcinomas and carcinomas with mucin showed more mucinous carcinomas to be in Dukes stage C (62.1%) on detection. Also, many of these were in Dukes stage B (23.2%), and only 8.4% and 6.3% were in Dukes stage A and AC, respectively. On the other hand, 33.9% of carcinomas with mucin were in Dukes stage C at the time of detection. A similar number of carcinomas with mucin were in Dukes stage A, AC and C (30%). A smaller number of carcinomas with mucin were in Dukes stage B (7.7%) (Fig. 5).

Discussion and Conclusion

Some studies have indicated that a finding of mucinous carcinomas may be an adverse prognostic factor, affecting on an average younger patients, showing no male predomination, and having poorer prognosis. This poorer prognosis and aggressive biological behavior of mucinous carcinomas were directly connected with the mucinous component⁶⁻⁸. In some other studies, an association with decreased survival was demonstrated only when mucinous carcinomas and signet ring cell carcinomas were grouped

together and compared to non-mucinous carcinomas. However, data on this type may be merely a reflection of the aggressive clinical course of signet ring cell carcinomas¹⁰. According to these authors, the mucinous histologic type itself was not an independent prognostic factor in colorectal carcinomas¹¹.

The results presented show an increased number of mucinous colorectal carcinomas and carcinomas with mucin. The share of these types of tumor increased more than 3-fold during the observed period. The results also showed that there was no strong male predominance for this type of colorectal carcinoma, and female had an almost identical risk for this tumor type. The population affected with mucinous colorectal cancer were in general younger than the population who had cancer without mucinous content. The median age was approximately the same in patients with carcinoma with mucin and those with nonmucinous carcinoma. Comparison of mucinous cancer and cancer with mucin revealed an almost identical distribution of the two types and confirmed their higher incidence in proximal colon than of carcinomas without mucinous content. Comparison of Dukes staging between mucinous carcinomas and carcinomas with mucin showed higher Dukes stage in mucinous carcinomas at the time of detection, which may be related to the amount of mucinous content. We confirmed that mucinous carcinomas had poorer prognosis, predilection for younger age group, higher incidence in proximal colon, and no male predomination, however, the group of mucinous cancers also included signet ring cell carcinomas. Colorectal carcinomas with mucin had some characteristics of both mucinous cancer and nonmucinous cancer, and could be positioned somewhere in between these two groups. Further epidemiological studies are needed to assess the true behavior of colorectal carcinomas with less than 50% of mucinous content, and effects of signet ring cell carcinoma on some of the parameters examined in this study.

References

1. DEVESSA SS, CHOW WH. Variation in colorectal cancer incidence in the United States by subsite of origin. *Cancer* 1993;71:3819-26.
2. COTRAN RS, KUMAR V, COLLINS T. Pathologic basis of disease. 6th ed. Philadelphia: W.B. Saunders, 1994:833.
3. GREEN JB, TIMMCKE AE, MITCHELL WT, HICKS TC, GATHRIGHT JB Jr, RAY JE. Mucinous carcinoma – just another colon cancer? *Dis Colon Rectum* 1993;36:49-54.
4. NOZOE T, ANAI H, NASU S, SUGIMACHI K. Clinicopathological characteristics of mucinous carcinoma of the colon and rectum. *J Surg Oncol* 2000;75:103-7.
5. SUMA KS, NIRMALA V. Mucinous component in colorectal carcinoma – prognostic significance: a study in a south Indian population. *J Surg Oncol* 1992;51:60-4.
6. HANSKI C. Is mucinous carcinoma of the colorectum a distinct genetic entity? *Br J Cancer* 1995;72:1350-6.
7. YOUNES M, KATIKANENI PR, LECHAGO J. The value of the preoperative mucosal biopsy in the diagnosis of colorectal mucinous adenocarcinoma. *Cancer* 1993;72:3588-92.
8. JI BT, DEVESA SS, CHOW WH, JIN F, GAO YT. Colorectal cancer incidence trends by subsite in urban Shanghai, 1972-1994. *Cancer Epidemiol Biomarkers Prev* 1998;7:661-6.
9. DUKES CE. The classification of cancer of rectum. *J Pathol Bacteriol* 1932;35:323-2.
10. MULCAHY HE, SKELLY MM, HUSAIN A, O'DONOGHUE PP. Long-term outcome following curative surgery for malignant large bowel obstruction. *Br J Surg* 1996;83:46-50.
11. WU CS, TUNG SY, CHEN PC, KUO YC. Clinicopathological study of colorectal mucinous carcinoma in Taiwan: a multivariate analysis. *J Gastroenterol Hepatol* 1996;11:77-81.

Sažetak

Mucinozni adenokarcinomi debelog crijeva se po nekim svojim kliničko-patološkim obilježjima razlikuju od nemucinoznih adenokarcinoma. Napravljena je revizija svih karcinoma debelog crijeva od 1996. do 2001. godine. Karcinome s mucinoznim sadržajem dodatno su pregledala tri neovisna patologa te su podijeljeni u dvije podskupine: mucinozni karcinomi (više od 50% sluzi) i karcinomi s mucinom (manje od 50% sluzi). Dobiveni rezultati pokazuju povećanje udjela karcinoma s mucinoznim sadržajem u ukupnom broju kolorektalnih karcinoma. Predispozicija obolijevanja od karcinoma s mucinoznim sadržajem podjednaka je za oba spola dok su muškarci češće obolijevali od nemucinoznih karcinoma. Usporedba prosječne dobi pokazala je da su bolesnici s mucinoznim karcinomima prosječno mlađi od onih s nemucinoznim i karcinomima s mucinom. Lokalizacija mucinoznih karcinoma i karcinoma s mucinom je bila podjednaka i primjetan je pomak u desni dio kolona. Usporedba Dukesove klasifikacije mucinoznih karcinoma i onih s mucinom pokazala je da se u trenutku dijagnosticiranja većina mucinoznih karcinoma nalazi u Dukesovu stadiju C, za razliku od karcinoma s mucinom kojih je u času dijagnosticiranja bilo podjednako u Dukesovu stadiju A, AC i C bolesti. Dobiveni rezultati pokazuju da se po nekim svojim obilježjima mucinozni karcinomi razlikuju od nemucinoznih, dok karcinomi s mucinom posjeduju neke osobitosti i jednih i drugih.

Ključne riječi: *karcinomi debelog crijeva, mucinozni karcinomi, karcinomi s mucinom*

INCIDENCE OF HISTOLOGIC PATTERN AND ANATOMIC DISTRIBUTION OF COLORECTAL CARCINOMA (1989-2001)

D. Brezovečki-Bidin, D. Baličević, D. Tomas, L. Tuzović, M. Škarica, N. Bulj, S. Hrkač-Knežević, D. Ciglar, V. Radotić, M. Glasnović, T. Leniček, M. Belicza
Ljudevit Jurak University Department of Pathology, Sestre milosrdnice University Hospital, Zagreb, Croatia

The aim of this study was to examine the incidence of colorectal carcinoma during a 13-year period according to histologic pattern, anatomic localization, and sex and age distribution. This study was also linked to our previous study where colorectal carcinomas were divided according to the prewar, war and postwar periods, as we wanted to compare some basic conclusions.

A total of 2559 patients with colorectal cancer were analyzed. Patient data were obtained from the computer based colorectal carcinoma registry established at the Ljudevit Jurak University Department of Pathology, Sestre milosrdnice, University Hospital, Zagreb, Croatia. We examined the total number of colorectal carcinoma and their incidence in all biopsies made during the 13-year period, share of mucinous colorectal carcinomas, sex distribution, mean age, and anatomic localization, where carcinomas were divided into four subgroups: right sided (cecum and colon ascendens), transverse (transverse colon), left sided (descendent colon, sigma and rectum), and unknown localization.

During the study period, 148699 biopsies were made, and 2559 or 1.7% were colorectal carcinomas. The incidence of colorectal carcinomas slightly increased between 1989 and 1993 but from 1994 this trend rose faster and in 2001 the number of colorectal carcinomas was two fold than in 1989 (Fig 1). The mean share of mucinous carcinomas was 6.5% (n=166), varying from 0.6% in 1990 to 16% in 1993 (Fig. 2.). The mean age ranged from 62.1 years in 1990 to 68 years in 1995, with overall mean for the study period of 65.6 years (Fig 3). Sex distribution showed male predominance (58.6% vs. 41.4%) (Fig. 4). Left-sided cancers were most common (66.1%) followed by right-sided (8.7%) and transverse colon cancers (6.2%). In 19.3% of cases the localization of colorectal carcinomas remained unknown (Fig 5).

The results showed a significant increase in the incidence of colorectal carcinomas, especially in the last nine years. The rate of mucinous carcinomas altered with two unexplainable peaks in 1993 and 1994, when the total

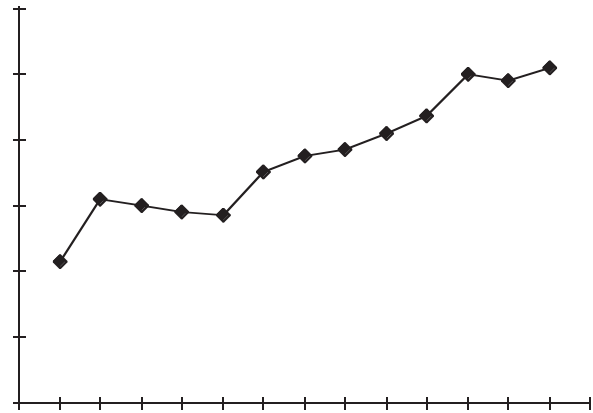


Fig. 1. Incidence of colorectal carcinoma 1989-2001.

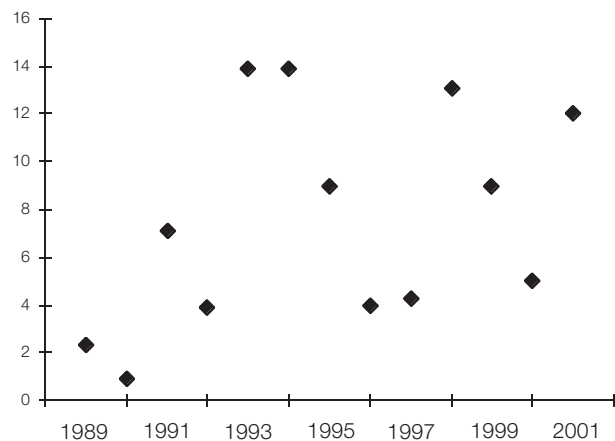


Fig. 2. Incidence of mucinous colorectal carcinoma 1989-2001.

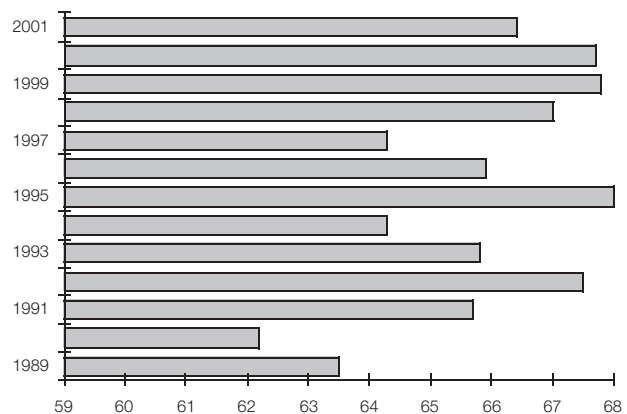


Fig. 3. Mean age of patients with colorectal carcinoma 1989-2001.

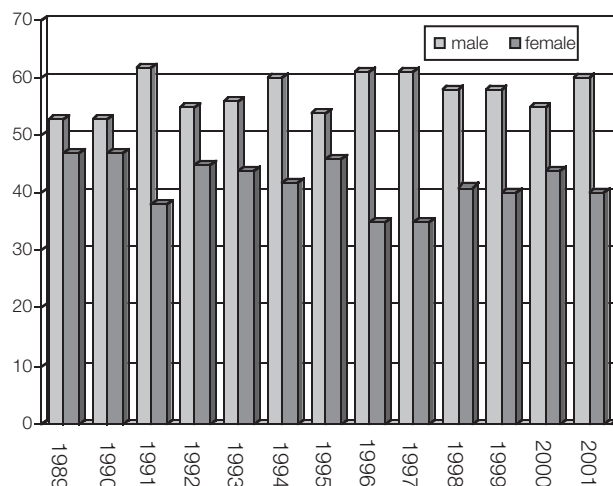


Fig. 4. Sex distribution of patients with colorectal carcinoma 1989-2001.

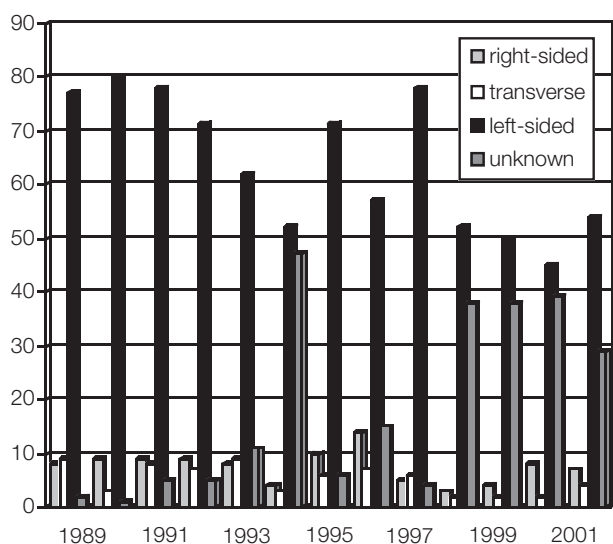


Fig 5. Localization of colorectal carcinoma 1989-2001.

number of colorectal carcinomas slightly decreased. The mean age and sex distribution were as expected and close to recent literature data. The localization was also as expected, however, a slight decrease in left sided carcinoma during the 13-year period was obvious. In conclusion, the study pointed to the significant increase in colorectal carcinoma in our population, with no significant change in age and sex distribution, and a slightly decreased incidence of rectosigmoidal cancer, which is a trend noticed in western countries some years before. The obtained data also confirmed the conclusions from our previous studies.

References

1. TUZOVIC L, *et al.* Comparison of colorectal cancer features during three periods in hospital cancer registry. *Acta Clin Croat* 2001;40:291-7.
2. CHATTAR-DORA D, *et al.* Colorectal cancer in a multi-ethnic urban group: its anatomical and age profile. *Int Surg* 2000;85:137-42.
3. MANSER MD. Colorectal cancer registration: the central importance of pathology. *J Clin Pathol* 2000;53:875-7.

INFLUENCE OF DIFFERENTIATION GRADE EXPRESSED BY GLEASON SCORE ON SURVIVAL IN PROSTATE CANCER PATIENTS

K. Milostić, S. Tomić, G. Trgo, I. Olujić

Department of Urology and Department of Pathology, Split Clinical Hospital, Split, Croatia

Through a retrospective clinical study we present the influence of differentiation grade (Gleason score) on survival in patients with prostate cancer. The study included operative material of 50 prostate cancers, overall age 72.5 (51-87) years. The patients were operated on with transurethral resection (35%-70%) and classic transvesical adenomectomy (15%-30%). After histologic analysis, Gleason score was determined. The patients were classified in three groups: well (Gleason score 2, 3 and 4), moderately (Gleason score 5, 6 and 7) and poorly differentiated carcinomas (Gleason score 8, 9 and 10). Comparison of survival of patients with well and moderately differentiated carcinomas showed no statistically significant survival difference (log rank=3.41; $p=0.065$). Comparison of survival of patients with moderately and poorly differentiated carcinomas revealed no statistically significant survival difference either (log rank=2.09; $p=0.148$). However, comparing the groups with well and poorly differentiated carcinomas, a statistically significant difference (log rank=14.7; $p=0.0001$) was found. Because of that, we separated moderate group of the carcinomas with a cut off-7 and obtained high statistical significance in survival (log rank=8.73; $p=0.031$). Patients with Gleason score 2-6 had average survival of 94 months, but patients with Gleason score 7-10 had average survival of only 47 months. Univariate analysis of the differentiation grade showed the high statistical significance to be a prognostic factor in patients with prostate carcinoma. Differentiation grade is clinically useful to identify tumors with poor and good biological behavior, as well as patients in whom there is a good reason for radical surgery and adjuvant postoperative therapy.

MULTIVARIATE STATISTICAL ANALYSIS OF MOLECULAR DATA ON APC AND CDH1 GENE INVOLVEMENT IN RENAL CELL CARCINOMA AND CLINICAL PARAMETERS OF THE DISEASE

N. Pećina-Šlaus¹, K. Gall-Trošelj², K. Pavelić², J. Pavelić²

¹Department of Biology, School of Medicine, University of Zagreb, ²Division of Molecular Medicine, Ruder Bošković Institute, Zagreb, Croatia

When investigating cancer at the molecular level, data obtained by the methods of molecular biology are usually compared and correlated with only one clinical parameter at the time resulting in one-dimensional approach to statistical analysis. The employment of multivariate statistical methods simultaneously correlates and weighs all investigated parameters offering new insights into the problem. In this paper, the data obtained investigating renal cell

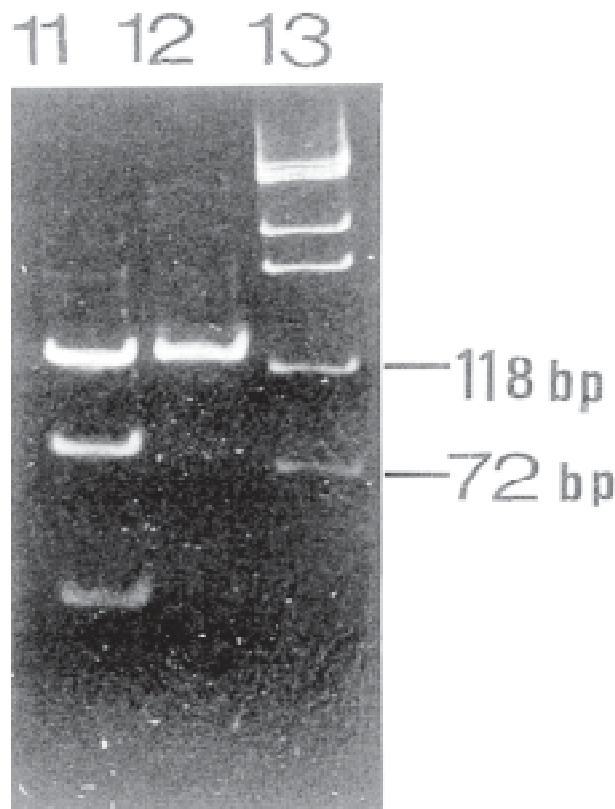


Fig. 1. Loss of heterozygosity at APC in renal cell carcinoma. Exon11/RsaI/RFLP, 13% polyacrylamide gel stained with ethidium bromide: lane 1 - informative blood sample; lane 2 - LOH in corresponding renal carcinoma (cut allele is missing); lane 3 - molecular standard (X174 DNA/HaeIII).

carcinoma (RCC) at the molecular level were analyzed by the multivariate statistical method (principal components) together with clinical parameters: TNM stage, histopathologic grade, age and sex.

Molecular analysis was confined to genetic instabilities of renal cell carcinoma regarding the roles of two tumor suppressor genes (adenomatous polyposis coli, APC and E-cadherin, CDH1). Both gene products are components of adherens junction, where E-cadherin is bound to β -catenin which in turn binds to the central part of the APC protein¹. Besides their structural roles in cellular architecture, protein products of APC and CDH 1 genes play signaling roles in the wnt signal transduction pathway^{2,3}.

Mutations in the adenomatous polyposis coli gene are responsible for the disease familial adenomatous polyposis (FAP) and the majority of sporadic colorectal cancer, but are also found in a large variety of other cancers⁴. The other gene investigated, E-cadherin, is one of the most important molecules of cell-cell adhesion in epithelial tissues. It is a member of a large family of genes that code for calcium-dependent-cell-adhesion-molecules (CAMs) and is generally localized on the surface of epithelial cells⁵. A number of epithelial cancers demonstrate loss of expression as well as mutations of E-cadherin gene. Recently a tumor invasion/suppressor role has been assigned to this gene.

Forty-five human renal cell carcinomas were tested for APC gene instability by polymerase chain reaction/loss of heterozygosity (LOH) using RFLP method⁶. E-cadherin gene (CDH1) was analyzed by PCR amplification of tetranucleotide marker (D16 S752) and the alleles were visualized by PAGE/silver staining. The overall proportion of LOH cases of the APC gene was 37.5% (9/24) (Fig.1). D16 S752 marker linked to E-cadherin gene (informativity 91%) revealed 3 (7.5%) LOH cases (Fig. 2A). In 10% of RCC samples another type of genomic instability was detected, replication error (RER) indicating that another cellular mechanism, mismatch repair, is targeted in RCC (Fig. 2B).

The results of the multivariate statistical analysis of the samples informative for both APC and E-cadherin genes showed that in this data set LOH of the APC gene positively correlated with advanced age and more severe TNM stages. Genomic instabilities of the E-cadherin gene, on the other hand, appear to be correlated with younger age groups and less severe TNM stages (Fig. 3).

Our results suggest that alterations in APC gene are not the first event in kidney tumorigenesis, but are involved in the progression of RCC. Analysis of E-cadherin involvement although less conclusive (because of the lower fre-

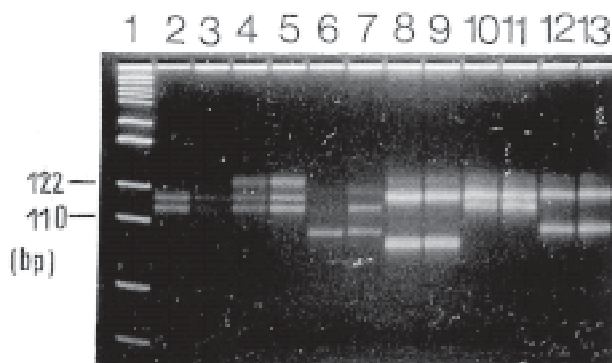
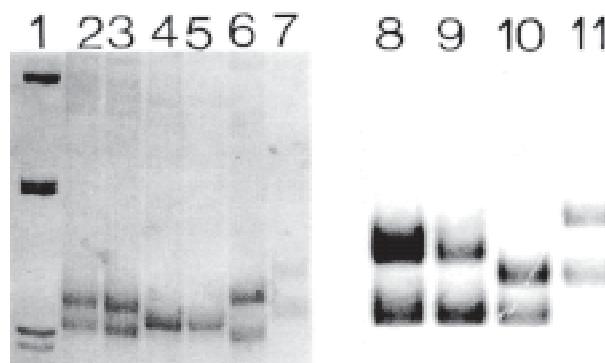


Fig. 2. A) LOH of the E-cadherin gene on Spreadex gel (Elchrom Scientific) stained with Sybergold (Molecular Probes). Polymorphic tetranucleotide repeat D16 S752 is shown (informativity 91%). Lane 1 - molecular marker M3 (Elchrom Scientific); lanes 2, 3, 4, 5, 8, 9, 10, 11, 12, 13 - heterozygous RCC and corresponding blood samples; lanes 6 - LOH of E-cadherin gene in RCC sample; lane 7 - corresponding informative blood sample.



B) Genetic instability (replication error, RER+) of E-cadherin gene on 15% polyacrylamide gel stained with silver: lane 1 - molecular standard M3; lanes 2, 3, 8, 9 - heterozygous RCC and corresponding blood samples; lane 4, 5 - homozygous (uninformative) RCC and blood samples; lanes 6, 10 - RER+ RCC samples; lanes 7, 11 - corresponding informative blood samples.



Fig. 3. Multivariate statistical analysis. Scatterplot of samples on first two principal components.

quency of APC changes) suggest that changes in this gene may be an earlier event. Given that E-cadherin is involved in diverse mechanisms in the cell it is also possible that the impairment of its function lies in transcriptional mechanisms.

References

1. SIEBER OM, TOMLISON IP, LAMLUM H. The adenomatous polyposis coli (APC) tumour suppressor - genetics, function and disease. *Mol Med Today* 2000;6:462-9.
2. PEIFER M, POLAKIS P. Wnt signaling in oncogenesis and embryogenesis - a look outside the nucleus. *Science* 2000;287:1606-9.
3. STOCKINGER A, EGER A, WOLF J, BEUG H, FOISNER R. E-cadherin regulates cell growth by modulating proliferation-dependent beta-catenin transcriptional activity. *J Cell Biol* 2001;154:1185-96.
4. KINZLER KW, VOGELSTEIN B. Lessons from hereditary colorectal cancer. *Cell* 1996;87:159-70.
5. GUILFORD P. E-cadherin downregulation in cancer: fuel on the fire? *Mol Med Today* 1999;5:172-7.
6. PEĆINA-ŠLAUS N, PAVELIĆ K, PAVELIĆ J. Loss of heterozygosity and protein expression of APC gene in renal cell carcinomas. *J Mol Med* 1999; 77:446-53.

VANISHING-BURNED LESION OF TESTICLE CANCER - TWO CASE REPORTS

K. Milostić S. Tomić, M. Glavina-Durdov, G. Trgo, I. Olujić
Department of Urology and Department of Pathology,
Split Clinical Hospital, Split, Croatia

The purpose of this presentation is to show that a testicular scar should not be ignored in young men, because it may represent an introduction in testicular cancer. Because of breathing difficulties the first patient was diagnosed as having lung cancer and was operated on. Pathohistology: pulmonary carcinoma of embryonal type. Urological examination revealed a knotty testicle, and orchiectomy was performed. Pathohistology: scar, hemosiderine pigment,

hemosiderophages, and mononuclear cell infiltrate without malignant cells. The second patient underwent orchiectomy because of trauma to the previously normal testicle with normal tumor markers. Pathohistology: scar with hemosiderine pigment, hemosiderophages and mononuclear cell infiltrate without malignant cells. After one year, numerous retroperitoneal lymph node metastases developed, with strongly elevated AFP and β -HCG markers. It is concluded that testicular cancers metastasizing in the lung should be considered in young men, because primary carcinoma is very rare in this population. In case of trauma to the testicle in young men, long-term follow-up of tumor markers and lymph node status is mandatory.

FINE STRUCTURE OF LEYDIG CELLS IN PATIENTS WITH NON-OBSTRUCTIVE AZOOSPERMIA

D. Ježek¹, N. Knežević², Lj. Banek¹, I. Krhen², V. Mužić¹, S. Kalanj-Bognar³, R. Pezerović-Panijan¹, Z. Mareković²

¹Institute of Histology and Embryology; ²Department of Urology, ³Institute of Chemistry and Biochemistry, Medical School, University of Zagreb, Zagreb, Croatia

Leydig cells are situated within the testis interstitium. These cells are an important source of testosterone, a male sex hormone that stimulates spermatogenesis. Therefore, the structural integrity of Leydig cells is necessary for the normal sperm production. The purpose of the study was to describe changes of the ultrastructure of Leydig cells in patients with non-obstructive azoospermia. A total of 44 testicular biopsies from infertile patients with non-obstructive azoospermia and 8 control biopsies were analyzed. In control biopsies, Leydig cells showed normal ultrastructure. A round or oval nucleus was situated mostly in the center of the cell. The chromatin of the nucleus was predominantly euchromatic, with a low presence of heterochromatin associated with the nuclear envelope. A prominent nucleolus was frequently observed. The cytoplasm of the cell was rich in cisternae of smooth endoplasmic reticulum and mitochondria with tubular cristae. Occasional cisternae of rough endoplasmic reticulum, glycogen, lipid droplets and Reinke's crystals were also observed. Leydig cells in infertile men with non-obstructive azoospermia had a significantly changed ultrastructure. The nucleus of such cells was often indented with the increased presence of heterochromatin. Within the cell cytoplasm, a lot of lipid droplets and vacuoles of the elec-

tron low-density content could be noticed. There was a reduction in the cisternae of smooth endoplasmic reticulum, glycogen and mitochondria. The presence of Reinke's crystals seemed to be reduced in the pathologically changed cells. However, it should be pointed out that all biopsies contained a limited number of Leydig cells with the normal fine structure. Leydig cells in patients with non-obstructive azoospermia showed significant changes in their ultrastructure. The cells with normal (unchanged) morphology were also observed within the same biopsies, but were less numerous. Electron microscopic observations on the fine structure of Leydig cells could help in the understanding of factors contributing to the male-factor infertility.

ULTRASTRUCTURAL ANALYSIS OF SPERMS WITH IMPAIRED MOTILITY – A CASE REPORT

V. Mužić¹, D. Ježek¹, P. Cvitković², Lj. Banek¹, P. Romac², D. Lučinger²

¹Institute of Histology & Embryology, School of Medicine, University of Zagreb

Vuk Vrhovac Institute, School of Medicine, University of Zagreb, Zagreb, Croatia

Causes of male-factor infertility are often multifactorial and include various disturbances of sperm motility, i.e. asthenospermia. Asthenospermia could be a consequence of anomalies of the sperm head or tail. In severe cases, these abnormalities could be combined resulting in severe teratospermia, which can be detected at the light microscopic level. However, only at the electron microscopic level a fine structure and anomalies of the sperm head and tail can be analyzed. This case report describes a patient with severe asthenospermia. A 30-year-old patient had normal sperm count with extremely poor motility (repeated spermograms). On an average, 97% of the sperms were immotile and 85% were polymorphic, as recorded by the computer-aided semen analysis. In order to perform an electron microscopic analysis, the ejaculate (minimum 3 days of abstinence, ~3 ml) was fixed in 4% glutaraldehyde (in 0.1 M phosphate buffer), postfixed in 1% OsO₄, dehydrated and embedded in Durcupan. Semithin and ultrathin sections were prepared by Reichert ultramicrotome. Ultrathin sections were placed on copper grids, contrasted and examined by a Carl Zeiss 902A electron microscope. Many sperms manifested various abnormalities of the head and tail. Normally structured sperms were only sporadically found. Abnormal sperms had often a globular appearance of the head

with a defect of chromatin condensation. Thus, the head of such sperms was by 2-3 μm bigger than in normal sperm. Within the chromatin of the head, sometimes membrane-like inclusions could be seen. Residual body, instead of being phagocitized, was often found attached to the nucleus. The acrosome showed various malformations and/or was smaller than usual. The tail also showed several types of abnormalities. The mitochondria within the proximal part of the tail were frequently missing, or the number of mitochondria was significantly reduced. The constellation of microtubules was disturbed in such a manner that the central pair of microtubules did not occupy the central position within the tail and was pushed aside. It is concluded that the ultrastructural analysis of semen sample could provide useful information on the sperm morphology. However, the electron microscopic examination of the semen should be done in strictly selected cases.

PERIACINAR CLEFT-LIKE SPACES IN PROSTATIC NEEDLE CORE BIOPSIES

B. Krušlin¹, I. Novosel², A. Reljić³, H. Čupić¹, B. Spajić³, M. Belicza¹

¹Ljudevit Jurak University Department of Pathology, Sestre milosrdnice University Hospital, Zagreb;

²Department of Pathology, Dr. Ivo Pedišić County Hospital, Sisak;

³Department of Urology, Sestre milosrdnice University Hospital, Zagreb, Croatia

The neoplastic cells of prostatic cancer often appear pulled away from the surrounding stroma leaving halos around the acini. These periacinar halos or so-called cleft-like spaces are often observed, especially in Gleason grade 3 prostatic carcinoma.

As the accurate diagnosis of prostatic carcinoma in needle core biopsies (NCBs) demands a sophisticated approach, there are many diagnostic criteria that should be satisfied.

The aim of our study was to analyze prostatic NCBs in order to determine the frequency of cleft-like spaces in tumors and non-tumorous prostatic tissue. We analyzed 20 sextant NCBs that were performed at the Department of Urology, Sestre milosrdnice University Hospital for clinical suspicion of prostatic carcinoma (PSA > 4.0 ng/ml and/or DRE and TRUS positive). After a pathohistologic diagnosis of adenocarcinoma in NCB, prostatectomy was performed. Specimens were fixed in 10% buffered formal-

dehyde, embedded in paraffin, cut at 5- μm thickness, and routinely stained with hematoxylin and eosin. In some cases, the material was stained with HMW-CK and alcian-PAS. Prostatectomy specimens underwent step crosssections and pathohistologic evaluation that confirmed the diagnosis of adenocarcinoma. As a control group, we used NCBs of 20 patients in whom no cancer was found. Out of 20 patients who were diagnosed as having prostatic adenocarcinoma in at least one of NCB specimens, 14 (70%) had a NCB with either focal or diffuse cleft-like spaces. In 5 (25%) cases, clefts were incompletely defined or less pronounced, which means that only half of acinus was circumscribed with empty periacinar space in at least three glandular structures. If each NCB specimen is considered as a sample *per se*, the diagnosis of adenocarcinoma was made in 58 of the total of 115 NCB samples. Concerning periacinar clefts, 23 (39.7%) specimens had clearly marked periacinar halos and in 25 (43.1%) they were incompletely defined, but present. In only 9 NCB specimens with the diagnosis of prostatic carcinoma there were no cleft-like spaces around the tumorous acini. In each of 20 cases, the prostatectomy specimens contained adenocarcinoma.

In the control group, there were no well-defined clefts observed in any of 119 NCB specimens. We conclude that cleft-like spaces could be a useful additional criterion in the diagnosis of prostatic adenocarcinoma in NCBs.

CORRELATION BETWEEN NUCLEAR GRADE AND CELL TYPE IN RENAL CELL CARCINOMA

S. Kozlović, M. Turčić, M. Fegeš-Bedić, A. Kopjar, M. Sladojević, H. Čupić, B. Krušlin
Department of Pathology, General Hospital, Varaždin;
Department of Pathology, County Hospital, Čakovec;
Ljudevit Jurak University Department of Pathology,
Sestre milosrdnice University Hospital, Zagreb, Croatia

There are several different clinical and pathologic prognostic parameters in renal cell carcinoma (RCC) including nuclear grade and cell type. However, many issues regarding these factors are still unresolved. The aim of this study was to determine nuclear grade and cell type of RCC, and to analyze their relationship.

Surgical pathology computer-based registry at Department of Pathology, Sestre milosrdnice University Hospital, was canvassed for the period from January 1, 1998 to December 31, 2001, to find all patients with RCC. Pa-

tients with other primary tumors of the renal parenchyma and pelvis were not included in the study. Nuclear grade was determined according to Fuhrman *et al.* and WHO classification, and cell types as proposed by Thoenes *et al.* Nuclear grade was determined in the worst area of the tumor. The predominant cell type was denoted as the cell type.

In the examined period, there were 193 RCCs in 130 (67.3%) male and 63 (32.6%) female patients, age range 23-82 years. The tumors showed nuclear grade 2 in 95 (49.2%), grade 3 in 58 (30.1%), grade 4 in 21 (10.9%) and grade 1 in 17 (8.8%) cases. There were two (1.0%) cases of chromophobe RCC that were not graded. Clear cells represented dominant cell type in 154 (79.8%), eosinophilic cells in 31 (16.1%), spindle cells in 5 (2.6%), chromophobe in two (1.0%) and basophilic in one tumor. In the groups of nuclear grade 1 and 2 tumors, clear cells represented dominant cell type in 102 (91.1%) cases, and in groups 3 and 4 less than 57.0%.

The great majority of RCCs belong to nuclear grade 2 and 3 groups. In our study, the tumors composed of eosinophilic cell type usually showed higher nuclear grade than those of the clear cell type. Basophilic and chromophobe cell types were very rarely observed. Our findings suggest that eosinophilic and spindle cell types are associated with higher nuclear grade suggesting a more aggressive behavior of these types of RCC.

EXPRESSION OF PROLIFERATING CELL NUCLEAR ANTIGEN AND PROTEIN PRODUCTS OF RETINOBLASTOMA AND ADENOMATOUS POLYPOSIS COLI GENES IN HUMAN FETAL TESTIS

S. Marić, F. Bulić-Jakuš¹, D. Ježek², G. Jurić-Lekić², M. Kos³, M. Vlahović¹

Dept. of Biology, Medical School, Osijek;
Dept. of Biology, Medical School, Zagreb, Dept. of Histology and Embryology, Medical School, Zagreb;
Dept. of Pathology, Hospital for Obstetrics and Gynecology, Medical School, Zagreb, Croatia

Proliferating cell nuclear antigen (PCNA) is a cofactor necessary for the activity of DNA polymerase delta expressed in proliferating cells. Retinoblastoma (RB) and adenomatous polyposis coli (APC) genes are tumor suppressor genes whose protein products seem to have important roles during development of different tissues and or-

gans. The purpose of this study was to investigate the expression of PCNA, RB and APC proteins in growing human fetal testis at the single cell level. Human testicular tissue samples were archive biopsies from aborted fetuses (18-27 weeks of gestation) obtained from the University Department of Obstetrics and Gynecology, Zagreb, with permission of the Ethics Committee of the same hospital. Tissue was routinely fixed in Bouin's fixative and embedded in paraffin. Serial sections (5 mm) were put on silanized slides (DAKO, S 3003) and air-dried for 24 hours at room temperature. Samples were routinely deparaffinized and hydrated and heated in a microwave oven for 9 minutes at 620 W and 11 minutes at 310 W; then, 3% H₂O₂ and a protein block were applied each for 5 minutes. Monoclonal Mouse Anti-PCNA, Clone PC 10, (M 0879, DAKO), was diluted to 1:50; Monoclonal Mouse Anti-Human Retinoblastoma Gene Product, Clone Rb1 (M 7131, DAKO), was diluted to 1:10 and Monoclonal Mouse IgG, APC (OP80-100UG, Calbiochem) was diluted to 1:25. Negative control was a standard negative reagent (V 1617, DAKO). Samples were treated with primary antibodies for 5 minutes and washed. DAKO Catalysed Signal Amplification (CSA) System Peroxidase was used for visualization of primary antibodies according to the manufacturer's instructions. Hematoxylin was used for counterstaining. PCNA, RB and APC proteins were found in samples of testicular tissue (18-27 weeks of gestation). PCNA was frequently expressed in tubules (nuclei of Sertoli cells and prospermatogonia), and also in the surrounding peritubular and interstitial cells. RB protein was found in testicular tubules in prospermatogonia and Sertoli cells but was almost absent from the interstitium. APC protein was detected rarely in the cytoplasm of prospermatogonia and interstitial (Leydig) cells. We recorded cell-specific expression of the endogenous proliferation marker (PCNA) and tumor suppressor genes in growing fetal testis, which is important for elucidation of their role in the normal development of human testis.

INCIDENCE OF PRIMARY MALIGNANT TUMORS OF THE CENTRAL NERVOUS SYSTEM IN THE 1991-2001 PERIOD

J. Talan-Hranilović¹, I. Novosel², M. Belicza¹, L. Negovetić³

¹Ljudevit Jurak University Department of Pathology, Sestre milosrdnice University Hospital, Zagreb;

²Department of Pathology, Dr Ivo Pedišić County Hospital, Sisak;

³Department of Neurosurgery, Sestre milosrdnice University Hospital, Zagreb, Croatia

Among primary malignant intracranial tumors, malignant gliomas have the highest incidence in all ethnic groups, although there are differences in their prevalence.

The aim of the study was to analyze overall and histology-specific trends in the prevalence of primary malignant central nervous system (CNS) tumors in neurosurgical biopsy material at the Ljudevit Jurak University Department of Pathology and Department of Neurosurgery, Sestre milosrdnice University Hospital during the 1991-2001 period. We analyzed tumor incidence according to histologic type, age and sex. The aim was to show whether there was an increase in the number of malignant tumors of CNS, and in their incidence in younger age groups and whether the rate of malignant tumors of CNS showed a linear rise according to age and sex. The malignant tumors of our interest were mostly glioblastomas and anaplastic astrocytomas as they are most common of the malignant tumors of CNS.

We analyzed the number of malignant tumors for each year of the study period according to histologic diagnosis, age and sex. Median was determined for each age group, as shown in the table and figure.

Study results showed that during the 1991-2001 period there were 503 malignant tumors in neurosurgical bi-

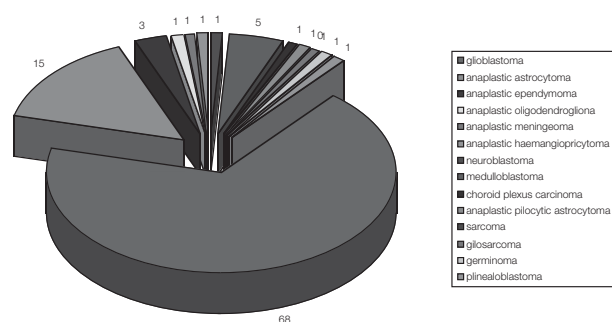


Fig. 1. Frequency of primary malignant CNS tumors in the 1991-2001 period

opsy material. Malignant tumors with the highest incidence were glioblastomas with a frequency of 349 and anaplastic astrocytomas (astrocytoma grade III) with a frequency of 81. The incidence rate according to sex in these two histologic types was 184 in male and 165 in female patients with glioblastoma, while anaplastic astrocytoma was diagnosed in 56 male and 25 female patients. Other histologic types considered had a lower incidence as expected: anaplastic ependymoma 13, anaplastic oligodendroglioma 3, anaplastic meningioma 3, anaplastic hemangiopericytoma 7, neuroblastoma 5, medulloblastoma 23, choroid plexus carcinoma 3, anaplastic pilocytic astrocytoma 4, sarcoma 2, gliosarcoma 5, germinoma 6 and pinealoblastoma 4 (Fig. 1).

The median age for glioblastomas, both female and male patients, was 55.3 years, and for anaplastic astrocytoma 33.6 years. The youngest patient with glioblastoma as the most frequent malignant tumor of CNS, was a male aged 13, and the oldest was a female aged 83.

Summarized data imply an increase in the number of malignant glial tumors, especially during the last few years of study period, with a slight but persistent male predominance.

The peak incidence of malignant glial tumors was in 2000 (Fig. 2). The most important result of this survey was a slow linear decrease of age at onset for malignant glial tumors, especially in male population. Among patients aged 20-40, glioblastoma was diagnosed in 8.3% of cases, with an equal male to female ratio (14:13). Age median

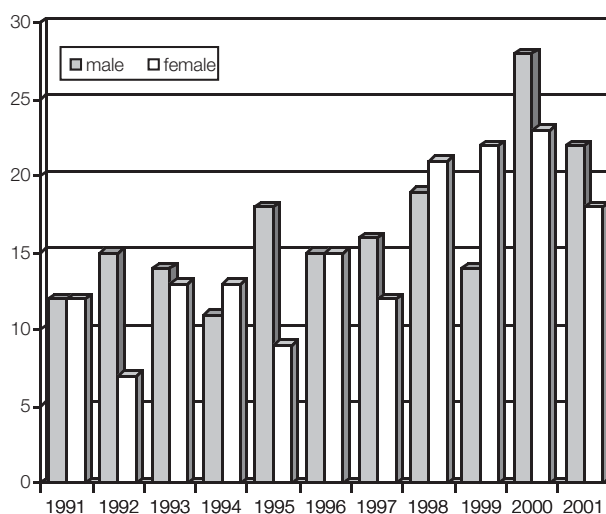


Fig. 2. Frequency of glioblastoma according to sex in the 1991-2001 period

of anaplastic astrocytoma showed a twenty-year earlier onset as compared to glioblastoma (Table 1).

Table 1. Frequency and age median for glioblastomas and astrocytomas anaplasticum.

	Age median		Frequency		Total
	male	female	male	female	
glioblastoma	54.5	56,1	184	165	349
anaplastic astrocytoma	34.5	32.7	56	25	81

The male to female ratio was almost equal except for the years 1992 and 1995, when the rate in male was by 50% higher (the beginning and the end of the war). The total number of glioblastomas showed a significant increase in the post-war period, with a peak incidence recorded 5 years after the war. This could have been the consequence of stress caused by the war.

CEREBELLAR GANGLIOGLIOMA WITH TRANSFORMATION TO GLIOBLASTOMA IN AN ADULT

T. Sajko, J. Talan-Hranilović¹, H. Jednačak, L. Negovetić

Department of Neurosurgery ¹Ljudevit Jurak University Department of Pathology, Sestre milosrdnice University Hospital, Zagreb, Croatia

Ganglioglioma of the cerebellum is a rare tumor of this localization that is often difficult to diagnose preoperatively. To our knowledge, there are less than 20 reported cases of this tumor in the literature. All gangliogliomas are potentially malignant tumors due to their glial component. We present a case of a 55-year-old woman, without previous medical history. Upon admission to our Department, in May 2000, neurologic examination revealed cerebellar symptomatology and symptoms of elevated intracranial pressure. Preoperative CT scans showed a large lesion, 54x43 mm, in the left cerebellar hemisphere, compressing the fourth ventricle with subsequent obstructive hydrocephalus. She underwent surgery one day after admission and subtotal reduction of the tumor was done. Pathohistologic analysis revealed a cerebellar ganglioglioma with marked pleomorphic ganglion cells, astroglial cells and abundant Rosenthal fibers. Immunohistochemically, the ganglion cells stained positive for NSE and

glial cells for GFAP. Postoperative MR scan revealed a residual tumorous lesion and second-act surgery was performed after a one-month period. Pathohistologic examination showed the presence of polymorphic glial cells with multiple mitoses and necroses pointing to cerebellar glioblastoma. Postoperative recovery was complicated with hypertensive hydrocephalus and ventriculoperitoneostomy was performed. The patient died two months after hospital admission. None of the neuroradiologic studies could establish the exact diagnosis. It was only reached by pathohistologic analysis. This is a rare case of cerebellar ganglioglioma with transformation to glioblastoma.

CEREBELLAR MEDULLOBLASTOMA INVOLVING PINEAL REGION IN A 62-YEAR-OLD MALE. CASE REPORT

L. Negovetić, T. Sajko, J. Talan-Hranilović¹, V. Beroš
Department of Neurosurgery, ¹Ljudevit Jurak University Department of Pathology, Sestre milosrdnice University Hospital, Zagreb, Croatia

Medulloblastoma is one of the most common primary tumors of the central nervous system in children and uncommon in adult age. A case of a 62-year-old man with medulloblastoma in the superior cerebellar and pineal region is described. In July 2000, a 62-year-old man was admitted to our Department with symptoms of elevated intracranial pressure. Non-contrast CT scans revealed obstructive hydrocephalus and ventriculoperitoneostomy was done. Postoperatively performed MRI showed a tumorous lesion in the superior cerebellar region expanding toward and consuming the pineal region. A metastatic tumor or pinealoblastoma was suspected. The patient underwent surgery and pathohistologic analysis revealed a desmoplastic medulloblastoma. Medulloblastoma is an uncommon tumor of the posterior fossa mainly found in children. Medulloblastomas may be difficult to recognize in the elderly because of their rarity and their histologic similarity to common metastatic tumors. Medulloblastomas arising earlier in life occur close to the midline, whereas those arising later in life are located more laterally within a cerebellar hemisphere. This case report presents an exceptional occurrence of medulloblastoma involving the superior cerebellar and pineal region, in the late middle aged adult. Thus, it does not correlate with the common, accepted hypothesis concerning these tumors.

EFFECT OF MORPHOLOGIC CELL TYPES ON THE EXPRESSION OF BCL-2, KI-67 AND P-53 IN UVEAL MELANOMAS

A. Krvavica¹, J. Talan-Hranilović², M. Belicza²

¹Department of Pathology and Forensic Medicine, General Hospital Zadar;

²Ljudevit Jurak University Department of Pathology, Sestre milosrdnice University Hospital, Zagreb, Croatia

SUMMARY – Uveal melanomas are known to be less aggressive malignant tumors compared with melanoma of other localizations but the same morphological characteristics. We hypothesized that immunohistochemical determination of expression of the known proliferation markers bcl-2 and ki-67, and p-53 as a suppressor gene marker, could better explain the biological behavior of uveal melanoma *vs.* melanoma of other localizations. Thirty cases of primary uveal melanoma of two levels of invasion were tested retrospectively for the presence of bcl-2, Ki-67 and p-53 proteins with the indirect peroxidase-antiperoxidase immunoenzyme method and three step ABC/AP method. The intensity of reaction was assessed by semiquantitative method.

Key words: *bcl-2 oncoprotein, Ki-67 oncogene, p-53 suppressor gene, uveal melanoma*

Introduction

Uveal melanomas consist of two distinct cell types, spindle and epitheloid, having different clinical implications. These melanomas are known to be less aggressive malignant tumors compared with the cutaneous type of the same cell characteristics¹. Although many factors are important, cell type is of major prognostic significance. The lesions composed completely or predominantly of spindle cells are of low aggressiveness, do not tend to metastasize, and permit about a 75% survival at 15 years. In contrast, epitheloid melanomas have only 35% survival at 15 years despite early enucleation. The bcl-2 oncoprotein plays a central role in programmed cell death induced by p-53, acting as an inhibitor of the apoptotic process, and it has given name to a family of proteins engaged in promotion /inhibition of apoptosis. It is localized on nuclear envelope, inner mitochondrial membrane and rough endoplasmic reticulum. Bcl-2 in malignant melanoma may play a role in tumor development by sparing

the cells from apoptotic death and thereby exposing them to secondary events². Ki-67 antibody reacts with nuclear antigen present in proliferating cells of various human malignant tumors³. Ki-67 expression begins in the G1 phase of cell cycle, increases through S, G2 and M, and is absent in G0 phase. It is a well established technique for measuring cell proliferation in routinely processed, formalin fixed, paraffin embedded tissue. Roles for p-53 have been identified in aspects of DNA damage recognition, DNA repair, cell cycle regulation, and most particularly in triggering apoptosis after genetic injury. p-53 is the most commonly mutated gene in human malignancy, prevalent in cancers of a wide variety of histogenesis and primary sites⁴.

Aims of the study

- to investigate the expression of bcl-2, Ki-67 and p-53 immunocomplexes in uveal melanoma cells;
- to examine whether the intensity of expression correlates with morphological cell type

Material and Methods

Thirty cases of primary uveal melanoma were tested for the presence of bcl-2, Ki-67 and p-53 proteins with the indirect peroxidase-antiperoxidase immunoenzyme method and three step ABC/AP method⁵. All cases were diagnosed at the Sestre milosrdnice University Hospital from Zagreb.

The pure epitheloid cell type was present in 5/30 melanomas, whereas 13 were of spindle cell, and 12 a combination of epitheloid and spindle cell type. The intensity of reaction was assessed by semiquantitative method: negative (-); positive in <50% of cells (+); positive in 50% of cells (++); and positive in >50% of cells (+++). Data were statistically analyzed by Fisher's exact test with $p > 0.05$ as statistically significant, and Stuart-Maxwell test for little samples, with $p < 0.016$.

Results

Table 1. Expression of Ki-67 protein according to cell types

Ki-67	S		M		E		Total	
	n	%	n	%	n	%	N	%
-	3	10.0			1	3.3	4	13.3
+	3	10.0					3	10.0
++	6	20.0	6	20.0	3	10.0	15	50.0
+++	1	3.3	6	20.0	1	3.3	8	26.7
Total	13	43.3	12	40.0	5	16.7	30	100.0

Table 2. Expression of p-53 protein according to cell types

p-53	S		M		E		Total	
	n	%	n	%	n	%	N	%
-	4	13.3			1	3.3	5	16.7
+	2	6.7	1	3.3	1	3.3	4	13.3
++	6	20.0	5	16.7	2	6.7	13	43.3
+++	1	3.3	6	20.0	1	3.3	8	26.7
Total	13	43.3	12	40.0	5	16.7	30	100.0

Comparison between Ki-67 and p-53 protein expression and morphological cell types showed no statistically significant differences (Fisher's exact test $p > 0.05$).

Table 3. Expression of bcl-2 protein according to morphologic cell types

bcl-2	S		M		E		Total	
	n	%	n	%	n	%	N	%
-	7	23.3	4	13.3	2	6.7	13	43.3
+	3	10.0	1	3.3	2	6.7	6	20.0
++	2	6.7	2	6.7			4	13.3
+++	1	3.3	5	16.7	1	3.3	7	23.3
Total	13	43.3	12	40.0	1	16.7	30	100.0

S=spindle cells; M=mixed cell population; E=epitheloid cells

Comparison between bcl-2 expression and morphological cell types showed no statistically significant differences (Fisher's exact test $p > 0.05$).

Conclusion

The intensity of expression of the bcl-2, Ki-67 and p-53 proteins in uveal melanoma did not vary with the morphological cell type.

References

1. MC LEAN IW, *et al.* Modifications of Callender's classification of uveal melanoma at the Armed Forces Institute of Pathology. *Am J Ophthalmol* 1983;96:502.
2. JAY V, QUIONG Y, HUNTER WS, ZIELENSKA M. Expression of bcl-2 in uveal malignant melanoma. *Arch Pathol Lab Med* 1996;12:497-8.
3. BROWN DC, *et al.* Monoclonal antibody Ki-67, it's use in histopathology. *Histopathology* 1990;17:489.
4. TOBAL K, WARREN CS, COOPER A, MC CARTNEY A, HUNGERFORD J, LIGHTMAN S. Increased expression and mutation of p-53 in choroidal melanoma. *Br J Cancer* 1992;66:900-4.
5. STERNBERGER LA, *et al.* The unlabelled antibody enzyme method of immunohistochemistry. Preparation and properties of soluble antigen-antibody complex horse radish peroxidase-antihorse radish peroxidase and it's use in identification of spirochettes. *J Histochem Cytochem* 1970;18:315.
6. ARNITAGE P. Statistical methods in medical research. Oxford: Blackwell Sci Publications, 1971.

Sažetak

UTJECAJ MORFOLOŠKOG TIPA STANICA NA EKSPRESIJU BCL-2, KI-67 I P-53 U UVEALNIM MELANOMIMA

Usprkos morfološkoj građi sličnoj drugim melanomima, poznato je da uvealni melanomi imaju daleko bolju prognozu od melanoma drugih lokalizacija. Upravo stoga pretpostavili smo da bi određivanje ekspresije bcl-2, Ki-67 kao poznatih čimbenika proliferacije, te p-53 proteina u stanicama uvealnih melanoma moglo protumačiti ovakvo biološko ponašanje uvealnih melanoma. U tu svrhu ispitano je retrogradno 30 primarnih uvealnih melanoma stadija pT2 i pT3 na prisutnost bcl-2, Ki-67 i p-53 proteina indirektnom metodom peroksidaze-anti-peroksidaze i trofaznom metodom ABC/AP. Stupanj reaktivnosti određen je semikvantitativnom metodom.

Ključne riječi: *bcl-2 onkoprotein, Ki-67 onkogen, p-53 supresorski gen, uvealni melanom*

UNDIFFERENTIATED NASOPHARYNGEAL CARCINOMA (LYMPHOEPITHELIOMA) - A CASE REPORT

V. Blažičević, V. Čačinović, Ž. Kotromanović
Department of Pathology and Forensic Medicine, Osijek University Hospital, Osijek, Croatia

Undifferentiated nasopharyngeal carcinomas (lymphoepithelioma) are quite common in some areas of the Orient, but are rare in the USA and Europe. They often occur in children and show a distinctly bimodal age distribution, with peaks in the second and sixth decades. Survival corre-

lates with the stage of disease. About 50%-80% of patients are initially seen with cervical lymph node metastases from an occult primary tumor. We report on four patients with undifferentiated nasopharyngeal carcinoma (lymphoepithelioma). Clinicopathologic features and treatment of this tumor are discussed.

CHANGING TRENDS IN LYMPHOMA INCIDENCE IN BIOPTIC MATERIAL IN A 13-YEAR PERIOD (1989-2001)

L. Perković¹, D. Tomas², S. Čurić-Jurić³, M. Šokčević³, I. Maričević³, H. Čupić²

¹Sveti Duh General Hospital

²Ljudevit Jurak University Department of Pathology and

³University Department of Cytology, Sestre milosrdnice University Hospital, Zagreb, Croatia

The aim of our study was to determine the trends in lymphoma incidence in bioptic material of all malignant lymphomas diagnosed during a 13-year period (1989-2001). Patient data were obtained from the files of the Department of Cytology and computer based surgical pathology registry at the Ljudevit Jurak University Department of Pathology. A total of 187 patients were recorded in the study period. The following data were reviewed: cytologic and histologic type and localization of lymphoma, and patient age and sex. All samples were routinely stained with HE, histochemical stains (PAS, Gomori, Giemsa, May-Grünwald-Giemsa), and analyzed by immunohistochemistry. During the 13-year period, there were 187 cases of lymphoma: 167 of non-Hodgkin lymphoma (NHL) and 20 of Hodgkin disease (HD). There were 35 cases (30 NHL and 5 HD) in which both cytology and histology were performed. We observed an increasing frequency of lymphomas during the study period. In 1989, there were 10 cases but the number increased to 25 in 2001. Sex distribution showed no significant differences during the 1989-2001 period. Age distribution showed the mean age to increase in males from 48.0 to 54.4, and in females from 41.0 to 69.5 years. In this preliminary study, we noticed an increasing frequency of lymphomas during the 13-year period, with sex distribution showing no significant differences, and with a mean age increase. Comparison of cytologic and pathohistologic diagnoses showed correlation in the majority of cases.

Table and Fig.1. Prevalence of lymphomas, 1989-2001

Year	Lymphomas
1989	10
1990	9
1991	5
1992	12
1993	11
1994	11
1995	15
1996	15
1997	14
1998	15
1999	18
2000	25
2001	27
all	187

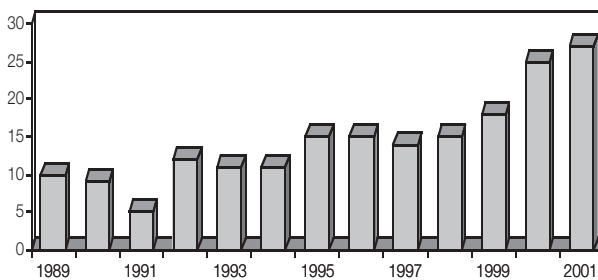
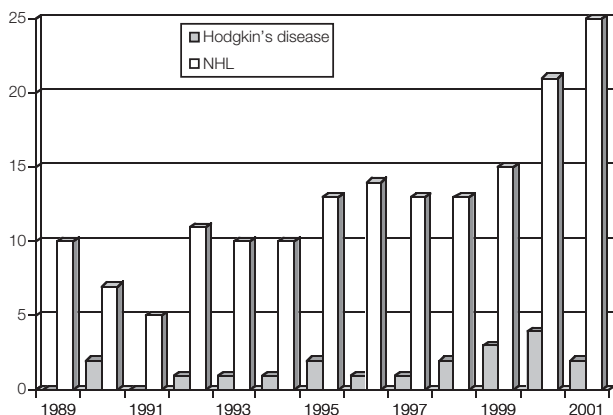


Table and Fig. 2. Comparison of NHL and Hodgkin's disease, 1989-2001

Year	Hodgkin's disease	NHL
1989	0	10
1990	2	7
1991	0	5
1992	1	11
1993	1	10
1994	1	10
1995	2	13
1996	1	14
1997	1	13
1998	2	13
1999	3	15
2000	4	21
2001	2	25
all	20	167



References

1. STRICKLAND AH, ARTHUR GE, MATTHEWS JP, BRESFORD JA, LOWENTHAL RM. Increased survival in patients diagnosed with Hodgkin's disease in Tasmania, 1972-1992. *Aust N Z J Med* 1998;28:609-14.
2. LIU S, SEMENCIW R, WATERS C, WEN SW, MAO Y. Time trends and sex patterns in Hodgkin's disease incidence in Canada, 1970-1995. *Can J Public Health* 2000, 91:188-92.
3. McNALLY RJ, ROMAN E, CARTWRIGHT RA. Leukemias and lymphomas: time trends in the UK, 1984-93. *Cancer Causes Control* 1999, 10:35-42.
4. CANI MI, POLLAN M. Non-Hodgkin's lymphomas and occupation in Sweden. *Int Arch Occup Environ Health* 2001;74:443-9.

INCIDENTAL MALIGNANT TUMORS AT AUTOPSY DURING A 48-YEAR PERIOD (1953-2000)

M. Elez, V. Gladić, H. Jurlina, T. Leniček, M. Glasnović, A. Husnjak, H. Čupić
Ljudevit Jurak University Department of Pathology, Sestre milosrdnice University Hospital, Zagreb, Croatia

The aim of our study was to determine the frequency of clinically non-diagnosed malignant tumors. We analyzed retrospectively autopsy reports from the Ljudevit Jurak University Department of Pathology, University Hospital Sestre milosrdnice, for a 48-year period (1953-2000). During this period, there were a total of 31374 autopsies performed, of which in 1059 incidental malignant tumors (IMT) were found, which makes 3.4% of the total number. The leading primary sites of origin of IMT, found on autopsy were the lungs and stomach, followed by the colon, liver, kidney, pancreas and prostate in descending order. Malignant tumors in other organs were found in smaller numbers. When

divided into age groups, the peak incidence occurred in the seventh and eighth decade of life, when mortality and morbidity are often associated with a large number of concurrent pathological processes, mainly with non-malignant diseases that often mask the symptoms developed by IMT. We completed our data with pTNM classification for the 1993-2000 period, which showed a surprisingly high number of advanced stages in which malignant tumors were accidentally detected on autopsies (T2N2M1 was the most frequent stage of pulmonary cancer, T2N1M1 in stomach and prostate cancer, and T4N3M1 in colon cancer), which is in agreement with previously published studies. The noticeable decline in the average rate of autopsies throughout the investigated period did not affect the incidence of incidental malignant tumors (the lowest incidence was 2.8% and highest 3.9%). The study showed a significant proportion of advanced primary tumors that were detected on autopsy and which had not developed into a clinical disease. It is a complex problem, which could be elucidated by additional investigation and closer collaboration with clinicians.

EFFECT OF GREEN TEA ON FREE RADICAL ACTIVITIES IN RAT TERATOMA

R. Klepac
Department of Biology, Zagreb University School of Medicine, Zagreb, Croatia

Free radicals are different aggressive oxygen species which have one unsaturated oxygen atom. They damage cell macromolecules: DNA, proteins and lipids. Free radicals are associated with different chronic diseases such as cataract and cancer. Many studies demonstrated that polyphenosis from green tea depressed tumor growth and its development. In this study, we transplanted seven-day rat embryos under the kidney capsul. These embryos developed after two weeks into teratoid tumors. One half of treated rats were given 2% solution of green tea *ad libitum*. All rats were sacrificed after three months. Green tea did not influence tumor growth. In tumor mitochondria, green tea depressed the production of superoxide anion (80%). Tea solution did not change the level of lipid peroxidation, which is a characteristic parameter of oxidative stress in tumor tissues. In tumor mitochondria, green tea increased the antioxidative capacity level of GSH, enzymatic activity of SOD and cytochrome c oxidase. These results show that green tea increased antioxidative defense in rat teratoma, which probably retarded tumor development.

STUDY OF NUCLEATED RED BLOOD CELLS IN EVALUATION OF FETAL ASPHYXIA

M. Elayoty, S. Aref, H. Abdelhady
Mansoura University Children Hospital, Mansoura, Egypt

The aim of the study was to determine whether a relationship exists between the presence of nucleated red blood cells (NRBC), timing of perinatal asphyxia, and severity of hypoxic neurologic impairment. Nucleated red blood cells from 27 single full term asphyxiated neonates were compared with cord blood NRBC of 30 full term non asphyxiated newborns. Our patients were classified into 3 groups according to the degree of neurologic impairment suggestive of hypoxic ischemic encephalopathy (mild - group I, moderate - group II and severe - group III). The first and highest NRBC value and the time to NRBC disappearance were assessed. Asphyxiated neonates exhibited a significantly higher number of NRBC *per* 100 white blood cells (median=120; range: 5-835) than did the control group (median=1; range: 0-8) ($p=0.001$). Newborns with severe neurologic impairment (group III) had significantly higher cord blood NRBC than group II and I ($p=0.001$ each). The time of NRBC clearance from peripheral blood was significantly longer in group III than in group I and II patients (median value of NRBC on day 7 day was 0.0 (range 0-10) in group I; 11 (range: 0-80) in group II; and 122 (range 0-500) in group III). Meconium stained amniotic fluid was significantly more present in group III than in groups II and I ($p=0.001$). Correlation studies revealed highly significant positive correlations between cord blood NRBC, cord blood pH, and degree of neurologic impairment ($p=0.001$ both). In this limited study, counting of NRBC appeared to identify the presence of fetal asphyxia and correlated well with the severity of asphyxia. The peak value of NRBC and the time of clearance along with the presence of meconium stained amniotic fluid can help in determining the time of fetal injury. In general, the closer the birth to the asphyxia event, the lower the number of NRBC.

IMMUNOGLOBULIN DEPOSITS IN SKIN BIOPSIES OF PATIENTS WITH SYSTEMIC CONNECTIVE TISSUE DISEASES

B. Bogoeva¹, A. Pusevski², S. Kostadinova¹, G. Petrushevska¹
Institute of Pathology, Faculty of Medicine; Department of Rheumatology, Skopje, Republic of Macedonia

The aim of the study was to find deposits of immunoglobulins in the analyzed skin biopsies of patients with connective tissue diseases (CTD). Skin biopsies from 25 patients with CTD (15 with scleroderma, 5 dermatomyositis, 3 rheumatoid arthritis and 2 SLE) were analyzed histologically and histochemically. All biopsies were stained by HE, PAS and staining for elastic tissue (Weighert resorcin fuchsin and Van Gieson). Histologic changes were present in all skin biopsies. They were characterized by swelling and degeneration of collagen fibers that became eosinophilic. Capillaries and small vessels showed thickening of the basal lamina, endothelial cell damage and perivascular edema with lymphocytic infiltrates. Biopsies were positive for PAS and elastic tissue staining. Skin biopsies were tested with direct immunofluorescence technique for anti-human IgG, IgM and IgA. Granular or linear immunofluorescent deposits were found at the dermoepidermal junction (DEJ) in 10 cases with scleroderma, 1 dermatomyositis and 2 SLE. Deposits of immunoglobulins were also found in the vessel walls of skin biopsies in 5 cases with scleroderma, 2 dermatomyositis and 2 SLE. Antinuclear antibodies (ANA) were analyzed by the indirect immunofluorescence technique using serum from the same patients, 20 of which were positive. The fluorescence technique provides visual localization of the antigen or antibodies fixed to tissues, and is a useful immunohistochemical approach to the study of these diseases.

HISTOLOGIC VARIABILITY IN THE ILIAC CREST BIOPSY OF POSTMENOPAUSAL AND OSTEOPOROTIC WOMEN

P. Lozo¹, D. Krpan², A. Kravica³, V. Kušec⁴
¹Lozo Health center, Zadar;
²Sveti Duh General Hospital, Zagreb;
³Zadar General Hospital, Zadar;
⁴Clinical Institute of Laboratory Diagnosis, Zagreb University Hospital Centre, Zagreb, Croatia

SUMMARY – Many investigations have been carried out on osteoporosis and showed this disorder in a new light. The reduction in bone structure and dynamics points to the etiology that may be of therapeutic significance. Today we still do not know everything about the histomorphometric characteristics of each metabolic disturbance and bone disease. Bone biopsy and histomorphometry are not available for most patients and that is the reason why a broad classification of these reductions in osteoporosis and osteomalacia are widely

accepted in clinical practice. New findings from this complex domain are necessary to design a strategy in the evolution of new therapeutic devices and drugs with the intention to decrease the high disability and mortality rate in the vulnerable population of postmenopausal women.

Key words: osteoporosis, osteomalacia, metabolic bone diseases, bone histomorphometry, postmenopause

Postmenopausal osteoporosis is the commonest type of osteoporosis in clinical practice¹. At the cellular level, osteoporosis is the consequence of imbalance or uncoupling of osteoblastic bone deposition and osteoclastic bone resorption^{2,3}. Histomorphometric studies have demonstrated considerable heterogeneity in the activity of bone cells and bone turnover in osteoporosis. It is well established that the diagnosis of osteoporosis and fracture risk assessment are based on bone density measurement^{4,6}. Association of bone histology characteristics and their impact on bone density remains to be elucidated and was addressed in this study.

Forty-three postmenopausal women underwent transiliac bone biopsy in the course of diagnostic procedures and the following static histomorphometric parameters were assessed by optical grid: bone volume, osteoblast and osteoid surface, osteoid thickness and osteoclast surface. Bone mineral density (BMD) was measured by DEXA at the lumbar spine and hip. The published reference data for histomorphometric indices were used for comparison of own results. Data were analyzed according to normal, osteopenic and osteoporotic BMD results, and showed no difference for any of the histomorphometric parameters.

A subgroup of patients with increased osteoclast and osteoblast/osteoid surface (14/43) were identified, and among them those with reduced bone volume (4/43). BMD and T-scores for lumbar spine and hip in these two subgroups were lower but not statistically significantly from those in patients with normal histomorphometric parameters for bone volume, osteoclast, osteoblast and osteoid surfaces (8/43).

These results support the existence of great histologic variability of bone cell activity in the postmenopause and osteoporosis. The lack of association of single or several histomorphometric parameters indicating rate of turnover with BMD was probably the consequence of a high variance and limited patient sample. In conclusion, evidence for increased bone cell activity with or without reduced bone volume might be encountered in postmenopausal women with normal or reduced bone mineral density.

References

- MELTON LJ 3rd. How many women have osteoporosis now? *J Bone Miner Res* 1995;10:175-7.
- KHOSLA S, KLEEREKOPER M. Metabolic bone diseases - introduction. In: FAVUS MJ, ed. *Primer on the metabolic bone diseases and disorders of mineral metabolism*, 3rd.
- MALLUCHE, FEUGERE. *Atlas of mineralised bone histology*. Karger, 1986.
- KRPAN D. Evaluacija fotonske apsorpcijometrije u praćenju renalne osteodistrofije u bolesnika liječenih kroničnom intermitentnom hemodijalizom. /MS thesis /. Zagreb: School of Medicine, University of Zagreb, 1985.
- KRPAN D. Histomorfometrijske značajke kosti bolesnika na kroničnoj dijalizi. Doctoral dissertation, Zagreb: Zagreb School of Medicine, 1991.
- REHMAN MTA, HOYLAND JA, DENTON J, FREEMONT AJ. Histomorphometric classification of postmenopausal osteoporosis: implications for management of osteoporosis. *J Clin Pathol* 1995;48:229-35.

Sažetak

HISTOLOŠKA RAZLIČITOST U KOŠTANOJ BIOPSIJI POSTMENOPAUZALNIH I OSTEOPOROTIČNIH ŽENA

Brojna istraživanja provedena posljednjih godina pokazala su osteoporozu u novom svjetlu. Promjene u koštanoj strukturi i dinamici upućuju na etiologiju poremećaja, što je od presudnog značenja za liječenje bolesti. S obzirom na činjenicu da još uvijek malo znamo o histomorfometrijskim značajkama pojedinih metaboličnih bolesti te da je biopsija kosti i histomorfometrija još uvijek teže dostupna većem broju bolesnika, danas se u kliničkoj praksi uglavnom rabi klinička klasifikacija po kojoj se one dijele u dvije široke kategorije: osteoporozu i osteomalaciju. Nova saznanja iz ovoga područja su od presudne važnosti za planiranje buduće strategije razvoja novih terapijskih sredstava i lijekova kako bi se smanjio visok postotak invaliditeta i smrtnosti u osjetljivoj populaciji postmenopauzalnih žena.

Ključne riječi: osteoporozu, osteomalacija, metabolične koštane bolesti, histomorfometrija kosti, postmenopauza

COMBINED HOMICIDE – SUICIDE IN OSIJEK COUNTY, EAST CROATIA

M. Marcikić¹, B. Dumenčić¹, E. Matuzalem¹, K. Marjanović¹, M. Ugljarević²

¹Dept. of Forensic Medicine and Pathology, School of Medicine, Josip Juraj Strossmayer University, Osijek

²Dept. of Pathology, General Hospital, Vukovar, Croatia

Homicide and suicide are closely intertwined in combined homicide-suicide. These tragic acts generate much public concern because in some cases, homicide-suicide

involves annihilation of entire family. The phenomenon is difficult to study in part because the perpetrator is dead. The literature review addresses demographic variable and proposes two classifications, one based on psychopathology, and the other on the relationship between the offender and the victim, and suggests a three dimensional analytical approach to the understanding of homicide-suicide: psychopathology and ego deficits of the perpetrator, cumulative and precipitating stressors, and motivation and vector of destructive urges against self and the other victims. To further understand the nature of this tragic phenomenon, the investigators systematically collected data on all combined homicide-suicide events (n=11) that occurred over a 15-year period (1987-2001) in the Osijek County.

Combined homicide-suicide represented approximately 1% of suicide and 5% of homicide in the study period. Consortial (64%) followed by filial (27%) type were the two most common combined homicide-suicide types. Husband, lover and boyfriend were typical offenders in consortial homicide-suicide. A father killed his daughters and then hanged himself. Another father simultaneously destroyed his son and himself by hand grenade. In another case, a suicidal mother killed her daughter and son. Only one case could be delineated as adversarial homicide-suicide. The same method of destruction was implemented on both the victim and the perpetrator in consortial homicide-suicide. The couple's home and apartment were a common (57%) milieu of this devastating act. Depression, alcoholism and possessiveness were the personality traits equally present in consortial perpetrators.

PROSTATIC CANCER MORTALITY IN THE PRE- AND POST-PSA ERA: THE TRIESTE EXPERIENCE

R. Bussani, D. Camilot, F. Bassan, F. Silvestri
Institute of Pathological Anatomy, c/o Ospedale Maggiore, Trieste, Italy

The exponential increase of PSA determinations in the Province of Trieste, the presence of only one Institute of Pathological Anatomy, and the high autoptical rate allow us to make a comparison between the biological evolution of the prostatic neoplasms diagnosed in the period preceding the introduction of PSA and those histologically evidenced precisely after more or less casual PSA evaluation. All cases of prostate carcinoma diagnosed in our Institute

in the years 1989/1990 and during the 1997-1999 period were histologically reviewed. Each patient was studied according to biologic evolution and, if deceased and autopsied, there was reanalysis of the diagnostic report to determine the cause of death. The processed data showed a significant increase in the incidence of prostate carcinoma in recent years, which was particularly evident in younger subjects and almost certain PSA-correlation often showing low grade tumors (≤ 4). Besides death rate in the two periods under study, strongly influenced by different follow-up times, in the subjects who died and were autopsied there was progressive reduction in T3 cases and an overall decrease in deaths due to cancer. Although the observed data are absolutely preliminary and susceptible to profound changes regarding rightful extension of the follow-up periods, we recorded an improvement in the biology of these neoplasms, presumably related to the early diagnosis and consequent possibility of surgical treatment in relatively young subjects with low grade and low stage tumors.

DIFFUSE METASTATIC LEPTOMENINGEAL MELANOMATOSIS AS THE FIRST CLINICAL SIGN OF A CUTANEOUS MELANOMA

R. Bussani, D. Camilot, F. Bassan, F. Silvestri
Department of Pathological Anatomy, University of Trieste, Trieste, Italy

A 64-year-old man was hospitalized for right hemiparesis and systemic hypertension (180/110). In the last two months, the patient suffered from frequent episodes of vomit without other symptoms and was treated with antacids. His clinical history was characterized by diabetes mellitus and ischemic cardiopathy. The general condition of the patient rapidly worsened, and after five days he presented high fever, lethargy and dyspnea due to massive bronchopneumonia. Neither intracranial hypertension nor liquor alterations were found. Electroencephalographic findings were nonspecific. Magnetic resonance imaging was obtained using a 0.5 Tesla scanner. On contrast enhanced T1 weighted images obtained with axial, coronal and sagittal scans, a mild high intensity signal was noted on the surface of the sulci. This feature, although mild, is representative of meningeal enhancement. Two days later, the patient went into coma and died. At autopsy, the brain weighed 1580 grams. Leptomeninges of the brain and of the spinal cord, cerebral cortex, ependyma of lateral ventricles, and basal nuclei were diffusely and intensively

brownish. Small black metastatic lesions were evident in the pleural region and in the liver. Thorough examination of the body revealed a small pigmented lesion (15 mm) on the left shoulder. Histologic examination of the cutaneous lesion showed nodular melanoma. Cerebral and spinal meninges were extensively infiltrated by melanomatous cells which diffusely spread along the perforating vessels into the cerebral cortex. Melanoma is the third most common cause of cerebral metastases in most series. A very infrequent form of metastatic diffusion to the meninges is the so called lep-

tomeningeal carcinomatosis, a pathological entity first described by Eberth in 1870. The neurological symptoms in the patient were probably due to the very extensive neoplastic metastatization of the meninges and cerebral cortex. This is, to our knowledge, the first case of leptomeningeal melanomatosis in which magnetic resonance was done only few days before the patient's death. The radiographic feature observed in our patient may be useful for future diagnosis of this uncommon pathology.