

## INTRACRANIAL HYPERTENSION DUE TO LHERMITTE-DUCLOS DISEASE: CASE REPORT

Vili Beroš<sup>1</sup>, Tomislav Sajko<sup>1</sup>, Jasna Talan-Hranilović<sup>2</sup> and Lucijan Negovetić<sup>1</sup>

<sup>1</sup>Department of Neurosurgery, and <sup>2</sup>Ljudevit Jurak Department of Pathology, Sestre milosrdnice University Hospital, Zagreb, Croatia

**SUMMARY** – A 24-year-old woman presented with symptoms of increased intracranial pressure. Computed tomography scanning showed a hypodense cerebellar mass. Magnetic resonance imaging (MRI) revealed a large lesion within the left cerebellar hemisphere and vermis that reduced the fourth ventricle and compressed the aqueduct with subsequent dilatation of the ventricular system. The case is described because of the rare occurrence of Lhermitte-Duclos disease in a central location. The preoperative diagnosis was verified by histologic findings obtained upon subtotal resection of the lesion. MRI provides an opportunity to improve the surgical approach and to evaluate long-term follow-up, thus reducing the probability for recurrence and complications. Therefore, MRI is considered the imaging method of choice to make the diagnosis of Lhermitte-Duclos disease.

**Key words:** *Cerebellar neoplasms, surgery; Ganglioneuroma, diagnosis; Intracranial pressure; Tomography x-ray, computed; Magnetic resonance imaging; Case report*

### Introduction

Ninety-eight cases of dysplastic gangliocytoma of the cerebellum have been reported in the literature since the disease was first recognized and described by Lhermitte and Duclos<sup>1,2</sup>. The disease is characterized by a cerebellar mass composed of enlarged cerebellar folia containing abnormal ganglion cells. It presents in young and middle-aged adults, commonly with symptoms of increased intracranial pressure.

We present a young woman with hydrocephalus due to the aqueductal stenosis caused by a rare occurrence of dysplastic gangliocytoma arising within the left cerebellar hemisphere and vermis. Literature review revealed a single report describing this rare entity arising at a central location, i.e. within the cerebellar vermis<sup>3</sup>. The disease is of interest for its uniqueness in neuropathology,

which includes substantial metamorphosis of the cerebellar structure with sparing of its general configuration<sup>4</sup>. In this report, attention is drawn to clinical presentation, radiologic findings (computer tomography (CT) scans, magnetic resonance imaging (MRI)), and pathohistologic examination of this rare entity.

### Case Report

A 24-year-old woman, mother to four children, with uneventful medical history, was admitted to the hospital in February 1999 with a 1.5-month history of progressive, predominantly posterior headaches, visual disturbances, nausea and vomiting. On admission, neurologic examination revealed an unsteady tandem gait with a tendency to fall to the left. She exhibited positive Romberg's sign and had difficulty on the left-side finger-to-nose testing. Funduscopy showed no edema. No nystagmus was observed. The remainder of her neurologic examination was normal.

CT scans showed a large hypodense area in the left cerebellar hemisphere and vermis. This unenhancing mass

Correspondence to: *Vili Beroš, M.D.*, Department of Neurosurgery, Sestre milosrdnice University Hospital, Vinogradska c. 29, HR-10000 Zagreb, Croatia

Received May 14, 2000, accepted in revised form August 17, 2000

showed a few calcifications, displaced and reduced fourth ventricle, and compressed sylvian aqueduct determining obstructive hydrocephalus (Fig. 1). MRI performed both with and without contrast medium revealed an irregular lesion of approximately 70x50 mm, consuming the area of the left cerebellar hemisphere and vermis. The lesion was hypodense on T1-weighted images, and of a moderately high signal on T2-weighted images, but unenhanced upon i.v. administration of the contrast medium (Fig. 2). There was also evidence for tonsillar herniation below the level of the fourth ventricle (Fig. 3).

**Operation.** Left paramedian suboccipital craniectomy and C-1 laminectomy were performed. Upon opening of dura mater, a very large, wide, gray-colored cerebellar folia were visualized expanding throughout the left cerebellum and vermis. Subtotal resection of the lesion was performed to decompress the fourth ventricle. Also, a large portion of the left cerebellar hemisphere was removed.

The patient recovered uneventfully with resolution of her neurologic symptoms. She was discharged from the

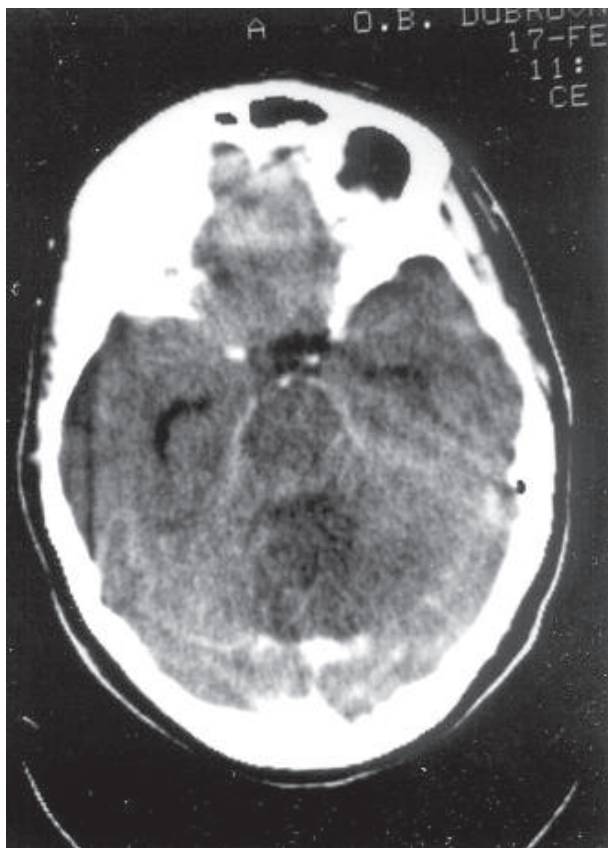


Fig. 1. Computed tomography scan showing hypodensity in the region of vermis and left cerebellar hemisphere.

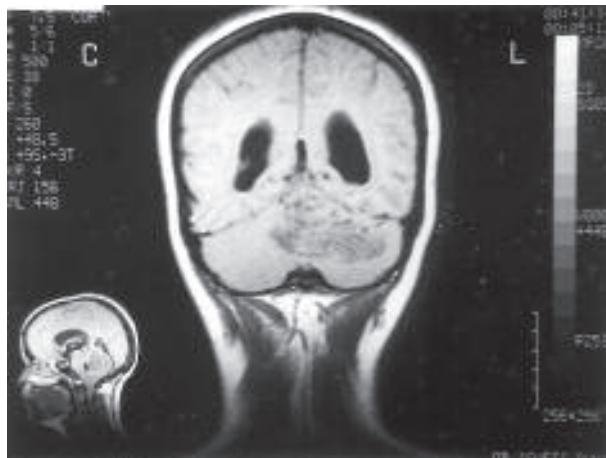


Fig. 2. Coronal T1-weighted image shows multiple linear striations consistent with thickened cerebellar folia.

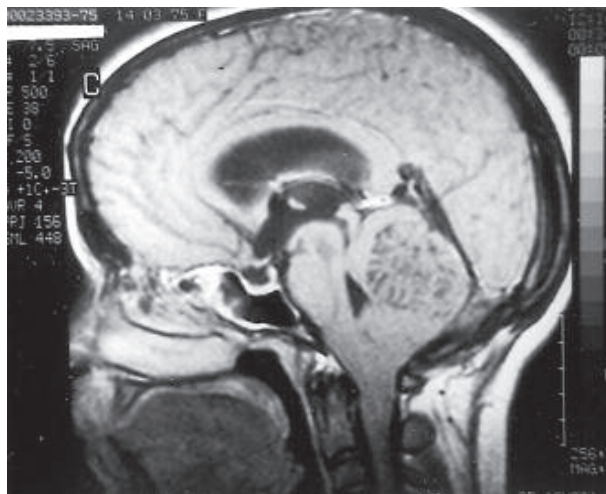

Fig. 3. Sagittal T1-weighted image. Multiple enlarged folia forming a characteristic tiger-striped appearance, are evident. The vermis has expanded into the fourth ventricle and there is evident tonsillar herniation below the level of foramen magnum.

hospital on day 9 after the surgery and continued to do well for ten months thereafter.

**Pathohistologic examination.** On gross examination, the surgical specimen was characterized by enlargement and hypertrophy of the cerebellar cortex and folia. On histologic examination, the internal granular cell layer was completely replaced by very large neurons some of which bore superficial resemblance to Purkinje's cells. These neurons were markedly variable in shape and size. Normal Purkinje's cells were absent throughout the specimen (Figs. 4 and 5). Immunoperoxidase preparation using the monoclonal antibody against 200 kD neurofilament polypeptide confirmed the presence of neuritic differen-

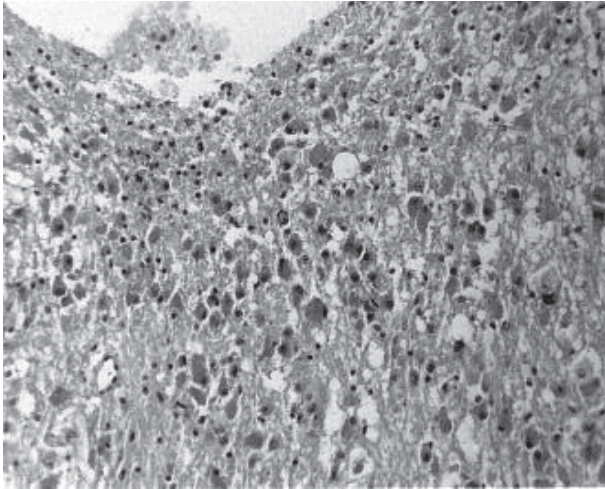


Fig. 4. Dysplastic gangliocytoma of the cerebellum. Enlarged granular neurons. (HE x200)

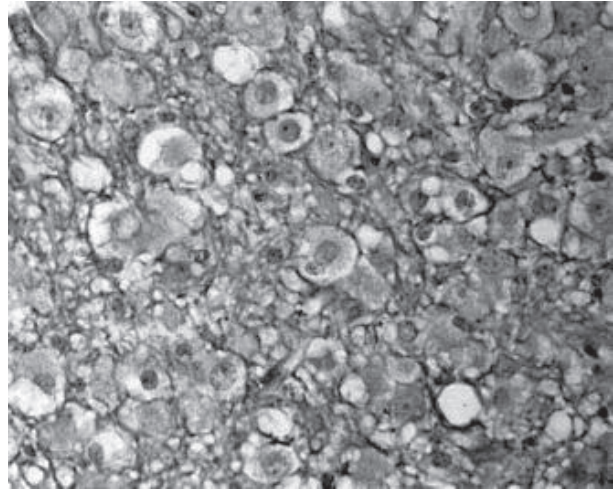


Fig. 6. Dysplastic neurons. (NF x400)

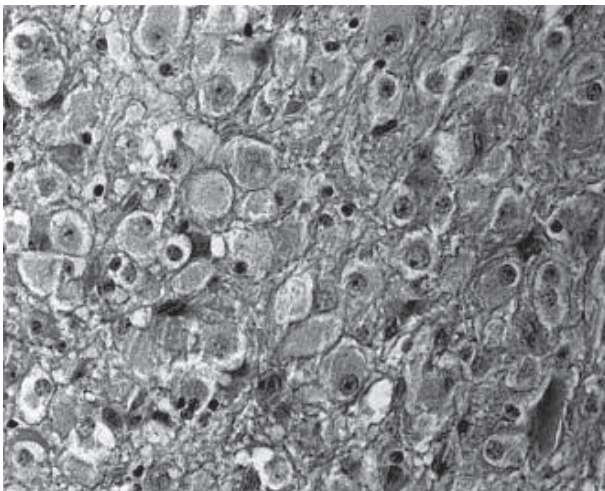


Fig. 5. Dysplastic granular neurons. (HE x400)

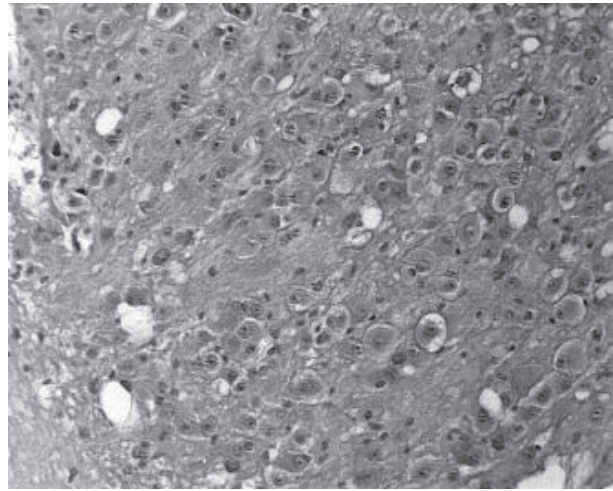


Fig. 7. Enlarged and dysplastic neurons. (NSE x200)

tiation (Fig. 6). Immunoreactivity for neuron specific enolase was detected in the tumor ganglion cells (Fig. 7).

## Discussion

In 1920, Lhermitte and Duclos described an unusual abnormality of the cerebellum, characterized by enlarged cerebellar folia which contained circumscribed regions of abnormal ganglion cells. Although this disorder is now commonly classified as a dysplastic gangliocytoma, plethora of names as benign hypertrophy of the cerebellum, purkinjeoma, hamartoma of the cerebellum, diffuse ganglioneuroma of the cerebellar cortex, neurocystic blastoma, hamartoblastoma, gangliomatosis of the cerebellum,

Lhermitte-Duclos disease, neurocytoma myelinicum, and gangliocytoma myelinicum diffusum reflects the difficulty of its pathogenetic classification<sup>5-7</sup>.

Pathologically, Lhermitte-Duclos disease (LDD) has paradoxical features of both malformation and benign neoplasm. The lesion is thought to arise from an abnormality in granule cell migration and differentiation<sup>8</sup>. Numerous associated abnormalities have been described in patients with LDD<sup>1,9,10</sup>. These include megaloccephaly (in approximately 50% of reported cases), microgyria, spongioblastomas, peritheliomas, hydromyelia, partial gigantism, hemangiomas, polydactyly, macroglossia, and leontiasis ossea<sup>1,10,11</sup>. Familial occurrence has been reported<sup>1,12</sup>. Coexisting conditions in LDD patients include neurofibromatosis and postural hypotension<sup>13,14</sup>. Coexist-

ence of Cowden disease or multiple hamartoma syndrome, an autosomal dominant disorder of the skin and mucous membranes, with LDD has been described in eight reports<sup>12,15-21</sup>, suggesting that this constellation of diseases represents a phakomatosis. Characteristic skin lesions include multiple facial papules and cobblestone-like trichilemmomas. In this syndrome, thyroid disorders are also common and malignancies of the breast, colon and adnexa may occur<sup>2</sup>. Ambler et al.<sup>1</sup> have published an extensive review of 34 patients with LDD in 1969, and 64 patients have been described in the literature since then. Owing to the wide availability of MRI, 45 LDD patients have been reported since 1989<sup>2</sup>.

Patients usually present clinically in the third and fourth decade of life with signs and symptoms of cerebellar dysfunction (less frequent) and/or hydrocephalus (more common, associated with headaches, ataxia, visual disturbances, nausea and vomiting)<sup>21</sup>. The male to female ratio is approximately 1:1<sup>22</sup>. The duration of symptoms ranges from several months to more than ten years<sup>13,23</sup>. A case of LDD in a newborn has also been described, suggesting a very slow evolution of this dysplastic process in subsequently symptomatic patients<sup>24</sup>. Tumor regrowth after surgical resection has been recorded in a few cases<sup>9,21,25</sup>. Recurrence may be due to subtotal excision of the lesion<sup>21,25-28</sup>. The possibility of recurrent disease many years after gross surgical excision necessitates long-term follow-up<sup>2</sup>. Conventional x-ray, CT scans and angiography have not proven sensitive enough to demonstrate diagnostic features distinctive for LDD<sup>29</sup>. The usual CT appearance is a non-enhancing hypodense to isodense mass with occasional focal calcifications<sup>21,25,27,30-32</sup>. Compared with CT, MRI depicts the extent of LDD in a clearly superior manner<sup>13</sup>. On MRI, the lesion is typically of a moderately high signal on T2-weighted images and slightly hypointense to brain on T1-weighted images<sup>21</sup>. Normal gyration is preserved and the white matter is unaffected<sup>23,33,34</sup>. In some patients, the characteristic striated appearance of the cerebellum is sufficient now to regularly suggest the diagnosis of LDD preoperatively<sup>29</sup>.

## Conclusion

In this case report, we present a patient with dysplastic gangliocytoma of the cerebellum as both a hemispheric and vermian lesion. Due to the central location, early symptoms included hydrocephalus, while the typical cerebellar syndrome was poorly manifested. The diagnosis

was made preoperatively by MRI, which showed the characteristic striated appearance of the cerebellum. Although MRI cannot replace the pathohistologic diagnosis, the characteristic striated appearance seems to be strongly suggestive of LDD<sup>34</sup>.

Surgery appears to be the only efficient treatment, and repeated resection has been reported with generally good relief of symptoms<sup>9,13</sup>. Long-term follow-up is advisable in order to reduce the probability of occasional symptomatic recurrence and to identify the possible signs of Cowden disease, which carries a risk of developing malignancies.

The diagnosis of this rare entity should be considered in any young and middle-aged adult presenting with signs of intracranial hypertension combined with characteristic radiologic features. Our case supports and confirms the current state of the art on LDD that has been acquired by thorough analysis of clinical, radiologic and pathohistologic findings.

## References

1. AMBLER M, POGACAR S, SIDMAN R. Lhermitte-Duclos disease (granule cell hypertrophy of the cerebellum): pathological analysis of the first familial case. *J Neuropathol Exp Neurol* 1969;28:622-47.
2. KULKANTRAKORN K, AWWAD EE, LEVY B et al. MRI in Lhermitte-Duclos disease. *Neurology* 1997;48:725-31.
3. SIDDIQI SN, FEHLINGS MG. Lhermitte-Duclos disease mimicking adult-onset aqueductal stenosis. *J Neurosurg* 1994;80:1095-8.
4. Di LORENZO N, LUNARDI P, FORTUNA A. Granulomolecular hypertrophy of the cerebellum (Lhermitte-Duclos disease): case report. *J Neurosurg* 1984;60:644-6.
5. LHERMITTE J, DUCLOS P. Sur un ganglioneuroma diffus du cortex du cervelet. *Bull Assoc Fr Etude Cancer* 1920;9:99-107.
6. RUSSEL DS. Gangliomatosis of the cerebellum. In: RUSSEL DS, RUBINSTEIN LJ, eds. *Pathology of tumours of the nervous system*. London, Melbourne, Auckland: Edward-Arnold, 1989:302-4.
7. VARTER JE, MERREN MD, SWANN KW. Preoperative diagnosis of Lhermitte-Duclos disease by magnetic resonance imaging. *J Neurosurg* 1989;70:135-7.
8. WOLANSKY LJ, MALANTIC GP, HENRY R et al. Preoperative MRI diagnosis of Lhermitte-Duclos disease: case report with associated enlarged vessel and syrinx. *Surg Neurol* 1996;45:470-6.
9. MARANO SR, JOHNSON PC, SPETZLER RF. Recurrent Lhermitte-Duclos disease in a child: case report. *J Neurosurg* 1988;69:599-603.
10. OPPENHEIMER DR. A benign "tumour" of the cerebellum: report on two cases of diffuse hypertrophy of the cerebellar cortex with review of nine previously reported cases. *J Neurol Neurosurg Psychiatry* 1955;18:199-213.

11. LEECH RW, CHRISTOFERSON LA, GILBERTSON RL. Dysplastic gangliocytoma (Lhermitte-Duclos disease) of the cerebellum: case report. *J Neurosurg* 1977;47:609-12.
12. PADBERG GW, SCHOT JD, VIELVOYE GJ, BOTS GT, de BEER FC. Lhermitte-Duclos disease and Cowden disease: a single phakomatosis. *Ann Neurol* 1991;29:517-23.
13. MILBOUW G, BORN JD, MARTIN D et al. Clinical and radiological aspects of dysplastic gangliocytoma (Lhermitte-Duclos disease): a report of two cases with review of the literature. *Neurosurgery* 1988;22:124-8.
14. RUCHOUX MM, GRAY F, GHERARDI R, SCHAEFFER A, COMOY J, POIRIER J. Orthostatic hypotension from a cerebellar gangliocytoma (Lhermitte-Duclos disease): case report. *J Neurosurg* 1986;65:245-8.
15. ALBRECHT S, HABER RM, GOODMAN JC, DUVIC M. Cowden syndrome and Lhermitte-Duclos disease. *Cancer* 1992;70:869-76.
16. ENG C, MURDAY V, SEAL S et al. Cowden syndrome and Lhermitte-Duclos disease in a family. A single genetic syndrome with pleiotrophy? *J Med Genet* 1994;31:458-61.
17. RIMBOU J, ISAMAT F. Dysplastic gangliocytoma of the cerebellum (Lhermitte-Duclos disease) and its relation to the multiple hamartoma syndrome (Cowden disease). *J Neurooncol* 1994;18:191-7.
18. VINCHON M, BLOND S, LeJUENE JP et al. Association of Lhermitte-Duclos and Cowden disease: report of a new case and review of the literature. *J Neurol Neurosurg Psychiatry* 1994;57:699-704.
19. VITAL A, VITAL C, MARTIN-NEGRIER ML et al. Lhermitte-Duclos type cerebellum hamartoma and Cowden disease. *Clin Neuropathol* 1994;13:229-31.
20. WELLS GB, LASNER TM, YOUSEM DM, ZAGER EL. Lhermitte-Duclos disease and Cowden's syndrome in an adolescent patient. *J Neurosurg* 1994;81:133-6.
21. WILLIAMS DW III, ELSTER AD, GINSBERG LE, STANTON C. Recurrent Lhermitte-Duclos disease: report of two cases and association with Cowden's disease. *AJNR Am J Neuroradiol* 1992;13:287-90.
22. HULCELLE P, DOOMS G, VERMONDEN J. Lhermitte-Duclos disease: a case report. *J Neuroradiol* 1994;21:40-5.
23. SMITH RR, GROSSMAN RI, GOLDBERG HI, HACKNEY DB, BILANIUK LT, ZIMMERMAN RA. MR imaging of Lhermitte-Duclos disease: a case report. *AJNR Am J Neuroradiol* 1989;10:187-9.
24. ROESSMANN U, WONGMONGKOLRIT T. Dysplastic gangliocytoma of the cerebellum in a newborn: case report. *J Neurosurg* 1984;60:845-7.
25. REEDER RF, SAUNDERS RL, ROBERTS DW, FRATKIN JD, CROMWELL LD. Magnetic resonance imaging in the diagnosis and treatment of Lhermitte-Duclos disease (dysplastic gangliocytoma of the cerebellum). *Neurosurgery* 1988;23:240-5.
26. HAIR LS, SYMMANS F, POWRES JM, CARMEL P. Immunohistochemistry and proliferative activity in Lhermitte-Duclos disease. *Acta Neuropathol (Berl)* 1992;84:570-3.
27. RADHAKRISHNAN VV, SANDHYAMANI S, SHARMA R, ROUT D. Dysplastic gangliocytoma of the cerebellum (Lhermitte-Duclos disease): a case report with review of the literature. *Indian J Cancer* 1992;29:86-9.
28. STAPLETON SR, WILKINS PR, BELL BA. Recurrent dysplastic cerebellar gangliocytoma (Lhermitte-Duclos disease) presenting with subarachnoid hemorrhage. *Br J Neurosurg* 1992;19:133-8.
29. MALIK MM, SELHORST JB, LEVY E, COLE HO, LEAKE D, GUSSLER JR. Noninvasive diagnosis of Lhermitte-Duclos disease. *Neurology* 1992;42 (Suppl 3):235. (Abstract)
30. DIETLIN M, SCHRÖDER R, WIDEMANN B, BENZ-BÖHM G. Dysplastic gangliocytoma of cerebellum in a newborn. *Pediatr Radiol* 1992;22:131-3.
31. SABIN HI, LIDOV HG, KENDALL BE, SYMON L. Lhermitte-Duclos disease (dysplastic gangliocytoma): a case report with CT and MRI. *Acta Neurochir (Wien)* 1988;93:149-53.
32. SHANLEY DJ, VASSALO CJ. Atypical presentation of Lhermitte-Duclos disease: preoperative diagnosis with MRI. *Neuroradiology* 1992;34:103-4.
33. CARTER JE, MERREN MD, SWANN KW. Preoperative diagnosis of Lhermitte-Duclos disease by magnetic resonance imaging. *J Neurosurg* 1989;70:135-7.
34. SONIER CB, FEVE JR, De KERSAINT-GILLY A, RUCHOUX MM, RYMER R, AUFRAY E. Lhermitte-Duclos disease: a rare cause of intracranial hypertension in adults. *J Neuroradiol* 1992;19:133-8.

## Sažetak

INTRAKRANIJSKA HIPERTENZIJA UZROKOVANA LHERMITTE-DUCLOSOVOM BOLEŠĆU:  
PRIKAZ SLUČAJA

V. Beroš, T. Sajko, J. Talan-Hranilović i L. Negovetić

Mlada žena u dobi od 24 godine primljena je sa simptomima povišenog intrakranijskog tlaka. Kompjutorizirana tomografija pokazala je hipodenznu cerebelarnu masu. Prikaz pomoću magnetske rezonance otkrio je veće oštećenje unutar lijeve cerebelarne polutke i vermisa, koje je smanjilo četvrti ventrikul i pritisnulo akvedukt uz posljedičnu dilataciju ventrikularnog sustava. Slučaj se opisuje zbog rijetke pojave središnje lokalizirane Lhermitte-Duclosove bolesti. Učinjena je subtotalna resekcija lezije, a histološki su nalazi potvrdili prijeoperacijski postavljenu dijagnozu. Magnetska rezonanca pruža mogućnost poboljšanja kirurškog pristupa i procjenu dugotrajnog praćenja, smanjujući tako vjerojatnost ponovne pojave bolesti i komplikacija. Stoga se magnetska rezonanca smatra metodom izbora u postavljanju dijagnoze Lhermitte-Duclosove bolesti.

Ključne riječi: *displastični gangliocitom, Lhermitte-Duclosova bolest, intrakranijska hipertenzija, stenozna akvedukta, cerebelarna lezija*