

FIRST EXPERIENCES IN ENDOLUMINAL REPAIR OF ABDOMINAL AORTIC ANEURYSM USING BIFURCATED STENT GRAFT

Ivo Lovričević¹, Vladimir Tonković², Ivo Despot¹, Drago DeSyo¹, Marijan Lovrenčić² and Zdenko Novotny³

¹Division of Vascular Surgery, Department of Surgery, ²Department of Radiology, and ³Department of Anesthesiology, Sestre milosrdnice University Hospital, Zagreb, Croatia

SUMMARY - The procedure of non-ruptured abdominal aortic aneurysm endoluminal repair is described. The first two procedures in Croatia by use of an AneuRx stent graft were performed in two patients admitted to the Division of Vascular Surgery, Sestre milosrdnice University Hospital in Zagreb. To our knowledge, these were the first self-supporting procedures carried out in Croatia. The principal characteristics of endoluminal material and equipment as well as their use are presented. Preoperative diagnostic procedures and postoperative course in the two patients are also described. Special emphasis is given to the indications and contraindications for this type of procedure as well as to the major possible complications. Endoluminal repair for aortic aneurysm is a new and revolutionary approach to the treatment of this serious and severe illness. Endovascular surgery is expected to mark the first decade of the new millennium.

Key words: *Aortic aneurysm, abdominal; Aortic aneurysm, abdominal - surgery; Stents; Tomography, x-ray - computed*

Introduction

Abdominal aortic aneurysm (AAA) is the most common atherosclerotic aortic disease, the incidence of which has been on a constant rise for the past three decades¹. By definition, AAA is a permanent local widening of the lumen surpassing the normal diameter by at least 50%, located between the renal arteries and the aortic bifurcation². The disease is most commonly found in the older age group, more commonly in males than in females, and it is encountered in 3 to 6 per cent of the population over 65^{2,3}.

The first surgical repair was performed by Dubost⁴. Since that first surgical procedure, the mortality rate of the electively operated patients has been constantly decreasing, owing to improved surgical and anesthesiology practices and techniques. Currently, the mortality rate is between 3 and 5 per cent of the total number of surgically treated patients. However, the mortality due to aneurysm rupture in surgically treated patients is high and exceeds 50%.

The new, endoluminal approach was first seen in the work of Parodi et al. 1991⁵, and has gradually paved its way to daily surgical practice as a minimally invasive surgical procedure. AAA endoluminal repair is currently used in the United States and western Europe. The first Croatian attempts in the use of the technique are described, briefly presenting the information available.

There are several models of different stent grafts. The most commonly used models are Meadox Vanguard Graft, World Medical Talent Graft and Medtronic AneuRx Graft, the latter used in the two cases presented, and many others.

Correspondence to: Ivo Lovričević, M.D., M.S., Division of Vascular Surgery, Department of Surgery, Sestre milosrdnice University Hospital, Vinogradska c. 29, HR-10000 Zagreb, Croatia

Received May 25, 1999, accepted in revised April 14, 2000

Subjects and Methods

Asymptomatic aneurysms were diagnosed in two males aged 52 and 64 years. Their ultrasound findings showed aneurysmal widening with the longest diameter of 4.5 and 6 centimeters, respectively. The indications for endovascular operation were made in the same way as those for open surgical repair of AAA. A criterion for the use of this technique was morphological possibility to use endoprosthesis.

Standard preoperative diagnosis included computed tomography (CT) in 5-mm slices, including the area from the suprarenal level down to the iliac arteries, and arteriography. The purpose of the diagnostic procedures was to obtain a detailed insight into the morphology of the aorta and its branches, with special reference to the position of the renal arteries and the length of the aortic neck. Another

important aspect to take in consideration was the structure of the iliac arteries, i.e. their angulations and narrowings. Finally, the preoperative CT scans and arteriography readings enabled us to determine the length and width of the aorta and iliac arteries, necessary for selection of an appropriate stent graft.

The patients were operated on under endotracheal anesthesia and systemic heparinization of 100 mg per kg body weight. The operative procedure exposed both groins, i.e. common femoral arteries with their branches. Intraoperative arteriography was performed, and stent grafts were placed by means of an intra-arterial conductor and inserted by means of a delivery catheter. In both patients, bifurcated stent grafts measuring 26x15 mm, 16.5 cm long, were placed.

The intraoperative course was uneventful in both patients. The loss of blood did not exceed 200 mL. The du-

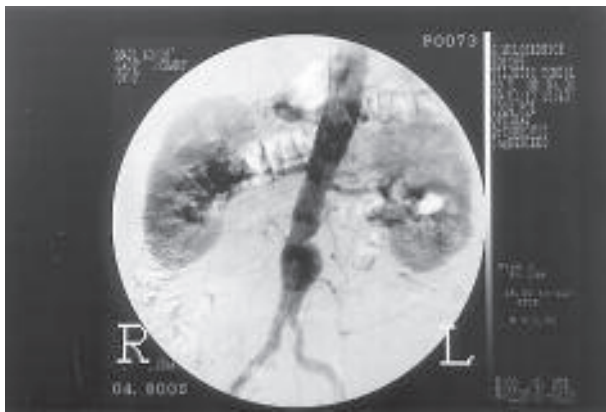

Fig. 1. Angiography and CT scans of patient 1: infrarenal abdominal aortic aneurysm with largest diameter of 4.5 cm.

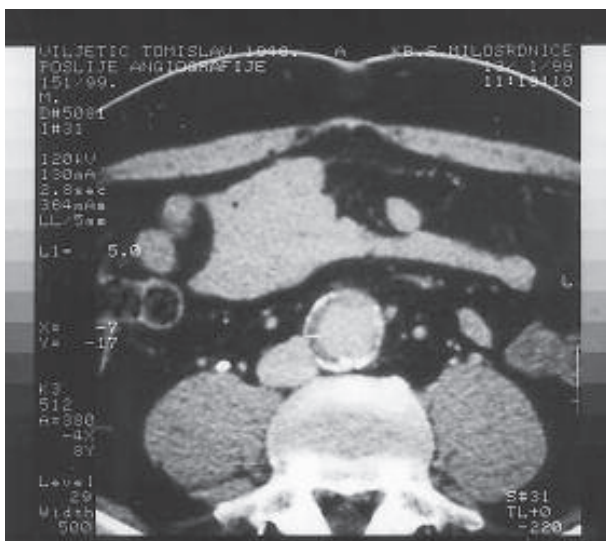
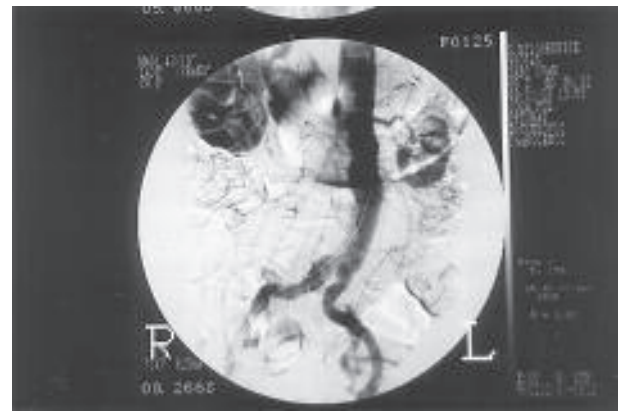


Fig. 2. Angiography and CT scans of patient 2: saccular aneurysm with largest diameter of 6 cm.

ration of each surgical procedure was approximately 2 hours and 30 minutes.

The postoperative course also proceeded uneventfully. The patients were discharged from the hospital on day 7 after abdominal CT scanning which showed the position of the stent grafts and which would have revealed any possible endoleaks. CT scans showed that both stent grafts were well placed, and there was no internal hemorrhage or endoleaks.

The main characteristic of the stent grafts chosen in these two cases is that they are made from woven thin-wall polyester, reinforced by nitinol stent which self-expands when exposed to high temperature. The graft is inserted into the 'delivery catheter' in which it is compressed, and this is how it is introduced into the artery. Stent grafts are available in five different size combinations, and their bi-

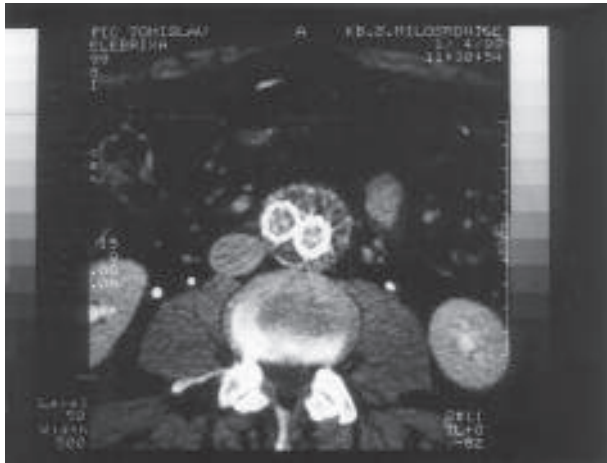


Fig. 3. Patient 1 postoperative CT scan: right position of the iliac segment of the prosthesis; no endoleak was observed.

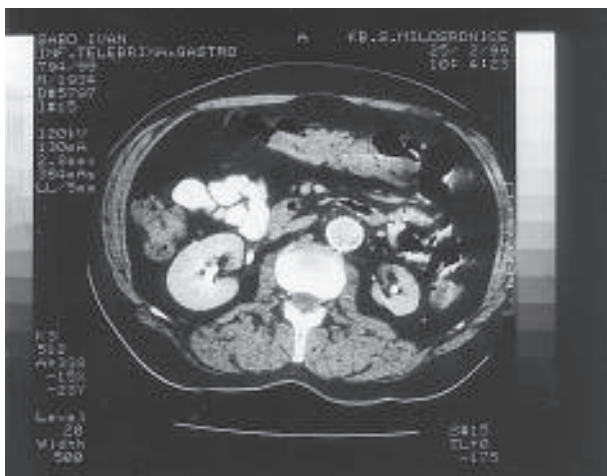

Fig. 4. Patient 2 postoperative CT scan: right position of infrarenal and iliac prosthesis; no endoleak was observed.

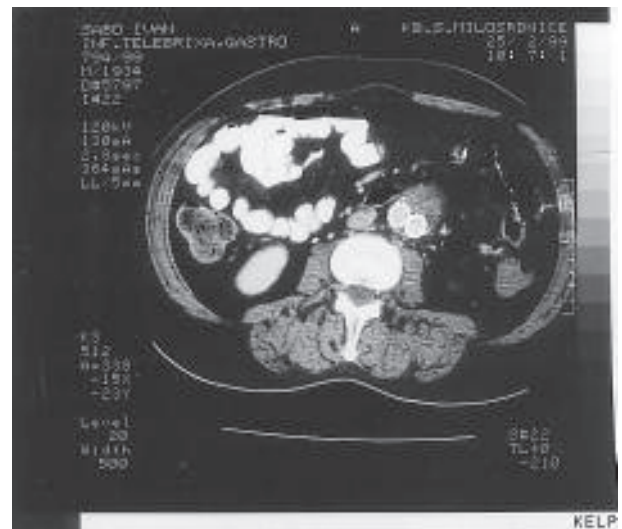furcated diameters range from 20x12 mm to 28x16 mm. The first figure represents the diameter of the aortic segment, and the second one is the diameter of the iliac segment. A special attachment for the other leg has to be of the same iliac dimension. The standard device includes cuffs for the aortic and iliac segments. The grafts are supplied in two different lengths, 13.5 and 16.5 cm.

Surgical procedure requires special equipment which includes introducers, guides and catheters, i.e. all equipment needed for intraoperative arteriography and radiology interventions. In addition, the following devices, included in the AneuRx Endovascular Delivery System, are needed for the graft insertion: rapid track introducer sheath; delivery catheter; and deployment handle.

The delivery of the graft is performed in a surgically sterile operating room environment, enabling intraoperative diascopy and arteriography. Surgical staff are ready for possible conversion into open surgical repair.

By means of the above mentioned equipment, a bifurcated graft stent is placed between the infrarenal part of the aorta up to the bifurcation of the common iliac artery, the two representing the two fixed attachment zones. The infrarenal aortic neck should be approximately 2 cm long, and definitely not shorter than 1 cm. Due to its structure, i.e. its mobility and partial adaptability, the graft is adaptable to the arterial structure in the area of the non-fixed attachment zones.

During the placement of the graft, radiopaque marker points, co-ordinated with preoperative and intraoperative arteriography and diascopy on the x-ray monitor, serve for orientation.



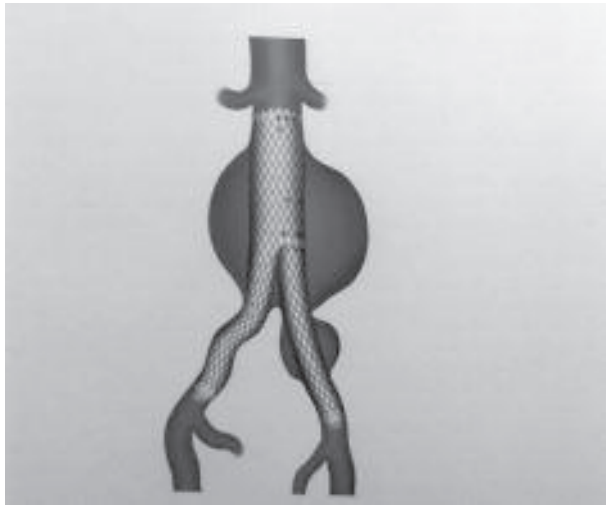


Fig. 5. Right position of the prosthesis at the end of the procedure.

Discussion

The AAA rupture is a well known phenomenon in surgical practice with a high mortality rate. It requires a very demanding surgical treatment, associated with a number of complications during the intra- and postoperative course, and a very uncertain outcome. On the other hand, it is also known that the 5-year survival rate of non-surgically treated patients with hemodynamically significantly enlarged aneurysms is less than 20%, and that the prognosis for the electively operated patients is much more favorable, with a 5-year survival rate of 64%^{6,7}. These facts point to the significance of the problem as well as to the inevitability of surgical intervention.

The indications for endoluminal procedure are the same as for the elective surgical treatment, and include aneurysms of more than 5 cm in diameter, aneurysms between 4 and 5 cm in diameter with a documented increase of 0.5 cm in the past 6 months, and aneurysms of an eccentric shape, however, these give rise to the question whether small aneurysms should be considered for surgical treatment in a great number of cases, because this less hazardous and less invasive approach would prevent their further growth. There also are some morphological preconditions for the use of endoluminal stent graft. They primarily include the above mentioned sufficiently long infrarenal aneurysm neck, which should be approximately 2 cm long and not more than 24 mm wide. Another precondition is the patency of iliac arteries, i.e. the absence of narrowings of less than 6 mm in diameter. In practice, this means that 30%-

50% of all abdominal aneurysms can be managed in this way.

Contraindications for the placement of an endoluminal stent graft include the restrained use of x-ray in some patients, and signs of a systemic infection for the management of elective hemodynamically significant aneurysms.

A rational indication for the treatment of AAA either by open or by endovascular surgery may be based on the premise that the mortality associated with this mode of treatment is lower than the risk of rupture within one year⁸. In recent studies, the early mortality of endovascular AAA repair varied from 0 to 6.6%⁹. A few studies comparing patients treated with stent grafts with a contemporary control patient group treated by open surgery showed no difference in the mortality^{10,11}.

At the same time, the main advantages of endovascular procedure include lower incidence of systemic complications, faster recovery, and reduced hospital stay.

Given the loss of blood of not more than 100-200 mL and the fact that the operative procedure itself takes approximately 2 hours under epidural anesthesia, it is obvious that this type of surgical repair should be adopted as the method of choice in high-risk patients. The main disadvantage of the procedure is the high cost of stent graft and need of long-term follow-up by imaging techniques, because of the risk of the occurrence of late endoleak.

Nowadays, the matter of interest mostly are bifurcated grafts because of a number of problems associated with the use of tubular grafts. The number of AAAs with a sufficiently long segment of normal dimensions above the aortic bifurcation, which is a precondition for the placement of a tubular graft, is rather low. On the other hand, the abdominal aorta is usually distinctly calcified and of an elliptic shape in this bifurcated segment, hence it is often the site of endoleak^{12,13}.

The success of the graft placement and the rate of complications are not presented in statistical terms because of the short time elapsed, since these grafts were actually placed for the first time and their number was too small (n=2) for any statistical analysis to perform. However, initial reports from other studies indicate that the graft delivery was associated with a very low rate of complications requiring conversion. Thus, in a series of 113 endoluminal grafts placed in Sydney in 1997¹⁴, intraoperative conversion was required in 18 patients. The Medtronic training center in Perugia reports on only one conversion in 150 patients. Similar data, with an ever lower relative number of conversions, have been communicated directly by Dr. Moll from Nieuwegein, the Netherlands.

In all reports, the so-called endoleak, i.e. bleeding within the aneurysm sac close to the graft inserted, is the most commonly described complication. The reports differentiate between primary 'endoleak', observed during the surgical repair, and secondary endoleak, detected on subsequent diagnostic procedures^{13,15,16}. This complication may lead to the aneurysm growth and rupture.

The Eurostar Register has been established in Europe in order to come up with some conclusions which would be common to all European centers for endovascular surgery¹³. This study included data on more than 1000 patients in total.

The most common complication, endoleak, is seen in 5% to 44% of patients. Although a half of them stop spontaneously, there have been some proposals for endovascular and surgical management of this complication.

Another parameter followed by the Eurostar Register is the dynamics of the possible aneurysm growth. Despite the placement of endoluminal grafts, aneurysm continues to grow in 11% of patients who also have endoleaks.

Endovascular repair is most probably a breakthrough in the treatment of AAA. Although still in an initial stage, it is gaining an ever more important place in the treatment of this serious condition due to its non-invasiveness and low intraoperative morbidity rate. It may be expected that the future use will lead to improvements in the technical characteristics of stent grafts and delivery materials as well as in the placement of grafts and management of complications, thus making it possible to evaluate the procedure and assess its benefits over a longer period of time.

References

- NEVIT MP, BALLARD DJ, HALLET JW. Prognosis of abdominal aortic aneurysms. A population based study. *N Engl J Med* 1989;321:109-14.
- BENGTSSON H, BERQUIST D, EKBERG O, JANZON L. A population based screening of abdominal aortic aneurysms (AAA). *Eur J Vasc Surg* 1991;5:53-7.
- BENGTSSON H, BERQUIST D, STERNBY NH. Increasing prevalence of abdominal aortic aneurysms. A necropsy study. *Eur J Surg* 1992;158:19-23.
- DUBOST C. Resection of an aneurysm of the abdominal aorta - re-establishment of the continuity by preserved human arterial graft with results after 5 months. *Arch Surg* 1952;64:405-8.
- PARODI JCL, PALMAZ JCL, BARONE HD. Transfemoral intraluminal graft implantation for abdominal aortic aneurysm. *Ann Vasc Surg* 1991;5:491-9.
- ERNST C. Abdominal aortic aneurysm. *N Engl J Med* 1993;328:1167-72.
- POLTERAURER P, PRAGER M, HLEZENBEIN T. Dacron vs PTFE in aortoiliac reconstruction: results of prospective randomised trial. *Surgery* 1992;111:626-33.
- SCOTT RAP, TISI PV, ASHTON HA, ALLEN DR. Abdominal aortic aneurysm rupture rates: a 7 year follow up of the entire abdominal aortic aneurysm population detected by screening. *J Vasc Surg* 1998;28:13-20.
- CUYPERS Ph, BUTH J, HARRIS PL, GEVERS EL. On behalf of Eurostar Collaborators. Realistic expectations for patients with stent-graft treatment of abdominal aortic aneurysms. Results of European Multicentre Registry. *Eur J Vasc Endovasc Surg* 1999;17:507-16.
- MAY J, WHITE GH, YU W. Concurrent comparison of endoluminal versus open repair in the treatment of abdominal aortic aneurysms: analysis of 303 patients by life table method. *J Vasc Surg* 1998;27:213-21.
- ZARINS CK, WHITE RA, SCHWARTEN D, KINNEY E, DIETRICH EB, HODGSON KJ, FOGARTY TJ. For investigators of the Medtronic AneuRx Multicenter Clinical Trial, Stanford, California. AneuRx stent graft versus open surgical repair of abdominal aortic aneurysms: multicenter prospective clinical trial. *J Vasc Surg* 1999;29:292-308.
- COLBURN MD, MOORE WS. Endovascular repair of abdominal aortic aneurysms using the EGS tube and bifurcated graft system. *World J Surg* 1996;20:664-72.
- MOORE WS, RUTHEFORD RB. Transfemoral endovascular repair of abdominal aortic aneurysm: results of the North American EVT phase I trial. *J Vasc Surg* 1996;23:543-53.
- MAY J, WHITE GH, WAUGH W, YU R, STEPHEN M, SINEURINE K, HARRIS P. Conversion from endoluminal to open repair of abdominal aortic aneurysms: a hazardous procedure. *Eur J Vasc Endovasc Surg* 1997;14:4-11.
- HARRIS PL, BUTH J, MIALHE C, MYHRE H, NORGRÉN L. The need for clinical trials of endovascular abdominal aortic stent/graft repair; the Eurostar project. *J Endovasc Surg* 1997;4:72-9.
- WAIN GH, MARIN ML, OHKI T, SANCHEZ LA, LYON RT, ROZENBLIT A, SUGGS WD, YUAN JG, VEITH FJ. Endoleaks after endovascular graft treatment of aortic aneurysms: classification, risk factors an outcome. *J Vasc Surg* 1998;27:69-80.

Sažetak

PRVA ISKUSTVA U ENDOLUMINALNOJ REKONSTRUKCIJI ANEURIZME ABDOMINALNE AORTE
UZ UPOTREBU BIFURKACIJSKE PROTEZE

I. Lovričević, V. Tonković, I. Despot, D. DeSyo, M. Lovrenčić i Z. Novotny

Prikazan je postupak endoluminalne rekonstrukcije nerupturirane aneurizme abdominalne aorte. Operacije je izvedena u dvojice bolesnika na Odjelu za vaskularnu kirurgiju Kliničke bolnice "Sestre milosrdnice" u Zagrebu, upotrebom AneuRx stent grafta. Prema našim spoznajama, operacija je prvi put samostalno učinjena u Hrvatskoj. Prikazana su glavna obilježja materijala i uređaja te njihova primjena. Također se daje prikaz prijeoperacijske dijagnostike i poslijeoperacijskog tijeka u dvojice operiranih bolesnika. Navedene su indikacije i kontraindikacije za primjenu postupka, kao i glavne moguće komplikacije. Endoluminalni način u liječenju aneurizme abdominalne aorte predstavlja nov i revolucionaran pristup, primjena kojega će doći do izražaja u prvom desetljeću novoga tisućljeća.

Ključne riječi: Aneurizma aorte, abdominalna; Aneurizma aorte, abdominalna - kirurgija; Stent; Tomografija, radiografija - kompjutorizirana