

NEUROLOGIC SYMPTOMS AS FIRST SIGNS OF BRAIN TUMOR IN CHILDREN

Branka Mučić-Pucić, Ljerka Cvitanović-Šojat, Tomislav Hajnžić and Marina Matajija

University Department of Pediatrics, Sestre milosrdnice University Hospital, Zagreb, Croatia

SUMMARY – During a 15-year period (1985-1999), 181 children were hospitalized at the Oncological Ward of the Department for Pediatrics, for primary brain tumor. Medical records were reviewed to assess the duration and prevalence of symptoms prior to diagnosis. Headache was the leading symptom found in 47% of children, followed by vomiting in 31%, ataxia in 27%, and ocular symptoms in 23% of children with brain tumor. Neurologic problems as the only symptom of brain tumor may mislead pediatricians and neuropaediatricians, so that a low index of suspicion may delay the diagnosis. The aim of this 15-year casuistics analysis was to help improve the diagnostic procedure and reduce the delay in reaching the diagnosis.

Key words: *Nervous system neoplasms, diagnosis; Neurologic examination; Child;*

Introduction

Intracranial tumors are the second most common malignancy of childhood, immediately following leukemia¹. The overall (population) incidence of intracranial neoplasms varies between 1:20,000 and 1:100,000 in different series. These tumors may be slightly less common in adolescents than in younger children². Primary brain tumors are the most common solid tumors that occur in childhood. The clinical symptomatology of intracranial tumors is often atypical, with only minor clinical symptoms that may not be different from those in common benign illnesses of children. Therefore, the possibility of a brain neoplasm should always be borne in mind, even if it materializes only rarely. The symptoms and signs differ with the location of the tumor and, to a certain extent, its histologic nature, these two factors being related. It is also essential to realize that the clinical significance of pathologic grading may be different from its biological value. A benign tumor that is strategically located so as

to be impossible to remove without interfering with the essential neural function is malignant for the patient even if histologically benign. Generally, supratentorial tumors account for about half the cases. The location varies with age. In infants, there is a predominance of supratentorial tumors, and in children older than 4 years of infratentorial tumors. The reasons for the changing age distribution of supra- and infratentorial tumors are poorly understood³. Most tumors of the central nervous system (CNS) occur in children without personal or familial predisposing conditions.

Signs of intracranial hypertension are: headache, vomiting, papilloedema, and diplopia.

Headache may be severe and relieved by vomiting. More often it is mild, but persistent, especially if it occurs in the morning, and must always attract the physician's attention.

Vomiting is one of the most constant signs of intracranial hypertension. It is usually but not always associated with headaches. Vomiting due to increased intracranial pressure is usually unremarkable except for its repetition and frequent morning recurrence^{1,4}.

Papilloedema makes an intracranial mass highly probable, but it is absent in more than half the children with brain tumors. So, its absence does not exclude the possi-

Correspondence to: *Branka Mučić-Pucić, M.D.*, University Department of Pediatrics, Sestre milosrdnice University Hospital, Vinogradska c. 29, HR-10000 Zagreb, Croatia

Received June 8, 2000, accepted in revised form March 13, 2001

bility of brain tumor. Papilloedema is not specific for brain tumors and may be present with increased intracranial pressure due to other causes as well as in certain conditions unassociated with intracranial hypertension.

In some patients, diplopia may be the first symptom and is due to paralysis of the sixth cranial nerve.

In order to clarify the features that might facilitate early recognition of brain tumors in children, our patient records were reviewed, with special reference to the time elapsed from the onset of neurologic symptoms and signs to the diagnosis of brain tumor.

Patients and Methods

Data of 181 children with brain tumors, admitted to the Departments of Neurology and of Oncology, Sestre milosrdnice University Hospital, during the 1985-1999 period, were retrospectively analyzed. Their charts were reviewed. The age at onset of symptoms, first presentation to a pediatric unit, presenting features, tumor site of origin, and type and diagnosis were recorded. Also, a detailed history and physical status of the child were recorded for each child. Computed tomography (CT) or magnetic resonance imaging (MRI) was performed in all patients. CT scan is the major neuroradiological investigation and is usually sufficient for the diagnosis, less expensive and more readily available. MRI is valuable for additional definition of brainstem tumors.

Results

Data of 92 boys and 89 girls were analyzed. The boys to girls ratio was 1.1:1 (Table 1). The age range was 0 to 16 years. According to specific developmental characteristics, patients were divided into age groups as follows: 0-2 years, 2-5 years, and 5-16 years. Careful history was taken, and detailed physical and neurologic examinations

Table 1. Rate of brain tumors according to age and gender

Age (yrs)	Male		Female		Total	
	n	%	n	%	n	%
0-2	18	9.9	19	10.5	37	20.4
2-5	24	13.3	20	11.0	44	24.3
5-16	50	27.6	50	27.6	100	55.2
Total	92	50.8	89	49.2	181	100.0

were performed. The diagnosis was confirmed by brain CT scan with and without iodine contrast injection.

The duration of symptoms before the diagnosis of brain tumor was analyzed. The symptoms were classified into 6 categories: headache, vomiting, ocular impairments (papilloedema, blurred vision, diplopia), ataxia, convulsions, and others (retarded development, fatigue, mood changes). Patients with multiple symptoms were classified in each of the respective categories.

Methods of descriptive statistics were used for data processing.

Headache was the leading symptom in 47% of study children (Fig. 1). It showed considerable qualitative variation, from the pattern of early morning headaches associated with vomiting to the type that may be relieved by usual analgesics. Vomiting was present in 31% of children, alone or associated with headache. Ataxia was present in 27% of children, and ocular impairments were recorded in 23% of children. Lassitude, self- or parent-reported, occurred in 16%, and convulsions in 12% of children. Presenting symptoms before making the diagnosis are shown in Fig. 1.

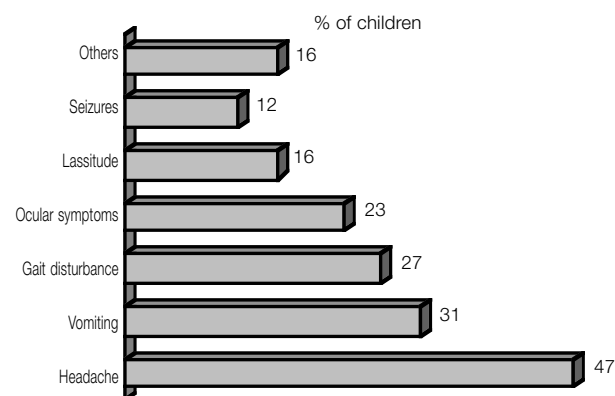


Fig. 1. Rate of symptoms in children with brain tumors before diagnosis

Headache was almost equally present in supratentorial and infratentorial tumors. Vomiting was present in 19% of infratentorial and 12% of supratentorial tumors. Gait disturbance was more pronounced in infratentorial than in supratentorial localizations (20% vs. 7%). Ocular disturbances were present in 14% of supratentorial and in 9% of infratentorial tumors. Seizures occurred in 9% of supratentorial and in only 3% of infratentorial localizations (Fig. 2).

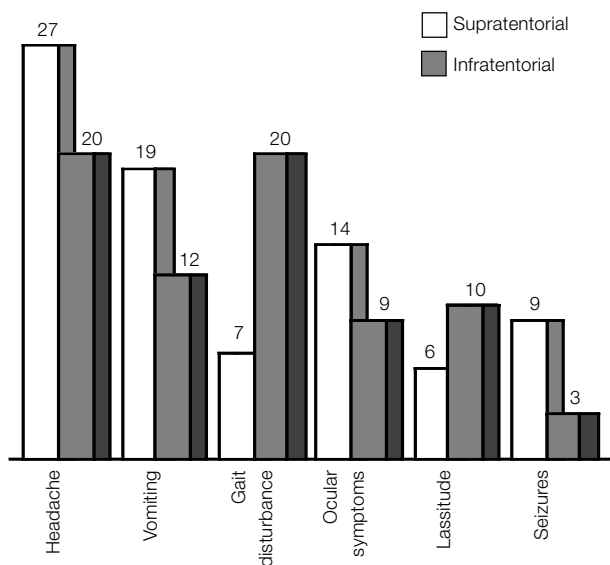


Fig. 2. Symptoms and brain tumor localization

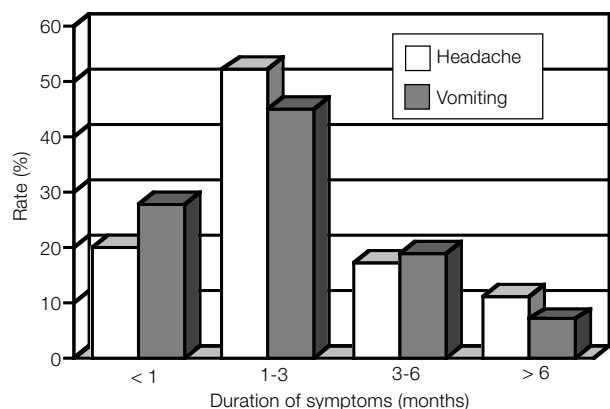


Fig. 3. The leading symptom duration in children with brain tumors

Table 2. Tumor localization according to age

Age (yrs)	Supratentorial		Infratentorial		Total	
	n	%	n	%	n	%
0-2	20	11.0	17	9.4	37	20.4
2-5	22	12.2	22	12.1	44	24.3
5-16	61	33.7	39	21.5	100	55.2
Total	103	56.9	78	43.1	181	100.0

The symptoms lasted from several days to several months. Most of them lasted for 1-3 months before reaching the final diagnosis (Fig. 3).

Tumor localizations are shown in Table 2. Supratentorial tumors were more common in infants (0-2 yrs) ,

whereafter a higher incidence of infratentorial tumors was reported. However, in our study an equal rate of supra- and infratentorial tumors was observed. At the age of 5 years, supratentorial tumors were found to prevail.

Discussion

Intracranial tumors presenting in the first years of life are uncommon in general pediatric practice. Many of the presenting symptoms are also common to other frequent childhood illnesses. The diagnosis may be especially difficult in the first two years of life. We tried to identify the reasons for the delay in reaching the diagnosis of brain tumor in children, and to propose a way to reduce the time elapsed from the onset of symptoms and signs to the diagnosis.

Our results showed a high incidence of headache (47%) as a presenting symptom of brain tumor in children. Headache with vomiting and ocular impairments was present in 23% of the children with brain tumors. In our series, 55% of the children had headache, ataxia and ocular impairments as presenting symptoms. If vomiting is added, these four symptoms were present in 73% of study patients. Vomiting, which is one of the most common signs of raised intracranial pressure but is not necessarily restricted to the early morning, occurred in 31% of study patients. This symptom is easily attributable to more common illnesses encountered in daily pediatric practice, but may occasionally also be secondary to tumor invasion of the floor of the fourth ventricle¹¹.

A predominance of infratentorial over supratentorial tumors in children was shown at the age extremes⁶.

Only 23% of our patients had the classical triad of headache, vomiting and papilloedema. In very young children, papilloedema is often absent, but an infant may show a behavioral change⁸. Our results are consistent with those of other authors⁶⁻⁸. This finding may be explained by the fact that the fontanelle and sutures are open in small children, serving as a safety valve, or the tumor is growing fast.

Conclusion

Intracranial tumors present a diagnostic challenge in very young children. The symptoms and signs are often nonspecific, mimicking more common diseases. Therefore, the possibility of a brain neoplasm should always be considered, even if it materializes very rarely. Benign neu-

rologic symptoms such as headache, which last for 3 months or more, should indicate the need of additional studies. Our results highlighted the neurologic impairments which might facilitate early recognition of a brain neoplasm.

References

1. AICARDI J. Diseases of the nervous system in childhood. Oxford: Blackwell Scientific Publications, 1992:780,782,783,786,816.
2. DIEBLER C, DULAC O. Pediatric neurology and neuroradiology. Berlin: Springer, 1987; 7:234-8.
3. GIUFFRÉ R. Biological aspects of brain tumours in infancy and childhood. Childs Nerv Syst 1989;5:59.
4. BRETT EM. Paediatric neurology. London: Churchill Livingstone, 1997:537,538,539.
5. DUFFNER PK, COHEN ME, MEYERS MH et al. Survival of children with brain tumours: SEER program 1973-1980. Neurology 1986;36:597-601.
6. EDGEWORTH J, BULLOCK P, BAILEY A et al. Why are brain tumours still being missed? Arch Dis Child 1996;74:148-51.
7. ABU-AREFEH I, RUSSELL G. Prevalence of headache and migraine in school children. BMJ 1994;309:765-9.
8. GORDON GS, WALLACE SJ, NEAL JW. Intracranial tumours during the first two years of life: presenting features. Arch Dis Child 1995;73:345-7.
9. AYSUN S, TOPCU M, GUNAY M, TOPALOGLUH S. Neurologic features as initial presentations of childhood malignancies. Pediatr Neurol 1994;10:40-3.
10. RICKERT CH. Epidemiological features of brain tumours in the first 3 years of life. J Childs Nerv Syst 1998;14:547-50.
11. DUFFNER PK, COHEN ME. Treatment of brain tumours in babies and very young children. Paediatr Neurosci 1985-1986;12: 304-10.

Sažetak

NEUROLOŠKI SIMPTOMI KAO PRVI ZNACI TUMORA MOZGA U DJECE

B. Mučić-Pucić, Lj. Cvitanović-Šojat, T. Hajnžić i M. Mataija

Za vrijeme petnaestogodišnjeg razdoblja (1985.-1999.) na Onkološkom odsjeku Klinike za pedijatriju bilo je hospitalizirano 181 dijete zbog primarnog tumora mozga. Analizirali smo njihove povijesti bolesti kako bismo ustanovili zbog kojih su simptoma bili primljeni i kako dugo su simptomi trajali prije postavljanja dijagnoze. Glavobolja je bila vodeći simptom u 47% djece, zatim povraćanje u 31%, ataksija u 27% te očni simptomi u 23% djece s tumorom mozga. Neurološki simptomi kao jedini simptomi tumora mozga mogu pedijatru i neuropedijatru biti dijagnostički problem. Zbog toga se može kasniti s postavljanjem točne dijagnoze, što pogoršava prognozu u takvih bolesnika.

Ključne riječi: Neoplasme živčanog sustava, dijagnostika; Neurološki pregled; Dijete