

SONOGRAPHY OF THE GASTROINTESTINAL TRACT IN PEDIATRIC AGE: REVIEW

Goran Roić¹, Mario Kopljar², Neven Ljubičić⁴, Mario Zovak², Zoran Bahtijarević³, Vesna Posarić¹,
Dubravko Gogolja³, Stjepan Višnjić³ and Ivan Fattorini³

¹Department of Pediatric Radiology, Zagreb Children's Hospital; ²Department of Surgery, Sestre milosrdnice University Hospital; ³Department of Pediatric Surgery, Zagreb Children's Hospital; ⁴Department of Medicine, Sestre milosrdnice University Hospital, Zagreb, Croatia

SUMMARY – Modern sonography techniques are increasingly used for the evaluation of gastrointestinal tract in pediatric age. High-resolution real-time scanners, graded compression technique, along with color-flow and power Doppler, represent non-invasive, accurate and reliable diagnostic methods. Sonography can easily be performed for the diagnostic evaluation of acute abdominal pain, gastrointestinal inflammatory diseases and congenital anomalies. Current applications of modern sonography techniques in the evaluation and treatment of pediatric gastrointestinal diseases are presented.

Introduction

The development of the high-resolution real-time scanners and graded compression sonographic technique has enabled introduction of sonography into an until recently unconquered area, i.e. the hollow part of the gastrointestinal system. Although fluoroscopic contrast studies remain the primary means of evaluating mucosal and luminal abnormalities in the gastrointestinal tract, they provide limited information on bowel wall and extrinsic abnormalities. In some diseases of the gastrointestinal system, sonographic technique has almost entirely expelled and substituted contrast radiology studies, and has become the diagnostic method of choice (hypertrophic pyloric stenosis, acute appendicitis, invagination, mesenteric adenitis, acute terminal ileitis), while in other diseases it represents an important complementary imaging method, often providing key information required for the subsequent patient management¹.

Hypertrophic Pyloric Stenosis

As compared to other diagnostic modalities, sonography provides the advantage of direct visualization and measurement of pyloric muscle thickness in longitudinal and transverse scans²⁻⁴. The sonographic criteria recommended for hypertrophic pyloric stenosis (HPS) differ in part from author to author, but the most widely accepted criteria are pyloric muscle thickness of ≥ 3 mm and pyloric canal length of ≥ 17 mm.

By means of sonography, the antropyloric region of the stomach can be relatively easily located, with gallbladder as a guide-mark. This is due to the fact that the pyloric region is always immediately adjacent to the medial gallbladder wall, and as a rule it is easier to visualize a pathologically thickened than normal pylorus.

Although some earlier studies suggest the length of the pyloric canal to be the most important diagnostic criterion in sonography of HPS⁵⁻⁷, it is not always possible to visualize and to reliably measure the longest diameter of the pyloric canal due to the dorsally positioned pylorus. This is especially the case in patients with overdistended stomach, caused by dorsal rotation of the pylorus, thereby making the visualization and exact measurement of the

Correspondence to: *Goran Roić, M.D., Ph. D.*, Department of Pediatric Radiology, Zagreb Children's Hospital, Klaićeva 16, HR-10000 Zagreb, Croatia

pyloric canal in its longest diameter significantly more difficult^{1,8}. Therefore, based on our own experience, we believe that the pyloric muscle thickness, measured at longitudinal and transverse scans, represents the best diagnostic criterion (Fig. 1a,b).

Pylorospasm or antral dyskinesia may mimic HPS on radiology or sonography, but it usually occurs in older infants and children, and the clinical picture is less pronounced. Sonographically, the pyloric muscle thickness is usually between 1 and 3 mm, and the length of the pyloric canal is less than 15 mm⁸⁻¹⁰. In patients with bor-

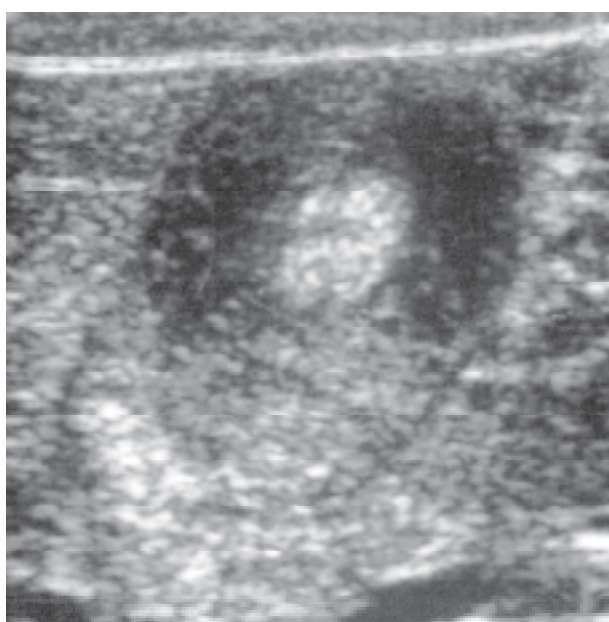
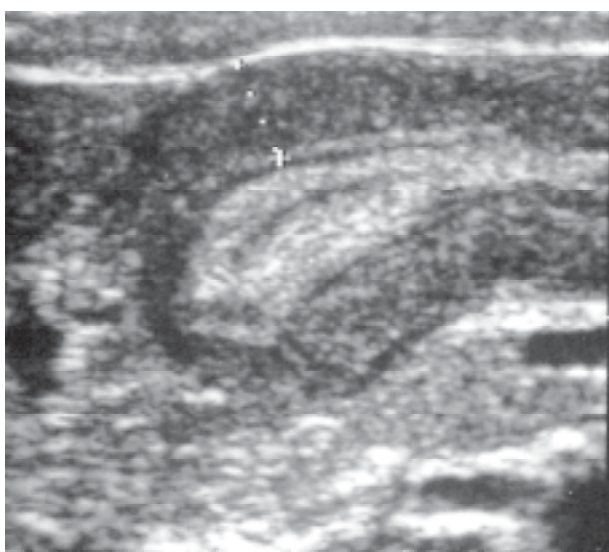


Fig. 1a, b. Hypertrophic pyloric stenosis. a) long-axis view shows abnormally thickened pyloric muscle, elongated pyloric channel; b) short-axis view shows hypoechoic thickened pyloric muscle.

derline values of muscle thickness (2.5-2.9 mm), it is necessary to evaluate other diagnostic criteria (the length of the pyloric canal), and in cases of persistent doubt, it is necessary to repeat the examination after 24-48 hours, or to perform additional radiologic assessment of the gastroduodenal tract.

The treatment for HPS is pyloromyotomy, in which the hypertrophic muscle is split longitudinally; the pyloric muscle thickness may remain abnormal for up to 12 weeks after successful pyloromyotomy¹¹.

Due to its characteristics, high-resolution sonography is the method of choice for the diagnosis of HPS, and in the hands of a skilled examiner it can almost completely replace radiologic assessment. Barium contrast studies should be performed in those patients in whom, based on clinical and history data, HPS is not the most probable cause of vomiting, and as an additional procedure in patients with borderline sonography measures.

Acute Appendicitis

One of the most common areas of the application of sonography in the gastrointestinal tract in childhood is the diagnosis and differential diagnosis of acute right lower quadrant pain in children. Due to specific anatomic and physiologic properties, the ileocecal region of the gastrointestinal tract in children represents one of the most challenging diagnostic fields, and at the same time is a very common site of pathology. Therefore, the high rate of unnecessary laparotomies (20%-30%) in cases of suspected acute appendicitis in pediatric age represents an important medical, economic and public health problem. It is the very application of sonography that enables not only an accurate diagnosis of acute appendicitis, but also a very reliable diagnosis of other diseases in the ileocecal region (lower right quadrant) that are, due to similar clinical and laboratory manifestations, a very common diagnostic problem in daily practice.

Acute appendicitis is the most common cause of urgent surgery in children. The incidence in the pediatric age group is about 4 *per* 1,000. The disease is characterized clinically by abdominal pain, nausea and vomiting, elevated body temperature, and leukocytosis. When clinical and laboratory assessment is unequivocal, further diagnostic procedures are not necessary and emergency surgery is indicated¹¹. However, in about one third of patients the presentation is atypical, mostly because of low pelvic or retrocecal localization of the appendix.

For proper evaluation of the appendix and ileocecal region, a 5-7.5 MHz linear sonographic probe is required, enabling compression of the lower right abdomen and displacement of the distended intestine. Normal intestine is filled with gas or content that is easily compressed and displaced, while acutely inflamed appendix is immobile and non-compressible.

The normal appendix is compressible, blind ending, and measures 6 mm or less in maximum diameter. It has a tubular appearance on longitudinal and a target appearance in the axial plane (Fig. 2). On longitudinal scans, acutely inflamed appendix can be seen as a tubular, blind ending structure with dilated lumen filled with hypoechoic content (Fig. 3a). Maximal sero-serosal diameter of the acutely inflamed appendix is greater than 6 mm, and

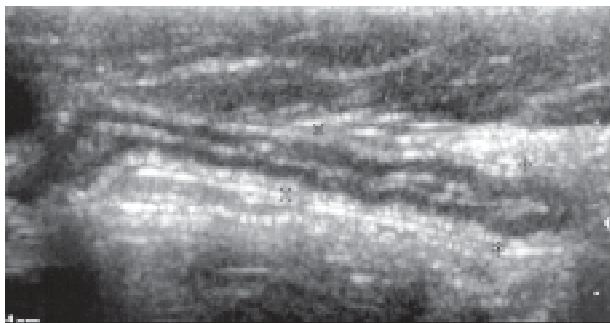
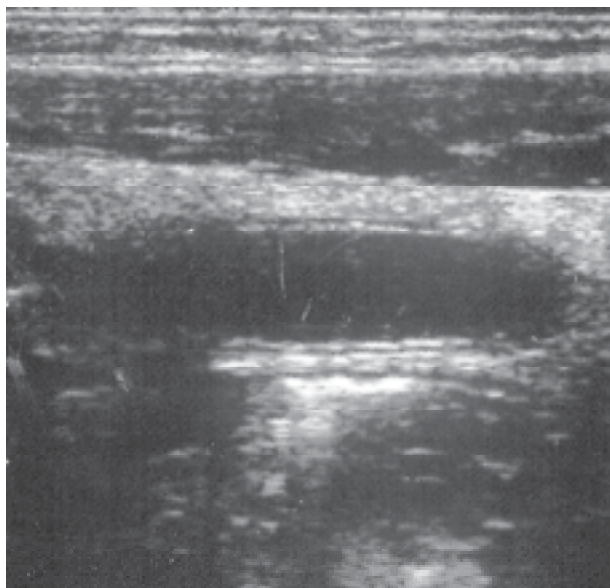


Fig. 2. Normal appendix: longitudinal scan through the right lower quadrant shows a normal-sized appendix measuring less than 6 mm in diameter. The central echogenic stripe represents the mucosa.



the wall thickness is greater than 2 mm. In the early stage of inflammation, before perforation, the internal linear echoic mucosal layer can be visualized. On transverse scans, inflamed appendix has a target-like appearance; the lumen is filled with liquid content surrounded with echoic mucosa and hypoechoic smooth muscle (Fig. 3b). Appendicolites are visualized as particularly echoic intraluminal foci with dorsal acoustic shadow (Fig. 4). Enlarged mesenteric lymph nodes measuring 7-30 mm are present in 40% of patients with acute appendicitis¹¹. Color and power Doppler of the acute, non-perforated appendix shows inflammatory hypervascularization of the wall of the appendix and adjacent tissue.

Perforation occurs in 20%-30% of children with acute appendicitis. Sonographically, it may be difficult to diagnose the perforation, since the lumen empties after perforation, reducing the total size and sero-serosal diameter of the appendix (Fig. 5). In most cases, sonography reveals the loss of echoic mucosa and the presence of loculated fluid with intensely echoic surrounding fat tissue. The most common complications of perforation are peritonitis and intraperitoneal abscesses. These abscesses are mostly localized in the lower right quadrant or pelvis, but can be found in other parts of the abdomen, including upper abdomen. Peritonitis manifests with ileus and intestinal dilatation accompanied by ascites. Color and power Doppler analysis shows inflammatory hypervascularization of the intestinal wall and adjacent soft tissue.

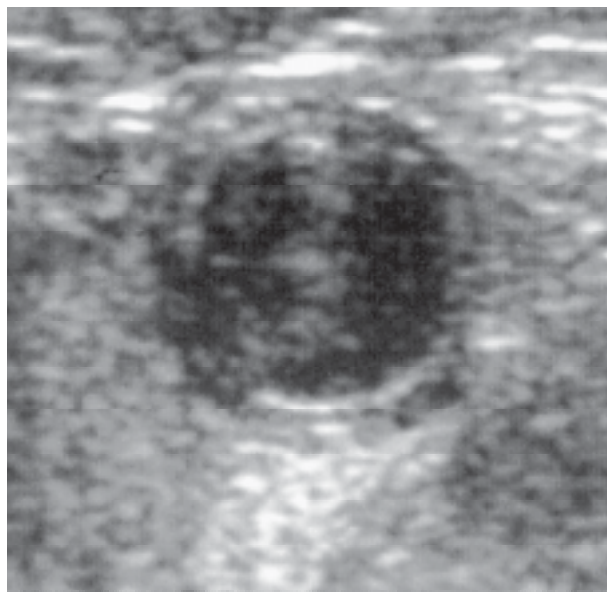


Fig. 3a, b. Acute appendicitis a) longitudinal scan through the dilated fluid-filled appendix; sero-serosal diameter is 8 mm; b) on transverse scan acute appendicitis has a "target-like" appearance.

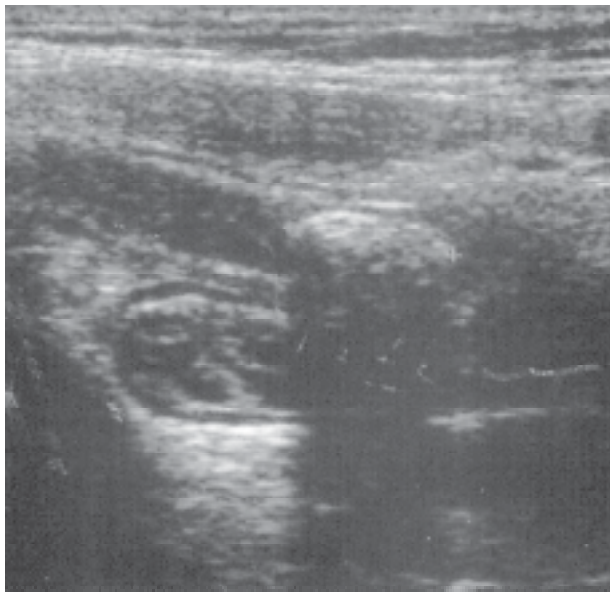


Fig. 4. Acute appendicitis: longitudinal sonogram shows a dilated fluid-filled appendix with an echogenic appendicolith.

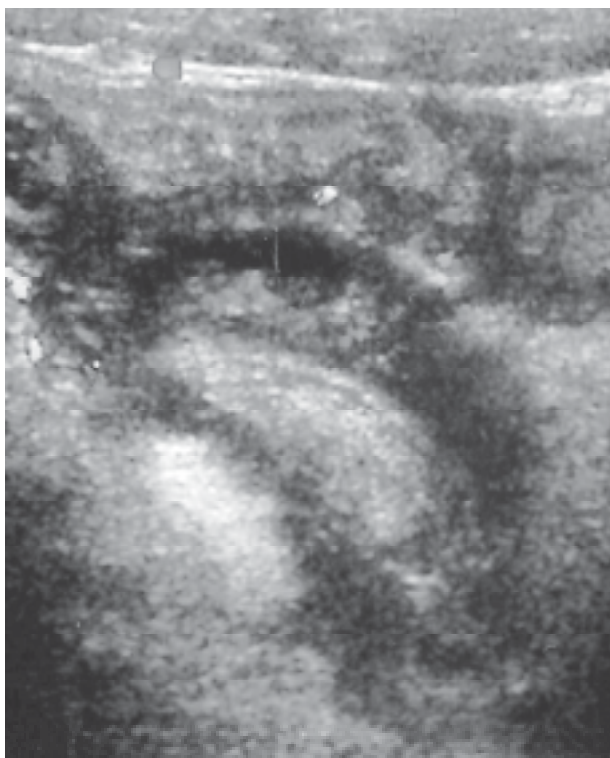


Fig. 5. Perforated appendicitis: longitudinal scan through the perforated appendix with neighboring hypoechoic collection; color-flow Doppler shows inflammatory hypervascularization of the periappendicular tissue.

If appendicitis is excluded by sonography, it is always necessary to analyze the pelvis and upper abdomen. One large series showed that the diagnosis of acute appendicitis was confirmed in only 21%–29% of children referred to sonography for equivocal acute appendicitis, whereas in others the cause of pain was a gynecologic disease, gastrointestinal tract anomaly, or renal disease^{12,13}.

Fluid collections in the pelvis or abdomen can be visualized after appendectomy. These can be found in 5%–23% of patients in the early postoperative period, most of which gradually resolve on conservative treatment^{14,15}. In case of intraperitoneal abscess formation, ultrasound-guided puncture and drainage are indicated.

Mesenterial Adenitis

Mesenterial adenitis is one of the most common causes of abdominal pain in children¹. Sonography can show normal lymph nodes as round or discoid nodes, 5–7 mm in diameter (Fig. 6). Mesenteric lymph nodes are most frequent in the ileocecal region, at the right border of psoas muscle and at the umbilical level, which is where they are most easily visualized by sonography.

During graded compression of the lower right abdomen, in order to displace the distended and filled intestine, mesenterial adenitis is seen as the enlargement of mesenteric lymph nodes, being round and hypoechoic (Fig. 7). Color Doppler flow can show inflammatory

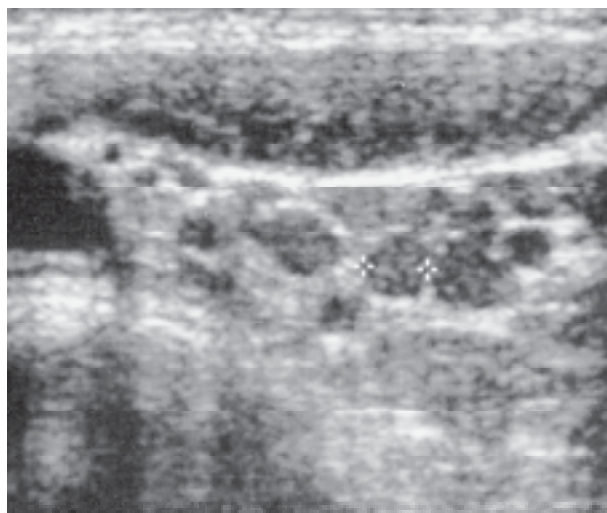


Fig. 6. Normal mesenteric lymph nodes: multiple nodes measuring 5–7 mm in diameter on transverse scan through the lower right abdomen.

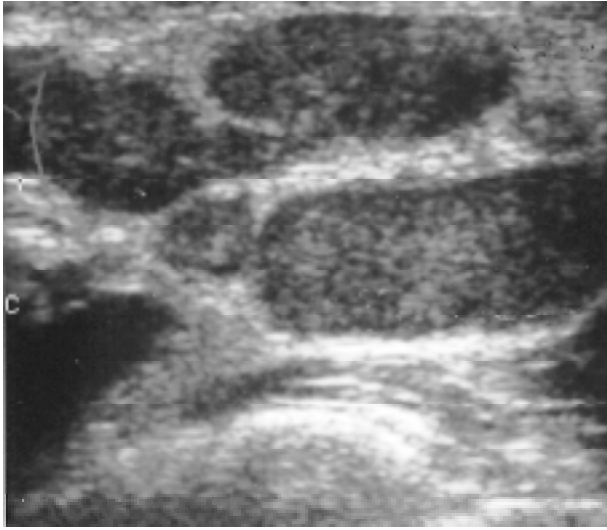


Fig. 7. Mesenteric adenitis: multiple enlarged hypoechoic mesenteric lymph nodes on transverse image of the right lower quadrant.

hypervascularization of the adjacent tissue, and power Doppler can show vascularization within the inflamed lymph node (Fig. 8). Since mesenteric adenitis with enlarged mesenteric lymph nodes is also present as a rule in cases of acute appendicitis, visualization of the appendix and exclusion of appendicitis are obligatory in these patients¹².

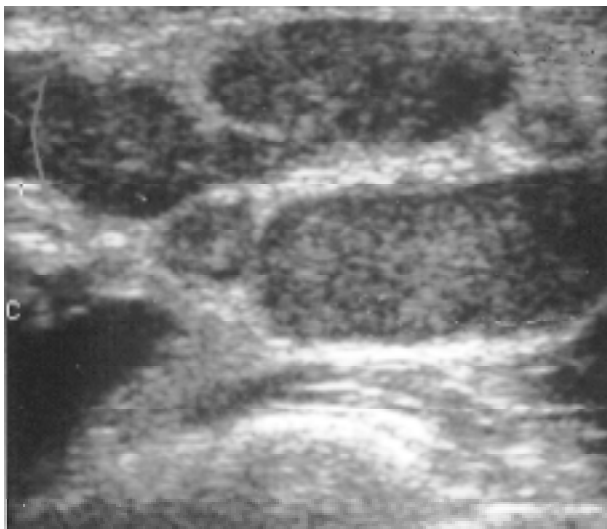


Fig. 8. Mesenteric adenitis: enlarged hypoechoic mesenteric lymph node; power Doppler shows inflammatory hypervascularization within the lymph node.

Acute Terminal Ileitis

Yersinia enterocolitica, *Campylobacter* and *Salmonella* are the most common causes of acute inflammation that specifically localizes to the ileocecal part of the intestine. In these cases, the dominant symptom is pain in the lower right quadrant, while the diarrhea is often mild or absent¹⁶.

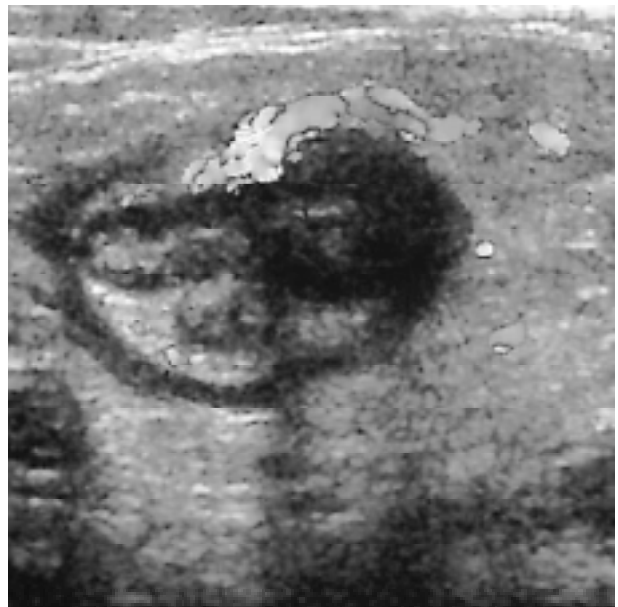
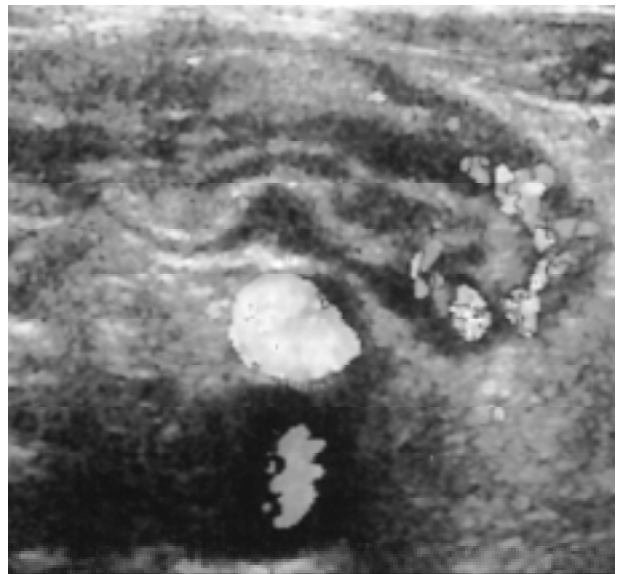
Fig. 9a, b. Acute terminal ileitis: a) longitudinal, and b) transverse scan through the terminal ileum shows the symmetrically thickened, hypoechoic intestinal wall; color-flow Doppler shows inflammatory hypervascularization of the intestinal wall and adjacent mesentery.

Such symptomatology often leads to unnecessary laparotomy because of the clinical resemblance with acute appendicitis. On surgery, normal appendix is removed, and the edematous wall of terminal ileum, ileocecal valve or cecum are often found, along with enlargement of the regional lymph nodes. Sonography provides quick and reliable diagnosis of the inflammatory diseases of the ileocecal region in children and differential diagnosis from acute appendicitis, thereby preventing unnecessary appendectomies¹⁷.

Sonographic findings in inflammatory diseases of the ileocecal region include hypoechoic and symmetrically thickened wall of the terminal ileum, ileocecal valve and cecum, with narrowed lumen and retarded peristalsis of the inflamed segment of the ileum^{18,19}. The changes in the terminal ileum are most evident during intestinal contraction when mucosal reflection has the "cobblestone" appearance¹⁶. Wall thickening is confined to the mucosa and submucosa, without involvement of the muscular layer, serosa and adjacent fat tissue. As a rule, reactively enlarged and inflamed mesenteric lymph nodes can be found in the ileocecal region, at the right border of psoas muscle and at the umbilical level. Tuberculosis, histoplasmosis, and some viruses and fungi can also cause acute terminal ileitis or ileocectitis with similar clinical and sonographic findings. Color and power Doppler analysis shows increased vascularity within the mucosa and submucosa of the inflamed ileal segment as well as inflammatory hypervascularization of the adjacent mesentery and surrounding omentum²¹ (Fig. 9).

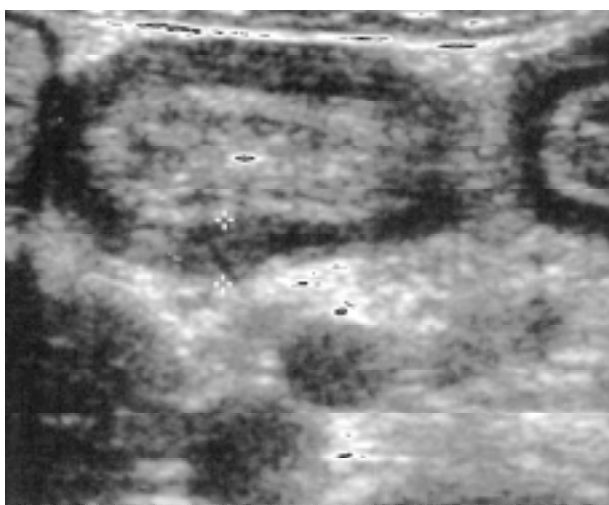

Fig. 10. Henoch-Schönlein purpura: transverse scan of the ileum shows hypoechoic thickened small bowel wall.

Henoch-Schönlein Purpura

Henoch-Schönlein purpura is a vasculitis characterized by nonthrombocytopenic purpura, arthritis, abdominal pain, and nephritis. The gastrointestinal tract is a common site of involvement, and the bowel is affected in about half of children with Henoch-Schönlein purpura²¹. In some patients, bowel involvement may precede the onset of skin lesion and mimic acute appendicitis.

Sonographic findings include diffuse circumferential bowel wall thickening, ranging between 5 and 8 mm in diameter (Fig. 10). Intramural hematomas appear as fo-

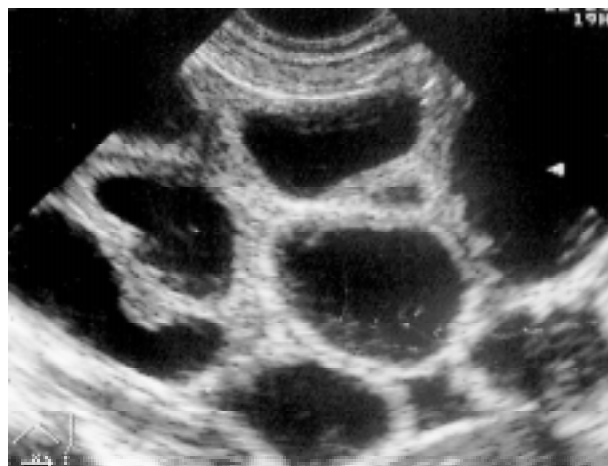

Fig. 11. Small bowel (ileal) atresia: transverse scan of the lower abdomen shows dilated fluid-filled small bowel loops. Ileal atresia was found at operation.

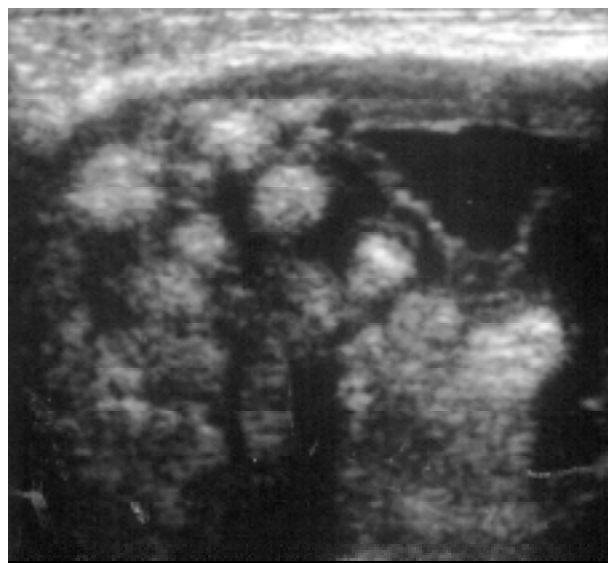


Fig. 12. Meconium ileus: transverse scan of the lower abdomen shows multiple bowel loops containing echogenic thick meconium.

cal areas of wall thickening. These hematomas can be multifocal and complicated by intussusception. Color Doppler sonography through the affected bowel shows hypervascularity in the bowel wall.

Jejunal and Ileal Atresia or Stenosis

Jejunum and ileum are the most common sites of atresia or stenosis in the small bowel. Atresia is more common than stenosis. Patients with jejunal or ileal atresia present in the neonatal period with bilious vomiting, abdominal distension, or failure to pass meconium²¹. About 25% of patients have an associated abnormality, including midgut malrotation, gastroschisis, duodenal atresia, or tracheoesophageal fistula²¹. In older children, acquired disorders, such as incarcerated hernia, intussusception and acute appendicitis, are more common causes of bowel obstruction.

Sonography is not usually needed for the diagnosis of uncomplicated congenital bowel obstruction, unless the clinical findings are atypical. The sonographic appearance of small bowel obstruction is that of multiple dilated fluid-filled bowel loops with active peristalsis (Fig. 11). Bowel wall thickening and ascites may also be observed.

Meconium Ileus

Meconium ileus results from inspissation of abnormally thick and tenacious meconium in the distal small bowel. It is almost always a manifestation of cystic fibrosis; about 10% to 20% of patients with cystic fibrosis present with meconium ileus²¹.

The sonographic findings of meconium ileus include echogenic bowel contents and dilated bowel loops (Fig. 12).

Meconium peritonitis is the result of antenatal perforation of the bowel and extrusion of sterile meconium, which produces a nonbacterial chemical peritonitis. It may be seen as a complication of bowel atresias, meconium ileus, and *in utero* volvulus. Up to half of all cases of meconium ileus are complicated by meconium peritonitis²¹. In meconium peritonitis, intense foci of echogenicity with varying degrees of acoustic shadowing or a pattern of diffuse peritoneal echogenicity may be seen on sonography. Echogenic ascites may also be found.

Intussusception

Intussusception occurs when a segment of the intestine (intussusceptum) protrudes into the aboral intestinal segment (intussusciens). It most frequently occurs in children between 3 months and 2 years of age²²⁻²⁵. Classical clinical symptoms include sudden abdominal pain followed by mucinous and bloody stools, and palpable abdominal mass. In about 90% of cases, the invagination is localized in the ileocecal region, and others are ileocolic, colocolic and ileoanal. In over 90% of intussusceptions there is no leading mass, and it is believed that in these cases the thickening of the lymphatic follicles in the terminal ileum is the main etiologic factor, resulting in the disturbance of peristalsis and subsequent invagination. In other cases, the leading mass can be found, which is most frequently Meckel's diverticulum, polyp, duplication and rarely lymphoma or intestinal wall hematoma²⁶. Traditional diagnostic means for intussusception are barium, water or air enema under x-ray control, followed by the attempt of hydrostatic reduction, also under x-ray control. Intussusception in children can be reliably diagnosed with ultrasound, given its characteristic sonographic appearance. Sonography is most commonly used as the method of choice for intussusception, although ultrasound-guided hydrostatic reduction is more frequently used²⁷.

Sonographic findings in intussusception are very characteristic, especially on transverse scans through the intestine at the level of invagination^{26,28,29}. Most commonly it appears as a round or oval mass with hypoechoic outer layer (edematous intestinal wall) around the echoic center (invaginated bowel) (Fig. 13). The number of rings depends on the degree of edema, and in cases with pronounced edema only two layers can be visualized, i.e. the outer hypoechoic intussusciens and inner hyperechoic intussusceptum. On longitudinal scans, intussusception has a "sandwich" or kidney-like appearance ("pseudo-kidney" sign). The presence of free intraperitoneal fluid is probably related to the duration of intussusception, and is absent in its short history³⁰. Rarely, temporary invaginations of the intestinal loops can be seen on sonography; only a few centimeters of the intestine invaginates and vascularization of the intestinal wall is not compromised; after a few minutes, spontaneous disinvagination occurs.

Sonography can be used as a valuable screening method for invagination in childhood. Although contrast enema in most institutions still has the primary role in the diagnosis and therapy of invagination in children, the future definitely belongs to sonography, and sonography

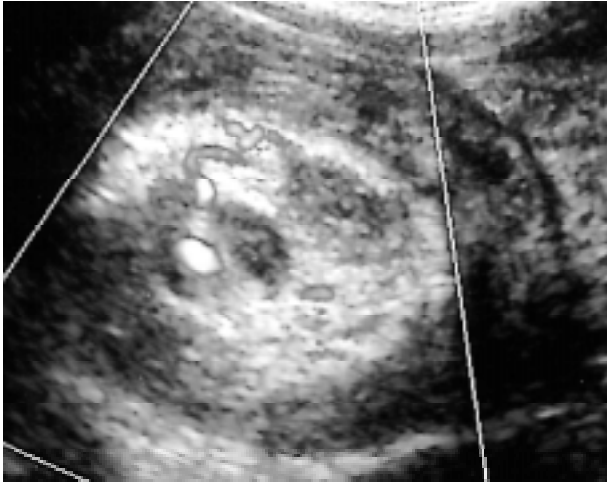


Fig. 13. Intussusception: transverse scan at the level of ascending colon shows a mass formed of echogenic center and outer hypoechoic layer ("doughnut sign") – ileocolic intussusception.

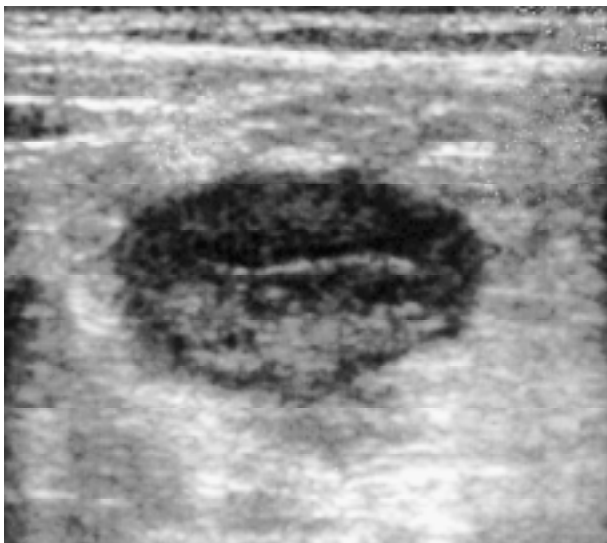
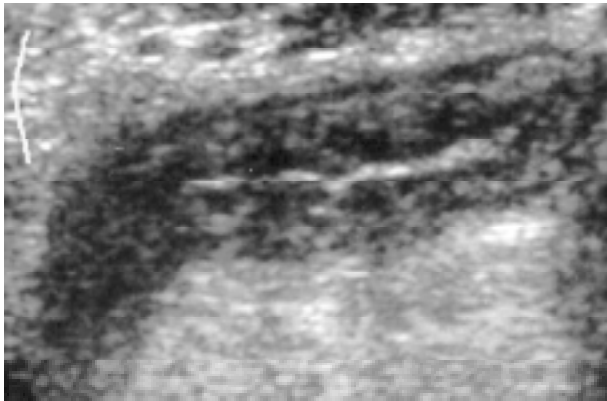


Fig. 14a, b. Crohn's disease: a) longitudinal, and b) transverse scan through the terminal ileum shows symmetrically thickened and hypoechoic intestinal wall; hyperechoic adjacent fat tissue.

will take the central role in both the diagnosis and conservative therapy of intussusception^{21,27}.

Crohn's Disease

Crohn's disease or regional enteritis is a transmural inflammatory disease that can involve any part of the digestive tract, from mouth to anus. The etiology of this disease is not known; there are hypotheses that the disease is caused by an unknown agent, or that it represents an autoimmune process of non-clarified pathogenesis³¹. Up to 10% of patients with Crohn's disease have positive family history for inflammatory bowel disease. The disease is most common between 20 and 40 years of age, but it may occur throughout childhood, especially during the first years of the second decade of life. In most cases, the process involves terminal ileum. In children, small intestine can also be involved without any changes in the ileum, or only colon may be affected. The involvement of the esophagus, stomach and duodenum is uncommon, especially in childhood¹⁸. The manifestation of the disease may be diverse; although gastrointestinal symptoms may be mild or moderate, it most commonly manifests with abdominal pain with diarrhea. Weight loss, growth retardation, delayed puberty, or fever of unknown origin may be the only symptoms of the disease. Extraintestinal manifestations such as arthritis and sclerosing cholangitis are less common in children than in adults. Crohn's disease may also present as an acute ab-

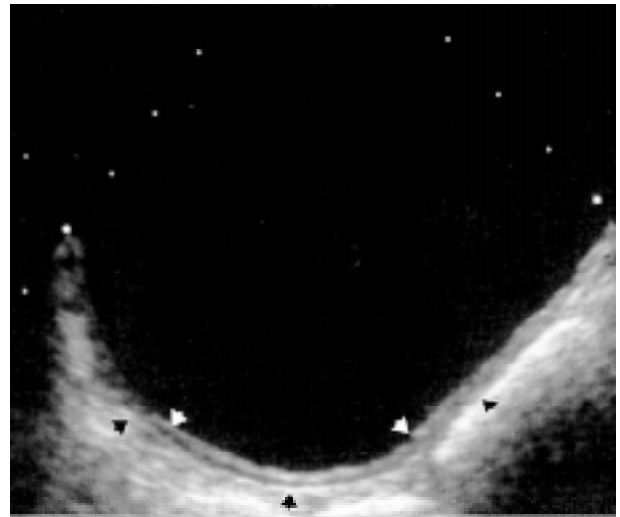


Fig. 15. Enteric duplication cyst: transverse scan through the lower abdomen shows an anechoic mass with an echogenic inner lining of the mucosa (white arrows) and hypoechoic rim of the smooth muscle (black arrows).

dominal condition mimicking appendicitis or a severe form of infectious ileocectitis³².

On sonography, Crohn's disease manifests with symmetric hypoechoic thickening of the intestinal wall, with central echoic area representing the mucosa and intraluminal gas³³ (Fig. 14a,b). The wall thickness usually ranges between 5 and 14 mm^{21,33}. As opposed to acute terminal ileitis, the whole thickness of the intestinal wall is affected, with spread to the adjacent fat tissue. Peristalsis is present, but often slowed. Hypoechoic and heterogeneous collections (abscesses) are often found, along with the enlargement of mesenteric lymph nodes. Color Doppler analysis shows increased flow in the mucosa and submucosa of the involved intestinal loop.

Enteric Duplication Cyst

Enteric duplication cysts are congenital anomalies characterized by duplication of the normal bowel wall; they may occur anywhere along the gastrointestinal tract and are usually directly attached to the bowel. They are most common in the ileum. The cyst wall contains all normal bowel layers including mucosa, submucosa and muscularis. Clinical signs and symptoms include abdominal distension and pain, palpable abdominal mass, vomiting, and rectal bleeding.

On sonography, duplication cysts are well defined spherical or tubular fluid-filled anechoic masses with through-transmission of sound. A combination of an echogenic inner lining of the mucosa and a hypoechoic rim of the smooth muscle is thought to be specific for duplication (Fig. 15). The presence of these two layers is useful to exclude other cystic masses such as mesenteric, omental, choledochal or ovarian cysts, which lack the mucosal lining²¹.

References

1. SIEGEL MJ. Gastrointestinal tract. In: Siegel MJ, ed. Pediatric sonography. New York: Raven Press, 1985:266-8.
2. GRAIF M, ITZCHAK Y, AVIGAD I, STRAUSS S, BEN-AMI T. The pylorus in infancy: overall sonographic assessment. *Pediatr Radiol* 1984;14-7.
3. HALLER JO, COHEN HL. Hypertrophic pyloric stenosis: diagnosis using US. *Radiology* 1986;161:335-9.
4. KELLER HWALDMANN D, GREINER P. Comparison of preoperative sonography with intraoperative findings in congenital hypertrophic stenosis. *J Pediatr Surg* 1987;22:950-2.
5. BLUMHAGEN JD. The role of ultrasonography in the evaluation of vomiting in infants. *Pediatr Radiol* 1986;16:267-70.
6. BLUMHAGEN JD, WEINBERGER E. Pediatric gastrointestinal ultrasonography. In: *Ultrasound annual*. New York: Raven Press, 1986:99-140.
7. STUNDEN RJ, LE QUESNE GW, LITTLE KE. The improved ultrasound diagnosis of hypertrophic pyloric stenosis. *Pediatr Radiol* 1986;16:200-5.
8. SAWISCHUK LE, HAYDEN CK Jr, STANSBERRY SD. Sonographic pitfalls in imaging of the antropyloric region in infants. *Radiographics* 1989;9:437-47.
9. O'KEEFFE FN, STANSBERRY SD, SWISCHUK LE, HAYDEN CK Jr. Antropyloric muscle thickness at US in infants: what is normal? *Radiology* 1991;178:827-30.
10. ELAM EA, HUNTER TB, HUNT KR, FAJARDO L, BOREN W, GAINES J. The lack of sonographic image degradation after barium upper gastrointestinal examination. *AJR Am J Radiol* 1989;153:993-4.
11. OKORIE NM, DICKSON JAS, CARVER RA, *et al.* What happens to the pylorus after pyloromyotomy? *Arch Dis Child* 1988;63:1339-40.
12. PUYLAERT JBCM. Acute appendicitis: US evaluation using graded compression. *Radiology* 1986;158:355-60.
13. AVELINE B, GUIMARAES R, BELY N, SALLES JP, CUGNENC PH, FRIJA G. Intraabdominal serous fluid collections after appendectomy: a normal sonographic finding. *AJR Am J Radiol* 1993;161:71-3.
14. SIEGEL MJ, CAREL C, SURRETT S. Ultrasonography of acute abdominal pain in children. *JAMA* 1991;266:1987-9.
15. SIVIT CJ, NEWMAN KD, BOENNING DA, *et al.* Appendicitis. usefulness of US in diagnosis in a pediatric population. *Radiology* 1992;185:549-52.
16. BAKER DE, SILVER TM, CORAN AG, MC MILLIN KI. Postappendectomy fluid collections in children: incidence, nature and evolution evaluated using US. *Radiology* 1986;161:341-4.
17. PUYLAERT JBCM, VAN DER ZANT FM, MUTSAERS JAEM. Infectious ileocectitis caused by *Yersinia*, *Campylobacter*, and *Salmonella*: clinical, radiological and US findings. *Eur Radiol* 1997;7:3-9.
18. SIEGEL MJ, FRIEDLAND JA, HILDEBOLT CF. Bowel wall thickening in children: differentiation with US. *Radiology* 1997;203:631-5.
19. PUYLAERT JBCM, VERMEIJDEN RJ, VAN DER WERF SDJ, DOORNBOS L, KOUMANS RKJ. Incidence and sonographic diagnosis of bacterial ileocectitis masquerading as appendicitis. *Lancet* 1989;ii:84-6.
20. PUYLAERT JBCM, LALISANG RI, VAN DER WERF SDJ, DOORNBOS L. *Campylobacter* ileocolitis mimicking acute appendicitis: differentiation with graded-compression US. *Radiology* 1988;166:737-40.
21. SIEGEL MJ. Gastrointestinal tract. In: Siegel MJ, ed. Pediatric sonography. Philadelphia: Lippincott Williams & Wilkins, 2002:362.
22. WEST KW, STEPHENS B, VANE DW, GROSFELD JL. Intussusception: current management in infants and children. *Surgery* 1987;102:704-10.
23. BISSET GS, KIRKS DR. Intussusception in infants and children: diagnosis and therapy. *Radiology* 1988;168:141-5.
24. MORRISON SC, STORK E. Documentation of spontaneous reduction of childhood intussusception by ultrasound. *Pediatr Radiol* 1990;20:358-9.

25. BHISIKTUL DM, LISTERNICK R, SHKOLNIK A, DONALDSON JS, HENRICKS BD, FEINSTEIN KA, FERNBACH SK. Clinical application of ultrasonography in the diagnosis of intussusception. *J Pediatr* 1992;121:182-6.
26. EIN SH. Leading points in childhood intussusception. *J Pediatr Surg* 1976;11:209-11.
27. WOOD SK, KIM JS, SUH SJ, PAK T, CHOI SO. Childhood intussusception: US-guided hydrostatic reduction. *Radiology* 1992;182:77-80.
28. SWISCHUK LE, HAYDEN CK, BOULDEN T. Intussusception: indications for ultrasonography and an explanation of the doughnut and pseudokidney signs. *Pediatr Radiol* 1985;15:388-91.
29. BOWERMAN RA, SILVER TM, JAFFE MH. Real-time ultrasound diagnosis of intussusception in children. *Radiology* 1982;143:527-9.
30. PATRIQUIN HB, AFSHANI E, EFFMAN E, *et al.* Neonatal intussusception: a report of 12 cases. *Radiology* 1977;125:463-6.
31. KIRKS DJ. Gastrointestinal tract. In: Kirks DJ, ed. *Practical Pediatric Imaging*. Lippincott-Raven, 1998;937-40.
32. AGHA FP, GHAHREMANI GG, PANELLA JS, KAUFMAN MW. Appendicitis as the initial manifestation of Crohn's disease: radiologic features and prognosis. *AJR Am J Radiol* 1987;149:515-8.
33. DINKEL E, DITTRICH M, PETERS H, BAUMANN W. Real-time ultrasound in Crohn's disease. *Pediatr Radiol* 1986;16:8-12.

Sažetak

ULTRAZVUK PROBAVNOGA SUSTAVA U PEDIJATRIJI: REVIJALNI RAD

G. Roić, M. Kopljar, N. Ljubičić, M. Zovak, Z. Bahtijarević, V. Posarić, D. Gogolja, S. Višnjic i I. Fattorini

Ultrazvučna dijagnostika sve se više rabi u dijagnostici probavnoga trakta u dječjoj dobi. Ultrazvuk visoke razlučivosti, tehnika dozirane kompresije, uz obojeni i *power* dopler, neinvazivna je i pouzdana dijagnostička metoda. Pretraga je tehnički jednostavna za izvođenje, te se najčešće izvodi pri evaluaciji akutne abdominalne boli, upalnih bolesti probavnoga trakta i urođenih anomalija. U radu je prikazan današnji doseg ultrazvuka u dijagnostici i terapiji bolesti probavnog trakta u dječjoj dobi.