

NEUROLOGIC MANIFESTATIONS IN ADULT CELIAC DISEASE: CASE REPORT

Jagoda Stipić¹, Zdravko Perković², Vesna Crnek-Kunstelj³, Maja Relja¹, Asija Stipić-Marković⁴ and Franjo Škreb⁵

¹Department of Neurology, ²Department of Endocrinology, Zagreb University Hospital Center; ³Department of Biology, Zagreb University School of Medicine; ⁴Department of Immunology and Pulmonology, Sveti Duh General Hospital; ⁵Department of Nuclear Medicine, Dubrava University Hospital, Zagreb, Croatia

SUMMARY – Celiac disease is more common than previously thought, and a high index of suspicion is important in its diagnosis. Typically, cases of celiac disease present at the age of 5-24 months with the symptoms of intestinal malabsorption, growth retardation, abnormal stools, abdominal distension, muscle wasting, hypotonia, poor appetite and low spirit. In adults, the symptoms of celiac disease may be highly varied. The incidence of malignancies is also increased. Most of these are small bowel lymphomas and carcinomas of the esophagus and colon. In some patients, the disease is associated with clinical dysfunction of the nervous system, manifesting variably as encephalopathy, cerebellar abnormalities, seizures, cerebral atrophy and dementia, brain stem encephalitis, cerebral vasculitis, myopathy, quadriplegia (metabolic), myelopathy, peripheral neuropathy, multifocal leukoencephalopathy, and psychiatric disorders. Presentation is made of a 47-year-old woman with misdiagnosed celiac disease, who first developed pain in the back which was treated with spinal support. She also complained of very severe bone pains. Finally, she was admitted to the hospital with a history of increasing difficulty on walking, weakness in her legs, urine incontinence, and 5-kg weight loss in four months. Celiac disease should therefore be considered on differential diagnosis in patients presenting with unexplained neurologic symptoms.

Key words: *Celiac disease, complications; Nervous system diseases, complications; Celiac disease, diagnosis; Case report; Adult*

Introduction

Celiac disease (CD) is more prevalent than previously believed and is frequently underdiagnosed, particularly in adults who may present with subtle symptoms. The variable clinical presentation in CD reflects the diverse pathologic expression of this multisystem disorder. Neurologic complications occur in about 10% of CD patients¹.

We describe a female patient without any specific symptoms of CD such as diarrhea with bulky, offensive stools,

abdominal pain and bloating, flatulence, and even constipation. The disorder manifested with neurologic symptoms, severe pain in the back and bones, paraparesis, urine incontinence, fatigue, headache, and depression. At first we thought the symptoms to be caused by a malignant disease.

Case Report

A 47-year-old woman, completely healthy until two years before, had since been experiencing severe pain in the back, then in both legs. Physical therapy had resulted in only transient improvement. Radiographic vertebral scan and EMNG revealed no pathologic alterations. For about one year, the pain increased in frequency and severity, radiating to both legs, the patient walked with difficulty, es-

Correspondence to: *Jagoda Stipić, M.D.*, Department of Neurology, Zagreb University Hospital Center, Kišpatičeva 12, HR-10000 Zagreb, Croatia

Received November 30, 2001, accepted in revised form February 25, 2002

pecially upstairs. Additional physical therapy failed to produce any improvement. One month before hospitalization, the patient could not walk without help and suffered urine incontinence. Over the preceding four months, she unintentionally lost approximately 5 kg in weight. For all these symptoms, she was admitted to the Department of Neurology, Zagreb University Hospital Center.

The patient was 162 cm tall, her body weight was 48 kg and body mass index (BMI) 18 kg/m², which is below the normal values. Her skin and mucosa were normal, she was well hydrated, with no signs of bleeding. Arterial pressure was 120/70 mm Hg and pulse 80/min. She had pedal edema with normal peripheral arterial pulsations. Neurologic examination revealed flaccid paraparesis with weaker tendon reflexes, flexor plantar responses, and urine incontinence. There was no loss of pain, touch or thermal sensation.

Laboratory tests showed mild normocytic anemia (E 3.89, Hb 118, He 0.35, MCV 91), low total serum protein (48 g/L), albumin (26.4 g/L) and gamma-globulin (7.9 g/L). The level of calcium was 2.11 mmol/L, calcium in 24-hour urine 1.62 mmol/L, and phosphorus 0.67 mmol/L; serum prothrombin activity, magnesium, ionic calcium and APTV were normal; alkaline phosphatase was 355 U/L. Dynamic changes of total alkaline phosphatase in peripheral blood during hospital treatment are shown in Fig. 1.

The patient had positive serum HLA-B8 and HLA-DR3 histocompatibility antigens. EMNG showed a minor L5 radix lesion bilaterally. Computed tomography (CT) showed lesions in the brain white matter. Radiologic stud-

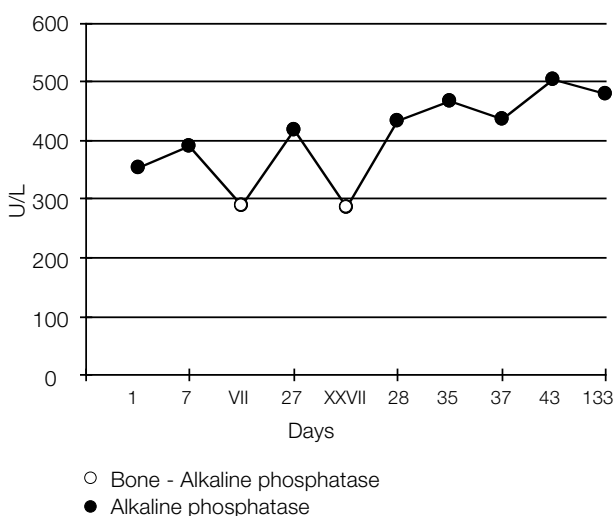


Fig. 1. Changes in peripheral blood alkaline phosphatase.

ies of the vertebral spine, pelvis and both femurs revealed signs of osteomalacia. Also, the patient had an abnormally low BMD. Hypoproteinemia, elevated values of alkaline phosphatase, radiographic scans, and low BMD indicated osteomalacia, which in turn strongly pointed to the diagnosis of protein and vitamin D malabsorption.

Later, laboratory findings showed low folic acid of 4 (normal 7-28) nmol/L, 25-hydroxyvitamin D of 1.5 (normal 22-190) nmol/L, normal B12 value, and increased PTH of 16.8 (normal 1-6) pmol/L.

Positive antiendomysium IgA antibodies were recorded, and small intestine biopsy was indicated, which revealed villous atrophy. Characteristic changes included flattening or loss of villi, hyperplasia of mucosal crypts, and increased intraepithelial lymphocyte count. Small intestinal mucosa showed total atrophy of intestinal epithelium with moderate to abundant lymphocytic infiltrates in lamina propria (Fig. 2).

Based on these findings, gluten enteropathy with malabsorption of protein, vitamins D and K, and folic acid, with consequential hyperparathyroidism and osteomalacia were diagnosed. Therapy with a non-gluten diet and oral substitution of folic acid, active vitamin D (0.75 mg/day), vitamin K by infusion, calcium and phosphates in dairy products and tablets was initiated. With this therapy, leg edema disappeared. Serum calcium, phosphorus and prothrombin complex normalized, and body weight increased by 3 kg. Bone pain diminished and muscle strength increased. After 3 months of gluten-free diet, weight gain of 12 kg was recorded, along with normalization of all hematology and clinical chemistry findings, and 24-urine calcium decrease (1.6 mmol/d/U). The patient was now able to walk independently, and felt some pain

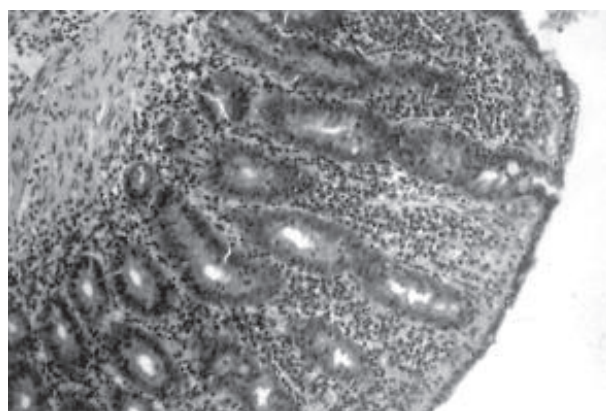


Fig. 2. In our patient, small intestinal mucosa showed total atrophy of intestinal epithelium, with moderate to abundant lymphocytic infiltrations in lamina propria.

in her bones and back only on climbing upstairs. Now she had urination control again, and generally felt much better, free from episodes of depression.

Discussion

Celiac disease results from an abnormal immune response to gliadin, a component of dietary gluten, found in wheat, barley, rye and possibly oats. This response causes villous atrophy of small intestinal mucosa, which in turn leads to malabsorption and predisposes to gastrointestinal malignancy, especially carcinoma of the oropharynx and esophagus, and small bowel lymphoma². Gluten sensitive enteropathy straddles the realms of food hypersensitivity and autoimmunity, and the way in which these two processes are able to combine to produce small intestine mucosal damage has been an area of much controversy. However, with recent advances in the study of CD, especially identification of the antigenic target transglutaminase, a model of celiac pathogenesis has become possible to design.

An initial mucosal damage, possibly due to intestinal infection or even toxic effect of gliadin, upregulates tissue transglutaminase (tTG). This enzyme causes cross-linking of various proteins, including gliadin. This tTG gliadin complex represents a 'new antigen' (neoantigen), which could then trigger the production of anti-tTG antibodies. Gliadin specific CD4+ T-helper cells (which exist in small bowel mucosa of CD patients) provide help for the production of anti-tTG antibodies by tTG specific B cells. Transglutaminase plays a role in maintaining the integrity of both intestinal crypt microarchitecture and dermoepidermal junction, so the development of villous atrophy and dermatitis herpetiformis lesions could be explained by this final common pathway^{3,4}.

An immunologic mechanism involving both small bowel and brain tissue has been suggested as a possible cause⁵. It has also been postulated that adults with CD may be at a risk of superimposed neurologic disease of the central nervous system due to the permanent or intermittent state of immunodeficiency⁶.

There may be a genetic role as there is an increased incidence of HLA-B8 and HLA-DR3 in CD patients⁷. Also, there is the possibility of a viral role based on the homology of 12-amino acid sequence, human type 12 adenovirus E1b protein in alpha-gliadin fraction. Although the mechanism is not known, a damage is known to occur.

IgA antibodies to gliadin, endomysium and/or tTG are detectable in most untreated patients. Antibody test-

ing should not be used to make the diagnosis because of the possibility of false positive results. A definite diagnosis in both adults and children is based on the finding of villous atrophy in the small intestinal mucosa biopsy specimen. Serologic testing can help in the diagnosis of CD. Two tests are most commonly used: antigliadin antibody (AGA) test and endomysial antibody (EMA) test. These are IgA antibodies. Testing for IgG antibodies is of little diagnostic value, since the sensitivity and specificity are only about 50%. More specific tests for tTG antibodies have also been developed and are likely to replace other tests when they become more widely available⁸.

CD may occur at any age, even after the age of 70, although in adults it usually occurs between the age of 20 and 60. In adults and adolescents, presentation with classical symptoms of diarrhea, weight loss and malnutrition, or bone pain has become much less common. Mild and subclinical forms are frequent, occurring in more than 50% of patients. Atypical presentation may involve an otherwise unexplained hematologic abnormality (iron deficiency with or without anemia, folate deficiency, macrocytosis), constitutional symptoms, or fatigue with minimal weight loss and no intestinal symptoms, or mild abdominal or digestive complaints⁹.

Pedal edema and bruising can occur as a result of protein and vitamin K malabsorption. The metabolic role of vitamin K is to facilitate carboxylation of glutamyl to γ -carboxyglutamyl residues. Besides hepatic tissue, in which the clotting factors are produced, γ -carboxyglutamyl-containing proteins are also abundantly available in bone tissue. Osteocalcin accounts for up to 80% of total γ -carboxyglutamyl content of a mature bone. Human carboxylated osteocalcin contains three γ -carboxyglutamyl residues, which confer a highly specific affinity to the calcium ion of the hydroxyapatite molecule. Besides the γ -carboxylation of osteocalcin, vitamin K may also affect either the parameters of bone metabolism such as calcium hemostasis, or prostaglandin E2 and interleukin-6 production. Evidence from observational studies and first intervention trials indicate that the vitamin K intake is much higher than the current recommendations for improved biochemical markers of bone formation and bone density¹⁰.

The most common cause of severe bone pain in untreated CD is osteomalacia, i.e. malformation of the bone due to the lack of vitamin D and calcium. It affects mostly the hips, and sometimes shoulders and back. It usually improves with specific treatment, which includes gas-

trointestinal diet for CD patients, vitamin D supplementation and other interventions.

Another cause of bone pain is osteoporosis. It can often cause pain in the back, due to vertebral shortening, thus squeezing the nerves. It is a very painful condition without any possibility to improve; once the vertebrae have shortened, they cannot be stretched again to their original size. Muscle pain can also occur because of vitamin D deficiency.

CD may be associated with various neurologic manifestations. The most common conditions are polyneuropathy and spinocerebellar ataxia. Other conditions include motor neuron disease, myelopathy, epilepsy and encephalopathy. Neurologic manifestations may precede gastrointestinal symptoms¹¹. This disorder affects predominantly the cerebellum, deep gray masses, brain-stem nuclei, and spinal cord. Its cause and pathogenesis are unknown⁷. Peripheral neuropathies of axonal and demyelinating types have also been reported and may respond to the elimination of gluten from the diet. Cases of myoclonus, internuclear ophthalmoplegia, multifocal leukoencephalopathy, and dementia have been described. The mechanism underlying these processes remains obscure but may be immunologic or related to trace vitamin deficiencies. It has also been claimed that occult CD accounts for a substantial proportion of patients with neurologic dysfunction of unknown cause. Some authorities recommend that cryptogenic ataxia and neuropathies be routinely screened for the presence of gluten sensitivity, whereas others suggest that children with white matter lesions should be tested for CD, even if free from intestinal symptoms¹².

In conclusion, CD should be considered on the differential diagnosis in patients presenting with unexplained neurologic symptoms.

References

1. FINELLI PF, McENTEE WJ, AMBLER M, KESTENBAUM D. Adult celiac disease presenting as cerebellar syndrome. *Neurology* 1980;30:245-9.
2. DUGGAN JM. Recent developments in our understanding of adult celiac disease (review). *Med J Aust* 1997;166:312-5.
3. BRUCE SE, BJARNASON I, PETERS TJ. Human jejunal transglutaminase: demonstration of activity, enzyme kinetics and substrate specificity with special relation to gliadin and coeliac disease. *Clin Sci* 1985;68:573-9.
4. SULKANEN S, HALTTUNEN T, LAURILA K, KOLHO KL, KORPONAY-SZABO IR, SARNESTO A, *et al.* Tissue transglutaminase autoantibody enzyme-linked immunosorbent assay in detecting celiac disease. *Gastroenterology* 1998;115:1322-8.
5. DOHAN FC. More on celiac disease as a model for schizophrenia. *Biol Psychiatry* 1983;18:561-4.
6. PETTERSON A, SJOBERG K, LERNMARK A, ERIKSSON S. HLA genotypes in coeliac disease and in healthy individuals carrying gliadin antibodies. *Eur J Gastroenterol Hepatol* 1993;5:445-50.
7. KINNEY HC, BURGER PC, HURWITZ BJ, HIJMANS JC, GRANT JP. Degeneration of the central nervous system associated with celiac disease. *J Neurol Sci* 1982;53:9-22.
8. FEIGHERY C. Coeliac disease (review). *BMJ* 1999;319:236-9.
9. BARR GD, GREHAN MJ. Coeliac disease (review). *Med J Aust* 1998;169:109-14.
10. WEBER P. Management of osteoporosis: is there a role for vitamin K? *Int J Vitam Nutr Res* 1997;67:350-6.
11. HAGEN EM, GJERDE IO, VEDELER C, HOVDENAK N. Neurological disease associated with celiac disease. *Tidsskr Nor Laegeforen* 2000;120:439-42.
12. KIESLICH M, ERRAZURIZ G, POSSELT HG, MOELLER-HARTMANN W, ZANELLA F, BOEHLES H. Brain white-matter lesions are common in celiac disease. *Pediatrics* 2001;108:21.

Sažetak

NEUROLOŠKE MANIFESTACIJE CELIJAKIJE U ODRASLIH: PRIKAZ SLUČAJA

J. Stipić, Z. Perković, V. Crnek-Kunstelj, M. Relja, A. Stipić-Marković i F. Škreb

Celijakija je učestalija nego što se misli i to treba uzeti u obzir pri diferencijalnoj dijagnostici nejasnih neuroloških sindroma. Obično se javlja u dobi od 5-24 mjeseca sa znacima crijevne malapsorpcije, zaostajanjem u rastu, nadutošću uz učestale stolice, slabost mišića, hipotoniju, slab apetit i neraspoloženje. U odraslih znaci celijakije mogu biti različiti. Učestalost malignoma također je povećana. U nekih je bolesnika celijakija povezana sa znacima oštećenja živčanoga sustava poput encefalopatije, cerebelarne simptomatologije, cerebralne atrofije, demencije, cerebralnog vaskulitisa, miopatije, oduzetosti ekstremiteta, periferne neuropatije, višezarišne encefalopatije i psihijatrijskih poremećaja. Opisana je 47-godišnja bolesnica s nedijagnosticiranom celijakijom, u koje je prvi simptom bila intenzivna bol u leđima, zbog koje je provodila fizikalnu rehabilitaciju. Nakon toga javili su se difuzni bolovi u kostima uz teškoće pri hodu, a potom napredujuća slabost donjih ekstremiteta. Zbog flacidne parapareze, smetnji mokrenja i gubitka tjelesne težine bolesnica je primljena na bolničko liječenje. Dakle, u bolesnika s nejasnom neurološkom simptomatologijom treba u obzir uzeti i mogućnost da se primarno radi o celijakiji.

Ključne riječi: *Celijakija, komplikacije; Bolesti živčanoga sustava, komplikacije; Celijakija, dijagnostika; Prikaz slučaja; Odrasla osoba*