

SEVERE HEAD INJURIES IN ALCOHOL ABUSERS

Boris Božić¹, Andrej Kogler¹, Tomislav Sajko¹, Nenad Kudelić¹ and Vladimir Tonković²

¹University Department of Neurosurgery, ²Department of Interventional and Diagnostic Radiology, Sestre milosrdnice University Hospital, Zagreb, Croatia

SUMMARY – The issue of severe head injuries in alcohol abusers is presented. During the 1993 – 2002 period, 3700 patients with a history of alcohol abuse were treated for severe head injuries at the University Department of Neurosurgery, Sestre milosrdnice University Hospital in Zagreb. The leading injury was brain concussion, followed by acute subdural hematoma. Severe head injury in alcohol abusers results in high mortality and morbidity in both younger and older population. The mortality rate in patients who underwent surgery ranged between 23% and 55%, and in those not operated on between 38% and 85%.

Key words: *Brain injuries, surgery; Brain injuries, etiology; Brain injuries, epidemiology; Alcohol drinking, complications; Risk factors; Retrospective studies*

Introduction

The incidence of severe head injury is much higher in alcohol abusers than in non-alcoholics^{1,2}. The percentage of these injuries almost equals that recorded in traffic accidents. The factors contributing to it include cerebral atrophy¹ and alcohol induced coagulopathies (Fig. 1). The factor responsible for the higher incidence of bleeding in alcohol abusers is the higher level of vascular fragility. This especially refers to so-called bridging veins located in the subdural space, extending from the brain cortex to the dura. In alcohol abusers, these veins are stretched due to cerebral atrophy, and the application of even minimal force leads to their tear and formation of subdural hematoma. Subdural hematoma is a major finding in alcohol abusers sustaining severe head injury.

Patients and Methods

Between 1993 and 2002, a total of 3700 patients with a history of alcohol abuse were treated for severe head injury at the University Department of Neurosurgery, Sestre

milosrdnice University Hospital in Zagreb. The number of alcohol abusers who sustained severe head injury was compared with the total number of patients with severe head injury (Fig. 2). The number of alcoholics operated on for severe head injury was compared with the total number of patients operated on for the same injury (Fig. 3)^{4,5}. The number of alcoholics with severe head injury who were operated on was compared with the number of those who did not undergo surgery (Fig. 4)^{6,7}. The rate of mortality and disability were also compared between alcohol abusers with and without operative treatment (Fig. 5).

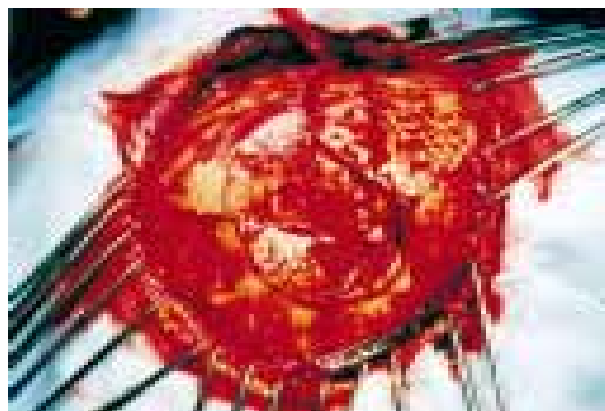

Fig. 1. Severe head injury in an alcohol abuser – multifragmental skull fracture with acute epidural hematoma and brain concussion (intraoperative image).

Correspondence to: *Boris Božić, M.D., Ph.D.*, University Department of Neurosurgery, Sestre milosrdnice University Hospital, Vinogradska c. 29, HR-10000 Zagreb, Croatia
E-mail: neuroklinika@iskon.hr

Received October 12, 2003, accepted November 20, 2003

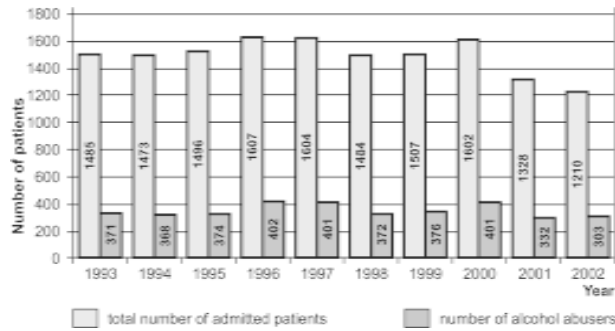


Fig. 2. Number of alcohol abusers with severe head injury (n=3700) and total number of patients admitted during the 1993-2002 period (25%).

Discussion and Conclusion

During the 1993 – 2002 period, 3700 alcohol abusers were treated at our Department for severe head injury, accounting for 25% of the total number of patients treated for severe head injury. The number of alcohol abusers operated on for severe head injury accounted for 12% of all patients operated on at the Department during the study period. Of these 3700 patients, 1246 (33%) underwent surgery, whereas the rest of 2454 (67%) patients were treated without operative procedures. The leading finding in the patients operated on was subdural hematoma (49%), followed by epidural hematoma (15%) (Figs. 6 and 7)^{7,8}. The number of acute and chronic subdural hematoma was almost equal. The major finding in alcohol abusers who did not undergo surgery was brain concussion (36%) (Fig. 8).

The mortality and morbidity rate in alcohol abusers of young adult age who did not undergo surgery was 23%, and in those operated on 38%. In older age alcoholics, the mortality and morbidity rate was 55% and 85% in those not

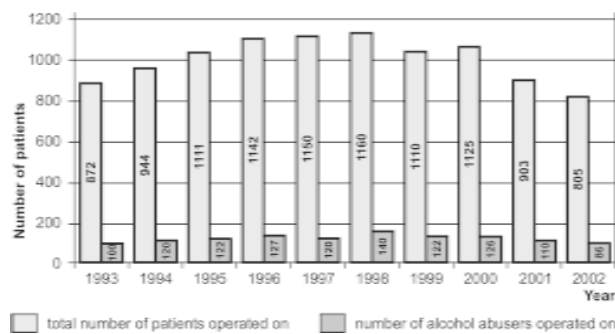


Fig. 3. Number of alcohol abusers with severe head injury operated on (n=1246) and total number of patients operated on (12%).

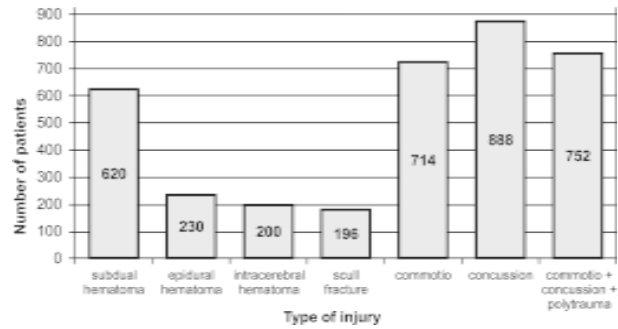


Fig. 4. Number and type of severe head injury in alcohol abusers operated on (n=1246; 33%) and number of patients treated without surgery (n=2454; 67%).

submitted to surgery and those operated on, respectively. The major cause of mortality and morbidity was acute subdural hematoma.

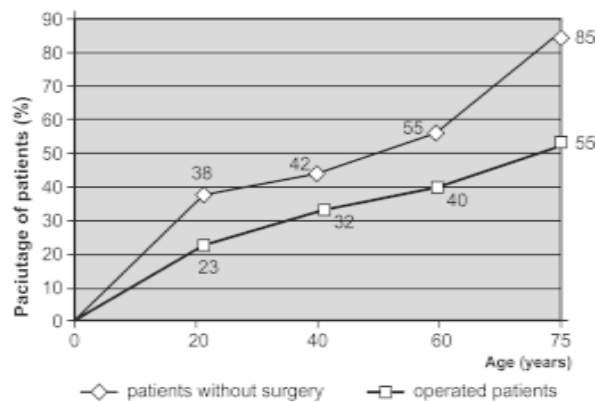


Fig. 5. Mortality and morbidity in alcohol abusers with severe head injury treated during the 1993-2002 period according to age.

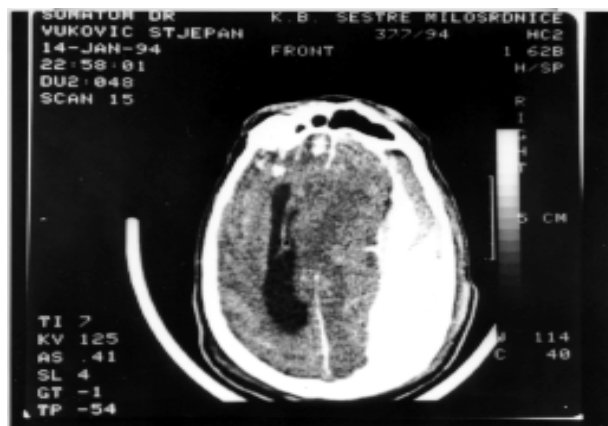


Fig. 6. CT scan showing an acute subdural hematoma.

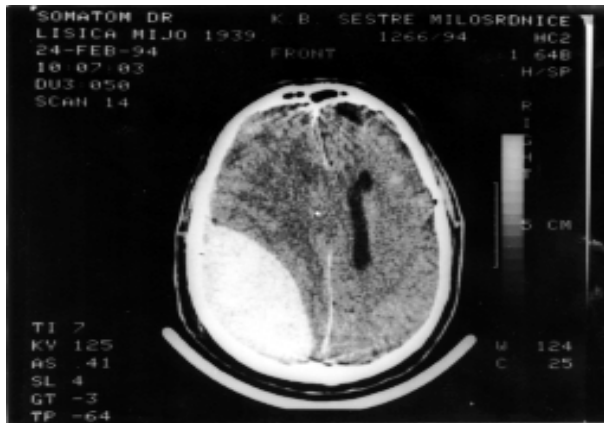

Fig. 7. CT scan showing an acute epidural hematoma.

The results showed the mortality and morbidity rate in alcoholics to rise with age, which is consistent with literature data. On literature review, we did not find any report on such a large series of patients with a history of alcohol abuse and severe head injury. Severe head injury in alcohol abusers poses a serious problem in our population and results in high mortality and morbidity rates.

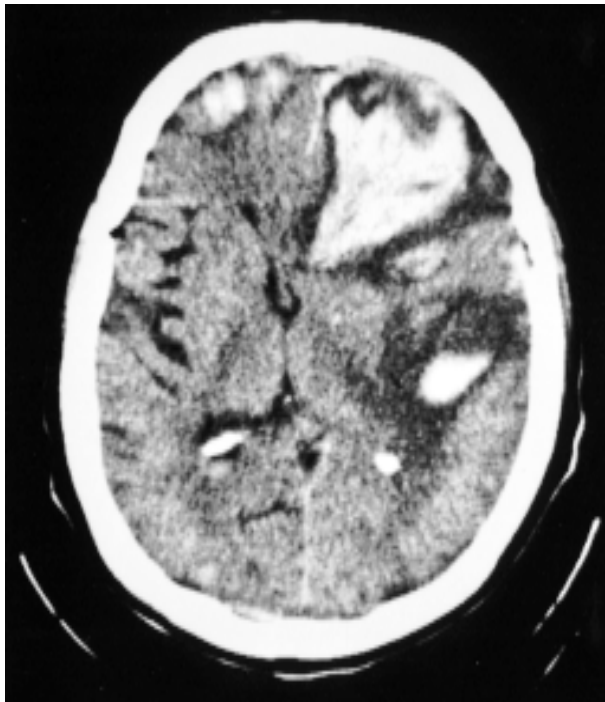


Fig. 8. CT scan showing multiple brain concussions.

References

1. EICHNER ER. The hematologic disorders of alcoholism. *Am J Med* 1983;54:621-30.
2. BROWN FD, MULLAWS S, DUOLA EE. Delayed traumatic intracerebral hematomas: report of three cases. *J Neurosurg* 1988;48:1019-22.
3. BOŽIĆ B, KOGLERA, NEGOVETIĆ L, RADIĆ I, ŽIVKOVIĆ DJ, ČOSIĆ T, ILEJ M. Craniocervical lesions in alcoholic. *Acta Clin Croat* 1997;36:(Suol 1):94.
4. MILLER JD. Physiology of trauma. *Clin Neurosurg* 1982;29:103-30.
5. CLIFTON GL, McCORMIC WF, GROSSMAN RG. Neuropathology of early and late deaths after head injury. *Neurosurgery* 1981;8:309-14.
6. KOGLER A, BOŽIĆ B, NEGOVETIĆ L, KOVAČ D, ČERINA V. Neurosurgical treatment of patients with acute intracranial space-occupying syndrome. *Acta Clin Croat* 1997;36:(Suppl 1):93.
7. ABBOT WD. Traumatic subdural hematoma. *Am J Surg* 1973;33:17-23.
8. BOŽIĆ B, KOGLERA, NEGOVETIĆ L, KOVAČ D, ŠKARICA R. Decompression craniotomy in complicated craniocerebral lesions. *Acta Clin Croat* 1997;36:(Suppl 1):94.
9. YUMANS JR. Causes of shock with head injury. *J Trauma* 1974;4:204-9.
10. KURZE T. Prognosis of patients with severe head injury. *Neurosurgery* 1979;4:283-9.
11. MILLER JD. ICP monitoring: current status – future directions. *Acta Neurochir* 1987;85:80-6.
12. KLATZO I. Neuropathological aspects of brain oedema. *J Neuro-pathol Exp Neurol* 1997;26:1-14.

Sažetak

KRANIOCEREBRALNE OZLJEDE U OSOBA S ALKOHOLNOM BOLEŠĆU

B. Božić, A. Kogler, T. Sajko, N. Kudelić i V. Tonković

U radu su prikazane kranIOCerebralne ozljede u populaciji osoba s alkoholnom bolešću. Provedena je retrospektivna analiza bolesnika koji su liječeni u Klinici za neurokirurgiju Kliničke bolnice "Sestre milosrdnice" u razdoblju od 1993. do 2002. godine. U prikazanom materijalu prevladavaju teške kranIOCerebralne ozljede koje se najčešće očituju kao akutni subduralni hematomi, često u kombinaciji s teškim nagnječenjem mozga i politraumom. Ove ozljede rezultiraju izrazito visokim stupnjem smrtnosti i pobola kako u mlađim tako i u starijim dobnim skupinama. Kod neoperiranih bolesnika kreću se u rasponu od 23% do 55%, a kod operiranih bolesnika od 38% do 85%.

Ključne riječi: Ozljede mozga, kirurgija; Ozljede mozga, etiologija; Ozljede mozga, epidemiologija; Pijenje alkohola, komplikacije; Rizični čimbenici; Retrospektivne studije