

ULTRASOUND MONITORING OF THE SUCCESS OF REHABILITATION OF THE FEMORAL MUSCLE AFTER THE INJURY OF THE KNEE JOINT

Melita Uremović¹, Renata Budić², Marija Bošnjak-Pašić³, Vesna Vargek-Solter³, Branka Bošnjak⁴, Darko Solter and Vida Demarin³

¹Zagreb Insurance Company, Zagreb; ²Special Hospital for Rehabilitation, Krapinske Toplice; ³University Department of Neurology, ⁴University Department of Psychiatry, Sestre milosrdnice University Hospital, Zagreb, Croatia

SUMMARY – The ultimate goal of successful rehabilitation of the knee joint is to achieve normal movement of the knee joint and to re-establish active muscle control in the shortest time possible. The knee joint movement during rehabilitation can be objectively measured by using a goniometer. The recovery of femoral muscles after a knee joint injury can be accurately and precisely monitored by ultrasonic measurement of the muscular volume. The aim of this longitudinal study was to standardize and evaluate the method of ultrasonographic measurement of muscular volume itself, and practical applicability of the method, in order to reach a general conclusion on the femoral muscle rehabilitation. The measurements were performed at equal intervals in 30 subjects with a history of knee joint injury, and in 30 asymptomatic subjects as a control group. The results showed that the ultrasound method could precisely and accurately monitor the process of muscular atrophy that develops during immobilization, as well as the course of muscular restitution during physical therapy. Full recovery of the rectus femoris muscle was achieved in more than a half of the patients, i.e. 54.4 per cent of women and 53.8 per cent of men. Vastus intermedius muscle responded less readily to physical therapy. Full recovery was achieved in 22.2 per cent of female and 28.6 per cent of male patients. Within the same intervals, no muscular mass changes were recorded in the control group. Prior to implementation, it is necessary to precisely determine the reproducibility of the method and measurement errors. The ultrasound method has good reproducibility because the error does not exceed 2 per cent of the measurement value. However, practical application of ultrasonic measurement is not simple, because it requires experience and procedure standardization.

Key words: *Muscles, diagnosis; Muscles, ultrasonography; Wounds and injuries, diagnosis; Knee, physiology*

Introduction

The knee is the most complex human joint, and its functional stability is secured by the mutual functioning of joint parts, ligaments, joint capsule, menisci and numerous surrounding muscles¹. In the recent time, the number of knee joint injuries has increased in traffic and in

sports activities. The largest number of injured persons are young and middle aged people who are employable, so it is very important to begin the rehabilitation as soon as possible after the injury in order to achieve the quickest and best possible recovery. Every injury of the knee joint results in the development of hypotrophy of the upper leg muscles, which can amount to up to 1 cm^{per} day. Successful rehabilitation of the knee joint means to achieve full mobility of the joint, and to establish normal tonus of the upper leg muscles^{2,3}. Joint mobility during rehabilitation can be measured objectively by goniometer, while the re-

Correspondence to: *Melita Uremović, M.D.*, Zagreb osiguranje, Maksimirska 101, HR-10000 Zagreb, Croatia

Received October 22, 2002, accepted December 16, 2002

covery of the muscles, until recently, was monitored by measuring the extent of the upper leg muscles with a centimeter tape. That method is indirect, because measurements cover all parts of the upper leg (bone, fat tissue and skin thickness)^{4,5}. Ultrasound, computed tomography or magnetic resonance can be used for precise and accurate measurement of the surface of the femoral muscle volume during rehabilitation.

Ultrasound measurement has no ionizing radiation, it is inexpensive and widely used. There is a good space resolution during the measurement, real time is recorded and the possibility of three dimensional evaluation exists. The test can be repeated with no harm for the injured person. The disadvantage of this type of presentation of the tested muscle is the partial insight in the injured limb^{6,7}.

Unlike ultrasonic measurement, computed tomography has good spatial and contrast resolution, and presentation of the whole limb is obtained. Detailed analysis is possible and the procedure can be taken during the gypsum cast immobilization. Computed tomography has a high radiation, the real time cannot be recorded, and artifacts are derived if the osteosynthetic material is present in the knee joint. The examination is expensive and it is not appropriate for longitudinal monitoring of muscular alterations and for determining the dynamics of such alterations⁸⁻¹¹.

During the magnetic resonance examination, there is no ionizing radiation, optimal contrast resolution is achieved, examination in several planes and through the gypsum cast is possible. However, the test is expensive and contraindicated in patients with pacemakers and ferromagnetic extraneous substances (foreign bodies)²⁻¹⁵.

Subjects and Methods

The investigation was based on longitudinal examination of the muscular mass by ultrasound echosonography in adults who had sustained knee joint injury, during their medical treatment and rehabilitation.

The investigation included 30 subjects with knee joint injuries, aged 15 to 50 years, 9 females and 21 males, while the control group consisted of 30 asymptomatic subjects of the same age. In each subject, the knee injury was verified radiographically, echosonographically and clinically, within less than 48 hours from the injury. The evaluating parameters were age, sex, body weight, body height, occupation, injury diagnosis, date of measurement, length of the healthy and injured upper leg, volume of the upper leg, and ultrasound measurement of the volume of the mus-

culus vastus intermedius and musculus rectus femoris of the injured and healthy leg, measured in the middle of the upper leg -5 cm proximally and distally from the middle (center).

Instruments and procedure

All measurements were performed on an Kranzbüchler ultrasound machine (Medizinische Systeme GmbH, Germany) using a linear probe of 7.5 MHz frequency. During the measurements, the subjects were in prone position with their legs stretched, muscles relaxed, and feet in neutral position. First, the length of both legs was measured from the large trochanter to the lateral condyle of the shinbone (tibia) by using a centimeter tape. Then the middle of the upper leg, and points at 5 cm proximally and 5 cm distally from the middle were determined. The volume of both upper legs was measured at the determined points. Furthermore, the longitudinal and transverse ultrasound measurements of the musculus vastus intermedius and musculus rectus femoris were performed. All measurements were done three times: within 48 hours from the injury, upon immobilization removal, and after rehabilitation. From the known data on the linear probe length and width as well as on the length of the middle part of the femoral muscle and average value of the measured muscles, the volume of each measured muscle was calculated.

Results

The SPS (SPSS-7.5 for Windows, SPSS nc., Chicago, USA) software was used for statistical data processing. General data of the study subjects were expressed as mean and standard deviation, while median with measurement range was used to express the muscle volume measurements. The measurements were mutually compared by the even and odd t-tests.

There was no statistically significant difference between the patient and control group according to the basic parameters (age, sex, weight and height), ($p > 0.001$) (Figs. 1-3).

The results obtained showed no statistically significant difference in the sex distribution of the left and right leg injuries (Figs. 4-6).

Results of the measurement of musculus rectus femoris and musculus vastus intermedius volumes obtained within 48 hours from the injury showed no differences between the healthy and injured leg in either the patient or control group, so the volume was considered normal.

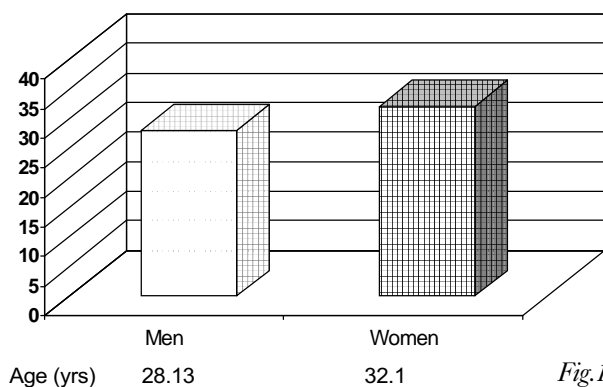


Fig.1.

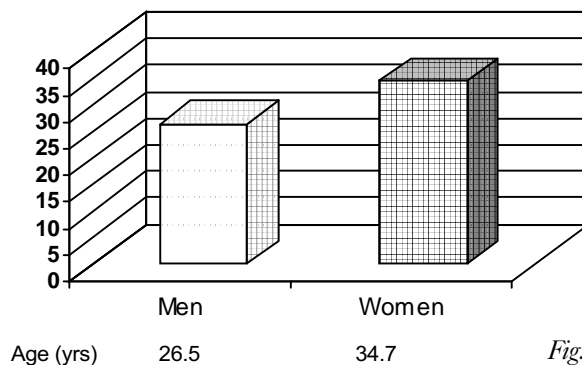


Fig.1a.

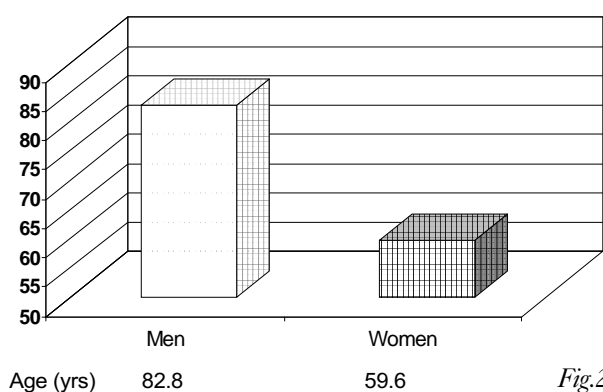


Fig.2.

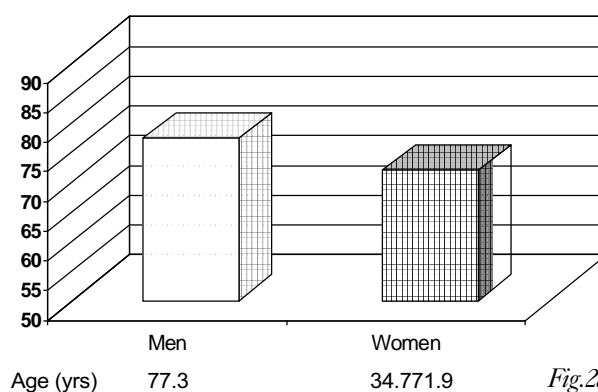


Fig.2a.

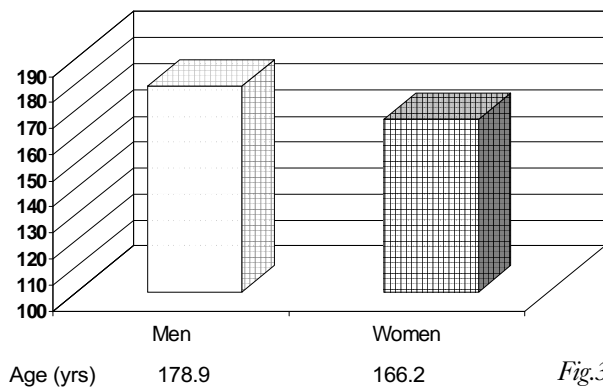


Fig.3.

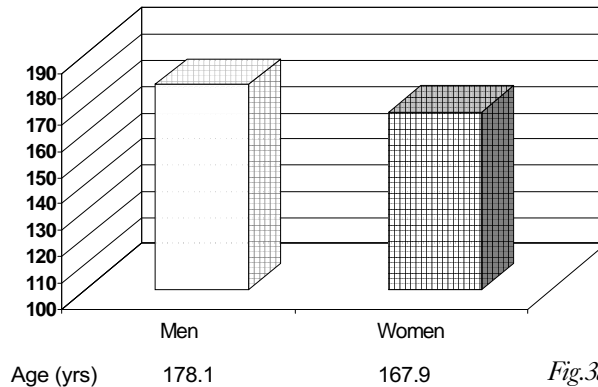


Fig.3a.

Figs. 1-3. General data on control group subjects (n=30) according to sex

Figs. 1a-3a. General data on patient group (n=30) according to sex

There was a significant difference between the first and second measurement in the reduction of muscular mass, and between the second and third measurement in the rate of muscular mass increment. During the period of inactivity and immobilization, hypertrophy of the injured upper leg muscle occurred. There was a statistically significant

difference between the first and second measurement in the values of muscle mass reduction, and between the second and third measurement in the volume related to muscle mass increase. In the healthy leg, a reduction of muscular volume occurred during the period of inactivity, whereas after physical therapy an increase in the muscu-




Fig. 4. Lateralization of injured leg muscle (n=13) according to sex (left leg)

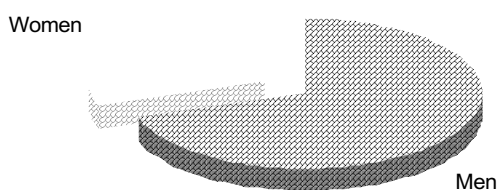


Fig. 6. Lateralization of injured leg muscle (n=30) according to sex (left + right leg)

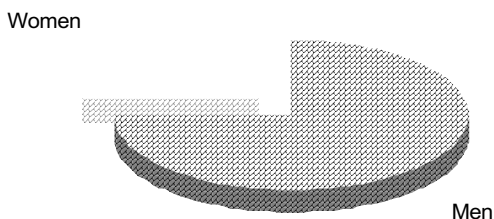


Fig. 5. Lateralization of injured leg muscle (n=17) according to sex (right leg)

lar volume was recorded, however, it was much less pronounced than in the injured leg. In the control group there were no differences in the values of muscular volumes among the three measurements (Figs. 7 and 8).

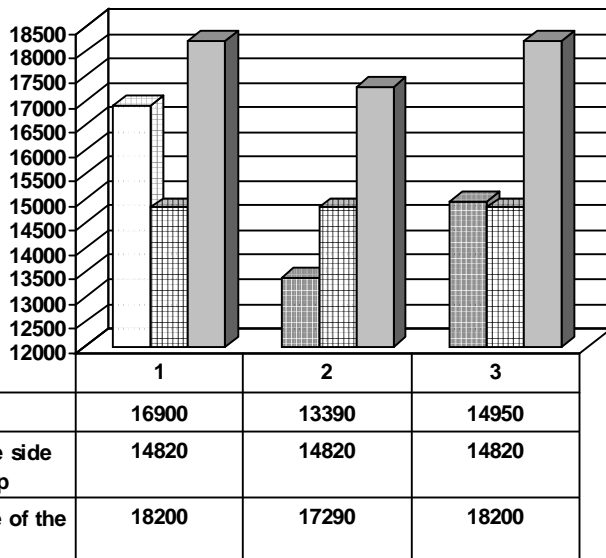
Discussion and Conclusion

Due to inactivity and immobilization that are necessary after a knee joint injury for the scarred tissue repair and faster muscular fiber restructuring, elasticity of the periarticular structures is reduced, which results in restriction of the joint circular movement and may lead to the development of connective tissue fibrosis⁶. During immobilization, the lack of muscular contraction results in hypotonia and hypotrophy of the injured leg muscles. Hypotrophy, due to inactivity, affects all muscles, it begins quickly, and may show a rate of up to 1 cm^{per} day. Therefore, rehabilitation of the injured knee joint should begin during immobilization^{17,18}. Successful rehabilitation of the knee joint means achievement of full joint circular move-

ment and regaining normal tonus and trophicity of the upper leg musculature, which is important for the functional stability of the joint^{9,20}. Until recently, rehabilitation of the upper leg muscles was monitored by measuring the volume of the upper leg muscles with a centimeter tape. This method is indirect because it includes all parts of the upper leg. The accurate and precise measurement of the surface and volume of the upper leg muscles during rehabilitation can be performed echosonographically, by computed tomography or magnetic resonance²²⁻²⁴. To our knowledge, only one scientific work has been published in the international literature, the one from the Liverpool University, where the muscle volume of the quadriceps femoris was measured by magnetic resonance and at the same time by statistical B mode ultrasound². Ten healthy volunteers with no history of upper leg injury or neuromuscular disorder participated in the study. The investigation was performed on the left upper leg, and all ultrasonic measurements were done prior to the magnetic resonance measurements. The measurement was done by a technique EDP 1200 cell B-mode scanner and 5-MHz probe.

Fig. 7. Measurement results of *m. rectus femoris*

- 1 Measurement after the injury
- 2 Measurement after 7 days
- 3 Measurement after physical therapy



Photographs were obtained on a Sony videoprinter. The magnetic resonance measurement was performed using the Sigma system of the whole body measurement. All volunteers were in supine position with the leg completely stretched out in neutral position during the test. The cross-section area of the quadriceps muscle was measured at the point where the proximal and distal third of the upper leg meet. In order to calculate with the error coefficient of 4-5 per cent, seven axial cross-sections of the upper leg were made, with a 5-cm distance between the cross-sections. Bland and Altman found the difference between the mean values of estimated cross-sectional area of the muscle obtained by ultrasound to be 0.49 cm², while the volume difference using magnetic resonance was 36.85 cm³. The differences obtained by these two methods are not considered relevant in clinical practice, since there is no statistically significant difference between the values of cross-sectional areas and the volume measured by ultrasound and magnetic resonance. This fact proves that the ultrasound method, unlike other methods, is more appropriate for research in this area²⁴⁻²⁷.

In our study, we wanted to apply a new method of testing changes in the upper leg muscular volume which we simplified as much as possible in order to make it applicable in the clinical routine. Reproducibility of the method is determined by repeated measurements in healthy subjects in short, one-day periods, as no change in the muscle volume is expected to occur in this time. The error of the method has been estimated from measurement differences and coefficient of variability of these measurements. Our research was conducted longitudinally, at different time periods and at different intervals, in order to determine the dynamics of muscular mass atrophy during immobilization and the restitution of muscular volume after rehabilitation. We believe that the dynamics of alterations in the muscle status is not linear concerning the negative quotient of volume alteration within a time unit (atrophy) and positive quotient (restitution of muscle volume).

Ultrasound monitoring of the muscle volume alteration during rehabilitation is simple and acceptable in daily practice, and it enables accurate and precise monitoring of the response of every muscle, especially during the use of physical therapy in the course of rehabilitation.

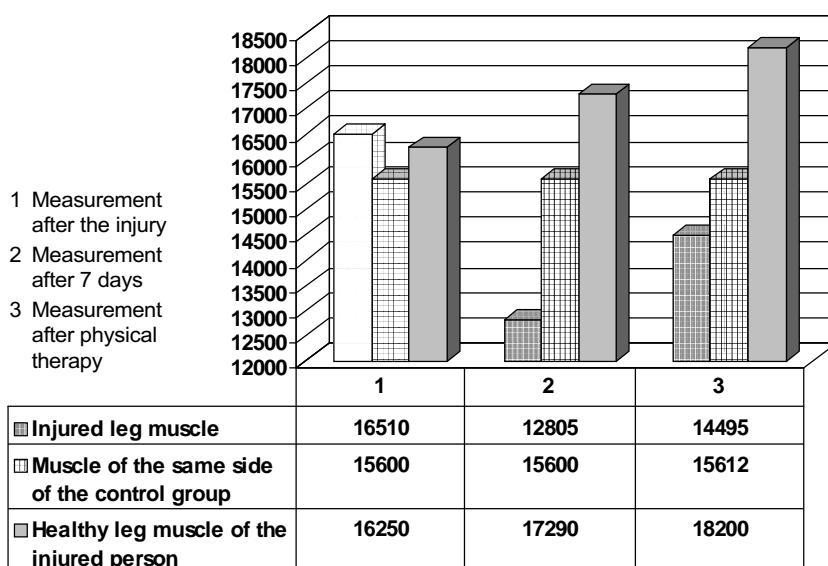


Fig. 8. Measurement results of *m. vastus intermedius*

References

1. RUSZKOWSKI I, *et al.* Ortopedija. 3rd ed. Zagreb: JUMENA, 1986:311-7.
2. SCHWEITZER ME, TRAIN D, DEEL YDM, HUME EL. Medial collateral ligament injuries; evaluation of multiple signs, prevalence and location of associated bone bruises, and assessment with MR imaging. *Radiology* 1995;194:825-9.
3. PEĆINA M. Koljeno. Primijenjena biomehanika. 1st ed. Zagreb: JUMENA, 1982:243-60.
4. YOUNG A, STOKES M, ROUND JM, EDWARDS RHT. The effect of high-resistance training on the strength and cross-sectional area of the human quadriceps. *Eur J Clin Invest* 1983;13:411-7.
5. SIPILA S, SUOMINEN H. Ultrasound imaging of the quadriceps muscle in elderly athletes and untrained men. *Muscle Nerve* 1991;14:527-33.
6. IKAI M, FUKUNAGA T. A study of training effect on strength per unit cross-sectional area of muscle by means of ultrasonic measurement. *Int Z Angew Physiol W inschl Arbeitsphysiol (Berlin)* 1970;28:173-80.
7. STOKES M, YOUNG A. Measurement of quadriceps cross-sectional area by ultrasonography: a description of the technique and its applications in physiotherapy. *Physiother Pract* 1986;2:31-6.
8. RICE CL, CUNNINGHAM D A, PATERSON DH, LEFCOE MS. Arm and leg composition determined by computed tomography in young and elderly men. *Clin Physiol* 1989;9:207-20.
9. SCHANTZ P, RANDALL-FOX E, HUTCHISON W, TYDEN A, ÅSTRAND PO. Muscle fibre distribution, muscle cross-sectional area and maximum voluntary strength in humans. *Acta Physiother Scand* 1983;117:210-26.

10. NARICI MV, ROI GS, LANDONI L, MINETTI AE, CERRETELLI P. Changes in force, cross-sectional area and neural activation during strength training and detraining of the human quadriceps. *Eur J Appl Physiol* 1989;59:310-9.
11. NICHOLAS JJ, TAYLOR FH, BUCKINGHAM RB, OTTONELLO D. Measurement of the circumference of the knee with ordinary tape measure. *Rheumatol Dis* 1976;35:282.
12. STOKES M. Reliability and repeatability of methods for measuring muscle in physiotherapy. *Physiother Pract* 1985;1:71-6.
13. BENEKE R, NEUERBERG J, BOHNDORF K. Muscle cross-section measurement by magnetic resonance imaging. *Eur J Appl Physiol* 1991;63:424-9.
14. PETERSON H, HAMLIN DJ, MANUSCO A, SCOTT KN. Magnetic resonance imaging of the musculoskeletal system. *Acta Radiol* 1985;26:225-34.
15. ENGSTROM CM, LOEBGE, REID JG, FORREST WJ, AVRUCH L. Morphometry of the human thigh muscles. A comparison between anatomical sections and computer tomographic and magnetic resonance images. *J Anat* 1991;176:139-56.
16. JAJIĆ I. Patofiziološka osnova rane kinezioterapije u traumatologiji. *Traumatologija u suvremenoj medicini. III Continuous Postgraduate Education, Zagreb University School of Medicine, Zagreb, 1983:199.*
17. WOODALL W, WELSH J. A biomechanical basis for rehabilitation programs involving the patellofemoral joint. *J Orthop Sports Phys Ther* 1990;11:535-42.
18. REILLY DT, MARTENS M. Experimental analysis of the quadriceps muscle force and patello-femoral joint reaction force for various activities. *Acta Orthop Scand* 1972;43:126-37.
19. PUČARI I. Kinezioterapija. In: DOMLJAN Z, *et al.* *Fizikalna medicina. Zagreb: Medicinski fakultet, 1993:4.*
20. JAJIĆ I. Specijalna fizikalna medicina. Zagreb: Školska knjiga, 1991.
21. FORNAGE B. Echographie et la médecine du sport. *J Echogr Med Ultrason* 1986;7:111-2.
22. FORNAGE B, TOUSCHE D, DESHAYES JL, SEGAL Ph. Diagnostic des calcifications du tendon rotulien. Comparaison échographique. *J Radiol* 1984;65:355-9.
23. AISEN AM, MARTEL W, BRAUNSTEIN EM, McMILLIN KI, PHILLIPS WA, KLING TF. MRI and CT evaluation of primary bone and soft-tissue tumors. *AJR Am J Roentgenol* 1986;146:749-56.
24. MAYHEW TM, OLSEN DR. Magnetic resonance imaging (MRI) and model-free estimates of brain volume determined using the Cavalieri principle. *J Anat* 1991;178:133-44.
25. BLAND JM, ALTMAN DG. Statistical methods for assessing agreement between two methods of clinical measurement. *Lancet* 1986;i:307-10.
26. WEISS LW. The use of B-mode ultrasound for measuring the thickness of skeletal muscle at two upper leg sites. *J Orthop Sports Phys Ther* 1984;6:163-7.
27. EHMAN RL, BERQUIST TH, McLEOD RA. Imaging of the musculoskeletal system: a 5 year appraisal. *Radiology* 1988;166:313-20.

Sažetak

ULTRAZVUČNO PRAĆENJE USPJEŠNOSTI REHABILITACIJE MIŠIĆA NATKOLJENICE NAKON OZLJEDE KOLJENSKOG ZGLOBA

M. Uremović, R. Budić, M. Bošnjak-Rišić, V. Vargek-Solter, B. Bošnjak, D. Solter i V. Demarin

Krajnji cilj uspješne rehabilitacije nakon ozljede koljena je postizanje normalnog opsega pokreta zgloba i uspostavljanje aktivne mišićne kontrole u što kraćem razdoblju. Mjerenje opsega pokreta zgloba može se u tijeku rehabilitacije provoditi objektivno pomoću goniometra. T očno i precizno praćenje oporavka natkoljeničnih mišića nakon ozljede zgloba koljena moguće je metodom ultrazvučnog mjerenja volumena mišića. Cilj ove longitudinalne studije bio je standardizirati i vrednovati metodu ultrazvučnog mjerenja volumena mišića i prikladnost primjene ove metode u praksi radi objektivizacije rehabilitacije četverglavog mišića natkoljenice. Mjerenje je bilo provedeno u istim vremenskim razmacima u 30 ispitanika koji su u anamnezi imali ozljedu zgloba koljena te u 30 asimptomatskih ispitanika koji su činili kontrolnu skupinu. Rezultati su pokazali da se ehosonografijom može točno i precizno pratiti tijek promjene volumena mišića pri procesu atrofije koja nastaje za vrijeme imobilizacije i tijekom restitucije mišića za vrijeme provođenja fizikalne terapije. Primjene treba točno odrediti ponovljivost metode i pogreške mjerenja. Ultrazvučna metoda ima dobru ponovljivost, jer pogreška ne prelazi 2% vrijednosti mjerenja.

Ključne riječi: *Mišići, dijagnostika; Mišići, ultrasonografija; Rane i ozljede, dijagnostika; Koljeno, fiziologija*