

RECONSTRUCTION OF CHRONIC MONTEGGIA'S LESIONS IN CHILDREN

Tomislav Đapić, Darko Antičević, Ranko Bilić and Davor Duvančić

Department of Orthopedic Surgery, University Department of Orthopedics, Zagreb University Hospital Center, Zagreb, Croatia

SUMMARY – Results of surgical treatment for chronic Monteggia's lesions in 16 children were retrospectively analyzed. The mean age at the time of reconstructive surgery was 7 years and 8 months. Using Bado's classification, there were 12 type I, 3 type III lesions, and 1 type IV lesion. In 11 cases, operative procedures consisted of a combination of corrective ulnar osteotomy and open reduction of radial head. Corrective ulnar osteotomy alone was required in 2 cases. Another two cases required a combination of corrective osteotomy of both radial and ulnar shafts. Annular ligament reconstruction had to be performed in only 1 case initially submitted to open reduction of radial head. The patients were examined at 9 years and 6 months of the initial reconstructive procedure on an average. Using the scale proposed by Morrey, there were 9 good, 4 satisfactory, and 3 poor results. Eleven complications were recorded including 2 radial nerve lesions, 2 nonunions at the site of ulnar osteotomy, 5 redislocations and 1 subluxation, and 1 ulnar fracture below the site of osteotomy. Seven of 11 patients with complications underwent repeat operative procedures. These seven patients included both children previously submitted to combined osteotomies of both the ulna and radius as well as both children who had undergone corrective ulnar osteotomy alone. Thus, a very high rate of complications was recorded in our series of patients undergoing operative treatment for the sequels of Monteggia's lesions. In our opinion, the main reason for this was inappropriate choice of operative treatment. Reporting on this very high rate of complications may hopefully draw attention to the fact that reconstructive procedures to correct the sequels of Monteggia's lesions should not be attempted before learning the basic principles that need to be addressed. These are reconstructive procedures that should only be performed after a thorough study of the possible complications. Based upon this survey of our experience, we conclude that in addition to ulnar deformity correction, open reduction and stabilization of radial head are mandatory to achieve a satisfactory result.

Key words: *Monteggia's fracture – surgery; Monteggia's fracture – classification; Monteggia's fracture – complications; Follow up studies; Child*

Introduction

Unreduced dislocations of radial head consequential to inappropriately treated or unrecognized Monteggia's lesions are rare in children. In an effort to avoid the undesirable longterm sequels of these residual radial head dislocations, a number of operative procedures have been proposed, e.g., open reduction of radial head with reconstruction of annular ligament¹⁻³; corrective ulnar osteotomy at

the site of malunited fracture⁴⁻⁸ with or without open reduction of radial head; and a combination of corrective osteotomies of both ulnar and radial shafts. Patient series reported in the literature are small, and there are no major prospective randomized studies⁸⁻¹⁵. The aim of the present study was to retrospectively analyze our own results obtained by the operative treatment of chronic Monteggia's fractures in order to determine the minimum treatment necessary to achieve a satisfactory result.

Patients and Methods

During the 1985-1998 period, 16 children (six female and ten male) were operated on at University Department

Correspondence to: Tomislav Đapić, M.D., Ph.D., Department of Orthopedic Surgery, University Department of Orthopedics, Zagreb University Hospital Center, Šalata 7, HR-10000 Zagreb, Croatia
ortopkl@mef.hr

Received January 30, 2003, accepted in revised form December 5, 2004

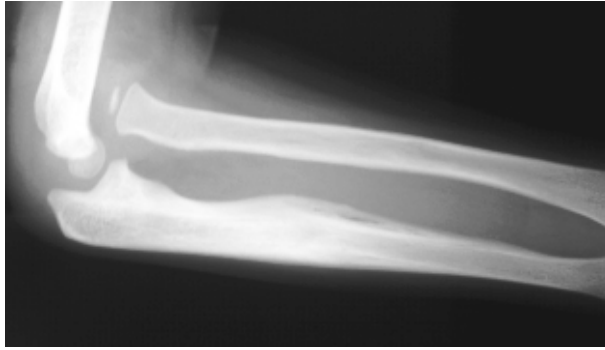

Fig. 1 (a) Radiogram of the elbow in a 6-year-old boy with chronic Monteggia's lesions

of Orthopedics, Zagreb University Hospital Center, to correct the sequels of chronic Monteggia's lesion, yielding an average of one child treated *per* year. According to laterality, the left side was involved in 9 and right side in 7 cases. The mean patient age at the time of surgery was 7 years and 8 month (range from 5 years and 2 months to 12 years and 10 months). According to Bado classification, there were 12 type I, 3 type III lesions and 1 type IV lesion. All patients were free from radial head changes such as overgrowth or secondary deformity. The mean interval between the initial injury and the reconstructive surgery was 11 months (range from 2 months to 4 years). Preoperatively, five patients had normal elbow mobility, whereas the remaining 11 had mild contracture. Two patients had valgus elbow deformity measuring 20 and 25 degrees.

A variety of surgical reconstructive procedures were performed. In 11 cases, open reduction of radial head was performed in combination with corrective ulnar osteotomy at the site of residual deformity. In 3 cases, open reduction was followed by radial head stabilization with Kir-

schner wire inserted through the capitellum into the proximal radius. In 2 cases, only corrective ulnar osteotomy was performed, with elongation by 8 and 12 mm. In 2 cases, corrective osteotomies of both the ulna and the radius were performed. In one case where there was no ulnar angulation, only open reduction of radial head was performed in combination with annular ligament reconstruction.

Postoperatively, the upper extremity was immobilized with the use of circular cast for 4 to 7 weeks (mean 6 weeks). All patients were evaluated clinically and radiographically at a mean of 9 years and 6 months (range from 3 years and 11 months to 17 years) of the initial reconstructive operation. Clinical evaluation performed by the first author consisted of three parts: 1) evaluation of elbow and wrist mobility according to "0" method; 2) evaluation of the proximal and distal radial-ulnar joint stability; and 3) evaluation of the neurologic status. Radiologic evaluation included standard anteroposterior and lateral projections of the operatively treated elbow. This anteroposterior projection was taken with the elbow extended and the forearm fully supinated. Lateral projection was taken with elbow flexion of 90° and the forearm in full pronation; to facilitate taking this lateral projection the shoulder was abducted to 90°.

Upon clinical and radiographic evaluation, the results were assessed according to Morrey's scale^{10,16}. This scale is based on both clinical and radiographic parameters. The clinical parameters include the presence or absence of pain plus assessment of elbow mobility and stability. The radiographic parameter consists of assessment of the radial head centrality. Using Morrey's scale, the final result is graded as good, satisfactory, or poor. The elbow is classified as good if there is full range of elbow flexion and extension. The forearm range of pronation and supination motion must exceed 100 degrees in aggregate. In addition, there is nor-

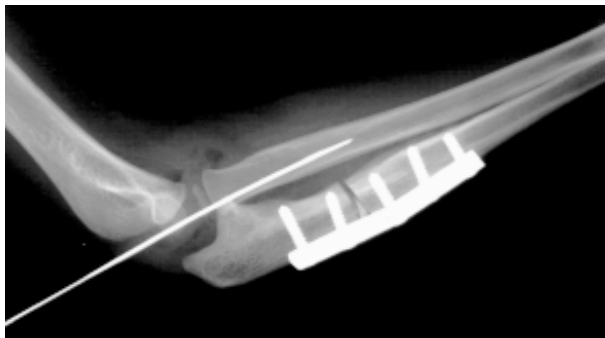


Fig. 1 (b) radiogram of the elbow in a 6-year-old boy with chronic Monteggia's lesions immediately after reconstructive operation

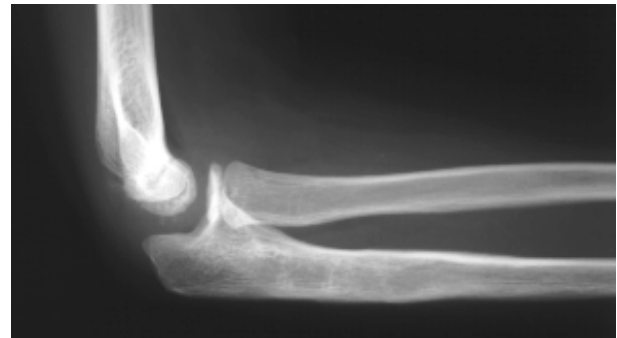

Fig. 1 (c) radiogram of the same elbow 4 years after reconstructive operation.

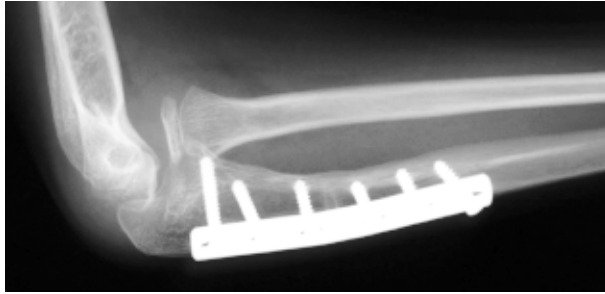


Fig. 2a. Subluxation after open reduction of the radial head without stabilisation with Kirschner wire and ulnar osteotomy. The parents refused repeat surgical procedure.

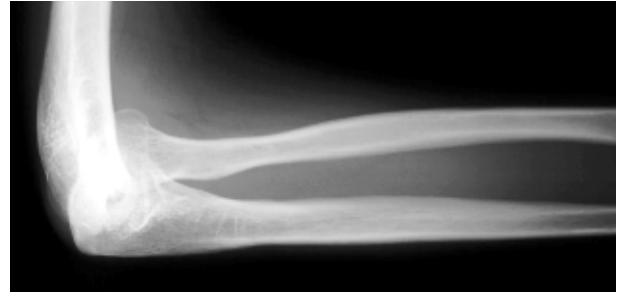


Fig. 2 b. 11 years after operation. Overgrowth of radial head is present. Final results was poor.

mal varus and valgus stability of the elbow with no pain. Radiographically, the radial head is centered at the capitellum. The clinical parameters for a satisfactory result are those where the elbow has minor elbow flexion contracture that does not exceed 30 degrees. The range of elbow flexion cannot be less than 100 degrees. The aggregate of the forearm pronation range is up to 100 degrees. The pronation must be at least 30 degrees. Pain is only temporary. There may be mild varus and valgus instability. Radiographically, the radial head is centered with the capitellum. The elbow is designated as poor result if the clinical parameter of elbow flexion is less than 100 degrees and there is flexion contracture exceeding 30 degrees. Forearm rotation is significantly limited with the aggregate rotation being less than 100 degrees. Pain is present and limits daily activities. The radiographic parameter includes a radial head that is partially or fully dislocated.

Results

All patients were evaluated by the first author at a mean of 9 years and 6 months of the initial reconstructive operation (range from 3 years and 11 months to 17 years). The mean patient age at the time of evaluation was 17 years and 2 months (range from 9 years and 1 month to 24 years). According to Morrey's scale, there were 9 good, 4 satisfactory, and 3 poor results (table 1). Radiographically, radial head was not centered in three patients with poor result: one was fully dislocated, and in the other two there was subluxation. Clinically, seven patients had full range of elbow flexion and extension, and six patients had mild contracture in the operatively treated elbow, whereas three patients sustained a significant loss of forearm rotation..

The survey of patient records revealed 11 complications (table 2.).Radial nerve injury was reported in two

patients; one of them fully recovered, whereas the other, a female, sustained permanent weakness of the hand and finger extension. Subsequent surgical exploration revealed no nerve transection. In two patients, nonunion developed at the site of corrective ulnar osteotomy, however, both were reported to have subsequently resolved. In one patient, spongioplasty was used, whereas Ilizarov technique produced successful union in the other. One patient experienced a complex complication on postoperative day 5. The ulna fractured below the fixation plate, which was associated with recurrent dislocation of the radial head. It was subsequently resolved by reoperation, when a longer plate was placed on the ulna and radial head was re-reduced and secured with Kirschner wire fixation through the humerus.

Redislocation occurred in five patients. One patient sustained persistent subluxation following initial reconstructive procedure (fig.2a,b). These five patients with recurrent dislocation underwent repeat operative procedures for radial head re-reduction. Unfortunately, subluxation persisted in one, and recurrent dislocation occurred in another one.

Seven patients had to be reoperated on. In one patient, radial nerve was explored. Five patients undergoing repeat procedures required radial head repositioning, and one of them also repeat osteosynthesis. Unfortunately, three patients required more than one repeat procedure: two patients underwent two repeat procedures each, whereas one patient underwent three repeat procedures. Overall, 11 repeat operative procedures had to be performed for complications, including patients requiring more than one repeat procedure. Both patients with corrective osteotomy of both ulna and radius as the initial reconstructive procedure required repeat operation for complications: one for exploration for radial nerve lesion, and the other for open

reduction of radial head. Final evaluation yielded poor result in both of them. Redislocation occurred in both patients with only corrective ulnar osteotomy with elongation as the initial reconstructive operation; one of them sustained a fracture of the ulna below the distal end of the plate. Following repeat surgery in the form of open reduction of the radial head with fixation with Kirschner wire through the humerus, the final result was good.

Discussion

Monteggia's lesions consist of various combinations of fracture of the ulna with the accompanying dislocation of the radial head. This combination of injuries was first described in 1814 by Giovanni Battista Monteggia^{17,18}. Currently, the most widely accepted classification of Monteggia's fractures has been provided by Jose Luis Bado¹⁷, a prominent orthopedic surgeon from Uruguay. He coined these injury combinations as Monteggia's lesions instead of fractures. According to Bado, Monteggia's lesions are divided into 4 types¹⁷. In type I lesion, the radial head dislocation is volar, and angulation of ulnar fracture is also apex volar. The fracture is usually oblique and located in the diaphysis or metaphysis. Type I lesion is most common in

both children and adults. In type II lesion, the radial head dislocation is posterior and the ulnar fracture angulation is apex posterior. It is very rare in children, occurring in approximately only 6% of cases. In type III lesions, the radial head dislocation is lateral and the ulnar fracture angulation is lateral or anterolateral. Ulnar fracture is usually located in the metaphysis. Type III lesion is the second most common lesion after type I in children, with an incidence of 23%. In type IV lesions, the radial head dislocation is combined with fractures of both the ulna and the radius. Type IV lesions are most infrequent, accounting for only 1% of all Monteggia's fractures¹⁸. In children, radial head dislocation may often occur with incomplete or so-called "greenstick fractures".

Occasionally, there may only be a plastic deformity of the ulna¹⁸⁻²⁰. In contrast to adults, conservative therapy may prove successful in the majority of affected children²¹. "Chronic" Monteggia's lesion is a term denoting a radial head dislocation or subluxation persisting for more than 4 weeks, while ulnar fracture has healed with or without angulation¹⁰. In 16%-33% of cases, chronic Monteggia's lesion occurs following an unrecognized acute lesion. In addition, it may be the consequence of an inappropriately treated acute lesion^{10,21}. It has been estimated that radial

Table I. Data of 16 patients who had a chronic Monteggia lesions.

Patient's number	Gender and side	Age et injury (yrs. +month.)	Time from injury to operation (months)	Bado Type	Type of operation	Follow-up time (yrs +month.)	Results-rating system of Morrey
1.	F, L	6+9	5	I	UO+OR	4+3	good
2.	M,R	7+10	48	I	UO+OR*	15+1	good
3.	M,L	6+6	4	I	UO	7+9	good
4.	F,L	8	5	I	UO+OR	14+11	good
5.	FR	5+5	3	IV	UO+RO	12+4	poor
6.	M,R	5+2	12	I	UO	10+1	good
7.	M,L	8+6	13	III	UO+OR	11+1	poor
8.	FR	7+2	6	I	OR	17	satisfactory
9.	FR	6+3	5	I	UO+OR	13+5	good
10.	M,R	6	2	III	UO+OR	12	good
11.	M,L	5+11	9	III	UO+RO	13+8	poor
12.	FL	12+3	9	I	UO+OR	3+11	satisfactory
13.	M,R	5+10	6	I	UO+OR*	3+7	good
14.	M,R	7+5	3	I	UO+OR*	4	good
15.	M,L	12+3	3	I	UO+OR	4	satisfactory
16.	M,L	12+10	5	I	UO+OR	4+2	satisfactory

F- female, L-left, R-right, UO- ulnar osteotomy, OR – open reduction of the radial head,

* -radial head was stabilised by a Kirschner wire, RO- radius osteotomy, yrs.- years,

head redislocation occurs in some 20% of conservatively treated Monteggia's fractures in children¹⁰. Acute type I lesions with a complete oblique fracture pattern are most unstable of Monteggia's lesions^{9,22}. Residual problems occurring in chronic Monteggia's lesions arise from dislocated radial head. These include valgus alignment of the elbow, pain, elbow instability, subluxation of distal radial-ulnar joint, and late neuropathies of the radial, ulnar and median nerves^{10,18,21,23}.

A number of operative methods have been described in the treatment of chronic Monteggia's lesions, which is an indication that there is no ideal method. The operative treatment may include open reduction of the radial head without reconstruction²⁴ of the annular ligament, or with reconstruction using other local tissues such as a part of triceps tendon, deep fascia of the forearm, or a part of fascia lata^{1,2,18,21}. Unfortunately, operative reconstruction of the annular ligament from adjacent tissues often results in the loss of forearm rotation^{10,18}. Both of our patients undergoing annular ligament reconstruction sustained loss of forearm rotation. Osteotomies of the ulna with or without elongation have also been described. They may be performed alone or in combination with open reduction of

radial head. This ulnar osteotomy may be combined with radius osteotomy. Ulnar osteotomy with elongation resolves ulnar angulation and shortening^{10,18,23,25,26}. Both of our patients undergoing only ulnar osteotomy with elongation sustained radial head dislocation and both required repeat reconstructive procedure. Repeat reconstructive procedures were also required in the two patients initially submitted to osteotomy of both the ulna and radius. The final result was poor even after these repeat procedures.

The aim of a case review should be to evaluate the causes of poor results. In this way, we have developed a set of recommendations to consider before undertaking operative reconstruction of chronic lesions. We believe it is important first to determine spatial direction of radial head dislocation and angulation of a poorly healed fracture of the ulna. Osteotomy should be planned in such a way that its direction is opposite to the direction of the malunited fracture angulation. It should be emphasized that open reduction of the radial head is mandatory, as isolated osteotomy of the ulna with elongation is inadequate. Osteotomy of the radial neck is accompanied by a high risk of radial nerve injury. According to our experience with intraoperative exploration of the humeroradial joint, interposed tissue is

Table II. Complications

Patient's number	Type of operation	Complications	Repeat surgery procedures	Number of repeat surgery procedures	Results-rating system of Morrey
1	UO+OR	transient radial nerve palsy	no		good
2	UO+OR*	no	no		good
3	UO	reluxation, ulnar fracture below plate, ulnar non-union	yes	2	good
4	UO+OR	no	no		good
5	UO+RO	permannent partial radial nerve palsy	yes	1	poor
6	UO	reluxation	yes	2	good
7	UO+OR	subluxation	no		poor
8	OR	no	no		satisfactory
9	UO+OR	reluxation	yes	1	good
10	UO+OR	no	no		good
11	UO+RO	reluxation, ulnar non-union	yes	3	poor
12	UO+OR	no	no		satisfactory
13	UO+OR*	no	no		good
14	UO+OR*	no	no		good
15	UO+OR	reluxation	yes	1	satisfactory
16	UO+OR	reluxation	yes	2	satisfactory

UO- ulnar osteotomy, OR – open reduction of the radial head,

*-radial head was stabilised by a Kirschner wire, RO- radius osteotomy, yrs.- years

quite frequently encountered. This additionally supports the concept according to which radial head reduction should be performed as an open surgical procedure to ensure fully congruent reduction. Reconstruction of annular ligament from any remnants of the original ligament should be attempted first. Reconstruction from the surrounding tissue fragments often results in the loss of forearm rotation.

We believe that in the three patients with recurrent radial head dislocation despite repeat procedures of open reduction of the radial head in combination with corrective ulnar osteotomy, appropriate stabilization of the radial head failed to be initially achieved. While fixation with Kirschner wire through the humerus into the proximal radius bears a risk of complications, it appears to significantly reduce the risk of recurrent dislocation of the radial head²⁴. Although referring to a small number of patients, we consider it significant that no dislocations occurred in the four patients in whom the open reduction of radial head had been followed by fixation with Kirschner wire.

In our series, best results were achieved in the three patients in whom there ulnar osteotomy overcorrection was combined with open reduction of radial head that was additionally stabilized by Kirschner wire fixation through the humerus into the radius.

Operative treatment of chronic Monteggia's lesions bears a very high risk of complications such as contractures, redislocation, lesions of radial, ulnar median nerves, and nonunion at the site of ulnar osteotomy^{18,21}. The number of complications and repeat procedures in our series was very high. It is felt that it was partially caused by the inappropriate choice of surgical procedure.

The postoperative analysis of our cases has led to a conclusion that the choice of operative procedure is very important in the surgical treatment of chronic Monteggia's lesions. All residual deformities have to be treated surgically. In case of residual ulnar angulation, corrective osteotomy with slight overcorrection in a direction opposite to the original deformity direction is necessary. Operative reduction of radial head should be accompanied by Kirschner wire stabilization in all cases. Reconstruction of the annular ligament may occasionally be done using annular ligament remnants, and if not, then annular ligament has to be reconstructed with a part of triceps tendon. In case of radial head instability, temporary Kirschner wire stabilization is required. This fixation with Kirschner wires involves passing it through the capitellum of distal humerus into the center of the radial head. An alternative is to

pass the wire obliquely through the radial neck to the adjacent proximal ulna.

Each case should be individually evaluated, taking into account the child's age, radial head appearance and type of lesion. Generally, the patient should be less than twelve years of age and free from any radial head changes such as overgrowth or secondary deformity where the articular surface is no longer concave²⁷. If the shape of the radial head has been preserved, the time elapsed between the injury and the reconstructive surgery is not essential. In our series, there was a patient in whom an excellent result was achieved by operative reduction of the radial head and corrective ulnar osteotomy performed 4 years after the injury.

And the last but not the least: like most other diseases and injuries, prevention is of utmost importance^{18,21,28-30}. In all forearm fractures, clinical examination is crucial. In addition to neurovascular status evaluation, it should include thorough clinical examination of the entire forearm from the elbow to the wrist. It is an imperative to include the elbow and the wrist in radiologic assessment²¹. In the treatment of acute Monteggia's lesions, good radiologic follow up is important. The surgeon should keep in mind that unstable fractures of the ulna are associated with a high incidence of radial head redislocation^{18,21,29}.

The authors would like to thank dr. Kaye Wilkins for his valuable contributions to discussion and critical review of the manuscript.

References

1. BELL TAWSE AJS. The treatment of malunited anterior Monteggia fractures in children. *J Bone Joint Surg [Br]* 1965;4:718-23.
2. LOYD-ROBERTS GC, BUCKNILL TM. Anterior dislocation of the radial head in children: aetiology, natural history and management *J Bone Joint Surg [Br]* 1977;4:402-7.
3. BOYD HB, BOALS JC. The Monteggia lesions. A review of 159 cases. *Clin Orthop* 1969;66:94-100.
4. HIRAYAMA T, TAKEMITSU Y, YAGIHARA K, MIKITA A. Operation for chronic dislocation of the radial head in children. *J Bone Joint Surg [Br]* 1987;4:639-42.
5. INOUE G, SHIONOYA K. Corrective ulnar osteotomy for malunited anterior Monteggia lesions in children. *Acta Orthop Scand* 1998;1:73-6.
6. BOUYALA JM, BOLLINI G, JACQUEMIER M, CHRESTIAN P, TALLET P, TISSERAND P, MOUTTET A. Le traitement des luxations anciennes de la tete radial chez l'enfant par l'osteotomie haute du cubitus. *Rev Chir Orthop* 1988;74:173-82.
7. MADSON-MOLLER B, HVID I, SOEJBJERG O. Ulnar osteotomy for reduction of chronic anterior dislocated radial head in children. In: Conference Book of 23rd Meeting of European Paediatric

- Orthopaedic Society. Geneva: European Paediatric Orthopaedic Society, 2004:57.
8. EXNER GU. Missed chronic anterior Monteggia lesion. Closed reduction by gradual lengthening and angulation of the ulna. *J Bone Joint Surg [Br]* 2001;83:547-50.
 9. STOLL TM, WILLIS RB, PATERSON DC. Treatment of the missed Monteggia fracture in the child. *J Bone Joint Surg [Br]* 1992;3:436-40.
 10. RODGERS WB, WATERS PM, HALL JE. Chronic Monteggia lesions in children. *J Bone Joint Surg [Am]* 1996;9:1322-9.
 11. HERTEL P, BERNARD M, MOAZAMI-GOUDARZI Y. The malunited juvenile fracture – Monteggia defect. *Orthopade* 1991;6:341-5.
 12. NAKHOSTINE M, ENGELHARDT P. Possibilities for treating chronic radius head dislocations. *Helv Chir Acta* 1991;1:113-8.
 13. ONER FC, DIEPSTRATEN AF. Treatment of chronic post-traumatic dislocation of the radial head in children. *J Bone Joint Surg [Br]* 1993;4:577-81.
 14. WEISMAN DS, RANG M, COLE WG. Tardy displacement of traumatic radial head dislocation in childhood. *J Pediatr Orthop* 1999;4:523-6.
 15. Von LAER L, PIRWITZ A, VOCKE AK. Post-traumatic problems involving the elbow in children. *Orthopade* 1997;12:1030-6.
 16. MORREY BF, BRYAN RS, DOBYNS JH, LINSCHIED RL. Total elbow arthroplasty. A five-year experience at the Mayo Clinic. *J Bone Joint Surg [Am]* 1981;7:1050-63.
 17. BADO JL. The Monteggia lesion. *Clin Orthop* 1967;50:71-86.
 18. STANLEY EA, de la GARZA JF. Monteggia fracture-dislocation in children. In: BEATY JH, KASSER JR, eds. *Fractures in children*. 5th Edition. Philadelphia: Lippincott Williams and Wilkins, 2001:530-1.
 19. WILEY JJ, GALEY JP. Monteggia injuries in children. *J Bone Joint Surg [Br]* 1988;5:728-31.
 20. LETT'S M, LOCHT R, WIENS J. Monteggia fracture-dislocations in children. *J Bone Joint Surg [Br]* 1985;5:724-7.
 21. RING D, JESSE B, JUPITER JB, WATERS PM. Monteggia fractures in children and adults. *J Am Acad Orthop Surg* 1998;6:215-24.
 22. THOMPSON JD, LIPSCOMB AB. Recurrent radial head subluxation treated with annular ligament reconstruction. *Clin Orthop* 1989;246:131-5.
 23. CHEN WS. Late neuropathy in chronic dislocation of the radial head. Report of two cases. *Acta Orthop Scand* 1992;63:343-4.
 24. DEVNANI AS. Missed Monteggia fracture dislocation in children. *Injury* 1997;28:131-3.
 25. SCHEIER H, WIESER R, MUNZIGER U. Invertebrate Monteggia fractures with persisting luxation of the radial head. Reduction of the radial head by osteotomy of the ulna. In: CHAPCHAL G, ed. *Fractures in children*. Stuttgart: Georg Thieme Verlag, 1981:196-8.
 26. HORII E, NAKAMURA R, KOH S, INAGAKI H, YAJIMA H, NAKAO E. Surgical treatment for chronic radial head dislocation. *J Bone Joint Surg [Am]* 2002;84A:1183-8.
 27. WILKINS KE. Changes in the management of Monteggia fractures. *J Pediatr Orthop* 2002;22:548-54.
 28. DORMANS JP, RANG M. The problem of Monteggia fracture-dislocations in children. *Orthop Clin North Am* 1990;21:251-6.
 29. GLEESON AP, BEATTIE TF. Monteggia fracture-dislocation in children. *J Accid Emerg Med* 1994;3:192-4.
 30. RING D, WATERS PM. Management of fractures and dislocations of the elbow in children. *Acta Orthop Belg* 1996; 62(Suppl 1):58-65.

Sažetak

Zastarjeli Montegini prijelomi u djece

T. Đapić, D. Antičević, R. Bilić i D. Đuvančić

Provedena je retrospektivna analiza rezultata kirurškog liječenja zastarjelih Monteginih prijeloma u 16 djece, 6 djevojčica i 10 dječaka. Prosječna dob u vrijeme rekonstruktivne operacije bila je 7 godina i 8 mjeseci (raspon od 5 godina i 2 mjeseca do 12 godina i 10 mjeseci). Prema Badoovoj klasifikaciji bilo je 12 slučajeva tipa I, 3 tipa III i 1 tipa IV. U 11 slučajeva primijenili smo kombinaciju korektivne osteotomije ulne i krvave repozicije glavice radijusa, u 2 slučaja učinjena je samo korektivna osteotomija ulne, u 2 slučaja kombinacija korektivne osteotomije ulne i radijusa, a u jednom krvava repozicija glavice radijusa uz rekonstrukciju anularnog ligamenta. Vrijeme praćenja iznosilo je prosječno 9 godina i 6 mjeseci (raspon od 3 godine i 10 mjeseci do 17 godina). Prema Morreyevih ljestvici bilo je 9 dobrih, 4 zadovoljavajuća i 3 loša rezultata. Zabilježeno je 11 komplikacija: 2 lezije radijalnog živca, 2 pseudoartroze na mjestu osteotomije ulne, 5 reluksacija i 1 subluksacija, 1 prijelom ulne ispod mjesta osteotomije. Zbog komplikacija ponovno je operirano 7 djece, uključujući oba djeteta kod kojih je bila primijenjena kombinacija osteotomije ulne i radijusa i te oba djeteta kod kojih je bila primijenjena samo korektivna osteotomija ulne. Kirurško liječenje zastarjelih Monteginih prijeloma u našoj seriji je bilo povezano s velikim brojem komplikacija. Smatramo da je glavni uzrok tome bio neprimjeren izbor kirurškog zahvata. Uz ispravljanje deformacije ulne neophodna je i krvava repozicija i stabilizacija glavice radijusa.

Ključne riječi: Montegin prijelom – kirurgija; Montegin prijelom – klasifikacija; Montegin prijelom – komplikacije; Studije praćenja; Dijete