

## ADULT PRIMARY EXTRAGONADAL GERM CELL TUMORS: REPORT OF THREE CASES

Boris Ružić<sup>1</sup>, Davor Trnski<sup>1</sup>, Jordan Dimanovski<sup>1</sup>, Ognjen Kraus<sup>1</sup>, Igor Tomašković<sup>1</sup> and Božo Krušlin<sup>2</sup>

<sup>1</sup>Department of Urology, and <sup>2</sup>Ljudevit Jurak Department of Pathology, Sestre milosrdnice University Hospital, Zagreb, Croatia

**SUMMARY** – Primary extragonadal germ cell tumors are rare neoplasms affecting young males. They usually present with abdominal retroperitoneal, mediastinal mass with varying symptoms. The rarest among these rare extragonadal germ cell tumors are embryonal cell carcinomas. Three cases of embryonal cell carcinomas are presented to show that the clinical presentation of this treatable tumor in this patient population may be quite unusual and difficult to diagnose. Differentiation between primary extragonadal tumors and metastasis of testicular primary tumor is essential but may be difficult in many instances.

**Key words:** *Neoplasms, germ cell and embryonal – pathology; Neoplasms, germ cell and embryonal – diagnosis; Treatment outcome*

### Introduction

Primary extragonadal germ cell tumors (EGGCT) are rare neoplasms affecting predominantly young males. Histologically, they are identical to testis germ cell tumors. They have a poor prognosis, different behavior, and natural course as compared to their gonadal counterparts<sup>1,2</sup>. Extragonadal germ cell carcinoma accounts for 3% to 5% of all germ cell carcinomas. Preferentially found in middle line structures, they may arise at sites such as the mediastinum, retroperitoneal area, sacrococcygeal area, or pineal area without primary tumor of the testis<sup>3,4</sup>. The most common localization of EGGCT is the mediastinum (50%-70%), followed by the retroperitoneum (30%-40%), the pineal gland (5%) and the sacrococcygeal area (less than 5%). Other less common sites include the orbit, suprasellar area, palate, thyroid, submandibular region, anterior abdominal wall, stomach, liver, vagina, and prostate<sup>1-5</sup>.

In children, benign and malignant EGGCT occur equally in males and females. In adults, only benign EGGCT (teratomas) occur at an equal frequency in both sexes;

more than 90% of malignant EGGCT occur in males. Although their incidence peaks in the third decade of life, several cases in patients older than 60 have been reported<sup>6,7</sup>.

The origin of EGGCT remains controversial. Whether they develop primarily on the midline or they are metastases of primary testicular tumor has long been debated<sup>8,9</sup>. The classical theory suggests that germ cell tumors in these areas are derived from local transformation of primordial germ cells misplaced during embryogenesis<sup>1,6</sup>.

EGGCT show the same histologic features as gonadal germ cell tumors. Histologically, they mirror their gonadal counterparts with which they share the same chemosensitivity and radiosensitivity<sup>1,2,6</sup>.

EGGCT can be benign (teratoma) or malignant. The latter group can be divided into seminomas and nonseminomas which include yolk-sac tumors, embryonal carcinoma, malignant teratoma, choriocarcinoma, and mixed germ cell tumors<sup>1,6</sup>. Seminomas account for 30%-40%, and nonseminomatous germ cell tumors for 60%-70% of these tumors. Embryonal cell carcinomas are among the rarest forms and account for less than 2% of these tumors<sup>1,5,10</sup>.

The symptoms vary depending on the site and size of the tumor. Those arising in nonvital organs can reach large sizes before becoming symptomatic, but small tumors may result in major symptoms if they obstruct, compress or

Correspondence to: *Boris Ružić, M.D.*, Department of Urology, Sestre milosrdnice University Hospital, Vinogradska c. 29, HR-10000 Zagreb, Croatia

E-mail: [boris.ruzic@zg.htnet.hr](mailto:boris.ruzic@zg.htnet.hr)

Received October 20, 2003, accepted January 7, 2003

rupture into important structures. Mediastinal EGGCT patients may present with chest pain, dyspnea, superior vena cava syndrome, cough, postobstructive pneumonia, weight loss, fever, night sweats, dysphagia, arm pain and vocal cord paralysis. Retroperitoneal EGGCT is the second most common localization (30%-40%) after the mediastinum. Patients with retroperitoneal EGGCT often present late, after their tumors have reached large dimensions. The presenting symptoms are abdominal mass with or without pain, backache and weight loss<sup>1,6</sup>.

The diagnosis of EGGCT requires complete physical examination. Gonadal origin should be excluded by careful testicular examination and ultrasound. Mediastinal EGGCT may be silent. In one third of patients, the anterior mediastinal mass is an incidental finding on routine chest x-ray. A large abdominal mass may be palpated in retroperitoneal EGGCT.

#### **Laboratory studies**

These include beta human chorionic gonadotropin (beta HCG) and alpha fetoprotein (AFP) tumor markers. These tumor markers provide diagnostic, staging, and prognostic information. Choriocarcinoma, embryonal carcinoma, and a minority of seminomas (<10%) produce beta HCG. AFP elevations are seen in yolk-sac tumors and embryonal carcinoma. AFP, beta HCG, or both are elevated in approximately 85% of nonseminomatous EGGCT.

#### **Imaging studies**

Testicular ultrasound should be ordered whenever a malignant germ cell tumor is diagnosed, thus to rule out a gonadal primary tumor. Computed tomography (CT) scan or magnetic resonance imaging (MRI) of the chest, abdomen and pelvis should be done.

#### **Other tests**

Biopsy of the tumor mass should be performed. Histologic confirmation may be obtained by open biopsy of an abdominal and mediastinal mass. Fine-needle aspiration biopsy (FNAB) is frequently performed to make the diagnosis, thus obviating the need of open biopsy<sup>1,5,6,10</sup>.

Modern approaches to the diagnosis and treatment can result in high rates of longterm survival and even cure. Treatment modality is chosen according to the site and histologic type of the primary tumor. Seminomas are very sensitive to chemotherapy and radiotherapy. Nonseminomatous EGGCT (NS-EGGCT) are less sensitive to these modalities and may require surgery for resection of

a postchemotherapy residual mass. Prior to the availability of cisplatin-based chemotherapy, cure rates for NS-EGGCT were less than 10%. Cisplatin-based chemotherapy has made a significant improvement in the treatment of seminoma of the mediastinum. Treatment with 4 cycles of cisplatin, etoposide and bleomycin (PEB) is the current standard of care. Radiotherapy can be used after chemotherapy in bulky mediastinal seminomas.

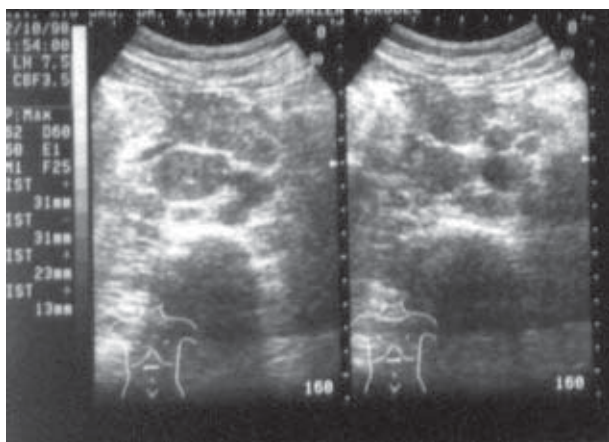
Extragenadal seminomas have a better prognosis than nonseminomas<sup>11</sup>. Patients with pure seminomatous EGGCT histology have a longterm chance of cure of almost 90% irrespective of the primary tumor site<sup>12</sup>. Patients with mediastinal nonseminomas have five-year survival rate of 45%. This outcome is clearly inferior compared to patients with nonseminomatous retroperitoneal primary tumors who have a five-year survival rate of 62%<sup>13</sup>. Mediastinal nonseminomas have certain unique aspects. They are more frequent in individuals with Klinefelter's syndrome and are associated with a risk of subsequent development of hematologic neoplasia that is not treatment related. Approximately 50% will survive with appropriate management. The high risk is partially related to tumor bulk, to chemotherapy resistance, and to the predisposition to develop hematologic neoplasia and other non-germ cell malignancies. The prognosis of retroperitoneal nonseminoma is reasonably good and, similar to the situation with nodal metastasis from a testicular primary tumor, is related to tumor volume<sup>14-16</sup>.

The higher the initial serum levels of AFP and beta HCG, the worse the effect on survival. The pathology of postchemotherapy residual masses reveals necrosis in 24%, teratoma in 45%, sarcoma in 5%, and viable germ cell cancer in 26% of cases. However, the smaller the residual mass, the lower the chance that it harbors viable tumor cells<sup>11</sup>.

#### **Case Reports**

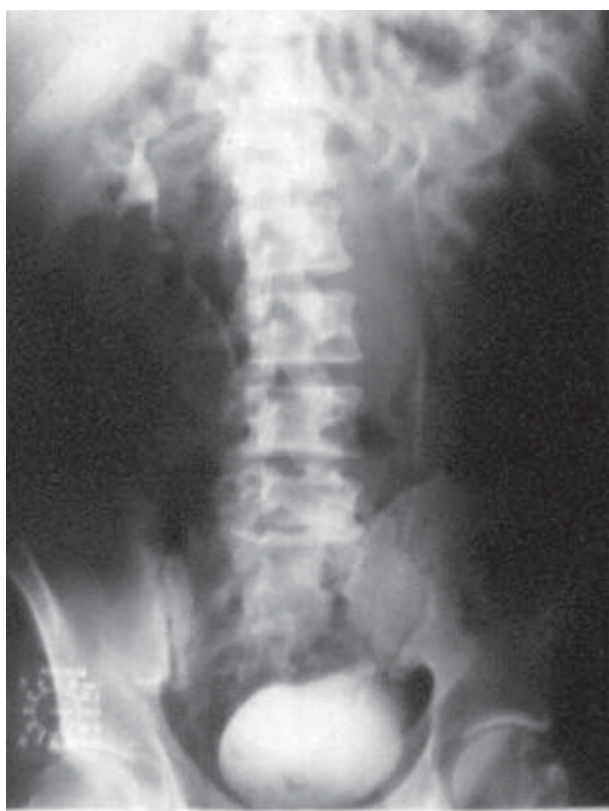##### **Case 1**

A 31-year-old male patient was referred to our hospital for constant back pain. Although he had previously been operated on for herniated disk, there were no signs of recurrence or new spinal pathology. Extended examination included abdominal ultrasound, which revealed multiple enlargements of retroperitoneal lymph nodes (Fig. 1). Elevated levels of testicular tumor markers (AFP=214.7 ng/mL and beta HCG=6950 IU/L) brought the patient to urologist. Neither testicular examination nor scrotal ultrasound of the testicles showed any pathologic findings. Intravenous urography revealed moderate dilatation and

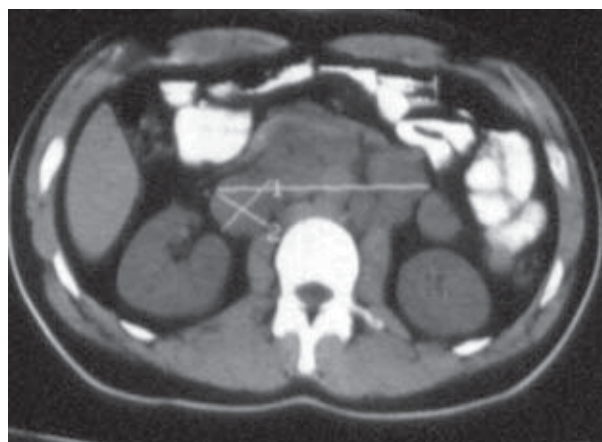

*Fig. 1. Ultrasonographic images showing a large heterogeneous retroperitoneal tumor.*

impression of the middle third of the right ureter (Fig. 2). Chest x-ray was normal. CT showed enlarged lymph nodes, 2.5 cm in diameter, around vena cava and aorta extending from renal hilum to aortal bifurcation. There was a single

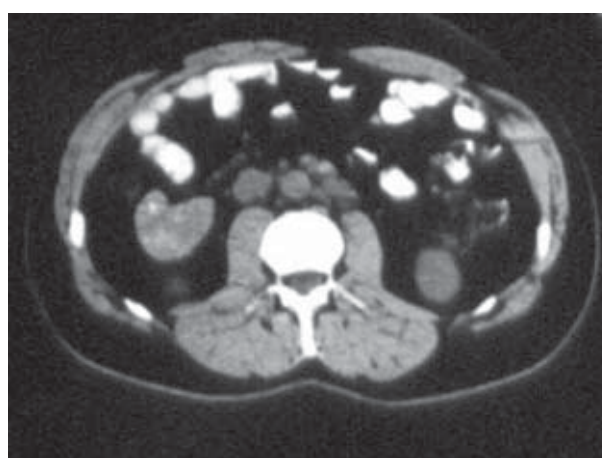


*Fig. 2. Intravenous urography showing impression of the middle third of the right ureter.*

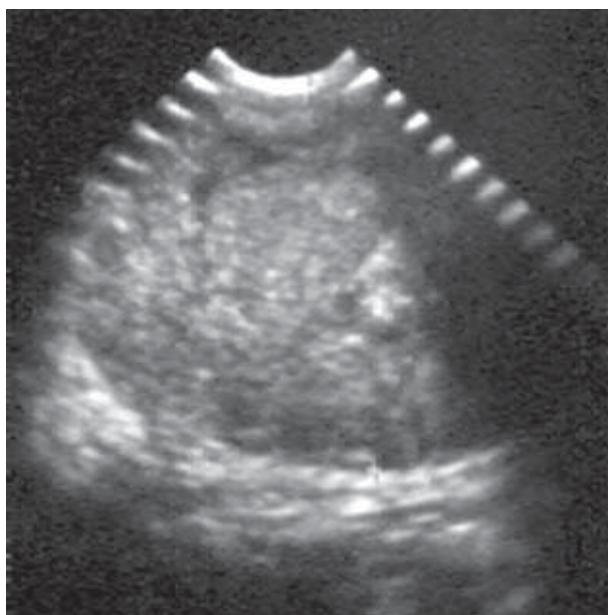


*Fig. 3. Computed tomography scan of the abdomen showing a large, well-defined, lobulated, heterogeneously enhancing soft tissue mass around the vena cava and aorta.*

nodal package of 10 cm in diameter (Fig. 3). Results of the retroperitoneal tumor ultrasound guided FNAB were consistent with poorly differentiated embryonal carcinoma. The patient was treated with 4 cycles of PEB chemotherapy. AFP fell to 3.07 ng/mL and beta HCG to 0 IU/L. Chest x-ray was normal. CT showed reduction in the size of retroperitoneal lymph nodes to less than 2 cm (Fig. 4). Additional 2 cycles of chemotherapy resulted in complete regression of nodal enlargement. Regular periodic checkups showed no signs of tumor recurrence, and at 5 years of follow-up after treatment the patient did well.



*Fig. 4. Computed tomography scan showing reduction in the retroperitoneal lymph node size after 4 cycles of PEB chemotherapy.*



*Fig. 5. Ultrasonographic image showing enlarged supraclavicular solid mass with a homogeneous echoic pattern.*

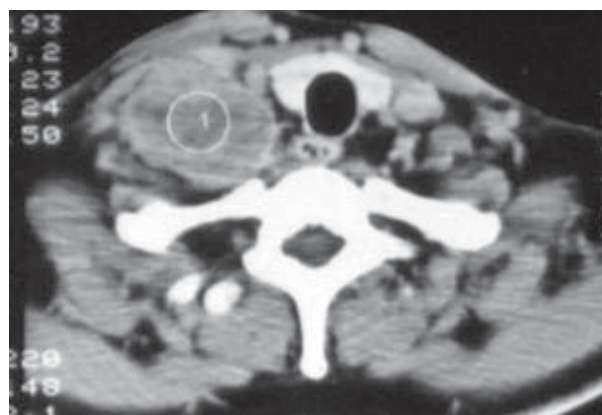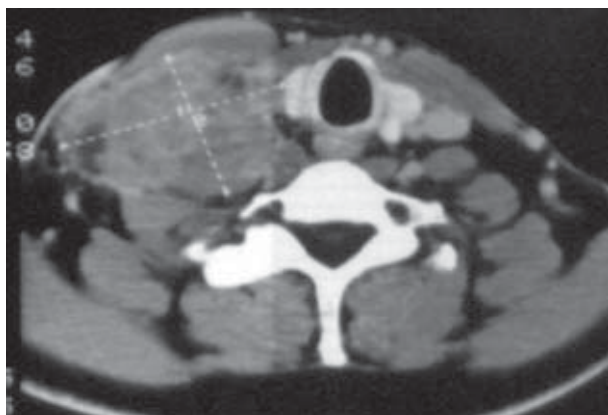
### Case 2

A 37-year-old man presented with left supraclavicular growing mass. On physical examination, it embedded the entire supraclavicular fossa. Ultrasonography revealed a solid mass of 150x120 mm, with a homogeneous echoic pattern (Fig. 5). CT scan of the neck showed a large, well-defined, lobulated, heterogeneously enhancing soft tissue mass (Fig. 6). Lymph node metastasis of some malignant neoplasm was highly suspected. Extirpation of the supraclavicular mass was performed and pathologic diagnosis

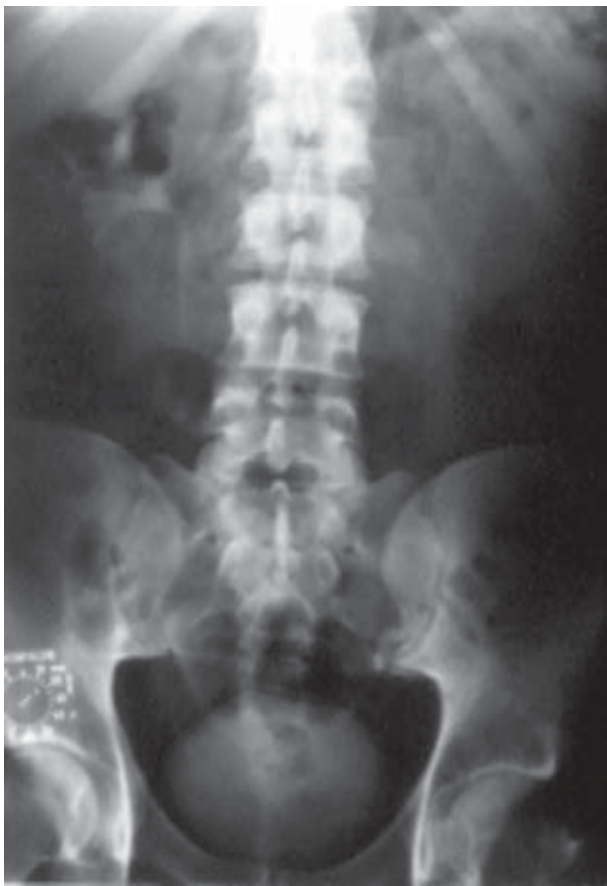indicated embryonal cell carcinoma. Ultrasonographic evaluation of the testicles produced normal finding. The AFP and HCG tumor markers were elevated (AFP=238 ng/mL; beta HCG=negative). Histologic examination of the testicular biopsy specimen showed no malignancy. Whole body CT scan revealed no pathologic findings. The mass was finally diagnosed as primary EGGCT. The patient received 4 courses of PEB chemotherapy. There was no evidence of recurrence over a 5-year period after treatment.

### Case 3

A 32-year-old male complained of severe left-sided abdominal pain and lumbago. He lost 15 kg over a 4-month period. Chest x-ray was normal. Intravenous urography showed left renal afuction and undefined contours of the psoas muscle (Fig. 7). Retrograde urography showed lateral dislocation of the left ureter, suggestive of retroperitoneal tumor (Fig. 8). As regular diagnostic algorithm was not indicative of any diagnosis, CT was performed. It showed a retroperitoneal tumor on the left of the aorta, of 4x5 cm in diameter, extending from renal hilum to aortic bifurcation (Fig. 9). Physical and ultrasonographic examination revealed left testicular atrophy, while the right testicle was normal. Beta HCG was 35 IU/L, and AFP exceeded 9900 ng/mL. Retroperitoneal tumor FNAB indicated embryonal carcinoma. No malignant cells were detected on either testicle biopsy. The scheduled surgical intervention was forestalled by sudden death caused by pulmonary embolism. On autopsy, a 4-cm long tumor thrombus completely obstructing pulmonary artery was found (Fig. 10). The inferior vena cava was occupied by an 8-cm long thrombus extending to the origin of both renal veins. Pathohistologic diagnosis of the retroperitoneal tumor was



*Fig. 6. Two computed tomography scans showing left supraclavicular tumor.*

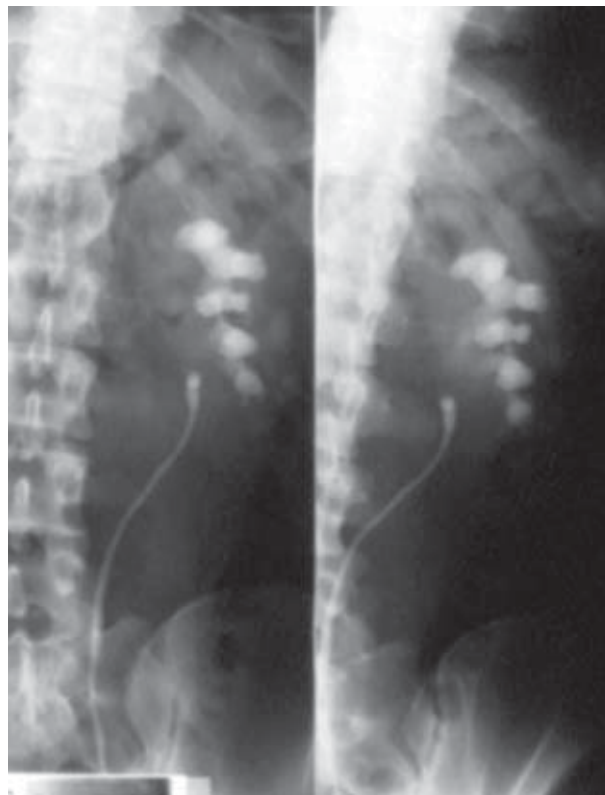


*Fig. 7. Intravenous urography showing left renal dysfunction.*

poorly differentiated embryonal carcinoma. Final pathohistologic examination showed no tumor cells in either testicle.

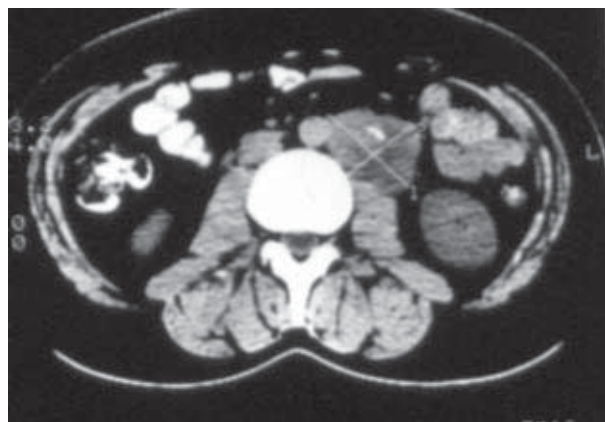
### Conclusions

Clinicians should take into consideration EGGCT in all metastatic tumors of unknown origin in young males. Meticulous physical examination and ultrasound of testicles should be undertaken in all cases of cervical lymph node enlargement, abdominal mass or mediastinal lymphadenopathy on chest x-ray in men. Evaluation of the AFP and beta HCG tumor markers is mandatory. The presented case reports show that clinical presentation of this treatable tumor in this patient population may be quite unusual and difficult to diagnose. Differentiation between primary extragonadal tumors and metastasis of primary testicular tumor is essential, but may be difficult in many instances. On the basis of these three case reports, we can assert that primary germ cell tumors may arise in the mediasti-



*Fig. 8. Retrograde urography showing lateral dislocation of the left ureter.*

num, retroperitoneum and neck. The treatment of choice is chemotherapy, followed by radical surgery. The prognosis of these tumors, which are always large at diagnosis, seems to be relatively good, however, a prolonged follow-up with repeated measurements of tumor markers is needed.



*Fig. 9. Computed tomography scan showing a bulky mass in the retroperitoneum.*

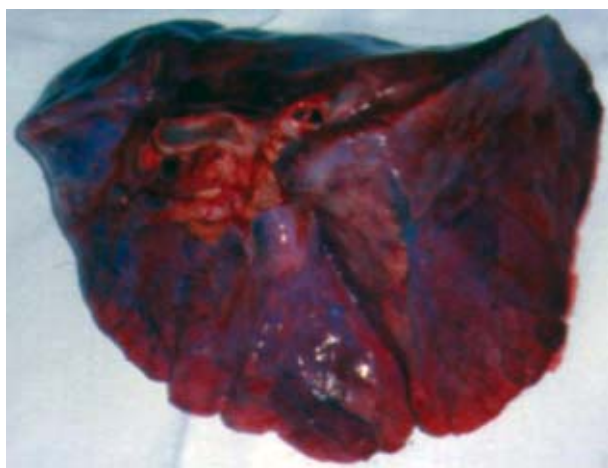

Fig. 10. A tumor thrombus completely occluding pulmonary artery.

## References

1. ABELOFF MD, ARMITAGE JO, LICHTERAS, *et al.* Clinical oncology. 2<sup>nd</sup> ed. New York: Churchill Livingstone; 2000.
2. ANDAC A, MERT B, SEVIL B, URAK S, HALUK O. Adult primary extragonadal germ cell tumors: treatment results and long-term follow up. *Med Pediatr Oncol* 2003;41:49-53.
3. HSU YJ, PAI L, CHEN YC, HO CL, KAO WY, CHAO TY. Extragonadal germ cell tumors in Taiwan: an analysis of treatment results of 59 patients. *Cancer* 2002;95:766-74.
4. BERKMEN F, PEKER AF, AYYILDIZ A, BASAYS, ARIKAI, UGUR I. Extragonadal germ cell tumors: clinicopathologic findings, staging and treatment experience in 14 patients. *J Exp Clin Cancer Res* 2000;19:281-5.
5. HAINSWORTH JD, GRECO FA. Extragonadal germ cell tumors and unrecognized germ cell tumors. *Semin Oncol* 1992;19:119-27.
6. CHAGANTI RS, HOULDSWORTH J. Genetics and biology of adult human male germ cell tumors. *Cancer Res* 2000;60:1475-82.
7. MAYORDOMO JI, PAZ-ARES L, RIVERA F, *et al.* Ovarian and extragonadal malignant germ-cell tumors in females: a single-institution experience with 43 patients. *Ann Oncol* 1994;5:225-31.
8. SCHOLZ M, ZEHENDER M, THALMANN GN, BORNER M, THONI H, STUDER UE. Extragonadal retroperitoneal germ cell tumor: evidence of origin in the testis. *Ann Oncol* 2002;13:121-4.
9. INCARBONE GP, POLETTI F, SALSI P, SEBASTIO N, CORTELLINI P, GABRIELLI M. Report of 2 cases of extragonadal germ cell neoplasia with primary burnt out tumor of the testis. *Acta Biomed Ateneo Parmense* 2000;71:53-7.
10. GRECO FA, VAUGHN WK, HAINSWORTH JD. Advanced poorly differentiated carcinoma of unknown primary site: recognition of a treatable syndrome. *Ann Intern Med* 1986;104:547-53.
11. DUELAND S, STEINWEG AE, HEILO A. Treatment and outcome of patients with extragonadal germ cell tumors – the Norwegian Radium Hospital's experience 1979-94. *Br J Cancer* 1998;77:329-35.
12. BOEKMEYER C, NICHOLS CR, DROZ JP, *et al.* Extragonadal germ cell tumors of the mediastinum and retroperitoneum: results from an international analysis. *J Clin Oncol* 2002;20:1864-73.
13. BOEKMEYER C, HARTMANN JT, FOSSA SD, *et al.* Extragonadal germ cell tumors: relation to testicular neoplasia and management options. *APMIS* 2003;111:49-59.
14. NICHOLS CR, HEEREMAN, PALMER C, *et al.* Klinefelter's syndrome associated with mediastinal germ cell neoplasms. *J Clin Oncol* 1987;5:1290-4.
15. NICHOLS CR, ROTH BJ, HEEREMAN, *et al.* Hematologic neoplasia associated with primary mediastinal germ-cell tumors. *N Engl J Med* 1990;322:1425-9.
16. NICHOLS CR, SAXMAN S, WILLIAMS SD. Primary mediastinal nonseminomatous germ cell tumors. A modern single institution experience. *Cancer* 1990;65:1641-6.

## Sažetak

### PRIMARNI EKSTRAGONADNI TUMORI ZAMETNIH STANICA U ODRASLIH: PRIKAZ TRIJU SLUČAJEVA

B. Ružić, D. Trnski, J. Dimanovski, O. Kraus, I. Tomašković i B. Krušlin

Primarni ekstragonadni tumori su rijetke neoplazme koje pogađaju uglavnom mlađe muškarce. Obično se očituju kao abdominalne retroperitonejske ili mediastinalne mase s različitim simptomima. Najrjeđi među rijetkim ekstragonadnim tumorima zametnih stanica su embrionalni karcinomi. Tri prikazana slučaja embrionalnih karcinoma pokazuju da kliničko očitovanje ovih tumora može biti neuobičajeno, a postavljanje dijagnoze otežano. Razlikovanje primarnih ekstragonadnih tumora i metastaza primarnog tumora testisa je ključno, ali u mnogim slučajevima problematično.

Ključne riječi: *Neoplazme, zametnih stanica i embrionalne – patologija; Neoplazme, zametnih stanica i embrionalne – dijagnostika; Ishod liječenja*