

PROGNOSTIC VALUE OF CLINICAL AND HISTOPATHOLOGICAL PARAMETERS OF UVEAL MELANOMAS: A RETROSPECTIVE STUDY

Ksenija Karaman¹, Kajo Bučan¹, Valdi Pešutić-Pisac², Igor Žuljan¹, Ljubo Znaor¹, Alen Siničić¹, Ivana Vujčić¹ and Marin Kuzmanić¹

¹University Department of Ophthalmology; ²Department of Pathology, Split University Hospital, Split, Croatia

SUMMARY – The aim of the study was to determine clinical and histopathologic prognostic factors for tumor related survival of patients with uveal melanoma. Clinical and histopathologic records of 20 patients with histologically verified uveal melanomas were retrospectively analyzed. Patients were operated on at University Department of Ophthalmology, Split University Hospital in Split, January 1, 1991 and December 31, 2000. Histopathologic confirmation was obtained from the Hospital Department of Pathology, Forensic Medicine and Cytology, Split University Hospital. Standard histological staining with hemalaun and immunohistochemical staining with primary antibody against melanoma antigen and S-100 protein were performed. Data on the cause of death were collected from death certificates obtained from Hospital Department of Pathology, Forensic Medicine and Cytology and from Split Population Registry, Split-Dalmatia County government. The overall annual incidence of uveal melanoma in Split-Dalmatian County was 0.44 *per* 100,000. Out of 20 intraocular melanomas, 4 (20%) were located at the ciliary body, 13 (65%) at the choroid, and 3 (15%) at the ciliary body and at the choroid. There was no statistically significant survival difference between groups with different tumor localization ($\chi^2=2.747$; $df=3$; $p=0.253$). The largest tumor diameter was 35 mm and the smallest 9 mm (median 12 mm), and there was no statistically significant correlation between tumor diameter and survival (Spearman's correlation 0.21).

Histological study revealed pure spindle A type melanoma in one (5%) case, pure spindle B type melanoma and pure epithelioid type melanoma in 4 (20%) cases each, and mixed type melanoma in 11 (55%) cases. There was no statistically significant survival difference between groups of patients with different histopathologic types of melanoma ($\chi^2=5.312$; $df=4$; $p=0.150$). Study results indicated that none of the study parameters (localization, tumor diameter and histopathology finding) could be considered a valid prognostic factor of uveal melanoma survival.

Key words: *humans; incidence; melanoma; uveal neoplasms; mortality rate; Croatia*

Introduction

Primary uveal melanoma is the most common primary intraocular malignant tumor in adults, with metastatic potential. The last reported annual incidence in the USA was 4.3 *per* million¹. Almost always it develops as unilateral and unifocal tumor². Ocular melanocytosis is a congenital condition characterized by melanocytic

hyperpigmentation of the episclera and uvea, affecting approximately 0.04% of the Caucasian population³. It is generally accepted that ocular melanocytosis implies an increased risk of uveal melanoma^{4,6}. The tumor is rare in children and primarily affects patients aged 60-70. Various clinical, histopathologic, and molecular genetic prognostic factors for survival have been determined⁷. The 5-year mortality rate after enucleation ranges from 16% to 53%, depending on tumor dimensions⁸.

The aim of this retrospective study was to determine the incidence of primary uveal melanoma in Split-Dalmatia County, Croatia; to evaluate clinical and his-

Correspondence to: *Professor Ksenija Karaman, MD, PhD*, University Department of Ophthalmology, Split University Hospital, Spinčićeva 1, HR-21000 Split, Croatia
e-mail: ksenija.karaman@kbsplit.hr

Received January 30, 2007, accepted March 26, 2007

topathologic prognostic factors for tumor related survival of patients with uveal melanoma; and to assess the 5-year mortality rate following enucleation due to uveal melanoma.

Patients and Methods

The clinical and histopathologic records of 20 patients with histologically verified uveal melanoma were retrospectively analyzed. Patients were operated on (enucleation) at University Department of Ophthalmology, Split University Hospital, between January 1, 1991 and December 31, 2000. Histopathologic findings were obtained from the Hospital Department of Pathology, Forensic Medicine and Cytology. Standard histologic staining with hemalaun and immunohistochemical staining with primary antibody against melanoma antigen and S-100 protein were performed.

Data on the cause of death were collected from death certificates kept at Hospital Department of Pathology, Forensic Medicine and Cytology, and Split Population Registry, Split-Dalmatia County government.

Statistical analysis was performed by use of the Statistica 6 software (StatSoft, USA). χ^2 -test and Spearman's correlation were used to analyze between-group difference and correlation, respectively. We also calculated between-group survival difference. The level of significance was set at $p < 0.05$.

Results

The study included 11 (55%) male and nine (45%) female patients. As the Hospital catchment population is the Split-Dalmatia County population of 463,676⁹, the overall annual incidence of primary uveal melanoma was 0.44 *per* 100,000. At the diagnosis of uveal melanoma, the youngest patient was aged 32 and the oldest 84 (median 66). Out of 20 diagnosed intraocular melanomas, 4 (20%) were located on the ciliary body, 13 (65%) on the choroid, and 3 (15%) on the ciliary body and on the choroid (Fig. 1). We found no iris melanoma. There was no statistically significant difference in survival between groups with different tumor localization ($\chi^2 = 2.747$; $df = 3$; $p = 0.253$).

The largest tumor diameter was 35 mm and the smallest 9 mm (median 12 mm), and there was no statistically significant correlation between tumor diameter and survival (Spearman's correlation 0.21). Periocular tissue invasion with tumor cells was found in only

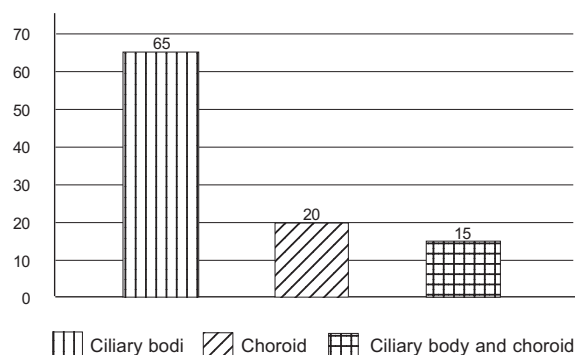


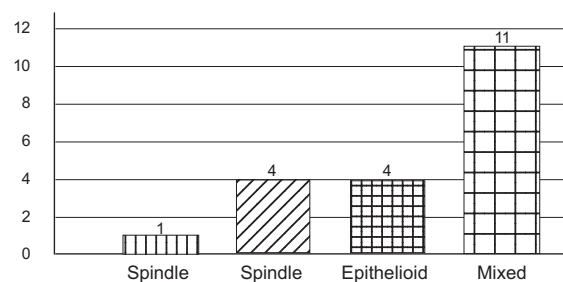
Fig. 1. Localization of uveal melanoma.

two (10%) and regional metastases were found in nine (45%) patients. Three (15%) patients were treated with orbital exenteration, and the rest of patients with enucleation.

Histopathologic indicated pure spindle A type melanoma in 1 (5%) case, pure spindle B type melanomas and pure epithelioid type melanoma in 4 (20%) cases each, and mixed type melanoma in 11 (55%) cases (Fig. 2). There was no statistically significant survival difference between groups of patients with different histopathologic types of melanoma ($\chi^2 = 5.312$; $df = 4$; $p = 0.150$). Five-year mortality rate following enucleation for uveal melanoma study was 65%.

Discussion and Conclusion

Our study showed the overall annual incidence of uveal melanoma to be consistent with that reported for the USA¹. Yet, our 5-year mortality of 65% is among the highest reported in the literature⁸. This could be attributed to the large median of tumor diameter of 12 mm in our patients. On the other hand, the data obtained



$\chi^2 = 5.312$; $df = 4$; $p = 0.150$

Fig. 2. Distribution of patients with uveal melanoma according to four histopathologic types of melanoma (N=20).

showed that none of the study parameters (histopathology, tumor localization and tumor diameter) could be considered a valid prognostic factor for uveal melanoma survival. Local invasion of tumor cells was found in two patients with tumor diameter of 35 mm and 12 mm. As these two cases belonged to the groups with largest and smallest tumor diameter, respectively, it may suggest that local invasion is not correlated to tumor diameter. These findings may be principally indicating that Callender's uveal melanoma classification needs to be amended after being in use unrevised for some 100 years.

References

1. SINGH AD, TOPHAM A. Incidence of uveal melanoma in the United States: 1973-1997. *Ophthalmology* 2003;110:956-61.
2. HONAVAR SG, SHIELDS CL, SINGH AD *et al.* Two discrete choroidal melanomas in an eye with ocular melanocytosis. *Surv Ophthalmol* 2002;47:36-41.
3. GONDER JR, EZELL PC, SHIELDS JA, AUGSBURGER JJ. Ocular melanocytosis. A study to determine the prevalence rate of ocular melanocytosis. *Ophthalmology* 1982;89:950-2.
4. VELAZQUEZ N, JONES IS. Ocular and oculodermal melanocytosis associated with uveal melanoma. *Ophthalmology* 1983;90:1472-6.
5. SINGH AD, De POTTER P, FIJAL BA, SHIELDS CL, SHIELDS JA, ELSTON RC. Lifetime prevalence of uveal melanoma in white patients with ocular(dermal) melanocytosis. *Ophthalmology* 1998;105:195-8.
6. GONDER JR, SHIELDS JA, ALBERT DM, AUGSBURGER JJ, LAVIN PT. Uveal malignant melanoma associated with ocular and oculodermal melanocytosis. *Ophthalmology* 1982;89:953-60.
7. SINGH AD, SHIELDS CL, SHIELDS JA. Prognostic factors in uveal melanoma. *Melanoma Res* 2001;11:255-63.
8. DIENER-WEST M, HAWKINS BS, MARKOWITZ JA, SCHACHAT AP. A review of mortality from choroidal melanoma. II. A meta-analysis of 5-year mortality rates following enucleation, 1966 through 1988. *Arch Ophthalmol* 1992;110:245-50.
9. Popis stanovništva 2001. godine. (Census 2001). 2001 (Accessed Oct 10, 2006 at <http://www.dzs.hr/>)

Sažetak

Prognostička vrijednost kliničkih i patohistoloških osobitosti melanoma srednje očne ovojnice: retrospektivna studija

K. Karaman, K. Bućan, V. Pešutić-Pisac, I. Žuljan, Lj. Znaor, A. Siničić, I. Vujčić i M. Kuzmanić

Cilj studije bio je ustanoviti kliničke i patohistološke prognostičke čimbenike preživljenja od melanoma srednje očne ovojnice kod bolesnika s tom bolešću. Provedena je retrospektivna analiza kliničkih i patohistoloških podataka 20 bolesnika s histološki dokazanim melanomom srednje očne ovojnice. Bolesnici su operirani u Klinici za očne bolesti KB Split u razdoblju od 1. siječnja 1991. do 31. prosinca 2000. godine. Melanomi su patohistološki verificirani u Zavodu za patologiju, sudsku medicinu i citologiju KB Split. Primijenjeno je standardno HE (hemalaun-eozin) bojenje i imunohistokemijsko bojenje na melanoma antigen i S-100 protein. Uzrok smrti utvrđen je uvidom u mrtvozorničke prijave o uzroku smrti u Zavodu za patologiju, sudsku medicinu i citologiju KB Split i u Matičnom uredu Split, Uredu državne uprave Splitsko-dalmatinske županije. Godišnja incidencija melanoma srednje očne ovojnice u Splitsko-dalmatinskoj županiji bila je 0,44 na 100.000 stanovnika. Od 20 intraokularnih melanoma, 4 (20%) su imala polazište iz zrakastog tijela, 13 (65%) iz žilnice, a 3 (15%) su bila smještena u zrakastom tijelu i žilnici. Nije nađena statistički značajna razlika u preživljenju prema lokalizaciji tumora ($\chi^2=2,747$; $df=3$; $p=0,253$). Najveći promjer tumora iznosio je 35 mm, najmanji 9 mm (medijan 12 mm). Nije utvrđena statistički značajna korelacija između preživljenja i veličine tumora (Spermanova rang korelacija 0,21). Histološka analiza utvrdila je 1 (5%) melanom vretenastog tipa A, 4 (20%) vretenastog tipa B, 4 (20%) epiteloidnog tipa i 11 (55%) miješanog tipa. Nije dokazana statistički značajna razlika u preživljenju ovisno o patohistološkom tipu tumora ($\chi^2=5,312$; $df=4$; $p=0,15$). Na temelju dobivenih rezultata može se zaključiti kako niti jedan od ispitivanih parametara (lokalizacija, veličina i patohistološki tip tumora) nije valjan prognostički čimbenik preživljenja kod melanoma srednje očne ovojnice.

Ključne riječi: *ljudi; učestalost; melanom; tumori srednje očne ovojnice; stopa smrtnosti; Hrvatska*

