

THE P53 LOSS OF HETEROZIGOSITY IN MULTIPLE PRIMARY CARCINOMAS OF THE KIDNEY, BLADDER, PROSTATE AND COLON

Borislav Spajić¹, Koraljka Gall-Trošelj³, Irena Novosel⁴, Petar Kirac², Zoran Jukić⁵, Ognjen Kraus¹ and Božo Krušlin²

¹Department of Urology and Surgery Sestre milosrdnice University Hospital, Zagreb; ²Ljudevit Jurak University Department of Pathology, Sestre milosrdnice University Hospital, Zagreb; ³Department of Molecular Medicine, Rudjer Bošković Institute, Zagreb; ⁴General Hospital, Sisak; ⁵General Hospital, Nova Gradiška, Croatia

SUMMARY – Due to the rarity of multiple primary synchronous malignancies, the correct and concurring data on their incidence are extremely difficult to find. Recent studies point to renal cell carcinoma as a tumor showing most prominent association with other types of simultaneous or metachronous primary carcinoma. To our knowledge, this is the first case of multiple primary adenocarcinomas of the kidney, prostate, and urothelial carcinoma of the urinary bladder associated with primary sigmoid adenocarcinoma and colostomic metastasis analyzed for p53 loss of heterozygosity.

Key words: *Carcinoma renal cell – pathology; Kidney neoplasms – pathology; Case report*

Introduction

The incidence of multiple primary malignancies with synchronous and/or metachronous occurrence of two or more primary carcinomas is very rare and there is a great need of extensive clinical preventive diagnostic approach to consistent follow-up of previously operated patients for solitary cancer, especially of the kidney or colon¹⁻³. To our knowledge, this is the first case of multiple primary adenocarcinoma of the kidney, prostate, and urothelial carcinoma of urinary bladder associated with primary sigmoid adenocarcinoma.

Case Report

An 80-year-old male patient consulted an urologist for disuric problems, with prominent symptoms of noc-

turia and urine retention. The first ultrasonographic evaluation confirmed urine retention (150 mL), a hyperechogenic mass (~3 cm) on the left bladder wall, hypertrophic prostate (~45 g) and a homogeneous mass of 5.5 cm in diameter on the lower pole of the right kidney. Computerized tomography, intravenous urography and cystoscopy confirmed the presence of tumors of the kidney and bladder.

In October 1999, a combined surgical procedure of transurethral resection of the bladder tumor and radical right nephrectomy was performed. Histologic evaluation of 20 tiny specimens, which varied in length from 0.3 cm to 1.0 cm, revealed a moderately differentiated, papillary urothelial carcinoma of the bladder without muscle layer infiltration. However, invasion of the lamina propria was found. Grossly, the renal tumor was well-circumscribed, yellowish, medium soft in consistency, located on the lower pole of the kidney, with the largest diameter of 5.5 cm. Histologically, it was a renal cell carcinoma consisting of clear and chromophilic eosinophil cell type, nuclear grade 3. Classification according to pTNM-system was: T2NxMx. Afterwards, BCG immunotherapy was introduced.

Correspondence to: *Božo Krušlin, M.D., Ph.D.*, Ljudevit Jurak University Department of Pathology, Sestre milosrdnice University Hospital, Vinogradska c. 29, HR-10000 Zagreb, Croatia
E-mail: bkrušlin@kbsm.hr

Received September 20, 2005, accepted October 25, 2005

In December 1999, during the second admission for complete urinary retention, transurethral resection was performed. Pathohistologic analysis confirmed prostatic adenocarcinoma with Gleason score 5 (3+2) in less than 5% of all examined material. Bone scintigraphy showed no presence of metastases. Preoperatively, T-PSA was 6.1 ng/mL and F/T ratio was 14.6%.

In March 2000, an operation according to Hartmann was performed because of the clinical symptoms of ileus. A tumor mass measuring up to 2.0 cm was found in the sigmoid region. Pathohistologic evaluation confirmed adenocarcinoma (Astler-Coller C2, Dukes C). Resected margins of the colon were free from tumor. Two of seven extirpated pericolic lymph nodes were positive. According to pTNM-system, the tumor was classified as T3N1Mx. Control ultrasonography of the upper abdomen was negative for metastatic disease.

In March 2001, extirpation of colostomic metastasis was done and pathohistologic evaluation confirmed metastatic cancer of the same histologic structure as the one found in the tumor of the sigmoid region.

The patient died in April 2001. On his family demand, autopsy was not performed.

Methods

Specimens were fixed in 10% buffered formalin, embedded in paraffin, cut at 5- μ m thickness, and routinely stained with hematoxylin and eosin. For immunohistochemical detection of *TP53* protein, deparaffinization and immunohistochemical staining was performed following the Microwave Streptavidin ImmunoPeroxidase (MSIP) protocol on a Dako TechMate™ Horizon automated immunostainer according to the manufacturer's instruction. We used monoclonal antibody DO-7 H7123 for *TP53* (Dako, Denmark). The dilution of antibody was "ready to use" and not specifically declared by the manufacturer. Positive control for *TP53* staining was colon carcinoma tissue.

Tissue specimens and genomic DNA extraction. Genomic DNA was extracted from three tumor samples: colon cancer, bladder cancer and kidney cancer. Eight 5- μ m sections were cut from each paraffin block. Two of the cut sections (the first and the eighth) were HE stained. The border between the tumor and nontumorous tissue was marked on stained slices and DNA was extracted separately (tumor *vs.* nontumor) from unstained slices 2-7. All sections were reviewed by the same pathologist.

DNA extraction and PCR. Genomic DNA was extracted as previously described⁴: sections were deparaffinized with two washes in xylene (2x2 hours), xylene was rinsed with ethanol and dried, deparaffinized samples were incubated in digestion buffer (50 mM TRIS-HCl pH 8.5, 1 mM EDTA, 0.5% Tween 20) containing 500 μ g/mL of Proteinase K and incubated for 48 hours at 37 °C. Proteinase K was inactivated at 95 °C for 8 minutes. Amplicons were amplified from 5 μ l of the boiled supernatant in 250 μ L reaction tubes containing 2.5 μ L of Buffer 1 (Eppendorf), 1.5 mM MgCl₂, 10 mM dNTP's (2.5 mM each), 5 pmol of each primer (exon 4F: 5' GATGCTGTCCGCGGACGATAT 3' : exon 4R and 5' CGTGCAAGTCACAGACTTGGC 3' and 1.0 U of Taq polymerase (Eppendorf). The samples were pre-denatured (94 °C for 2 minutes), and subsequently processed in 40 cycles consisting of 40 s at 95 °C, 35 s at 58 °C and 35 s at 72 °C, and final extension at 72 °C for an additional 10 minutes. Amplification of the product was verified by agarose gel electrophoresis stained with ethidium bromide. For an unknown reason, colon cancer sample repeatedly gave very poor yield and therefore amplification of this template was performed with commercial PCR beads Ready to Go (Amersham-Pharmacia).

LOH analysis. Loss of heterozygosity (LOH) in p53 gene was analyzed by the PCR/RFLP (restriction fragment length polymorphism) method based on polymorphic site in exon 4 (*Bst* U1). For RFLP analysis, 10-15 μ L of the PCR products were digested overnight with 20 U of *Bst* UI (NewEngland BioLabs) in a total volume of 25 μ L. The digested PCR products were separated on PAGE and silver stained. Loss of the upper band (247 bp; the original size of the PCR product) or two lower bands (160 bp, 87 bp) in tumor tissue was considered as LOH when compared with the presence of three bands in nontumorous tissue (one cut; 160 + 87 bp, and one uncut allele; 247 bp).

Results

Each tumor presented different profile regarding the p53. No LOH was detected in kidney cancer. Uncut allele was missing in urinary bladder, while cut allele was missing in colon cancer (Fig. 1). These results clearly show that this patient indeed developed three different primary tumors. Unfortunately, no second metachronous tumor (prostate) was available for this study. Immunohistochemistry results were positive on all three

samples as the specified antibody labeled wild-type as well as mutant type p53 (Fig. 2).

Discussion

This case report as well as data published in the literature so far suggest a great importance of continuous, life time follow-up of the patients previously operated on for carcinoma of the urinary tract or colon because of the significant possibility of synchronous and/or metachronous appearance of another primary carcinoma^{1-3,5,6}. Rabbani *et al.*³ report on at least 27% of patients with renal cell carcinoma to have one second primary carcinoma found to be synchronous with renal cell carcinoma in 39% of cases. This finding might be the consequence of slow and silent growth of renal cell carcinoma due to the most often polaric tumor localizations. The second malignant primary tumors occurred most commonly antecedently to renal cell carcinoma in 11 (42.3%) cases in a study by Turčić *et al.*⁶. Gacci *et al.*⁷ describe a patient who refused surgical removal of renal cell carcinoma when it was 3.0 cm in diameter. In the next nine years, the cancer grew up by only 2.4 mm *per* year before provoking any symptoms. Hence, the basis for this phenomenon to occur may indeed be a very long time delay between the kidney cancer occurrence and visible clinical signs of its existence. Very often, the second primary tumor is found inadvertently on CT scans done for determination of the extent of the firstly discovered primary carcinoma¹⁻³.

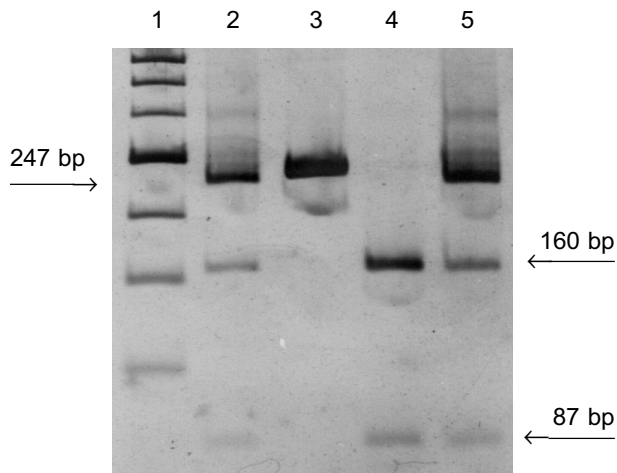


Fig. 1. p53 loss of heterozygosity. Line 1: DNA Marker Roche XIII; line 2: non-tumorous tissue; 3: bladder carcinoma; 4: colon cancer; 5: kidney cancer

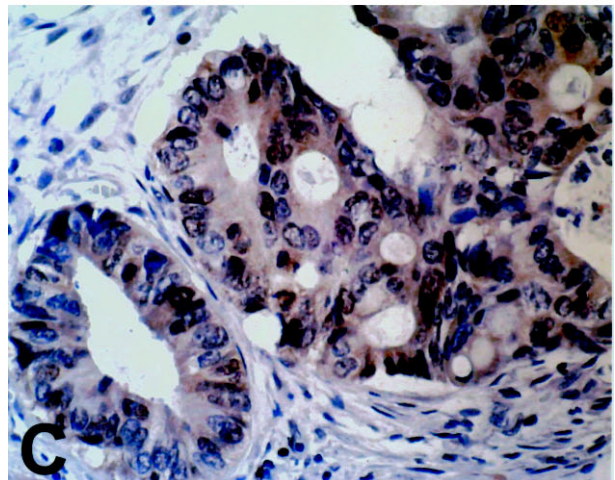
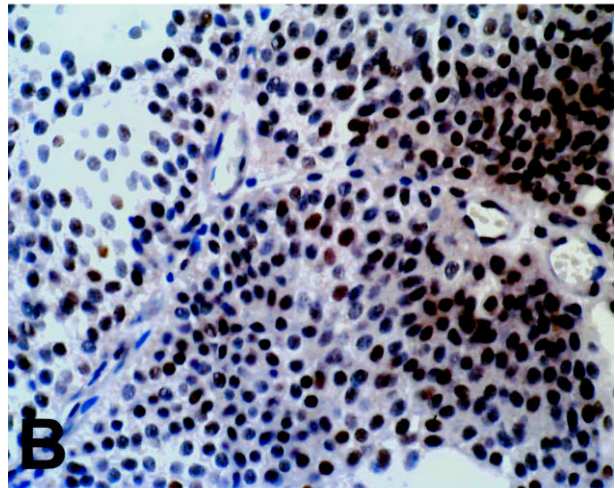
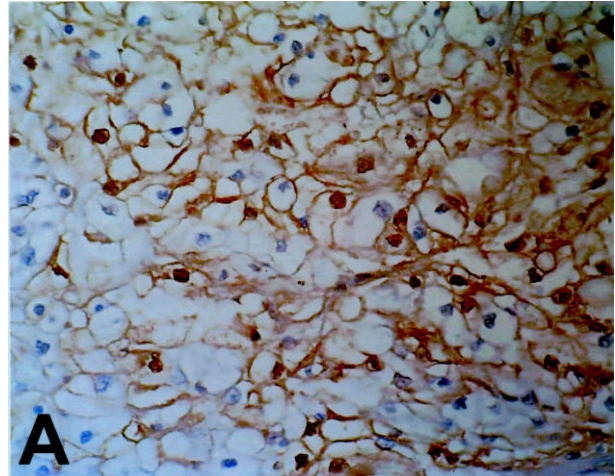


Fig. 2. p53 immunostaining in carcinoma of the kidney (A), bladder (B) and colon (C)

Data on the concurrence of colorectal and renal cell carcinoma incidence vary significantly. Recent studies by Halak *et al.*¹ and O'Boyle and Kemeny² showed an incidence of 0.5% and 4.9%, respectively. Maruyama *et al.*⁵ report that 8.7% of colorectal primary cancers are associated with extracolonic primary malignancy.

Our patient had no positive cancer history in his family. A similar case report describes an elderly patient with synchronous ureteral, bladder, urethral urothelial carcinoma and adenocarcinoma of the prostate⁸. The authors' extensive review of the literature on multiple primary malignant neoplasms show the prevalence to range between 0.7% and 11.7%, and they suggest that the increased number of second primary tumors is mainly due to the increased frequency of prostatic carcinoma in elderly men⁸.

According to the previously mentioned facts and not performing colonoscopy in our patient, which would probably discover sigmoid carcinoma in an earlier stage, we suggest comprehensive diagnostic approach to urinary and gastrointestinal tract in patients primarily operated on for renal cell carcinoma and in those with primary colonic malignancy. Having in mind the relatively false-low incidence of primary multiple synchronous and/or metachronous malignancies, a clinician should perform additional diagnostic treatments as part of the standard procedure: colonoscopy in patients with renal cell carcinoma and ultrasound of the kidney and upper abdomen or even computerized tomography in patients with colonic cancer.

Determination of the molecular relationship between multiple tumors in one patient might have an impact on the clinical management of the patient⁹. Van der Sijp *et al.*⁹ showed that among 25 patients, 12 had probable second primary tumor, 10 had metastasis of the primary lesion, and in 3 patients both an independent primary tumor and a metastasis were present. Sato *et al.*¹⁰ report on a patient with triple synchronous malignant tumors affecting the gallbladder, common bile duct and pancreas. They found p53 positive immunostaining in pancreatic tumor only¹⁰. Their findings suggested that the oncogenic mechanisms of multiple synchronous tumors were not the result of only one abnormal DNA reparative mechanisms. p53 germ-line mutations were identified in the peripheral blood and corresponding cancers of 3 patients who had multiple malignancies of the head and neck region¹¹.

Hence, it seems that analysis of DNA alterations in multiple primary tumors discovers, at least in part, the

relationship between the tumors. Our results based on DNA analysis may indicate that our patient did develop three independent tumors as each tumor had a unique profile regarding p53 RFLP analysis. One intriguing hypothesis may be that colon cancer and kidney cancer did represent primary tumors and interpretation of the results for bladder cancer needs some caution. It is well known that the tissue sample for LOH analysis must be "clear" regarding the normal, nontumorous tissue. However, even if one dissects the surrounding tissue completely, there is no way to avoid the genetic heterogeneity among tumor cells (if something like this exists in the sample tested). Hence, there is a possibility that a small proportion of kidney cancer cells that harbored one allele deletion (and hence were not detected by our LOH analysis) sent the "satellite" downstream. If so, then the proliferated malignant clone in the bladder may have represented a tumor that was secondary to kidney cancer. The challenge that exists in this hypothesis could possibly be clarified by single-cell PCR reactions or analysis of a large number of microsatellite markers (only retained heterozygosity in bladder cancer and LOH in kidney cancer would strongly indicate two primary tumors).

Acknowledgment

The study was supported by grants 0108001/02 (B.K.) and 0098095/02 (K.G-T) from the Ministry of Science and Technology, Republic of Croatia.

References

1. HALAK M, HAZZAN D, KOVACS Z, SHILONI E. Synchronous colorectal and renal carcinomas: a noteworthy clinical entity. Report of five cases. *Dis Colon Rectum* 2000;43:1314-5.
2. O'BOYLE KP, KEMENY N. Synchronous colon and renal cancers: six cases of clinical entity. *Am J Med* 1989;87:691-3.
3. RABBANI F, REUTER VE, KATZ J, RUSSO P. Second primary malignancies associated with renal cell carcinoma: influence of histologic type. *Urology* 2000;56:399-403.
4. GALL K, PAVELIC J, JADRO-SANTEL D, POLJAK M, PAVELIC K. DNA amplification by polymerase chain reaction from brain tissues embedded in paraffin. *Int J Exp Pathol* 1993;74:333-7.
5. MARUYAMA H, HASUIKE Y, FURUKAWA J, NAOI M, TAKATA N, YAYOI E, *et al.* Multiple colorectal carcinomas and colorectal carcinoma associated with extracolonic malignancies. *Jpn J Surg* 1992;22:99-104.
6. TURČIĆ M, ZNAOR A, NOVOSSEL I, RELJIĆ A, BELICZA M, KRUŠLIN B. Učestalost drugih primarnih tumora u bolesnika s primarnim karcinomom bubrega. *Acta Med Croat* 2005;59:91-5.

7. GACCI M, NATALI A, BARTOLETTI R, RIZZO M. Natural history of renal cell carcinoma. *J Urol* 2001;165:516-8.
8. DEMANDANTE CG, TROYER DA, MILES TP. Multiple primary malignant neoplasms: case report and a comprehensive review of the literature. *Am J Clin Oncol* 2003;26:79-83.
9. van der SIJP JR, van MEERBEECK JP, MAAT AP, ZONDERVAN PE, SLEDDENS HF, EGGERMONT AM, *et al.* Determination of the molecular relationship between multiple tumors within one patient is of clinical importance. *J Clin Oncol* 2002;20:1105-14.
10. SATO K, MAEKAWA T, YABUKI K, TAMASAKI Y, MAEKAWA H, KUDO K, *et al.* A case of synchronous cancers occurring in the gallbladder, common bile duct and pancreas. *J Gastroenterol* 2003;38:97-100.
11. GALLO O, SARDI I, PEPE G, FRANCHI A, ATTANASIO M, GIUSTI B, *et al.* Multiple primary tumors of the upper aerodigestive tract: is there a role for constitutional mutations in the p53 gene. *Int J Cancer* 1999;82:180-6.

Sažetak

P53 GUBITAK HETEROZIGOTNOSTI KOD VIŠESTRUKIH PRIMARNIH KARCINOMA BUBREGA, MJEHURA, PROSTATE I KOLONA

B. Spajić, K. Gall-Trošelj, I. Novosel, P. Kirac, Z. Jukić, O. Kraus i B. Krušlin

Višestruki primarni sinkroni maligniteti su vrlo rijetki, pa je iznimno teško naći točne i sukladne podatke o njihovoj incidenciji. Novija ispitivanja ukazuju na karcinom bubrežnih stanica kao na tumor koji pokazuje najizrazitiju udruženost s drugim vrstama istodobnih ili metakronih primarnih karcinoma. Prema našim saznanjima, ovo je prvi slučaj višestrukih primarnih adenokarcinoma bubrega, prostate i urotelnog karcinoma mokraćnog mjehura udruženih s primarnim sigmoidnim adenokarcinomom i kolostomnim metastazama analiziranih na p53 gubitak heterozigotnosti.

Ključne riječi: *Karcinom bubrežnih stanica – patologija; Neoplazme bubrega – patologija; Prikaz slučaja*