

PANHYPOPITUITARISM IN A 45-YEAR-OLD WOMAN: CASE REPORT

Martina Matovinović, Andreja Marić, Velena Radošević, Milan Vrkljan, Križo Katinić,
Vladimir Kalousek and Miljenko Kalousek

Department of Endocrinology, Diabetes and Metabolic Diseases, University Department of Medicine
Sestre milosrdnice University Hospital, Zagreb, Croatia

SUMMARY – A case of a 45-year-old woman with untreated panhypopituitarism is presented. Hypopituitarism is a rare disorder consisting of multiple deficiencies of hormones originating from the adenohypophysis. It is divided into primary and secondary. Primary disorders manifest at the pituitary level, whereas secondary hypopituitarism implies hypothalamic affection. Partial or total loss of all pituitary hormones is called panhypopituitarism. Hypopituitarism can be slow and insidious or severe and life-threatening. The expression of symptoms largely depends on the patient's age and the hormones involved. The leading symptom is growth retardation when the disorder develops in childhood or puberty. Sometimes years may elapse without accurate diagnosis, as in the case described. To date, only a few cases of untreated hypopituitarism have been published. In our patient, clinical examination revealed short stature and weak osteomuscular constitution, primary amenorrhea and lack of development of secondary sex characteristics. The patient's clinical history revealed signs of hypopituitarism from childhood, which had been untreated until she presented to our clinic. The results of complete testing showed the lack of all pituitary hormones and antidiuretic hormone, which was consistent with panhypopituitarism, including central diabetes insipidus.

Key words: *Hypopituitarism – etiology; Hypopituitarism – diagnosis; Pituitary gland – abnormalities; Growth; Case report*

Introduction

Hypopituitarism is a disorder of diverse etiology that results in a partial or total loss of pituitary hormone function. The clinical features vary according to the age of the patient, rapidity of the disease onset^{1,2}, particular hormones involved, and characteristics of the primary pathologic process. Hypopituitarism becomes clinically evident when more than 70 to 75 percent of the adenohypophysis is destroyed. Total loss of pituitary secretion requires at least 90 percent destruction of the pituitary gland.

Hypopituitarism can be divided into two categories, primary and secondary^{3,4}. The causes of primary hypopituitarism are pituitary tumors, ischemic lesions, inflammatory, neoplastic processes, iatrogenic, and autoimmune dysfunction. The causes of secondary hypopituitarism include hypothalamic tumor, inflammatory processes, trauma, and surgical procedures. The lack of all pituitary hormones is called panhypopituitarism.

Causes of Hypopituitarism

Primary hypopituitarism

Pituitary tumors

- adenomas
- craniopharyngeomas

Infarction or ischemic necrosis of the pituitary

- shock, especially postpartum (Sheehan's syndrome), or in diabetes mellitus or sickle cell anemia

Correspondence to: *Milan Vrkljan, M.D., Ph.D.*, Department of Endocrinology, Diabetes and Metabolic Diseases, Sestre milosrdnice University Hospital, Vinogradska c. 29, HR-10000 Zagreb, Croatia
E-mail: milan.vrkljan@zg.htnet.hr

Received March 25, 2005, accepted in revised form November 16, 2005

- vascular thrombosis or aneurysms, especially of the internal carotid artery
- sarcoidosis

Inflammatory processes

- meningitis (tubercular, fungal, malarial)
- pituitary abscesses

Infiltrative disorders

- Hand-Schüller-Christian disease (histiocytosis X)
- hemochromatosis⁵

Isolated or multiple pituitary hormone deficiencies

Iatrogenic

- irradiation
- surgical extirpation

Autoimmune dysfunction of the pituitary

Secondary hypopituitarism

Hypothalamic tumors

- pinealomas
- meningiomas
- ependymomas
- metastatic neoplasms

Inflammatory processes such as sarcoidosis

Trauma⁶

Isolated or multiple neurohormone deficiencies of the hypothalamus

Surgical transection of the pituitary stalk

Clinical Features

Clinical features of hypopituitarism are most often insidious⁷ and may not be recognized as abnormal by the patient, but occasionally it may be sudden or dramatic⁸. Gonadotropins are usually lost first⁹, followed by growth hormone (GH) and finally by thyroid-stimulating hormone (TSH) and adrenocorticotrophic hormone (ACTH) loss. Especially important is a lower function of the thyroid and adrenal glands due to their production of life indispensable hormones. Antidiuretic hormone (ADH) deficiency is rare in primary pituitary disease but is common in pituitary stalk and hypothalamic lesions. The function of all target glands will decrease when all hormones are deficient. The lack of luteinizing hormone (LH) and follicle-stimulating hormone (FSH) in wom-

en leads to amenorrhea, regression of secondary sexual characteristics, and infertility. The lack of the gonadotropins in men results in impotence, testicular atrophy, regression of secondary sexual characteristics, and decreased spermatogenesis with consequent infertility. It should be emphasized that reduced LH and FSH secretion can be caused by excessive prolactin (PRL) secretion due to disorders of the pituitary or pituitary stalk with decreased secretion of prolactin-inhibiting factor, and lead to secondary hypogonadism. GH deficiency is generally not clinically detectable in adults. TSH deficiency leads to hypothyroidism, and ACTH deficiency results in hypocorticism with attendant fatigue, hypotension, and intolerance to stress and infection. The main diagnostic test is to evaluate endocrine function by hormone status determination.

Case Report

A 45-year-old woman, a refugee from Bosnia, came for the first time to the Department of Endocrinology, Diabetes and Metabolic Diseases, Sestre milosrdnice University Hospital in Zagreb, for additional endocrinologic evaluation. The patient was transferred from another clinical hospital, where she was admitted for abdominal pain, vomiting and weight loss. The patient's medical history indicated that she may have suffered inflammation of the ear and brain when she was five months old. After that medical event she showed retarded growth and development. When she was 20 years old, she underwent a medical procedure for growth retardation. The findings showed hypogonadotropic hypogonadism, however, the patient gave up control visits and did not take any therapy. Now, she complained of frequent thirst and polyuria. In physical status, we emphasize weak osteomuscular constitution without facial abnormalities, extremely short body height (136 cm, 33 kg, BMI 17.8 kg/m²), and primary amenorrhea without secondary sex signs. The patient seemed to be emotionally unstable and introverted. We started endocrinologic evaluation, which yielded low values of all peripheral hormones. Neuroradiologic findings revealed empty sella turcica. X-ray showed open epiphyseal gaps in the distal portion of the ulna and radius, and osteoporosis of carpal bones. Osteoporosis was also confirmed by densitometry (DXA) of the femoral column and lumbar spine.

Diagnostic evaluation

Endocrinologic study

We measured the values of triiodothyronine (T3), thyroxine (T4) and TSH, which were low borderline (T3 1.1 nmol/L, normal range 1.1-2.8 nmol/L; T4 75 nmol/L, normal range 60-165 nmol/L; TSH 1.24 mIU/L, normal range 0.3-4.5 mIU/L). The levels of gonadotropins were extremely low (LH <0.10 IU/L, normal range 1.9-8.0 IU/L; FSH <0.10 IU/L, normal range 2.4-9.3 IU/L) with consecutive low levels of peripheral sex hormones (estradiol <50 pmol/L, normal range 92-367 pmol/L, progesterone <0.3 nmol/L, normal range 0.3-3.8 nmol/L, testosterone <0.5 nmol/L, normal range 0.7-2.5 nmol/L). The levels of ACTH (3.2 pmol/L at 8 a.m., 4.5 pmol/L at 5 p.m., normal range 2.0-13.3 pmol/L) and cortisol were low borderline and indicative of the lack of circadian rhythm (cortisol 50 nmol/L at 8 a.m., normal range 138-800 nmol/L, and 707 nmol/L at 5 p.m., normal range 80-488 nmol/L). The value of IGF-1 was low (<157 IU/L, normal range 600-2200 IU/L), whereas the level of GH was normal (1.26 ng/mL; normal range 0-5.0 ng/mL). Laboratory findings revealed a high total cholesterol level (7.6 nmol/L, normal range 3.6-5.2 nmol/L) predominated by a high LDL fraction (6.37 nmol/L, normal range <3.3 nmol/L). To evaluate stress reserve and stress response, we performed insulin tolerance test (ITT). During two-hour ITT test, a decreased stress response was established measuring serum cortisol (Fig. 1) and growth hormone levels. The levels of ADH in 24-h urine were extremely low (15.1 ng dU/L, normal range 30-90 ng dU/L).

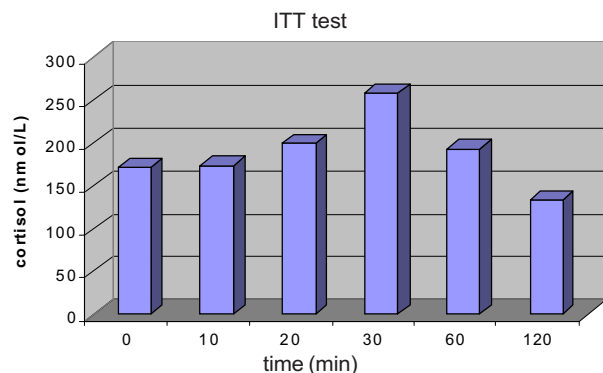


Fig. 1. Cortisol response in insulin tolerance test in our patient with panhypopituitarism.

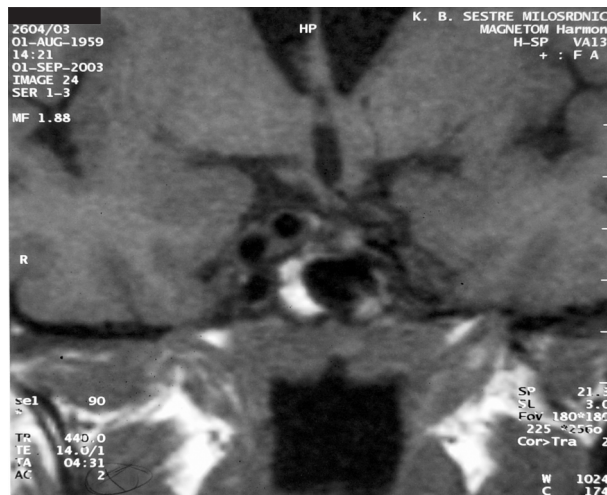

Fig. 2. MRI of the sellae and parasellae in our patient, showing a homogenic imbibition at the bottom of sella, corresponding to hypophyseal parenchyma, and hypoplastic left internal artery (coronal T1 section).

Radiologic study

Magnetic resonance imaging (MRI) is the first diagnostic study in patients with a suspected pituitary disorder¹⁰. MRI is the supreme method because it can resolve complicated anatomic relations in the pituitary region better than computed tomography (CT). It is especially useful in estimating tumor growth, progression, development disorder, visual field lesions, and therapeutic response.

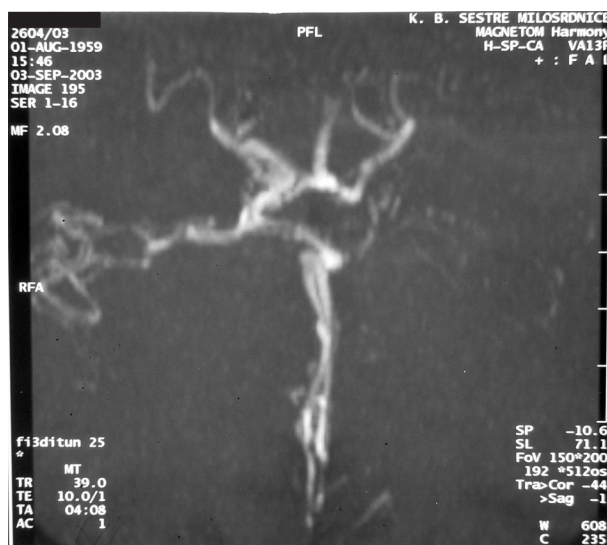


Fig. 3. MR angiography in our patient with panhypopituitarism, showing a hypoplastic left internal carotid artery.

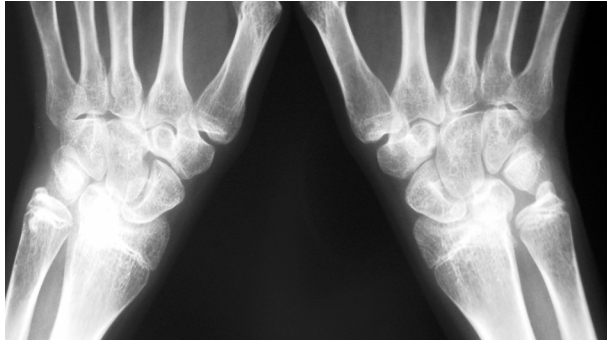


Fig. 4. X-ray in our patient with untreated panhypopituitarism, showing a partially ungrown epiphyseal gaps of the distal parts of the radius and ulna.

We performed MRI of the sellar and parasellar region. On precontrast scans there were no definite signs of hypophyseal tissue but postcontrast scans showed homogeneous imbibition at the bottom of the sella that could correspond to hypophyseal gland parenchyma¹¹ (Fig. 2). The chiasm was placed lower as a consequence of empty sella. Left internal carotid artery seemed to be hypoplastic, which was confirmed on MR angiography¹² (Fig. 3).

To estimate the patient's maturation, we performed an x-ray. The x-ray showed partially ungrown epiphyseal gaps of the distal parts of the radius and ulna with concomitant osteoporosis of metacarpal bones (Fig. 4), confirmed by densitometry (DXA) of the femoral column and lumbar spine.

Additional studies

Visual perimetry according to Goldman revealed no pathologic events at the chiasmatic level or through the visual tract. There were no pathologic findings on vision testing and fundus examination. Psychological evaluation showed mental retardation, more precise moderate grade oligophreny. There were no neurologic abnormalities.

Discussion

Hypopituitarism is an endocrine deficiency syndrome due to partial or complete loss of anterior lobe pituitary function. A state of loss of all pituitary hormones, including the lack of ADH, as described in our case, is named panhypopituitarism. The cause of hypopituitarism can be pituitary tumor¹³, which was excluded in our patient on the basis of MR finding. Other causes

such as inflammatory diseases could be one of the causes, however, in our patient's medical history we found some indistinct data on having suffered meningitis and otitis without any reliable medical documentation, so we could also neglect it. Hemochromatosis, an infiltrative system disorder was ruled out in the patient. The patient denied a history of any cranial surgical procedures, brain trauma, and irradiation. We found no medical documentation on the mentioned events. The clinical features of our patient were predominated by the presence of low stature and regression of secondary sexual characteristics, what is consistent with known fact that gonadotropin is usually lost first followed by growth hormone¹⁴. The lack of luteinizing hormone and follicle-stimulating hormone caused amenorrhea, regression of secondary sexual characteristics and infertility. The values of thyroid-stimulating hormone and adrenocorticotropic hormone were at the lower limit of normal range, which was connected with final reduction in the function of these cells, and symptoms of hypothyroidism and hypocorticism (with the symptoms she had presented before she came to us: abdominal pain, vomiting, weight loss). ADH deficiency led to frequent thirst and polyuria. The regular sequence of examinations in pituitary disease included endocrinologic, metabolic, neuroradiologic and ophthalmologic studies. Definitive diagnosis of panhypopituitarism and central diabetes insipidus was established.

The case presented is our first experience with panhypopituitarism in a 45-year-old woman, with open epiphyseal gaps of the distal portion of the ulna and radius^{15,16}, implying that the growth had not yet been completed, thus the growth process could not fulfill its own complete biological potential, although the patient reached her middle age. Therefore, we started with hormone replacement therapy with glucocorticoids, thyroid hormones, ADH and growth hormone. Sex hormones were not yet to be replaced despite osteoporosis and amenorrhea, because we tried to induce growth in our patient until the epiphyseal gaps of the ulna and radius got closed. Regular medical controls after 3 months, and then every 6 months, with complete clinical examination and endocrinologic testing, have been prescribed.

This case revealed many open questions. How did the patient manage to reach that age despite low values of the vital hormones necessary for life and growth? The possible cause of the disorder may have been some illness she had suffered in childhood (otitis, meningitis) or a vascular anomaly, hypoplasia of the internal carotid

artery, with possible collateral blood supply of the pituitary, inadequate for complete pituitary function. A further question is the possible association between the lack of hormones and impaired mental performance. It is interesting that a 45-year-old woman with growth and sexual retardation and clinical signs of diabetes insipidus failed to be properly managed and followed up by medical profession.

To our knowledge, only seven case reports of untreated hypopituitarism have been published to date¹⁷, only two of them with central diabetes insipidus, but with no data on any vascular anomaly, as in our case.

It was a very interesting and complicated medical case that necessitated involvement of several clinical specialties to reach the accurate diagnosis and therapy.

References

- BÜLOW B, HAGMAR L, MIKOCZY Z. Increased cerebrovascular mortality in patients with hypopituitarism. *Clin Endocrinol* 1997;46:75-81.
- BATES AS, VAN'T HOFF W, JONES PJ, CLAYTON RN. The effect of hypopituitarism on life expectancy. *J Clin Endocrinol Metab* 1996;81:1169-72.
- FROHMAN LA. Diseases of the anterior pituitary. Hypopituitarism. In: FELIG P, BAXTER JD, FROHMAN LA, eds. *Endocrinology and metabolism*. New York: McGraw-Hill, Inc., 1995. p. 313-27.
- LAMBERTS SW, DE HERDER WW, VAN DER LELY AJ. Pituitary insufficiency. *Lancet* 1998;352:127-34.
- WILLIAMS T, FROHMAN LA. Hypothalamic dysfunction associated with hemochromatosis. *Ann Intern Med* 1981;95:166.
- EDWARDS OM, CLARK JDA. Post-traumatic hypopituitarism. *Medicine* 1986;62:281.
- NAVARRO P, HALPERIN I, RODRIGUEZ C, GONZALEZ JM, VIDAL J, VILARDELL E. Congenital panhypopituitarism of late onset. *J Endocrinol Invest* 1994;17:347-50.
- TOLIS G, CRUESS S, GOLDSTEIN M, FRIESEN HG, ROCHEFORT JG. Survival and growth in a woman with untreated hypothalamic panhypopituitarism of 21 years' duration. *Can Med Assoc J* 1974;111:553-6.
- WADA S, MINAGAWA A, IMAMAKI K, SUDA S, YAMANAKA K, IITAKA M, *et al.* A patient of hypogonadotropic hypogonadism accompanied by growth hormone deficiency and decreased bone mineral density who attained normal growth. *Intern Med* 2000;39:641-5.
- CHAKERES DW. Magnetic resonance imaging of pituitary and parasellar abnormalities. *Radiol Clin North Am* 1989;27:265.
- HAMILTON J, BLASER S, DANEMAN D. MR imaging in idiopathic growth hormone deficiency. *Am J Neuroradiol* 1998;19:1609-15.
- HAMILTON J, CHITAYAT D, BLASER S, COHEN LE, PHILIPS III JA, DANEMAN D. Familial growth hormone deficiency associated with MRI abnormalities. *Am J Med Genet* 1998;80:128-32.
- PENTIMONE F, RICCIONI S, DEL CORSO L. Congenital hypopituitarism in a 48-year old adult. Natural course, hormonal study and MRI evidence. *Panminerva Med* 1999;41:351-4.
- VAN DER WERFF TEN BOSCH JJ, BOT A. Growth of males with idiopathic hypopituitarism without growth hormone treatment. *Clin Endocrinol (Oxf)* 1990;32:707-17.
- GREULICH WW, PYLE SI. *Radiographic atlas of skeletal development of the hand and wrist*. Stanford, CA: Stanford University Press;1959.
- THORNER MO, BENGTSSON BA, HO KKY. Consensus guidelines for the diagnosis and treatment of adults with growth hormone deficiency: summary statement of the Growth Hormone Research Society Workshop on Adult Growth Hormone Deficiency. *J Clin Endocrinol Metab* 1998;83:379-81.
- DEN OUDEN DT, KROON M, HOOGLAND PH, GEELHOED-DUIJVESTIJN PHLM, WIT JM. A 43-year-old male with untreated panhypopituitarism due to absence of the pituitary stalk: from dwarf to giant. *J Clin Endocrinol Metab* 2002;87:5430-4.

Sažetak

PANHIPOPITUITARIZAM U 45-GODIŠNJE BOLESNICE: PRIKAZ SLUČAJA

M. Matovinović, A. Marić, V. Radošević, M. Vrkljan, K. Katinić, V. Kalousek i M. Kalousek

Prikazuje se slučaj 45-godišnje bolesnice s neliječenim panhipopituitarizmom. Hipopituitarizam je rijedak poremećaj koji obilježava manjak više hormona prednjega režnja hipofize. Može biti primaran ili sekundaran. Primarni poremećaji nastaju na razini hipofize, dok su sekundarni na razini hipotalamusa. Djelomičan ili potpun manjak svih hormona hipofize naziva se panhipopituitarizam. Tijek hipopituitarizma može biti spor i podmukao ili nagao i životno ugrožavajući. Izražajnost simptoma ovisi prvenstveno o dobi bolesnika te zahvaćenim hormonima. Vodeći simptom je zaostajanje u rastu, kada bolest zahvati bolesnika u djetinjstvu ili pubertetu. Ponekad može proći niz godina bez potpune dijagnoze, kao što je opisano i u naše bolesnice. Do danas je objavljeno svega nekoliko slučajeva neliječenog hipopituitarizma. Kliničkim pregledom naše bolesnice nađen je nizak rast i slaba osteomuskularna građa, primarna amenoreja i nerazvijene sekundarne spolne značajke. Anamnestički podaci otkrivaju sliku hipopituitarizma od dječje dobi, ali bolesnica nije liječena do dolaska u našu kliniku. Rezultati sveobuhvatne obrade pokazali su manjak svih hormona hipofize i antidiuretičnog hormona, što govori u prilog panhipopituitarizma, uključujući i centralni dijabetes insipidus.

Ključne riječi: *Hipopituitarizam – etiologija; Hipopituitarizam – dijagnostika; Hipofiza – nenormalnosti; Rast; Prikaz slučaja*